Acta Chirurgica

ACADEMIAE SCIENTIARUM HUNGARICAE

EDITORIAL BOARD

BABICS ANTAL (chairman of the board), CSATA SÁNDOR (managing editor), PETRI GÁBOR (president), GLAUBER ANDOR, IHÁSZ MIHÁLY, MÉREI F. TIBOR, PÁSZTOR EMIL, RADNÓT MAGDA, RUBÁNYI PÁL, SURJÁN LÁSZLÓ, SZÉCSÉNY ANDOR, ZOLTÁN IMRE, ZSOLNAI BÉLA

ACTA CHIR. HUNG. TOMUS XXIII • FASCICULUS 1

AKADÉMIAI KIADÓ, BUDAPEST
1982

ACTA CHIRURGICA

ACADEMIAE SCIENTIARUM HUNGARICAE

A MAGYAR TUDOMÁNYOS AKADÉMIA ORVOSTUDOMÁNYI FOLYÓIRATA

FŐSZERKESZTŐ:

Dr. BABICS ANTAL akadémikus

SZERKESZTŐ:

Dr. CSATA SÁNDOR, az orvostudományok kandidátusa

A SZERKESZTŐSÉG CÍME: H-1096 BUDAPEST, NAGYVÁRAD TÉR 1. ISTVÁN KÓRHÁZ, UROLÓGIA
KIADJA AZ AKADÉMIAI KIADÓ, H-1054 BUDAPEST, ALKOTMÁNY U. 21.

Az *Acta Chirurgica* német, angol, francia, ill. orosz nyelven tudományos értekezéseket közöl a sebészet (általános sebészet, nőgyógyászat, urológia, oto-rhino-laryngológia, orthopaedia, szemészet, agy- és idegsebészet, tüdősebészet, szájsebészet, szív- és érsebészet stb.) tárgyköréből.

Az *Acta Chirurgica* évente 1 kötetben jelenik meg, mintegy 400 oldal terjedelemben. A kötet 4, negyedévenként megjelenő füzet formájában kerül kiadásra.

A közlésre szánt kéziratok, valamint a szerkesztőségi levelezés az alábbi címre küldendők:

Acta Chirurgica
H-1096 Budapest, Nagyvárad tér 1. István Kórház, Urológia

Megrendelhető a belföld számára az Akadémiai Kiadónál (1363 Budapest Pf. 24. Bankszámla: 215-11448), a külföld számára pedig a „Kultura" Külkereskedelmi Vállalatnál (1389 Budapest 62, P.O.B. 149. Bankszámla: 218-10990) vagy annak külföldi képviseleteinél és bizományosainál.

Die medizinwissenschaftliche Zeitschrift der Ungarischen Akademie der Wissenschaften *Acta Chirurgica* veröffentlicht Originalbeiträge ungarischer und ausländischer Wissenschaftler aus dem Themenkreis der Chirurgie und der verwandten Gebiete (allgemeine Chirurgie sowie die chirurgischen Beziehungen der Gynäkologie, Urologie, Oto-Rhino-Laryngologie, Orthopädie, Ophthalmologie usw., ferner Neurochirurgie, Gehirnchirurgie, Herz- und Gefäßchirurgie usw.) in deutscher, englischer, französischer oder russischer Sprache, mit kurzen anderssprachigen Zusammenfassungen.

Die *Acta Chirurgica* erscheinen jährlich in einem Band — im Umfang von etwa 400 Seiten — vier in vierteljährlichen Heften.

Die zur Veröffentlichung bestimmten Manuskripte sind an folgende Adresse zu senden:

Acta Chirurgica
H-1096 Budapest, Nagyvárad tér 1. István Kórház, Urológia

Bestellbar bei »Kultura« Außenhandelsunternehmen (H-1389 Budapest 62, P.O.B. 149) oder seinen Auslandsvertretungen.

Acta Chirurgica

ACADEMIAE SCIENTIARUM HUNGARICAE

EDITORIAL BOARD

BABICS ANTAL (chairman of the board), CSATA SÁNDOR (managing editor), PETRI GÁBOR (president), GLAUBER ANDOR, IHÁSZ MIHÁLY, MÉREI F. TIBOR, PÁSZTOR EMIL, RADNÓT MAGDA, RUBÁNYI PÁL, SURJÁN LÁSZLÓ, SZÉCSÉNY ANDOR, ZOLTÁN IMRE, ZSOLNAI BÉLA

TOMUS XXIII

1982

ACTA CHIRURGICA

TOMUS XXIII

INDEX

Balogh, Á., Szlávy, L., Sulyok, Z., Tóth, L. and *Besznyák, I.:* Diagnostic angiography in tumours of the neck 1
Csordás, T. and *Bertók, L.:* Effect of lead acetate on the endotoxin susceptibility of pregnant rats 9
Csata, S., Kulcsár, Gizella, Dán, P., Horváth, J., Nász, I., Ongrádi, J. and *Verebélyi, A.:* Adenovirus antibodies in tumorous diseases of the urogenital system 15
Galuska, L. and *Gervain, M.:* Investigation of the functioning of the ileum-ureter by means of camera renography 23
Szilágyi, I., Réffy, A., Demel, Zs. and *Józsa, L.:* Amyloidosis of bones 33
Szabó, V., Pajor, L., Sóbel, M. and *Balogh, F.:* Ultrasonic diagnosis of suprarenal adenoma 39
Papp, Gy., Gróf, J. and *Menyhárt, J.:* Disorders of the urea cycle in pathospermias 45
Papp, Gy. and *Balogh, Zsuzsa:* Successful vasoepididymoanastomosis by microsurgery 55
Tarsoly, E., Bornemisza, Gy. and *Furka, I.:* Tissue reaction to Hystoacryl Blue adhesive and histological investigation of its disappearance in various organs 61
Papp, L., Mezei, B., Osváth, B. and *Szabó, Z.:* Thermography in artificially induced coronary circulatory disorders 75
Gervain, M., Karácsony, Gizella and *Mohácsi, G.:* Experimental ureteroileal anastomosis 83
Ihász, M., Balázs, Mártha, Csillag, A., Szabó, K. and *Horkai, F.:* Carcinoid tumours of the gastrointestinal tract 95
Csáky, G., Balázs, Gy., Lukács, G., Szokol, M., Erdei, I., Balázs, Cs. and *Kincses, Éva:* Simultaneous occurrence of Graves' disease with endocrine ophthalmopathy, thyroiditis and thyroid carcinoma 117
Kovács, L., Pályi, I. and *Tisza, S.:* Effect of low-output He—Ne laser rays on the colony-forming ability of the cells of mice lymphoma 131
Szabó, L. E., Csikós, F., Helembai, L., Karádi, J. and *Csiba A.:* Metronidazole in the chemoprophylaxis of colon and rectum operations 135
Solti, F., Soltész, L., Ungvári, Gy., Szlávy, L. and *Gloviczky, P.:* Limb circulation after deep venous thrombosis 145
Antal, A. und *Lantos, J.:* Elektrometrische Messungen (pH, pK) auf der Organoberfläche bei experimenteller Änderung des Leberkreislaufes 153
Vallent, K., Fehér, J., Somogyi, Anikó und *Joós, Ágnes:* Angioneurotisches Ödem und Hypokomplementämie bei Schilddrüsenkarzinom 163
Magasi, P., Ruszinkó, B. und *Végh, A.:* Transvesikale Prostatektomie und ihre Komplikationen 173
Lukács, L. and *Péter, S.:* Early recognition of cutaneous malignant melanomas 183
Csata, S., Verebélyi, A. and *Gorka, A.:* Über das Nieren-Angioleiomyolipom 193
Hübler, J., István, M., Gimes, L. und *Nagy, Z.:* Die Epidermoidzyste des Hodens 205
Sápy, P., Mikó, Irén and *Furka, I.:* Comparison of suture materials in the pancreas 209
Csontai, Á., Nádas, Gy., Makó, J., Pánovics, J. and *Balogh, F.:* Diagnosis and treatment of adult polycystic kidney disease 217
Korányi, E., Zágh, I., Kottász, S. und *Kendelényi, E.:* Urologische Komplikationen bei Beckenfrakturen 229
Kottász, S. and *Szijjártó, F.:* Treatment of acute suppurative nephritis 235
Józsa, L., Réffy, A. and *Renner, A.:* Tumours arising in skeletal muscles and in tendons in adults 243
Szabó, V., Juhász, J. und *Balogh, F.:* Blutstillung der transvesikalen Prostatektomie mit einer modifizierten U-förmigen Nadel 249

Acta Chirurgica Academiae Scientiarum Hungaricae, Tomus 23 (1), pp. 1–7 (1982)

Diagnostic Angiography in Tumours of the Neck

Á. BALOGH,[1] L. SZLÁVY[3], Z. SULYOK[2], L. TÓTH[2] and I. BESZNYÁK[1]

National Institute of Oncology[1] Institute of Vascular Surgery[2] and Department of Radiology[3], Semmelweis University Medical School, Budapest

(Received July 30, 1980)

In two and a half years, 272 patients with diseases localized to the head and neck, including 143 patients with tumour, were admitted. Diagnostic angiography was performed in 13 cases. The diagnostic value and indications of angiography are discussed. The information supplied by angiography may be decisive in the diagnosis of tumours of the head and neck and for judging the operability and the course of the operation planned.

Routine application of angiography has reduced its complications to a minimum [2, 3, 5, 17] and contributed to the widespread use of the method in the diagnostics of tumours [4, 5, 9, 13, 17].

Nevertheless, the possibilities offered by angiography are not sufficiently exploited for the diagnosis of tumours of the head and neck. [13, 17]. Papers have been published on the diagnostics of tumours of the head and neck without even mentioning angiographic examination [7].

Since May 1, 1977 angiography has routinely been performed in all patients with head and neck tumours. Our experience is reported in the following.

Material and Method

Between May 1, 1977, and October 15, 1979, we have treated 272 patients with diseases localized to the head and neck. Of the patients, 129 suffered from globular goitre, 9 of which were substernal. Two patients had no tumour, but the superior vena cava syndrome induced us to perform superior cavography. Among the 143 tumour patients, 78 had a malignant goitre.

The angiographic methods used were, arch aortography and selective presentation of the vessels of the area under investigation, carotid arteriography, superior cavography, venography of the upper limbs, and lymphangiography.

Angiography was performed in 13 patients.

Arch aortography and selective examination of the afflicted vessels were performed in four cases by Seldinger's percutaneous catheterization. Arch

aortography was indicated in two patients by clavicular tumour and in another two by supraclavicular tumour. No superselective tests were used [1, 14, 18]. No complications occurred.

1. A 63-year-old woman was admitted with a tumour on her left clavicle which had been growing since a year. The lesion of the size of a female fist had destroyed the medial part of the collar bone and was intensely pulsating. The patient had been sent to us with the diagnosis of aneurysm of the subclavian artery. Arch aortography and selective angiography of the left subclavian and the common carotid arteries revealed a richly vascularized tumour not in direct contact with the subclavian artery. The tumour was removed after resection of the left clavicle. Histology showed a hypernephroma metastasis. The primary tumour was confirmed by pyelography and six weeks after the first operation the patient was subjected to nephrectomy on the left side. At present, two years after the operations, the patient has no complaints and regular check-ups have not revealed signs of relapse or of metastasis.

2. A 43-year-old man was admitted with a tumour which had been growing for three years. The fist-sized tumour filled the supraclavicular fossa, its middle part formed a protrusion of nut size directly above the subclavian artery and vein. Arch aortography revealed a fist-sized richly vascularized tumour which was not in direct contact with the subclavian artery (Fig. 1). The lesion seemed technically operable, but supplementary lymphangiography revealed lymph node metastases in the right axillary fossa and in the anterior-superior mediastinum, so that the patient could not be operated.

Percutaneous carotid angiography was performed in five patients. In two cases angiography was carried out because of a carotid body tumour for which carotid angiography is the diagnostic method of choice [3, 4, 6, 8, 10, 12, 14], and in two cases because of malignant struma metastasizing in the region of the internal jugular vein and of the sternocleidomastoid muscle, while in one case angiography was indicated by a tumour of the parotis.

3. In a 63-year-old woman a very painful tumour was localized behind and below the mandibular angle. The tumour which had been growing for a year extended to the mastoid process, lifted the upper third of the sternocleidomastoid muscle and the tonsil, and vaulted forward into the pharynx. Biopsy seemed risky because of the intense pulsation of the tumour on its pharyngeal side. Carotid angiography proved unambiguously that the tumour of the carotid body pushed the carotid branching widely apart and dislocated the extracranial sections of the external and internal carotid arteries. Multiple changes in the course of the vessels confirmed the intracranial spreading of the tumour, so that the patient was considered inoperable.

4. A man aged 56 had been operated 25 years ago for a tumour of the left parotis. No histological findings were available. Three years before being referred to us a tumour had started to grow in front and below the left ear,

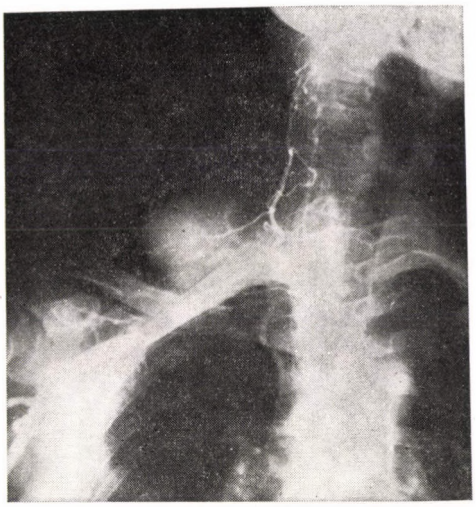

FIG. 1. *Case 2*: angiographic picture of a 43-year-old male patient. The angiogram clarified the relation of the tumour filling the supraclavicular fossa to the subclavian artery, traced the supplying arteries and the vascularization of the tumour

causing a forward vaulting of the angle of the mandible and spreading to the neck. The tumour could be moved on its base and examined from the oral cavity, seemed mobile and technically operable. Carotid angiography showed tumorous destruction of the large wing of the petrous bone, dislocation of the anterior and middle cerebral arteries and shifting of the sagittal sinus to the other side (Dr. Kenéz, Institute of Radiology, Fig. 2). Angiography indicated the inoperability of the tumour.

Superior cavography was performed in three cases. The information yielded by this method made us to attempt to remove the substernally localized goitre from an incision on the neck. The operations were successful. The third case will be reported in some detail. On the right side of the neck of a 56-year-old man an egg-sized growth appeared after every swallowing. He was referred to us with the diagnosis of a goitre. Chest X-rays showed a lesion expanding the upper anterior mediastinum and the patient complained of oedema of the eyelids in the morning. Suspecting an incipient superior vena cava syndrome superior cavography was performed in the later phase of which a pneumoangiogram was prepared to check the filling of the pulmonary artery. The tests confirmed a tumour in the mediastinum causing a considerable compression of the superior vena cava and infiltrating the upper lobar branches of the right pulmonary artery, so that filling of the pulmonary system was missing in the upper lobe of the right lung (Fig. 3). Consequently, the tumour was considered inoperable and only a lymph node biopsy was done.

Superior cavography was performed with the contrast material injected simultaneously on both sides by a catheter passed through the cubital veins

into the subclavian veins this being the only means to obtain clearly assessable pictures at the raised venous pressure in the cases of cava superior syndrome.

In one case venography of the upper limb allowed to form the correct diagnosis.

FIG. 2. *Case 4*: A characteristic angiographic picture of the left carotid artery (Dr. Kenéz, Institute of Radiology, Budapest). Beside bone destruction the picture clearly shows the dislocation to the right of the anterior cerebral artery and upward of the point Sylvius, indirect signs of the intracranial presence of tumour

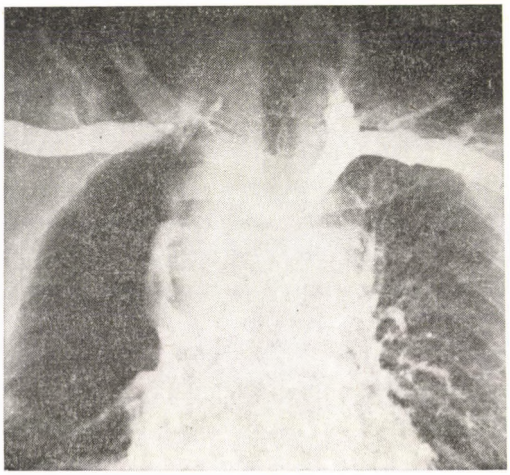

FIG. 3. *Case 5*: Cavographic pictures in the phase when the superior vena cava system is still clearly outlined by the contrast material, the pulmonary arterial system is already being filled. The picture shows a subtotal stenosis of the right brachycephalic vein. Compression of the superior vena cava and lack of filling in of the arteries of the right upper pulmonary lobe, with complete filling of the left pulmonary artery

6. A 28-year-old man had developed a thickening of the middle third of the clavicle and was referred to us with the diagnosis of a tumour of the clavicle. The history revealed an injury of the clavicle during physical exercise five months before. Venography of the left upper limb showed normal filling of the subclavian vein, reflecting normal conditions. We did not consider the process to be a tumour which was confirmed by bone biopsy. The histological finding showed a chronic periosteal reaction.

In this last case we performed venography, because the signs of compression produced by some space reducing process can be expected to appear earlier on the vena cava with its thin wall than on the elastic artery the wall of which is thicker.

Discussion

Angiography is regularly applied in the diagnosis of tumours of the head and neck. The choice of the type of angiography depends upon the nature of the process, the clinical picture and the symptoms. Quite often, the methods used together will give the correct diagnosis. In agreement with other authors [3, 4, 6, 8, 10, 12, 16, 17] we believe that carotid angiography is indispensable for the diagnosis of tumours of the carotid body, while superior cavography often gives useful information about cervical processes spreading to the mediastinum. In our practice we did not apply superselective arteriography, a method recommended by a number of authors [1, 8, 9, 11, 14, 18]. Neither did we apply perlingual lymphography which, according to the description of Gruart et al. [8], seems an ingenious and useful method.

The information is obtained by angiography on:

1. the extension of the process;
2. the vessels supplying the tumour;
3. the degree of vascularization, a basis for the assessment of malignancy;
4. the relationship of the process to the larger vascular trunks in its environment; this will help in the choice of the type of operation and of penetration;
5. the extension of the process to other (chest or intracranial) regions;
6. collateral circulation if the tumour causes arterial stenosis or occlusion, (e. g. when the internal carotid is affected, angiography may clarify whether the flow through the circle of Willis will permit carotid resection);
7. the necessity of vascular reconstruction during the operation;
8. whether the tumour causes venous compression;
9. the presence and extension of lymph node metastases (lymphangiography).

Clarification of all these conditions prior to surgery will help in the assessment of operability [1, 3, 4, 5, 13, 18], in the planning of the operation, and in the choice of penetration [3, 8, 10, 13, 15].

Indication of angiography in the diagnosis of the tumours of the head and neck can be summed up as follows.

1. When the localization, size or clinical symptoms of the tumour point to the involvement of the large vessels of the region;

2. when the origin, extension, nature, blood supply and vascularization of the tumour is not clear;

3. when metastases are looked for;

4. when penetration of the process to other regions has to be revealed.

References

1. Ayella RJ: A new method of catheterizing the great vessels arising from the aortic arch. Radiology 110:714, 1974
2. Balogh Á, Mogán I, Soltész L, Besznyák I: Acut iatrogen érkárosodások (Acute iatrogenic vascular lesions). Orv Hetil 117:2873, 1976
3. Barrett A: Value of angiography in the management of tumours of the head and neck. Radiology 84:1052, 1965
4. Barrett A: Angiography for extracranial tumors. Acta Radiol. [Diagn] (Stockh) 5: 110, 1966
5. Besznyák I, Pénztáros I, Czakó E: Angiographische Diagnostik der Krankheiten des Mediastinums und der Lunge. Acta Chir Acad Sci Hung. 17:17, 1976
6. Conley JJ, Chusid JG, Schechter MM: Angiography in head and neck surgery. Arch Surg 89:609, 1964
7. Doberneck RC: Diagnosis and treatment of the solitary mass in the neck. Am J Surg 40:181, 1974
8. El Gammal T: The blood supply of chemodectoma of the head and neck: report of two cases. Br J Radiol 44:515, 1971
9. Gruart FJ, Yoel J, Wagner AM: Value of perlingual lymphography in cancer of the head and neck. A means of exploration of the lymphatic system of the neck. Am J Surg 114:520, 1967
10. Howell A, Monasterio J, Stuteville OH: Chemodectomas of the head and neck. Surg Clin North Am 53:175, 1973
11. in der Maur GAP, van der Vegt JH: The angiographic visualisation of a cervical lymph node. Fortschr Röntgenstr 129:520, 1978
12. Irwin GAL: Carotid body tumors. Am J Roentgenol 95:769, 1965
13. Mandel MA, Kiehn CL, Sykora GF: Use of angiography in outlining solitary solid tumors of the head and neck. Plast Reconstr Surg 52:61, 1973
14. Oberson R, Otto R, Wiggli U, Dutoit ML: L'angéiographie supersélective de la face et du cou. Schweiz. Med. Wochenschr 103:992, 1973
15. Polyánszky T, Rónay P, Daubner, K: Nyaki daganatok sebészete (Surgery of neck tumours). Medicina, Budapest 1978
16. Southwick HW: Advances in detection and diagnosis of head and neck tumours. Cancer 37:604, 1976.
17. Tsyb AF, Vtiiurin BM: Angiographic methods in jugular tumors (in Russian) Vestn Khir 111/10:21, 1973
18. Wells SA, Doppman JL, Belezkian JP, Shimkin PM, Povell D, Ketcham AS, Aurbach CD: Repeated neck exploration in primary hyperparathyroidism: localisation of abnormal glands by selective thyroid arteriography, selective venous sampling and radioimmunoassay. Surgery 74:678, 1973

Über die Bedeutung der Angiographie in der Diagnostik und der chirurgischen Therapie der zervikalen Tumoren

Á. Balogh, L. Szlávy, Z. Sulyok, L. Tóth und I. Besznyák

Auf die Abteilung wurden wegen einer am Kopf oder am Hals lokalisierten Krankheit im Verlauf von zweieinhalb Jahren 272 Patienten aufgenommen; in 143 dieser Fälle handelte es sich um eine tumoröse Veränderung. In 13 Fällen wurden mit diagnostischem Ziel angiographische Untersuchungen vorgenommen. Damit im Zusammenhang finden die Formen, der diagnostische Wert und die Indikationen, im Spiegel des eigenen Materials eine Besprechung. Die gesammelten Erfahrungen erlauben die Feststellung, daß in der Diagnostik, der Beurteilung der Operabilität und der Festlegung des Operationsplanes der Kopf- und Halstumoren die durch die angiographischen Untersuchungen gelieferten Informationen nützlich bzw. — in gewissen Fällen — sogar entscheidend sein können.

Значение ангиографии в диагностике и оперативном лечении шейных опухолей

А. БАЛОГ, Л. СЛАВИ, З. ШУЙОК, Л. ТОТ и И. БЕСНЯК

Авторы приняли в хирургическое отделение Государсвенного онкологического института за два с половиной года 272 онкологического института за два с половиной года 272 больных с заболеваниями шейной и головной локализации, среди которых у 143 имелись опухолевые изменения. У 13 из них были проведены диагностические ангиографические исследования. Авторы знакомят с типами ангиографических исследований, с их диагностической ценностью и показаниями к их проведению. Все описываемое они иллюстрируют собственным материалом. По их мнению, в диагностике опухолей шеи и головы, в решении относительно их операбильности и разработке оперативного подхода является полезной, а иногда и просто необходимой информация, которую дают ангиографические исследования.

Dr. Ádám Balogh
Dr. István Besznyák
Department of Surgery, National Institute of Oncology, Budapest, Ráth Gy. u. 7/9, H-1122

Dr. Zoltán Sulyok
Dr. László Tóth
Institute of Vascular Surgery, Semmelweis University Medical School, Budapest, Városmajor u. 68, H-1122

Dr. László Szlávy
Department of Radiology, Semmelweis University Medical School, Budapest, Üllői út 78/a, H-1082

Acta Chirurgica Academiae Scientiarum Hungaricae, Tomus 23 (1), pp. 9—13 (1982)

Effect of Lead Acetate on the Endotoxin Susceptibility of Pregnant Rats

T. CSORDÁS and L. BERTÓK

First Department of Obstetrics and Gynaecology, Semmelweis University Medical School and National "Frédéric Joliot-Curie" Research Institute of Radiobiology and Radiohygiene, Budapest

(Received November 26, 1980)

Pregnant rats were found to be twice as susceptible to lead acetate as non-pregnant rats. Intravenous administration of subtoxic doses (2.5 mg/rat) greatly enhanced the susceptibility to endotoxin of pregnant rats. Lead acetate and small quantities (0.5 to 1 μg/rat) of endotoxin induced foetal death and abortion just as the usual abortifacient dose (1 mg/rat) of endotoxin. Thus, the increasing pollution of the environment by lead, the Gram-positive infections and entero-endotoxaemias might have an aggravating effect on foetal damages.

The increasing pollution by lead of the environment is a well-known fact. Beside industrial activities, it is due to the lead tetraethyl mixed to the petrol which reaches the environment with the exhaust fumes of cars and, therefore presents an increasing danger to the population of practically all settlements with large traffic [18]. Consequently, all experiments are important which aim at studing the lesions caused by lead in higher organisms. Our earlier observation that intravenously administered non-toxic quantities of lead acetate raise the susceptibility of rats to bacterial endotoxins by a factor of over 10 000 is important from the above mentioned aspect, too [1, 2, 23]. This effect of lead has since been confirmed by several authors [6, 7, 11, 12, 14, 22, 25, 26, 27]. It was moreover found that lead acetate induced endotoxin hypersensitivity is a method suitable for the demonstration of the entero-endotoxaemic origin of various shock conditions (intestinal syndrome of radiation sickness, abdominal ischaemia following superior mesenteric artery occlusion, tourniquet shock, etc.) [5, 17, 19]. It has later been proved that chronic lead uptake causes a considerable reduction in the defensive capacity against bacterial infections of experimental mice [12].

On the other hand, it is a generally known fact that the endotoxin of Gram-negative bacteria has an important role in the pathogenesis of abortions and premature births. Two to three per cent of abortions accompanied by fever lead to severe septic endotoxin shock, and septic states of other origin also induce foetal death and abortion [8, 9, 10, 15]. The enhanced endotoxin susceptibility of the pregnant organism is also well known [18]. Thus, if rats or mice are given endotoxin in the third part of pregnancy, the foetus will die

in untero and be aborted [16, 20, 21, 27]. It seems that the tissue injuring effect of endotoxin involves the release of prostaglandin which induces abortion [24]. The majority of authors regard the lesions of the placenta as a Sanarelli–Schwartzman syndrome [21, 22]. In our earlier experiments we were able to prevent the abortifacient effect of endotoxin in 90% of pregnant rats by radiodetoxified endotoxin (Tolerin®) [9, 10].

We have, therefore, studied whether it was possible further to enhance the increased endotoxin susceptibility of the pregnant organism by the administration of lead acetate.

Material and Method

Female Wistar R/A × Long Evans (hooed) F hybrid (LATI, Gödöllő) not pregnant and pregnant rats of 150 to 200 g weight were used in the experiments. The rats were chosen for mating from a larger population on the basis

TABLE I

Effect of intravenously administered lead acetate on the endotoxin susceptibility of pregnant rats

Group No.	Treatment	Death rate Died/total No.	
		Mother	Foetus
1	2.5 mg lead acetate	0/20	0/220
2	1.5 μg endotoxin	0/20	0/208
3	2.3 mg lead acetate plus 0.5 μg endotoxin	2/20	131/226
4	2.5 mg lead acetate plus 1.0 μg endotoxin	16/20	222/222
5	2.5 mg lead acetate plus 1.5 μg endotoxin	20/20	189/189

of vaginal smears so that all were in pre-oestrus. On the 17th to 19th day of pregnancy, endotoxin prepared from the fermentor culture of the *E. coli* strain 089 by means of the warm phenol-water method [28] was given intravenously in doses shown in Table I.

Lead acetate (Fischer Sci. Co., Fair Lann, N.J., USA) was dissolved in freshly boiled, CO_2-free, distilled water and administered intravenously simultaneously with the endotoxin [23]. After 24 hours the abdominal cavity of the surviving animals was opened and the dead and living foetuses were counted.

Results

Confirming our earlier results, while in non-pregnant rats 5 mg of intravenously administered endotoxin induced lethal shock, in pregnant animals 2 mg were sufficient to produce the same effect. One mg of endotoxin did not kill the mother but caused the death of all foetuses. In non-pregnant rats, 5 mg of lead acetate and 3 μg of endotoxin administered intravenously sufficed to produce lethal endotoxin shock, while pregnant rats were, as a rule, unable to tolerate the above dose of lead acetate. It seems that pregnant animals are more susceptible to lead than are non-pregnant ones. The non-toxic dose of lead acetate for pregnant rats was found to be 2.5 mg. Table I shows that 2.5 mg of lead acetate (Group 1) and 1.5 μg of endotoxin (Group 2) did not induce foetal death and abortion when given alone. When, however, the same lead acetate dose was administered with only one-third of the above endotoxin dose (0.5 μg, Group 3), this killed two out of twenty mothers (10%) and 131 out of 226 foetuses (58%). One μg of endotoxin with the same dose of lead acetate (Group 4) killed 80% of the mothers and 100% of the foetuses. One and a half μg of endotoxin, which in itself is not toxic, (Group 5) caused the death of all mothers when administered together with lead acetate. Thus, compared to the non-pregnant rats, lead acetate even in 50% lower doses greatly intensified the ndotoxin susceptibility of pregnant rats.

Discussion

It appeared from the experiments that the susceptibility to endotoxin induced by lead acetate is far more intense in the pregnant organism than in non-pregnant animals. In addition, the susceptibility to lead of the pregnant organism is also enhanced. These findings seem to have a practical importance. The increasing pollution by lead of the environment might intensify a given population, and particularly in pregnant women, the susceptibility to the toxins of Gram-negative and other pathogens. This possibility is indicated by the experiments of Hemphil et al. [12] who showed that chronic lead uptake greatly increased the susceptibility of mice to bacterial infections. Lead is namely capable of considerably reducing the activity of the reticulo-endothelial system, phagocytosis and other functions [7, 12, 14, 25, 26, 27]. It seems that, beside its known injurious effect (porphyrin metabolism), lead reduces or completely blocks the effect of bile acids which, due to their detergent properties, play a role in the detoxification of endotoxins [.3 4].

Acknowledgments

The authors are indebted to Mrs. I. Kiss, Mrs. F. Klie and Mrs. A. Sófalvi for skilful technical assistance.

References

1. Bertók L: Effect of sulfhydril compound on the lead acetate induced endotoxin hypersensitivity of rats. J Bact 95:1976, 1968
2. Bertók L: Effect of endotoxin tolerance on the lead acetate induced endotoxin hypersensitivity of rats. J Bact 96:569, 572, 1968
3. Bertók L: Physico-chemical defense of vertebrate organism: The role of bile acids in defense against bacterial endotoxins. Perspect Biol Med 21: 70, 1977
4. Bertók L: Role of bile in detoxification of lipopolysaccharide. Microbiology 91, 1980
5. Bertók L, Kocsár L: Die Rolle des Endotoxins beim intestinalen Syndrom der Strahlenkrankheit. Math Naturwiss 23:65, 1974
6. De Clercq E, Merigan TC: An active interferon obtained from *Hemophilus influenzae* type B. J Immunol 103:899, 1969
7. Cook JA, Di Luzio NR: Protective effect of cysteine and methylprednisolone in lead acetate-endotoxin induced shock. Exp Mol Pathol 19:127, 1973
8. Czeizel E.: Potential hazards of symptomless significant bacteriuria in pregnancy. (In Hungarian) Magy Nőorv Lap 32:340, 1969
9. Csordás T, Bertók L, Csapó Zs: Experiments for the prevention of abortifacient effect of endotoxin by radiodetoxified pretreatment in rats. (In Hungarian) Kísérl Orvostud 29:194, 1977
10. Csordás T, Bertók L, Csapó Zs: Experiments on prevention of the endotoxin-abortifacient effect by radiodetoxified endotoxin pretreatment in rats. Gynecol Obstet Invest 9:57, 1978
11. Filkins JP: Bioassay of endotoxin inactivation in the lead sensitized rat. Proc Soc Exp Biol Med 134:610, 1970
12. Hemphill FE, Kaeberle ML, Buck WB: Lead suppression of mouse resistance of *Salmonella typhimurium*. Science 172:1031, 1971
13. Hoffmann E, Trejo RA, Di Luzio NR, Lamberty J: Ultrastructural alterations of liver and spleen following acute lead administration in rats. Exp Mol Pathol 17:159, 1972
14. Holper K, Trejo RA, Brettschneider L, Di Luzio NR: Enhancement of endotoxin shock in the lead sensitized subhuman primate. Surg Gynecol Obstet 136:593, 1973
15. Kass EH: Bacteriuria and pyelonephritis in pregnancy. Arch Intern Med 105:194, 1960
16. Kertai P, Sajgó M, Czeizel E, Kováts M: Data of the mechanism of endotoxin fetopathy. (In Hungarian) Magy Nőorv Lap 28:286, 1965
17. Kisida E, Bertók L, Karika Gy: The role of endotoxin in superior mesenteric arterial occlusion induced shock. (In Hungarian) Magy Seb 28:156, 1975
18. Millar IB: Monitoring of lead in the environment. J. Epidemiol Community Health 32: 111, 1978
19. Orbán I, Bertók L, Regős J, Gazsó L: Die Rolle der bakteriellen Endotoxine beim Tourniquet-Schock der Ratte. Acta Chir Acad Sci Hung 194:339, 1978
20. Parant M, Chedid L: Protective effect of chlorpromazine against endotoxin induced abortion. Proc Soc Exp Biol Med 116:906, 1964
21. Rieder RF, Thomas L: Studies of the mechanism involved in the production of abortion by endotoxin. J Immunol 84:189, 1960
22. Rippe B, Berry LJ: Lead acetate sensitization to endotoxin in mice. Proc 8th Ann Meeting Reticuloendothel Soc 11:440, 1972
23. Selye H, Tuchweber B, Bertók L: Effect of lead acetate on the susceptibility of rats to bacterial endotoxins. J Bacteriol 91:884, 1966
24. Skarnes RC, Harper KJ: Relationship between endotoxin induced abortion and the synthesis of prostaglandin F. Prostaglandins 1:191, 1972

25. Trejo RA, Di Luzio NR: Impaired detoxification as a mechanism of lead acetate induced hypersensitivity to endotoxin. Proc Soc Exp Biol Med 136:889, 1971
26. Trejo RA, Di Luzio NR, Hoffmann R: Mechanism of lead-induced endotoxin hypersensitivity: a macrophage defect. Proc. 5th Int Congr Pharmacol 245, 1972
27. Trejo RA, Di Luzio NR, Loose LD, Hoffmann E: Reticuloendothelial and hepatic functional alterations following lead acetate administration. Exp Mol Pathol 17: 145, 1972
28. Westphal O, Lüderitz O, Bister F: Über die Extraktion der Bakterien mit Phenol-Wasser. Z Naturforsch 7b:148, 1952

Die Wirkung des Bleiazetats auf die Endotoxin-Empfindlichkeit der trächtigen Ratten

T. Csordás und L. Bertók

Die Verfasser haben bewiesen, daß die trächtigen Ratten auf Bleiazetat zweimal empfindlicher sind als die nicht trächtigen. Das intravenöse Einspritzen des subtoxischen Bleiazetats (2,5 mg/Ratte) steigert die Endotoxin-Empfindlichkeit der trächtigen Ratten in großem Maß. Das Bleiazetat und das Endotoxin in kleiner Menge/Dosis (0,5–1 μg/Ratte) verursacht das gleiche Fruchttod und Fehlgeburt wie die gewöhnliche abortofaciens Dosis des Endotoxins (1 mg/Ratte).

Die Verfasser zeigen darauf hin, dass die immer steigende Umwelt-Bleiverschmutzung, Gram-negative Infektionen und die Enteroendotoxemien auf den Fötusschaden eine erschwerende Wirkung ausüben können.

Влияние ацетата свинца на чувствительность к эндотоксину у беременных крыс

Т. ЧОРДАШ и Л. БЕРТОК

Авторами было показано, что беременные крысы двухкратно чувствительны к ацетату свинцу, чем не беременные крысы. Внутривенное введение ацетата свинца в субтоксической дозе (2,5 мг/крыса) в большой мере повышает чувствительность беременных крыс к эндотоксину. Ацетат свинца и небольшое количество эндотоксина (0,51 μg/крыса) вызывают такое же отмертвение эмбриона и выкидыш, как и абортофациентная доза эндотоксина (1 мг/крыса). Авторы указывают на возможность ухудающего влияния повреждения эмбриона из-за все более возрастающегося свинцового загрязнения среды, грамотрицательных инфекций и энтероэндотоксемий.

Dr. Teréz Csordás — First Department of Obstetrics and Gynaecology, Semmelweis University Medical School, Budapest, Baross u. 21, H-1778

Dr. Lóránd Bertók — "Frédéric Joliot-Curie" Research Institute of Radiobiology and Radiohygiene, Budapest, H-1775, P.O. Box 101

Acta Chirurgica Academiae Scientiarum Hungaricae, Tomus 23 (1), pp. 15—22 (1982)

Adenovirus Antibodies in Tumorous Diseases of the Urogenital System

S. CSATA,[1] G. KULCSÁR,[2] P. DÁN,[2] J. HORVÁTH,[2] I. NÁSZ,[2] J. ONGRÁDI[2] and A. VEREBÉLYI[1]

Department of Urology, Municipal István Hospital[1], and Institute of Microbiology[2], Semmelweis University Medical School, Budapest

(Received December 2, 1980)

More than 4000 tests were performed to provide information on the role of adenoviruses in the tumorous diseases of the urogenital system. In a large percentage of the tumour patients the antibody of the non-virion antigen of an adenovirus type with oncogenic properties was detected. In 33% of the patients in the control group who suffered from some inflammatory internal disease, an antibody against the non-virion antigen of the adenovirus with latent properties was found. This can be explained with the presence of antibodies in inflammatory diseases which permit the persistence of latent adenoviruses in the organism.

Since the first observations at the beginning of our century, the oncogenic property of more than 60 viruses has been proved. These viruses produce benign or malignant tumours in a great variety of animal species [1, 3, 27, 29, 45, 46]. A new step forward was the discovery that under experimental conditions human adeno- and herpesviruses, too, are capable of inducing malignant transformation of human and animal cells [6, 11, 13, 18, 21, 25, 26, 37]. A number of observations and studies indicates that the oncogenic properties of these viruses may manifest in human subjects, too, but in this respect no unambiguous direct evidence is available. So far the virus aetiology of some benign human tumours such as verruca vulgaris, condyloma acuminatum and molluscum contagiosum, and of certain papillomas could be proved [3]. In the case of malignant tumours the lack of direct evidence might be due to the failure of attempts to gain infectious viruses from malignant human tumours, just as no infectious virus particle can be found in cell cultures made experimentally malignant by human adeno- and herpesviruses [11, 14, 18, 25, 37]. In the latter cells there are, however, always substances of a protein-like nature (T-antigens, early non-virion antigens believed to be the fingerprints of viruses) to prove the correlation with the virus. Consequently, various methods have been evolved for the detection in human tumours of these tumour-specific protein components, in other words, antibodies produced against them.

In the case of herpesviruses, the results of these tests have provided almost convincing proof of the correlation between viruses and certain types of tumour [2, 13, 14, 30, 35, 44]. In the literature available we found hardly any similar data referring to adenoviruses. [37].

We have, therefore, investigated whether it is possible to demonstrate in the sera of patients suffering from malignant or benign urological tumours, prostate hypertrophy or from some other urological disease, as well as in the sera of appropriate controls, the presence and proportion of antibodies against latent and oncogenous adenoviruses. A search was also made for antibodies against the early non-virion tumour-specific antigen of the viruses.

Material and Method

We have tested the sera of a total of 516 patients and control subjects, the majority with eight types of antigen; thus more than 4000 tests were carried out. Distribution of the patients according to diagnosis is shown in Table I, and according to the type of tumour, in Table II.

The tests involved the complement binding reaction which was performed by means of Takátsy's microtitrator. In order to inactivate the own complement, before the test the sera were kept in a 56 °C water-bath for 30 minutes.

The following viruses, i. e. their early antigens were used: adenovirus types 1 and 5 (with latent property), the oncogenic types 12 and 18; early non-virion antigens of the adenovirus types 1, 5, 12 and 18; and the cell extract HEp-2 as control, as the applied viruses and their early antigens were grown and titrated on this cell culture.

To obtain the early non-virion adenovirus antigens a HEp-2 cell culture was infected with large doses of adenovirus types 1, 5, 12 and 18 and the viruses were left to be absorbed by the cells at 37 °C. Then the cultures were washed with Hanke's solution and covered with serum-free Parker's 199 solution containing 10 μg/ml of cytosine arabinoside to block the formation of virus components [9]. Twelve hours after infection the cells were scraped from the

TABLE I

Distribution of patients according to diagnosis

Diagnosis	No. of patients
Non-tumorous diseases of the urogenital system	193
Urogenital tumours	253
Internal diseases	70
Total	516

TABLE II

Urogenital tumours

Tumour	No. of patients
Malignant tumours	
Tumour of the bladder	57
Tumour of the prostate	32
Tumour of the kidney	15
Tumour of the testis	15
Other tumours	23
Benign tumours	
Papilloma of the bladder	18
Polypus of the urethra	4
Hyperthrophy of the prostate	89
Total	253

wall of the dish into Parker's solution and subjected to three or four melting-freezing cycles. After centrifugation at 1 500 g, the supernatant was used as antigen for testing the sera of the patients.

Results

Results of the complement binding test are shown in Table III which, however, does not contain the results gained with every type of adenovirus used in the test, since the results obtained with types 1 and 5 having a latent property were almost the same, and the results with the oncogenic types 12 and 18, too, were very similar. It appears from Table I that the incidence of

TABLE III

Incidence of antibodies against viruses and their early antigens (per cent)

Antigen	Urogenital tumour (n = 253)	Non-tumorous diseases of the urogenital system (n = 193)	Internal diseases (n = 70)
		%	
Adenovirus 1, total	19	34	12
Adenovirus 1, early	56	23	33
Adenovirus 12, total	13	6	2
Adenovirus 12, early	63	18	4

antibodies against adenovirus type 1 is lower in the case of urogenital tumours than in the sera of patients suffering from some other urological disease; the incidence was 19% in the first and 34% in the second group. The difference in the incidences of antibodies aginst the early non-virion antigens of these adenovirus types in the two groups of patients was even more conspicuous: the antibodies were found in more than 50% of the tumour patients and in only 23% of those suffering from some other urological disease. The incidence of these antibodies was 33% in the control group.

The incidence of antibodies against the non-virion antigen of the oncogenic adenovirus type 12 was even more remarkable. It was detected in more than 50% of the tumour patients, in 18% of those with some other urogenital disease and in 4% of the control group. It supports the specificity of the tests that the antibody against the structure antigen of adenovirus type 12 was found in 13% of the tumour patients, in 6% of those with other urogenital diseases and in 2% of those with internal diseases (see Table III).

The sera did not react with the antigen of the cell extract HEp-2; in some cases the titre was 1 : 2, so that only a titre above 1 : 4 for the virus antigens was considered positive.

Discussion

A number of tests have been devised in an attempt to approach the assumed correlation between benign and malignant human tumours and viruses [2, 11, 21, 29, 31, 39, 42].

Attempts were made to detect in the tumours the virus or its antigens, nucleic acid particles, i. e. genes, enzymes associated with the virus, antibodies produced against the virus or its components, early non-virion antigens produced in the infected cell as an effect of the virus, but not forming structural elements of the virus, and the antibodies produced against them. With the help of these methods it was possible to demonstrate a link between several human tumours and viruses, including tumours of the urogenital system and herpes simplex, cytomegalovirus and papovaviruses, as well as virus particles of type C [4, 5, 8, 10, 12, 19, 20, 23, 36, 43, 47]. The presence of virus nucleic acid was consistently observed in prostate cells growing *in vitro* for prolonged periods [33]. With respect to herpes simplex virus, there are data claiming that the antibody of the non-virion antigen of the virus can be found in 100% of the patients suffering from tumours of the urogenital system and of the oral region [35]. The affinity of oncogenic viruses to various organs or organ systems was also studied. As a result of these studies it was discovered that herpesviruses have a high incidence in the male urogenital organs. [41].It was observed that the cytomegalovirus persists for some time in the human semen [12] and virus induced prostatitis has also been described [22]. Several observa-

tions indicate the affinity of adenoviruses to the urogenital organs, though there are no data to confirm this. Our earlier investigations, too, indicated a relationship between the female urogenital organs and adenoviruses. Investigation of the cervical epithelial cells by means of the immune fluorescence method showed that in 7 to 8% of clinically healthy women, beside the herpesvirus antigens, adenovirus antigens can also be present, while the incidence of virus antigens is more than 20% in cases of malignant lesions of the cervical epithelial cells [7]. Examination of cervical epithelial cells obtained by curettage performed because of irregular bleeding revealed adenoviruses with latent properties in 14% of the cases [16]. In pregnant mice infected with human adenovirus we observed transplacental penetration of the virus into the foetus, and its persistence in the maternal ovaries [15].

According to our results, the antibody against the non-virion antigen of the type 12 oncogenic adenovirus occurs in more than 50% of the tumorous diseases of the urogenital system, in contrast to the 18% incidence in other, non-tumorous urological patients and to the 4% incidence in patients suffering from some internal disease.

The data indicate the presence and functioning of a comparatively high percentage of the defective form or genes of an oncogenic adenovirus in the organism of patients with urogenital tumour, as only these defective forms or genes of the adenovirus can induce non-virion antigens, whose presence was confirmed by the specific antibody produced against them.

The more than 4000 tests appear to point to the possible role of adenoviruses in urological tumours.

In the course of the present study, mainly antibodies against the non-virion type antigen of an oncogenic adenovirus were found in a high percentage of patients with urogenital tumours while in 33% of the patients with some internal disease constituting the control group primarily the antibody against the non-virion antigen of the adenovirus with latent properties was present. The diseases of the controls were inflammatory in nature and in such cases antibodies, that is latent adenoviruses, can always persist in the organism [24].

References

1. Andrewes Ch, Pereira HG: Viruses of vertebrates, Bailliere Tindalb, London 1972
2. Aurelain L, Cornish JD, Smith MF: Herpesvirus type 2-induced tumour-specific antigen (AG-4) and specific antibody in patients with cervical cancer and controls. Oncogenesis and Herpesvirus II. IARC Sci. Lyon 11:79, 1975
3. Becker FF: Cancer 2. Etiology: Viral carcinogenesis. New York 1975.
4. Centofanto YM, Kaufman HE, Zam Zs: Herpesvirus particles in prostatic carcinoma cell. J Virol 2:1608, 1973
5. Doochowski L, Ohstuki Y, Semen G, Maruyama K, Knesek JE, East JL, Bowen JM, Yoshida H, Johnson DE: Search for oncogenic viruses in human prostate cancer. Cancer Treat Rep 61:119, 1977
6. Docherty JJ, Chopan M: The latent herpes virus. Bact Rev 38:337, 1974
7. Dömötöri J, Dán P, Kulcsár G, Nász I .Csömör S. Paál M: Virusantigén vizsgálatok

kolposzkópos beteganyagon (Virus antigen tests in colposcopic patients). Magy Nőorv Lap 43:139, 1980
8. Elliott AY, Fraley EE, Cleveland P, Castro AE, Stein N: Isolation of RNA virus from papillary tumours of the human renal pelvis. Science 179:393, 1973
9. Feldman LA, Rapp F: Inhibition of adenovirus replication by 1-B-D-arabino-furanosylcytosine. Proc Soc Exp Biol Med 122:243, 1966
10. Fraley EE, Elliott AY, Castro AE, Cleveland P, Hakala T, Stein N: Ribonucleic acid virus associated with human urothelial tumors; significance for diagnosis and treatment. J Ur 111: 378, 1974
11. Garfinkle B, McAuslan BR: Transformation of cultured mammalian cells by viable herpes simplex virus subtypes 1 and 2. Proc Natl Acad Sci USA 71:220, 1974
12. Géder L, Sanford EJ, Rohner TJ, Rapp F: Cytomegalovirus and cancer of the prostate: *In vitro* transformation of human cell. Cancer Treat Rep 61:139, 1977
13. Gönczöl É: A cytomegalovirus fertőzés biológiai következményeinek vizsgálata (Study of the biological consequences of cytomegalovirus infection). Thesis, Debrecen 1975
14. Hollingshead A, Lee OB, Chretien PS, Tarpley JL, Rawls WE, Adam E: Antibodies to herpesvirus non-virion antigens in squamous carcinoma. Science 182:713, 1973
15. Horváth J, Dan P, Kulcsár G, Nász I, Geck P: Experimental carriership of human adenovirus in mice. Acta Microbiol Acad Sci Hung 25:139, 1978
16. Kulcsár G, Dömötöri J, Dán P, Nász I, Keskeny S, Horváth J, Geck P: Virological studies of gynaecological patients. Zentralbl Bakt E. [Orig A] 231:389, 1975
17. Lang DJ, Kummer JF, Hartley DP: Cytomegalovirus in semen. Persistence and demonstration in extracellular fluids. N Engl J Med 291:121, 1974
18. Lengyel A, Nász I: Az adenovirusok onkogén tulajdonsága (Oncogenous property of adenoviruses). Orvosképzés 42:11, 1967
19. Masukawa T, Garancis JC, Rytel MW, Mattingly RF: Herpes genitalis virus isolation from human bladder urine. Acta Cytol (Philad) 16:416, 1972
20. McCoombs RM: Role of oncornaviruses in carcinoma of the prostate. Cancer Treat Rep 61:131, 1977
21. Melnick JL, Courtney RJ, Powell KL, Schaffer PA, Benyesh-Melnick M, Dressman GR, Anzai T, Adam E: Studies on herpes simplex virus and cancer. Cancer Res 36:845, 1976
22. Morriseau PM, Phillips AC, Leadbetter jr GW: Virus prostatitis. J Ur 103:767, 1970
23. Murphy WM: Herpesvirus in bladder cancer. Acta Cytol (Philad) 20:207, 1976
24. Nász I, Béládi I, Lengyel A.: Az adenovirusok és kórokozó szerepük (The adenoviruses and their pathogenic role). Akadémiai Kiadó, Budapest 1967
25. Nász I, Kulcsár G: Oncogén virusok sejttransformáló hatása in vitro körülmények között, mint a daganatkutatás modellje (The cell-transforming effect of oncogenic viruses under *in vitro* conditions as a model of cancer research). Gyógyszerészet 13: 241, 1969
26. Nász I, Berencsi Gy: Az adenovirus DNS molekulárbiológiai tulajdonságai és daganatkeltő képessége (Molecular biological properties of adenovirus DNA and its cancerogenic ability). Orv Hetil 116:1503, 1975
27. Nász I: A virus és a daganat (Virus and tumour). Orv Hetil 4:175, 1968
28. Nász I: A virusok szerepe a rák kóroktanában (The role of viruses in the pathogenesis of cancer). Magy Tud 9:630 1970
29. Nász, I.: A viruskutatás jelene és perspektivái (Presence and perspectives of virus research). Magy Tud 25: 177, 1980
30. Notter MF, Docherty JJ, Mortel R, Hollinshead AC: Detection of herpes simplex virus tumor-associated antigen in uterine cervical cancer tissue. Five-case studies. Gynecol Oncol 6: 574, 1978
31. Pagano JS: Disease and mechanisms of persistent virus infection: Latency and cellular transformation. J Infect Dis 132:209, 1975
32. Pácsa S: A méhnyak carcinoma és herpesvirus kapcsolata (Link between cervical carcinoma and herpesvirus). Thesis, Pécs, 1977
33. Rapp F, Géder L, Murasko D, Lausch R, Ladds R, Eng-Shang Huang, Webber MM: Long-term persistence of cytomegalovirus genome in cultured human cells of prostatic origin. J Virol 16:982, 1975
34. Rotkin ID: A review of key epidemiological studies in cervical cancer related to current searches for transmissible agents. Cancer Res 33: 1353, 1973
35. Sabin AS, Tarro G: Herpes simplex and herpes genitalis in etiology of some human cancers. Proc Natl Acad Sci USA 70, 3225, 1973

36. Sapp WJ, Adams EW: C-type viral particles in canine venereal tumor cell cultures. Am J Vet Res 31:1321, 1970
37. Schlesinger RW: Adenoviruses: The nature of the virion and of controlling factors in productive or abortive infection and tumorogenesis. Adv Virus Res 14: 1, 1969
38. Shurshi Noda, Kosaku Eto: Uniform virus-like particles found within the prostate cancer cell in man. Kurume Med J 22:261, 1975
39. Sinkovics JG: Medical Oncology. An advanced course. Dekker, New York 1979.
40. Sprecher-Goldberges S, Thiry L, Lefebvre N, Dekegel D, De Halleux F: Complement fixing antibodies to adenovirus — associated viruses, adenoviruses, cytomegaloviruses and herpes simplex viruses in patients with tumors and control individuals. Am J Epidemiol 94:351, 1971
41. Stephen L, Beardcurff Deture FA, Drylis DM, Centifanto Y, Kaufman H: Association between herpes hominis type 2 and the male genitourinary tract. J Ur 112:126, 1974
42. Sula J: Experimental data concerning the question of the synergic action of influenza virus and some chemical carcinogens in the pathogenesis of lung cancer. Neoplasma 26: 17. 1979
43. Szabó V, Romics I, Horváth J: A surgical case of Gravitz's tumour of cystous appearance. Int Urol Nephrol 9:289, 1977
44. The TH, Klein G, Bergenhuysen MAC: Antibody reactions to virus-specific early antigens (EA) in patients with cytomegalovirus (VMV) infection. Clin Exp Immunol 16:1, 1974
45. Váczi L: A daganat-vírus kutatás fejlődése és eredményei (Development and results of cancer-virus research). Orvosképzés 51: 323, 1976
46. Vigier P: RNA oncogenic viruses: structure, replication and oncogenicity. In: Progress in Medical Virology, Vol. 12, Karger, Basel 1970
47. Zeigel RF, Arye SK, Horoszevicz JS, Carter WA: A status report. Human prostatic carcinoma, with emphasis on potential for viral etiology. Oncology 34:29, 1977

Adenovirus-Antikörper bei den Tumorkranken des Urogenitalsystems

S. Csata, G. Kulcsár, P. Dán, J. Horváth, I. Nász, J. Ongrádi und A. Verebélyi

Im Laufe von serologischen Untersuchungen wurde der vermutliche Zusammenhang zwischen Virussen und Tumoren analysiert. Mit den Seren von 446 tumorösen und nicht tumorösen Urogenitalsystemkranken und 70 internistischen Patienten wurden etwa 4000 Untersuchungen vorgenommen, mit dem Ziel die etwaige Anwesenheit der Adenovirus-Antikörper, mit besonderer Rücksicht auf die non-Virion-Antigen-Frühantikörper des über onkogene Fähigkeit verfügenden Adenovirus Typ 12. nachweisen zu können. Die Komplementbindungsreaktion zeigte, daß bei malignen Tumoren des Urogenitalsystems und bei Prostatahypertrophie die Adenovirus-Antikörper seltener vorkommen als in der Kontrollgruppe. Die non-Virion-Antigen-Antikörper der Adenovirusse waren bei 53% der Tumorkranken bzw. der an Prostatahypertrophie leidenden Patienten, bei 18% der nicht tumorösen urologischen Kranken und bei 4% der internistischen Patienten nachzuweisen. Die Ergebnisse sprechen dafür, daß bei den tumorösen Erkrankungen der urogenitalen Organe vermutlich auch die Adenoviren eine Rolle spielen.

Аденовирусный антител у больных с опухолью урогенительной системы

Ш. ЧАТА, Г. КУЛЬЧАР, П. ДАН, Й. ХОРВАТ, И. НАС, Й. ОНГРАДИ и А. ВЕРЕБЕИ

Авторы искали ответ на вопрос о возможной связи между вирусом и опухолями, используя для исследований серологические методики. В общей сложности они выполнил 4000 анализов сыворотки у 446 больных с опухолевыми или неопухолевыми заболеваниям урогенитальной системы, а также у 70 терапевтических больных, стараясь выявить антитела, выработанные против аденовирусов, обращая при этом особое внимание на антитела, образующиеся против ранних *(non-virion)* антигенов аденовирусов 12-го типа, облада-

ющих онкогенными свойствами. Реакция связывания комплемента показала, что у больных страдающих злокачественными опухолями мочеполовой системы или гипертрофией простаты, аденовирусные антитела встречаются реже, чем у больных контрольной группы. Антитела, вырабатывающиеся против не-вирионных антигенов аденовирусов, были обнаружены у 53% больных, страдающих опухолевыми заболеваниями урогенитальной системы или гипертрофией простаты, у 18% больных, страдающих неопухолевыми урологическими заболеваниями, и у 4% терапевтических больных. Результаты настоящих исследований указывают на то, что аденовирусы могут играть роль в возникновении опухолевых заболеваний органов урогенитальной системы.

Dr. Sándor Csata
Dr. András Verebélyi
Department of Urology, Municipal István Hospital, Budapest, Nagyvárad tér 1, H-1096

Dr. Gizella Kulcsár
Dr. Pál Dán
Dr. József Horváth
Dr. István Nász
Dr. József Ongrádi
Institute of Microbiology, Semmelweis University Medical School, Budapest, Nagyvárad tér 4, H-1089

Acta Chirurgica Academiae Scientiarum Hungaricae, Tomus 23 (1), pp. 23–31 (1982)

Investigation of the Functioning of the Ileum-Ureter by Means of Camera Renography

L. GALUSKA and M. GERVAIN

Central Laboratory of Isotope Diagnostics and Institute of Experimental Surgery, University Medical School, Szeged

(Received July 22, 1980

The use of camera renography under experimental conditions is described. The conductivity of the ileo-ureter formed by various surgical techniques in 24 dogs and the function of the operated kidney were studied. The non-invasive examination lasted for 20 minutes and was performed with two different labelled drugs (^{131}I-iodohippurate and ^{99m}Tc-DTPA) and a gamma-camera calculator system. The results have shown that the ileo-ureter provided with a direct single layer uretero-ileal anastomosis ensured best the transport of urine and so it seems to be most promising for human application.

Following the work of Winter and Taplin [9, 10], isotope tests began to spread in urological diagnostics by the end of the 1950s. In the recent 15 years, beside renography, kidney scintigraphy, camera renography and single injection clearance methods without urine have become part of up-to-date clinical diagnostics [1, 5, 7]. The bases of this rapid development were the non-invasive nature of the tests, the preparation of labelled drugs binding selectively to the renal parenchyma, and the modern recording systems.

Camera renography is well suited for the morphological and functional investigation of the urinary system. Beside a correct judgement of renal function, it allows to detect the localization and nature of disorders in urine transport [1, 6]. Thus, camera renography supplements the classical radiological methods. We, therefore, studied by camera renography the functioning of ureters created from the ileum.

Material and Method

Seventy ureteral substitutions were performed on female mongrel dogs weighing 6 to 21 kg (mean, 11.5 kg). In this paper the results of 33 camera renographies carried out in 24 animals will be reported.

After resection of the ureter, the passage of urine was restored by means of an isolated ileal loop. Urinary flow was ensured proximally by invaginational

direct two-layer and direct one-layer uretero-ileal anastomoses. Distally, continuity was ensured by a direct two-layer ileovesical anastomosis (Table I). In half of the experiments the capacity of the ileum was reduced by plication. The surgical technique has been described earlier [2].

Camera renography was carried out with a Nuclear-Chicago Pho-Gamma-III camera connected to a TPAI calculator. In 16 experi-

TABLE I

Types of operation

Type of anastomosis	Side	No. of animals
Invagination	left	2
Direct two-layer	left	4
Direct single-layer	right	15
Direct single-layer	left	3
	Total	24

Tested once	24 animals
One check-up	6 animals
Two check-ups	1 animal
Total number of tests	31

ments, ^{131}I-iodohippurate 170 μCi (6.29 MB_q) was given intravenously. In these tests a divergating collimator was used. In 17 experiments ^{99m}Tc-DTPA (diethylene trimino penta-acetic acid), a clearance material of glomerular filtration, which has favourable properties, and a parallel collimator were used. The dose of ^{99m}Tc-DTPA was 1 mCi (37-MB_q) per test.

After administration of the drug, a total of 64 pictures of 20 s duration were collected on the magnetic disk of the TPAI calculator. In the 4th to 5th, 13th to 14th and 19th to 20th minutes of the test, Polaroid pictures, too, were taken.

The tests were evaluated with the automatic complex program developed for the purpose of SEGAMS-80 (Szeged-gamma-camerasystem). The complex program allowed to analyse the morphological conditions on the summary picture obtained by the addition of the 64 recorded pictures, further to mark from the aspect of the examination the regions of interest (ROI), to generalize the time-activity curves corresponding to the ROI, to produce fitting curves and to calculate automatically the parameters of the curves. The resulting pictures, i. e. curves, appear on the screen of a colour television, the numerical data on an alpha-numerical screen and these can be printed.

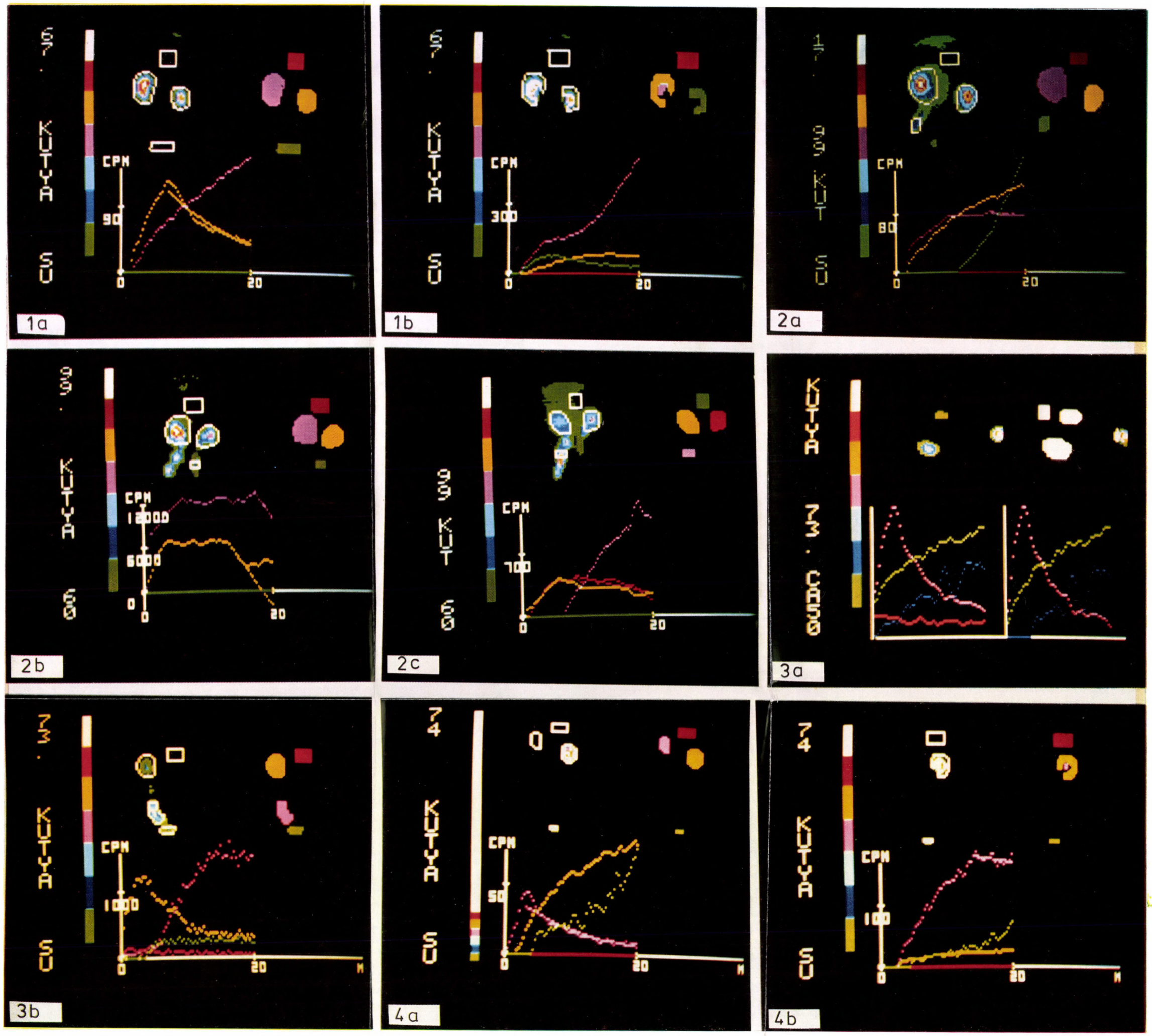

Figs 1—4

The time-activity curves prepared from the entire projection of the kidney, where one point represents an activity level of 20 s, were considered normal when the peak of the curve (T_{max}) was reached in less than 6 minutes in the case of iodohippurate, and less than 5 minutes in the case of DTPA. The half-life of iodohippurate excretion was less than 10, that of DTPA, less than 18 minutes.

The results obtained with camera renography were compared to those of radiological tests. The morphological causes of the deviation were controlled at necropsy [3, 8].

Results

Morphological conditions

In the course of the experiments good pictures were always obtained of the kidney, the ileo-ureter and the bladder. One week after the operation usually more marked renal activity and, consequently, greater kidney projections were observed on the operated side due to hindered passage (Fig. 1*b*). In 19 cases accumulation foci indicating some obstacle in the way of passage were seen in the projections of the kidney and the urinary tract.

In the course of repeated examinations, no difference between the sides was seen when the obstacle in the way of passage had ceased (Figs 2*a*, *b* and *c*). In two cases the projection of one of the kidneys was missing, in one of these cases because the kidney had been removed (Fig. 3*b*), in the other because necrosis of the kidney following suppurative nephritis.

After invaginational and two-layer direct anastomoses, the difference between the sides was still conspicuous 4 to 16 weeks after operation (Figs 4*a* and *b*), while in the cases of single-layer direct anastomoses the difference between the sides either disappeared or was reduced to a minimum (Figs 2*a*, *b* and *c*).

In the projection of the ileo-ureter, a marked increase in activity appeared on the summary picture on eight occasions, but in none of the cases could an obstacle in passage be confirmed by means of functional tests. Neither was a late rise in activity indicating ileo-urethral reflux observed in any of the experiments; vesico-ileal reflux occurred in a single case.

Functional tests

The most important parameters of the time-activity curves of the ROI in the projection of the entire kidney are given in Tables II and III. The time-activity curves plotted for the projections of the entire kidney are the common resultants of the drug transport of the parenchyma and the renal pelvis; when

TABLE II

Dynamic test-parameters of various types of anastomosis

Anastomosis	Time after operation (weeks)	No. of animals	Side	T_{max}			$T_{1/2}$		
				min.	mean	max. (min)	min.	mean	max.
Invagination	4	2	intact		5–5			9–acc.	
			operated		7–9			26–acc.	
Direct two-layer	4–16	4	intact	2.3	3.8	6.0	6.0	8.25	10
			operated	6.0	13.1	acc.	20.0	21.0	acc.
Direct single-layer	1	12	intact	3.3	6.0	9.0	3.5	7.95	10.0
			operated	11.0	11.0	acc.	10.0	25.0	acc.
Direct single-layer	2	3	intact	3.0	4.4	7.0	3.0	7.0	10.0
			operated	3.0	10.7	17.0	10.0	19.3	23.0

these are examined separately, the two curves will run parallel, but the T peak on the curve of the renal pelvis is about 1 minute longer. If there is an obstacle in the passage through the renal pelvis, the T peak will considerably be delayed. In the case of complete occlusion, the curve will rise steadily during the 20 minutes of the experiment and an accumulation type curve will appear (Fig. 1*b*). On the corresponding projection of the renal parenchyma, the transport of the labelled drug usually appears normal, but in the case of a protracted hindrance of excretion, an accumulation will appear on the level of the parenchyma. With such post-renal pelvis type obstacles in the way of passage, the height of the renal pelvis curve will be considerably above the activity level of the parenchyma curve. If a lesion of the parenchyma is the cause of the delayed drug transport, the curve will, as a rule, be protracted and can be of the accumulation type (Fig. 2*a*).

Table II contains the numerical data of the time-activity curves plotted from the entire projection of the kidney of animals subjected to three types of anastomosis. In the case of all the three types of anastomoses T_{max} and $T_{1/2}$ values corresponding to normal renograms were found on the intact side. In one dog which died of bilateral suppurative nephritis the curve of the intact side was also of the accumulation type.

In the early postoperative period, on the operated side pathologic curves were recorded, independently of the type of anastomosis. In the case of invaginational two-layer uretero-ileal anastomosis a definite transport disorder persisted for a time.

After single-layer uretero-ileal anastomosis, the passage disorder was still marked one week after operation (in 11 out of 12 experiments the curve

TABLE III

Data of repeated tests (No. of animals 6)

Test	Time (week)	Side	1		2		3		4		5		6	
			T_{max}	$T_{1/2}$	T_{max}	$T_{1/2}$	T_{max}	$T_{1/2}$	T_{max}	$T_{1/2}$	T_{max}	$T_{1/2}$	T_{max}	$T_{1/2}$
Ist	1	intact	3.3	5	1.0	*34*	3.2	7.0	*acc.*		4.0	5	3.0	5
		operated	*acc.*		1.0	*93*	*acc.*		14.0	86	*acc.*		*acc.*	
Check-ups														
	2	intact	6.0	7	3.2	21	5	5.2	—	—	—	—	—	—
		operated	*12.0*	*24*	*2.3*	*24*	6	7	—	—	—	—	—	—
	3	intact	—	—	—	—	—	—	12.0	5.0	—	—	—	—
		operated	—	—	—	—	—	—	*17.0*	*5.0*	—	—	—	—
	5	intact	—	—	—	—	—	—	5.0	19	—	—	—	—
		operated	—	—	—	—	—	—	8.8	14	—	—	—	—
	6	intact	—	—	—	—	—	—	—	—	5.0	3.6	—	—
		operated	—	—	—	—	—	—	—	—	5.0	6.6	—	—
	13	intact	—	—	—	—	—	—	—	—	—	—	—	mute*
		operated	—	—	—	—	—	—	—	—	—	—	3.0	3.1

Time = time after operation; acc. = accumulation-type curve

* removed

was of the accumulation type), but urine transport soon improved. Table III shows the results of repeated tests on the same animals. One week after surgery in four out of six cases curves of the accumulation type were recorded. The parameters improved gradually and proportionally to the time which had elapsed since the operation, and normalized in three to five weeks. In one animal (No. 6) in the first test after removal of the intact kidney, the kidney with the ileo-ureter produced an accumulation-type curve, but showed an improved drug transport in the course of later tests (Fig. 4).

Comparative tests

The results obtained with camera renography were compared to those of classical intravenous urography. Table IV shows the results of 50 X-ray tests

TABLE IV

Type of uretero-ileal anastomosis and rate of secretion

Type of anastomosis	Total no. of animals	Beginning of secretion min	No. of animals
Invagination	7	10	1
		20	1
		30	2
		none after > 30 min	3
Direct two-layer	20	10	11
		20	3
		30	1
		none after > 30 min	5
Direct single-layer	23	10	20
		20	2
		30	—
		none after > 30 min	1

TABLE V

Obstacle in the way of passage through the utero-ileal anastomosis

Type of anastomosis	Total no. of animals	Obstacle in the way of urine passage			
		none	medium	severe	occlusion
		no. of animals			
Invagination	7	—	2	1	4
Direct two-layer	20	6	4	4	6
Direct single-layer	23	19	1	1	2

with respect to secretion and Table V the rate of urine passage after the three types of operation [8]. The X-ray tests indicated changes of the same nature as those observed in the course of the isotope tests.

Discussion

Following to all three types of operation there was a transient hindrance in drug transport. This disturbance lasted, as a rule, for two weeks in those cases in which no organic obstacle to the passage was caused by some technical error. With respect to the late results, a marked difference was found between the invaginational, the two-layer and the direct single-layer uretero-ileal anastomoses. Owing to the persistent passage disturbance and the lesion of the renal parenchyma, the first two types of anastomosis are unsuitable for reconstruction of the ureter. This was supported by our earlier X-ray and histological findings [3, 8]. Lachand et al. [4] confirmed that stenosis or stricture can occur in 25 to 35% of uretero-ileal anastomoses.

In the case of single-layer direct anastomosis, too, a temporary disturbance of passage was found which, however, gradually improved and ceased two to six weeks after operation. This phenomenon can be explained with two factors: a temporary oedema develops in the line of anastomosis even when the finest atraumatic thread is used for suturing. A similar disorder in passage occurs after plastic operations of the renal pelvis; improvement sometimes takes weeks or months.

Due to the difference in peristalsis of the renal pelvis, the ureteral stump and the ileum, a temporary disorder of passage and slow excretion occur. Normal passage is restored once the anastomosis has healed and peristalsis of the ileum corresponds to the flow of urine. This adjustment might take some weeks, thus after substitution of the ureter by the ileum a disturbance of passage and a consequent reduction of renal function may occur. A previous affection of the renal parenchyma presumably influences the degree and duration of the reduced function of the kidneys, consequently, it is essential to assess renal function from the aspect of the indication of surgery.

The adequate peristalsis of the ileal graft was shown by the absence of urinary stasis. No reflux affecting the renal pelvis was observed; vesico-ileal reflux occurred in a single case. For the detection of reflux, camera renography is particularly valuable, being a method more physiological than radiology [11]. The data which have ascribed a decisive role to reflux in the development of lesions of the renal parenchyma and of hydronephrosis are probably due to the aphysiological nature of the methods applied. Woodside compared the classical and the isotope test methods and arrived at a similar conclusion [11]. We checked our camera renographic results in the course of the autopsies which, as

well as the histological findings, have confirmed our isotope-diagnostic observations.

Camera renography thus refines and extends diagnostic possibilities as it provides quantitative data on the condition of the parenchyma and, at the same time, on the rate of urine transport. These data are of primary importance in the 0 to 7 minute interval which is difficult to follow by X-rays. Camera renography can be repeated as often as necessary, the contrast medium causes no complications, and the radiation load is low. If, because of the failure of other surgical interventions, substitution of the ureter by ileum is chosen, camera renography will provide — just as in the case of kidney transplantation — reliable data on renal function and on the rate of urine transport, even in the early postoperative days.

References

1. Balogh F: Urológia (Urology). Medicina Kiadó, Budapest 1978
2. Gervain M: Uréterpótlás kirekesztett ileum-kaccsal (Ureter replacement with excluded ileum loop). Magy Seb 32:317, 1979
3. Gervain M, Karácsony G, Mohácsi G: Kísérletes adatok az uretero-ilealis anastomosisokhoz (Experimental data on uretero-ileal anastomoses). Magy Seb (in press)
4. Lachand AT, Duval F, Auvert J: The use of an intestinal loop for urinary diversion. Scientific Session of the Hungarian Association of Urology and Nephrology, Budapest 1979
5. Macleod MA, Sampson WF, Houston AS: Urinary clearance of ^{113m}In-DTPA and ^{99m}Tc(Sn)DTPA measured by external arm counting. Ur Res 5:71, 1977
6. Magyarsóki F, Vittay P, Kopcsányi Zs: Gamma-kamerás izotóp vizsgálatok értéke a parenchymas vesebetegségekben (The value of gamma-camera isotope tests in parenchymal kidney diseases). 5th Congress of the Hungarian Society of Urology and Nephrology, Debrecen 1979
7. Molnár Gy, Pál I.: Vizelet nélküli glomeruláris clearance-meghatározás radioactiv fémkomplexekkel (Glomerular clearance determination without urine with radioactive metal complexes). Orv Hetil 111:199, 1970
8. Timár P, Gervain M.: Röntgen vizsgálatok ileummal végzett uréterpótlás után kutyán (X-ray tests after ureter replacement with ileum on dogs). Ur Nephrol Szle (accepted for publication)
9. Winter ChC: A clinical study of a new renal function test: the radioactive diodrast renogram. J. Ur 76:182, 1956.
10. Winter ChC, Taplin GV: A clinical comparison and analysis of radioactive diodrast, hypaque, miokon and urokon renograms as tests of kidney-function. J. Ur 79: 573, 1958
11. Woodside JR, Borden TA. et al.: Isotope loopography, a new test: comparison with standard loopography and its relationship to renal function in patients with ileal conduit urinary diversion. J Ur 119:31, 1978

Untersuchung des Funktionsvermögens des Ileum-Ureters mit Kamera-Renographie

L. Galuska und M. Gervain

Unter Anwendung der Kamera-Renographie wurden die Leitungsfähigkeit des bei 23 Versuchshunden mit verschiedenen chirurgischen Methoden ausgebildeten Ileo-Ureters sowie die Gestaltung der Funktion der operierten Niere untersucht. Die 20 Minuten

lang haltende non-invasive Untersuchung wurde mit zwei verschiedenen Radiopharmaka (^{131}Hippuran und ^{99m}Tc-DTPA), mit dem Gammakamera-Kleinrechner vorgenommen. Die Ergebnisse sprachen dafür, daß der beste Harntransport durch den mit der direkten, einschichtigen ureteroilealen Anastomose versorgten Ileoureter gewährleistet wird. Angesichts der ermittelten Erfahrungen scheint die beschriebene chirurgische Lösung auch für die Praxis perspektivistisch zu sein.

Исследование функциональной способности илеоуретера методом камерной ренографии

Л. ГАЛУШКА и М. ГЕРВАЙН

Авторы знакомят с результатами применения камерной ренографии в экспериментальных условиях. С помощью этой методики они исследовали у 23 собак проводимость илео-уретера, созданного различными оперативными способами, и динамику функции оперированной почки. Продолжающееся 20 мин, не инвазивное исследование они производили с помощью системы гамма-камерного калькулятора с двумя разными фармакологическими препаратами (^{131}гиппуран и ^{90m}TC—DTPA). Как показали проведенные исследованияилео-уретер, снабженный прямым однослойным уретеро-илеальным анастомозом, обеспечивает самый лучший транспорт мочи. Авторы считают, что предлагаемое ими оперативное решение является наиболее перспективным с точки зрения практического применения.

Dr. László Galuska — Central Laboratory of Isotope Diagnostics, University Medical School, Szeged

Dr. Mihály Gervain — Institute of Experimental Surgery, University Medical School, Szeged

Acta Chirurgica Academiae Scientiarum Hungaricae, Tomus 23 (1), pp. 33—38 (1982)

Amyloidosis of Bones

I. SZILÁGYI, A. RÉFFY, ZS. DEMEL and L. JÓZSA
National Institute of Traumatology, Budapest

(Received January 19, 1981)

Incidence of senile amyloidosis has been studied in necropsy material of human femoral bones. The femoral head and the fractured region of the femoral neck were examined. Amyloid was detected both in fractured and in intact femoral bones.

The various forms of amyloidosis (primary amyloidosis, secondary amyloidosis, senile amyloidosis, etc.) are common conditions. The amyloid is deposited in both mesenchymal and ectodermal tissues. Little attention has been paid to amyloidosis in the articular cartilage, joints and bones. Koletsky and Stecher [4] described primary systemic amyloidosis involving the joints and bones, causing fracture of the femur. Amyloid deposits in the surface layer of the articular cartilage were briefly recorded by Gamarski and Netto [3] in a case of primary amyloidosis. Bywaters and Dorling [1] made the same findings in primary amyloidosis and multiple myeloma, respectively. Teglbjörg et al. [11] described local amyloid deposits in pyrophosphate arthritis. It has been observed that with age amyloid accumulates in the articular cartilages [2] and, recently, Ladefoged and Christensen [5] have found amyloid deposits in the articular cartilage of the hip joint in 28 of 30 unselected necropsies, i. e. in 93% of the cases. These were the only reports we could find on the presence of amyloid in articular cartilage and bones.

The aim of the present study was to determine the frequency of amyloid deposits in the bones of subjects having died after femoral neck fracture.

Material and Methods

The patient material comprises 29 autopsies carried out at the National Institute of Traumatology. All patients died within 2 weeks after fracture of the femoral neck or pertrochanteric fracture. There were no cases of generalized primary amyloidosis, rheumatoid arthritis, tuberculosis, myeloma or carcinoma in the material. The distribution according to age and sex can be seen in Table I.

The femoral head, the fractured region and specimens of the heart auricle were examined histologically in the first 10 cases from the fractured side and, in the others, from both sides. The specimens were fixed in 10%

TABLE I

Age and sex distribution of the patients

Age (year)	Male	Female
61–70	—	1
71–80	6	8
81–90	2	12
	8	21

formalin, decalcified in EDTA-solution, embedded in paraffin, and stained with haematoxylin-eosin and for amyloid with alkaline Congo-red [8], with Syrius supra red [10] and with thioflavine S or primuline [6]. The sections were examined by light-, polarization- and fluorescence microscopy.

Results

Amyloid was found in two cases only in the heart muscle, in 12 cases only in the bone, and in 15 cases in both regions (Table II). In the heart the amyloid deposits were in the perimysium, vessel walls and in the interstitial connective tissue (Fig. 1). Amyloid deposits were found in some cases below the articular cartilage. In the cortical bone a slight or moderate amyloid reaction was obtained. In the trabecular bone round, irregular or diffuse amyloid masses were seen.

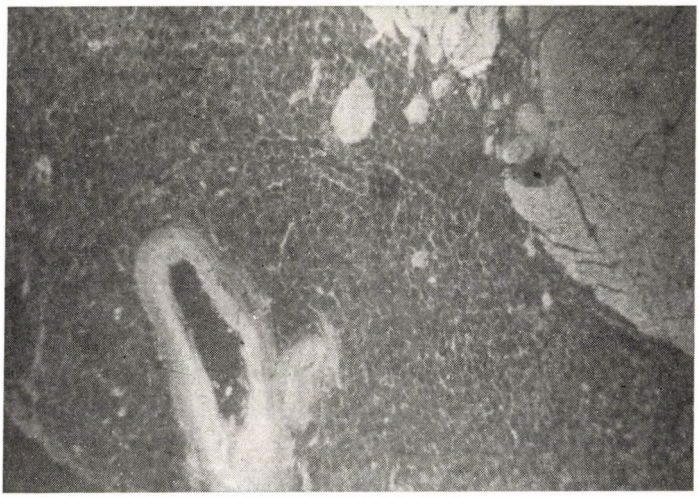

FIG. 1. Heart. Amyloid deposits in vessel wall. Thioflavine-S fluorescence. ×100

TABLE II

Amyloid deposits in different age groups

Age (year)	Head of femur	
	Cartilage	Bone
61–70	0	1
71–80	7	12
81–90	5	13
	12	26

FIG. 2. Amyloid deposits in cortical bone of head of femur. Syrius Supra Red stain. ×100

FIG. 3. Diffuse amyloid mass in trabecular bone of head of femur. Syrius Supra Red stain ×300



Fig. 4. Congophilic substance with green dichroism in head of femur. Congo-red stain, polarization microscopy. ×300

Fig. 5. Intense fluorescence of amyloid masses in trabecular bone of head of femur

The amyloid masses surrounded the haversian canals reaching sometimes the surface of the bone. Deposits were seen in both the fractured and the intact femoral bones. Osteoporosis was found in all cases but no necroses (Figs 2 to 5).

Discussion

The senile amyloid deposits in the organs increased with age [12, 13]: The presence of senile amyloid substance in the organs has amply been studied (heart muscle [7], brain: [9], Langerhans islets: [7], fibrous capsule of the hip

joint: [2], articular cartilage: [5], etc.). To the best our of knowledge, senile amyloidosis of the bones has not been described previously. Ladefoged and Christensen [5] found no difference in the amyloid content of cartilage from the upper and lower parts of the femoral head, indicating that the amyloid was equally distributed all over the cartilage surface and that pressure and friction cannot be the only pathogenetic factors. It is supposed that the amyloid deposits decrease the stability of the femur.

References

1. Bywaters EG, Dorling J: Amyloid deposits in articular cartilage. Ann Rheum Dis 29:294–299, 1970
2. Christensen HE, Sørensen KH: Local amyloid formation of capsula fibrosa in arthrosis coxae. Acta Pathol Microbiol Scand [A] 80, Suppl 223:128–131, 1975
3. Gamarski J, Netto MB: Osteo-articular manifestations in primary amyloidosis: case presentation. Arch Interamer Rheum 2:651–655, 1959
4. Koletsky S, Stecher RM: Primary systemic amyloidosis involvement of cardiac valves, joints and bones with pathologic fracture of the femur. Arch Pathol Lab Med 27: 267–288, 1939
5. Ladefoged C, Christensen HE: Congophilic substance with green dichroism in hip joints in autopsy material. Acta Pathol Microbiol Scand [A] 88:55–58, 1980
6. Nagy J: Block-festés kongóvörössel és savi thiazol fluorochromokkal (Block staning with Congo-red and acid thiazol fluorochromes). Morphol Igazságügyi Orv Szle 9:111–114, 1969
7. Nagy J: A senilis és praesenilis amyloidosisról (Senile and presenile amyloidosis). Orv Hetil 111:208–212, 1970
8. Puchtler H, Sweat F, Levine M: On the binding of Congo-red to amyloid. J Histochem Cytochem 10:355–364, 1962
9. Schwartz Ph, Kurucz J, Kurucz A, Zentralbl Pathol 106:320, 1964
10. Sweat F, Puchtler H: Demonstration of amyloid with direct cotton dyes. Arch Pathol Lab Med 80:613–617, 1965
11. Teglbjörg PS, Ladefoged C, Sørensen KH, Christensen HE: Local amyloid deposition pyrophosphate arthritis. Histological aspects. Acta Pathol Microbiol Scand [A] 87:307–311, 1979
12. Thung PJ: Amyloid and ageing. Proc IV. Congr Int Ass Gerontology 1: 175–179, 1957
13. Wright JR, Calcins E, Breen JW, Stolte G, Schultz RT: Relationship of amyloid to aging. Medicine 48:39–60, 1969

Knochenamyloidose

I. Szilágyi, A. Réffy, Zs. Demel und L. Józsa

Zur Untersuchung der Häufigkeit der senilen Amyloidose des Femurs im Sektionsmaterial, wurde das Knochengewebe im Bereich des Femurkopfes und der Femurhalsfraktur analysiert. Im Femur konnte sowohl in der Gegend des fraktuierten Schenkelhalses, als auch auf der intakten Seite, Amyloid nachgewiesen werden.

Амилоидоз костей

И. СИЛАДИ, А. РЕФФИ, Ж. ДЕМЕЛ и Л. ЙОЖА

На трупном материале авторы изучали частоту встречаемости старческого амилоидоза бедренной кости. Они исследовали костную ткань, взятую из области головки бедренной кости и места перелома шейки бедра. Они смогли выявить амилоид в костной ткани бедра как в области сложанной шейки, так и на здоровой стороне.

Dr. István Szilágyi
Dr. Antal Réffy
Dr. Zsolt Demel
Dr. László Józsa

National Institute of Traumatology, Budapest, Baross u. 23, H-1088

Acta Chirurgica Academiae Scientiarum Hungaricae, Tomus 23 (1), pp. 39–43 (1982)

Ultrasonic Diagnosis of Suprarenal Adenoma

V. Szabó,[1] L. Pajor[1], M. Sóbel[2] and F. Balogh[1]

Department of Urology, Semmelweis University Medical School[1] and Department of Gynaecology and Obstetrics, Korvin Ottó Hospital[2], Budapest

(Received March 6, 1981)

In two out of eight patients ultrasonic scanning confirmed and helped to find the localization of the suspected suprarenal lesion. The method is preferred since it is non-invasive and absolutely painless. Removal of the corticoadrenal adenoma in one patient normalized the hormone balance and in the other it restored normal blood pressure.

Relying on published data, we have applied echography because of its being non-invasive and absolutely painless in the diagnostics of the diseases of the suprarenal gland [1]. Owing to its size, it is difficult to depict the healthy suprarenal gland, while in children the task is easier since in them the gland is proportionally large [2]. According to the pertaining literature, ultrasonography is indicated when there is a suspicion of adrenal haemorrhage, tumour, cyst or hyperplasia [3].

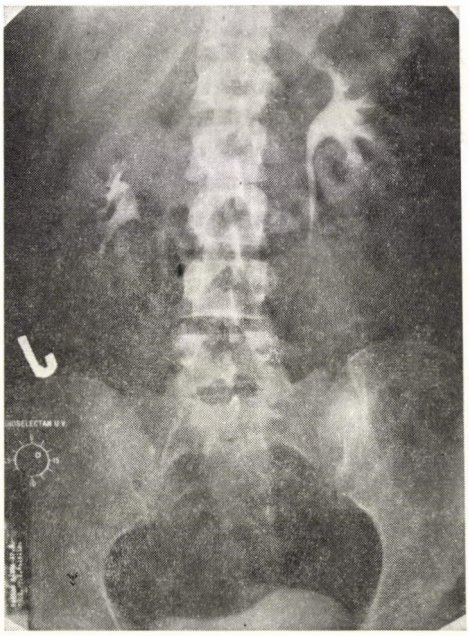

Fig. 1. Secretion urography. The right kidney is flattened, above its upper pole a round visceral shadow of about 25 mm diameter can be suspected

Material and Method

In the years between 1974 and 1979, our Department admitted 17 patients for endocrine surgery. The diagnosis on admission was Cushing's syndrome in 12 cases and adrenal tumour in five cases. Bilateral ultrasonic scanning was performed in eight patients to localize the process. Sonography was carried out without preparation in the prone position. After determination of the renal axes longitudinal and cross-sectional pictures were taken at every 0.5 cm supramedially from the upper pole. Attempts were made to take the pictures during a long inspiration to reduce the number of artifacts arising from respiratory movements and to utilize the caudal position of the organ. It is important to accurately differentiate the suprarenal gland from the kidney located in the same capsule. In two patients of eight, an adrenal disturbance was detected by means of sonography.

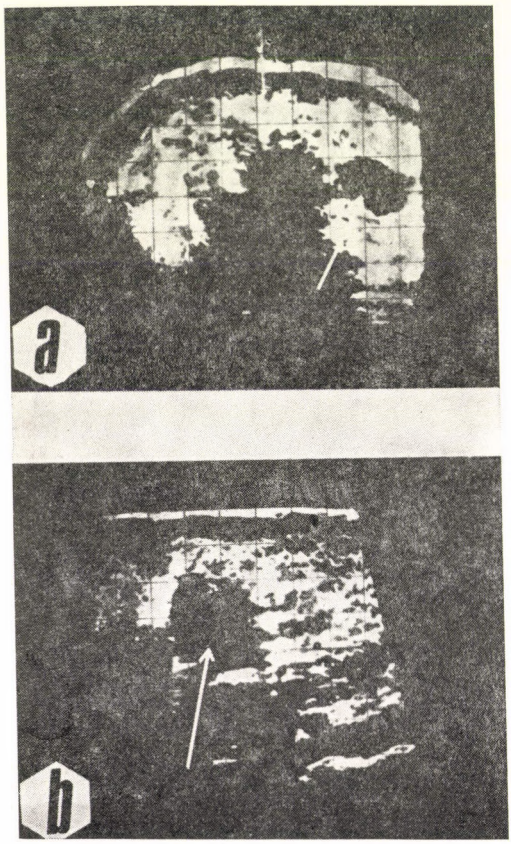

FIG. 2. Echographic longitudinal (*a*) and cross-sectional (*b*) pictures. Pictures taken at the height of the twelfth thoracic vertebra show an acoustically homogeneous formation of a size of 2.5 × 3 cm (arrows). Apparatus: Kretz-Technik 4100 MGS. Frequency: 1.5 MHz, size of picture: 3

Case Reports

Case 1. M. F., a 19-year-old female patient had had an excessive hair growth of body hair in the prvious two years. Endocrine tests indicated an androgen producing adrenal adenoma. Secretion urography showed the suspicion of a shadow about 2.5 cm in diameter above the compressed right kidney (Fig. 1). On the longitudinal and cross-sectional echograms a 2.5×3 cm,

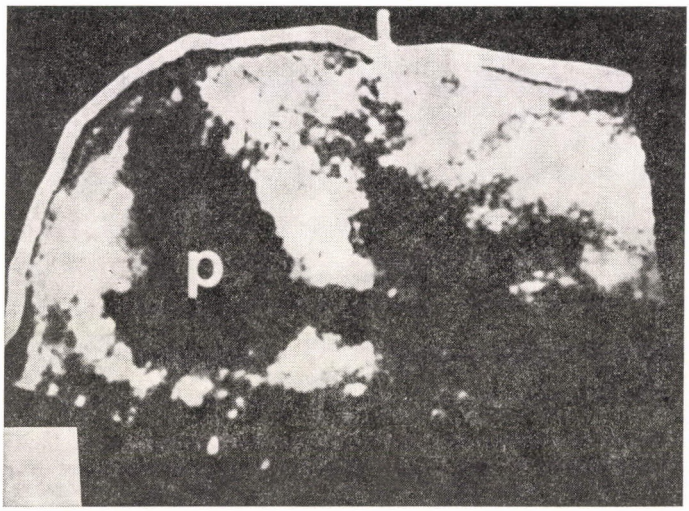

FIG. 3. Echographic (gray scale) cross-sectional picture. At the height of the twelfth thoracic vertebra a 2.5×5 cm large formation independent of the kidney is visible (p). Apparatus: Combison 200

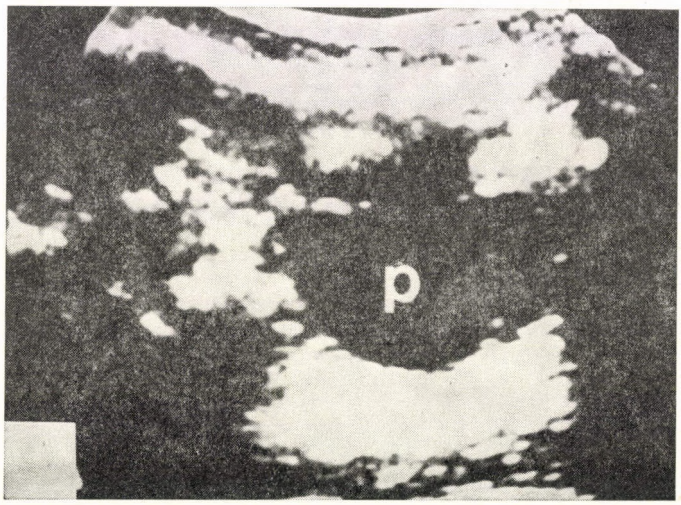

FIG. 4. On the paravertebral sectional picture of the left side a homogeneous resistance (p) can be seen above the kidney

acoustically homogeneous formation was visible on the right side (Fig. 2). Total adrenalectomy was performed on the right side; histological examination showed an adrenocortical adenoma. Subsequently, the patient's hormonal balance had normalized and in the three years since operation she has been free of complaints.

Case 2. G. L., a 67-year-old female patient in the past three years had had sudden episodes of high blood pressure. The possibility of phaeochromocytoma was considered, but only the high glycocorticoid level could be proved. Angiography pointed erroneously to a tumour in the upper pole of the left kidney. Echography showed on the left side a 2.5×5 cm homogeneous resistance without a marked capsule but nevertheless independent of the kidney (Figs 3, 4). At surgery, a cortical adenoma was removed. After the operation the patient's blood pressure soon became normal.

Discussion

For the pre-operative localization of biochemically proven adrenal diseases, the following procedures can be used

- secretion urography,
- pneumoretroperitoneum,
- adrenal arteriovenography,
- isotope (selenium, iodine) labelled cholesterol accumulation,
- selective cortisol level of the suprarenal vein,
- echography,
- computer tomography.

Of these tests the last two are non-invasive and therefore be given preference. In our cases the adrenal adenomas were about 40 mm in diameter, thus were far above the resolving power of the method. Technical development of the apparatus will probably lead to a further rise of the resolution power.

The echographic picture of the surgically removed adrenal adenomas was similar to that of cysts, since the acoustically homogeneous tumours were surrounded capsule-like by the tissues of the suprarenal gland which had suffered pressure atrophy.

References

1. Jsaon C, Birnholz et al.: Ultrasound imaging of adrenal mass lesions. Radiology 109: 163, 1973
2. Davidson JK et al.: Adrenal venography and ultrasound in the investigation of the adrenal gland: an analysis of 58 cases. Br J Radiol 48: 435, 1975
3. Beierwaltes XM et al.: Visualisation of human adrenal glands *in vivo* by scintillation scanning. J. Am Med Assoc 216 275, 1971

4. Brownlie K, Kreel L: Computer assisted tomography of normal suprarenal gland. J Comput Assist Tomogr 2:1, 1978
5. Andersson L et al.: In: Diagnostic Radiology, Urological Ultrasonography. Springer Verlag, Berlin–Heidelberg–New York 1977

Diagnostizierung des Nebennierenadenoms mit Sonographie

V. Szabó, L. Pajor, M. Sóbel und F. Balogh

Berichtet wird über zwei Fälle, in denen die mittels Sonographie nachgewiesenen Nebennierenadenome auch durch den intraoperativen Befund verifiziert wurden. Die angewendete Methode hat sich bei der Lateralisierung der vorangehend endokrinologisch nachgewiesenen Prozessen für völlig gefahrlos erwiesen.

Диагностика аденомы надпочечников ультразвуком

В. САБО, Л. ПАЙОР, М. ШОБЕЛ и Ф. БАЛОГ

В двух случаях авторам удалось диагностировать аденому надпочечника методом эхографии, подтвержденную затем на операции. Они подчеркивают безопасность этого диагностического метода при латеризации процессов, доказанных предварительно эндокринологически.

Dr. Vilmos Szabó
Dr. László Pajor
Dr. Ferenc Balogh
} Department of Urology, Semmelweis University Medical School, Budapest, Üllői út 78/b, H-1082

Dr. Mátyás Sóbel — Department of Gynaecology and Obstetrics, Korvin Ottó Hospital, Budapest, Gorkij fasor 9–11, H-1071

Acta Chirurgica Academiae Scientiarum Hungaricae, Tomus 23 (1), pp. 45–53 (1982)

Disorders of the Urea Cycle in Pathospermias

GY. PAPP, J. GRÓF and J. MENYHÁRT

Division of Clinical Biochemistry and Cytobiology, Joint Research Organization of the Hungarian Academy of Sciences and of Semmelweis University Medical School, Budapest

(Received June 20, 1981)

The andrologic roles of arginine and its metabolites are discussed. The level of the urea precursor citrulline and of the end-product urea in the serum and sperm plasma of pathospermic patients was studied.

Clarification of the molecular mechanism contributing to the development and maintenance of pathospermic states is one of the main problems of andrology.

In agreement with published data [1, 6, 7, 8, 12, 26] in earlier studies we found that in a certain group of pathospermic patients a characteristic change takes place in sperm plasma levels and enzymatic activities of the intermediaries and end-products of arginine metabolism [18, 19]. In the present paper we shall report on analysis of molecular mechanisms to be found in the background of some changes characteristic of the above mentioned group of pathospermias.

Material and Method

Samples

Blood and ejaculate samples were taken from healthy (NS; n = 10) and pathospermic (PS; n = 27) men aged between 19 and 45 years. On the basis of the clinical diagnosis, the PS group was divided into the following sub-groups: oligozoospermia (OS; n = 8), maximal oligozoospermia (MOS; sperm = 0 to 5×10^6/ml, n = 9), azoospermia (AS; n = 10).

The ejaculates were obtained by masturbation after exactly five days of abstinence. After 30 minutes of standing at room temperature, as required for routine tests, the liquefied ejaculates were centrifuged at 10 000 rpm, for 10 minutes at room temperature and the decanted sperm plasma was stored at −20 °C till further use.

The serum samples were obtained at the same time as the ejaculates. Coagulation of the blood taken from the cubital vein was inhibited by citrate. After centrifugation the supernatant was stored at −20 °C.

Determination of the urea, citrulline and protein contents of serum and sperm plasma was done according to Archibald and Ceriotti. For each determination 20 μl urea or 50 μl citrulline of the original samples was used. Part of the remaining sample was diluted to 200 times its initial volume with distilled water and the protein content of 200 μl of the diluted solution was determined by the method of Lowry et al. [13].

Determination of the apparent arginase activity

The degree of apparent arginase activity can be determined with the help of the following formula: Sperm plasma. Δ urea μmol/mg sperm plasma protein, where Δ urea = sperm plasma urea (μmol/ml) — serum urea (μmol/ml).

Results

Serum and sperm plasma urea concentration in pathospermia

The serum urea concentration in the PS-group (4.0 $\pm$ 1.18 mM) was practically the same as in the NS-group (3.83 $\pm$ 0.91 mM), at the same time, the urea concentration of the sperm plasma in the pathospermic group was about 66% higher than in the normospermic group (Fig. 1).

When within the PS-group, the urea concentration in the sperm plasma of the sub-groups formed on basis of the diagnosis was compared to that in the NS-group, the findings were as follows (Fig. 2). There was practically no

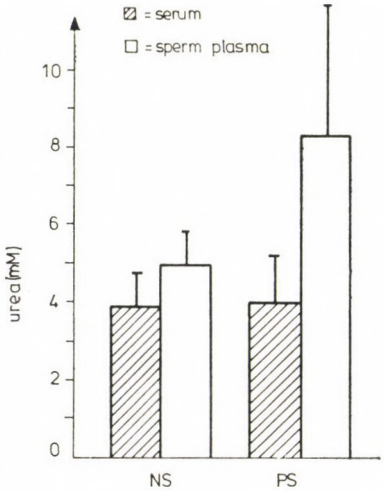

FIG. 1. Urea concentrations of blood serum and sperm plasma in normospermia (NS; n = 9) and pathospermia (PS; n = 28)

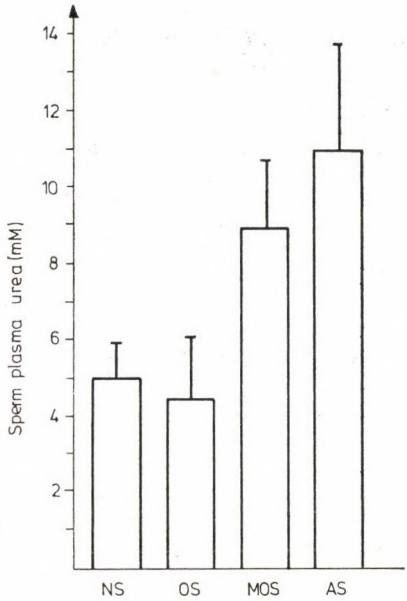

Fig. 2. Urea concentration (mmol/l) of sperm plasma in NS (n = 9), oligo (OS; n = 8), maximal oligo (MOS; n = 9) and aspermia (AS; n = 10)

difference in the sperm plasma urea concentration between the OS-group (4.4 ± 1.60 mM) and the NS group (5.0 ± 0.89 mM). In the MOS-group, urea concentration (9.0 ± 1.73 mM) was about 78% higher ($p < 0.01$) than in the NS and about 102% higher ($p < 0.01$) than in the OS-group, and the sperm plasma urea concentration in the AS-group, 11.1 ± 2.78 mM, was round 121% ($p < 0.01$) higher than in the NS and about 149% higher ($p < 0.01$) than in the OS-group. As far as this parameter is concerned, no difference has been detected between the groups AS and MOS.

Citrulline concentrations in blood serum and sperm plasma in pathospermia

There was no significant difference between the values of citrulline concentration for the serum (38.3 ± 12.55 μM) and for the sperm plasma (34.7 ± ± 13.69 μM) in the PS-group, and those measured in normospermic subjects (serum: 45.5 ± 6.62, sperm plasma: 42.5 ± 13.99 μM). Neither was there a significant difference in citrulline concentration in the serum and sperm plasma of normo- and pathospermic subjects (Table I).

Division of the PS-group into subgroups led to the following findings. The citrulline concentration of serum in the OS and MOS groups was about 22 and 24%, respectively, lower than in the NS-group. The serum citrulline

TABLE I

Urea (mmol/l) and citrulline (μmol/l) concentration of the sperm plasma in groups NS and PS

	Urea			Citrulline		
	NS	PS	Δ%	NS	PS	Δ%
$\bar{X}$	5.00	8.42	66.51	42.47	34.69	−18.33
± SD	0.89	3.46		13.99	13.69	
n	9	28		9	2.8	
P	≪0.01			>0.1		

Δ% = percentage deviation from the value in the NS-group (100%). The symbols are the same as in Fig. 1

TABLE II

Serum citrulline concentration (μmol/l) in groups NS, OS, MOS and AS

	Groups			
	NS	OS	MOS	AS
$\bar{X}$	45.39	35.38	34.28	44.30
± SD	6.62	8.18	10.16	15.73
Δ%	0	−22.06	24.48	−2.4
n	9	8	9	10
P		< 0.02	< 0.02	ns
			ns	ns
				ns

For symbols see Fig. 2 and Table I

TABLE III

Citrulline concentration (μmol/l) of sperm plasma in groups NS, OS, MOS and AS

	Group			
	NS	OS	MOS	AS
$\bar{X}$	42.47	47.11	29.64	30.48
± SD	13.99	12.10	9.18	11.12
Δ%	0	10.92	−36.50	−28.18
n	9	9	9	10
P		ns	<0.02	ns
			<0.01	<0.01
				ns

For symbols see Fig. 2 and Table I

concentration in the AS-group showed no marked difference from that in the NS subjects (Table II). No significant difference was found in the serum citrulline concentration in the three pathospermic subgroups either (Table II). As to the sperm plasma citrulline concentration in the pathospermic subgroups, only in the MOS group ($\Delta\% = -36.5$) was this value lower than in the NS-group (Table III), the sperm plasma citrulline concentration was significantly lower in the MOS and AS groups than the concentration in the OS group, but with respect to citrulline concentration, there was no significant difference between the MOS and AS groups (Table III).

Serum and sperm plasma protein concentration in pathospermia

No difference worth noting was found in serum protein concentration between the NS and PS groups (NS: 9.9 ± 1.24; PS: 8.9 ± 1.39). Similarly, there was no detectable difference in sperm plasma protein concentration between the same two groups (NS: 7.4 ± 2.13; PS: 5.9 ± 21.70). In normospermic subjects the sperm plasma protein concentration was about 30% ($p < 0.01$), and in pathospermia 33% ($p < 0.01$), lower than the serum protein level.

When the pathospermic group was divided into the usual subgroups, the results shown in Table IV were obtained. The protein sperm plasma concentration in groups OS and MOS were practically the same as the values measured in the NS group. The sperm plasma protein concentration in the AS group was 36% lower than the value measured in the NS group. In the sperm plasma protein level there was no significant difference in the three pathospermic subgroups.

TABLE IV

Protein concentration (g/dl) of sperm plasma in groups NS, OS, MOS and AS

	Group			
	NS	OS	MOS	AS
$\bar{X}$	7.44	6.42	6.67	4.75
$\pm$SD	2.13	2.02	2.52	1.58
$\Delta\%$	0	−7.31	−10.45	−36.19
n	9	8	9	10
P		ns	ns	$\leqslant$0.01
			ns	ns
				ns

The symbols are as in Fig. 2 and Table I

Apparent arginase activity of the sperm plasma in pathospermia

The apparent arginase activity of the sperm plasma was 48.6% higher in the PS group than in the normospermic subjects ($p < 0.01$) (Fig. 3). In the pathospermic subgroups, the following results were obtained (Fig. 4). There was no difference in apparent arginase activity of the sperm plasma in the OS

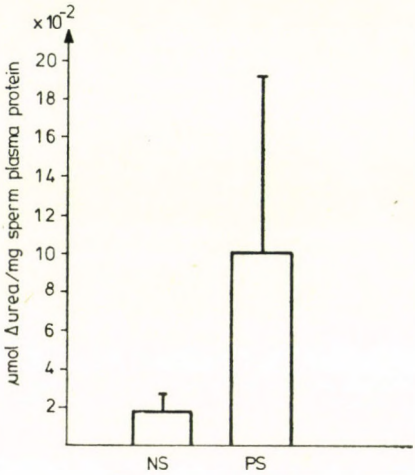

Fig. 3. Apparent arginase activity (μmol urea per mg sperm plasma protein) of sperm plasma in groups NS and PS

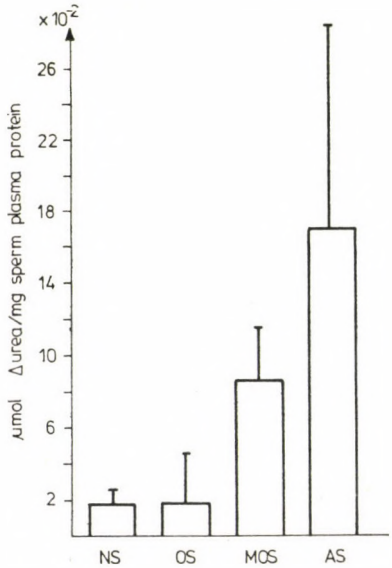

Fig. 4. Apparent arginase activity (μmol urea per mg sperm plasma protein) of sperm plasma in groups NS, OS, MOS and AS

group ($1.7 \pm 2.75 \times 10^{-2}$ μmol/l urea per mg protein) and if normospermic subjects ($1.7 \pm 0.84 \times 10^{-2}$ μmol/l of urea per mg protein), while it was significantly ($p < 0.01$) lower than the values measured in the MOS group ($8.6 \pm \pm 2.86 \times 10^{-2}$ μmol/l urea per mg protein) and in the AS group ($16.97 \pm \pm 11.30 \times 10^{-2}$ μmol/l urea per mg protein). In this value the MOS group differed from all the three other groups, but while the apparent arginase activity of the sperm plasma in the MOS group was 389% higher than in the PS and 405% higher than in the OS group ($p < 0.01$), it was about 49% lower than that in the AS sub-group ($p < 0.05$). The apparent arginase activity of the sperm plasma in the AS group surpassed by about 866% ($p < 0.01$), 898% ($p < 0.01$) and 97% ($p < 0.05$) the values measured in the NS, OS and MOS groups, respectively.

Discussion

With the spread of family planning, the importance of male sterility increased all over the world. In the course of clarifying the causes of pathospermia, first of all the morphologic, evolutionary and endocrinologic deviations were detected. According to Schirren (1980), beside the introduction of electron-microscopic morphological and histochemical techniques, development in this field can be expected primarily from immunological and biochemical research. We have decided to study the biochemical changes hidden in the background of male infertility. In addition to our earlier results, this decision seems to be justified by the following data.

l-arginine, an important constituent of the organisms of higher order, is an amino acid essential for proliferating tissues and cells (e. g. of spermatocytes) [2, 5, 9, 14, 15]. l-ornithine is the biologic precursor and, at the same time, the end-product of the biodegeneration of l-arginine, as well as, similarly to arginine, the biologic precursor of other basic polyamines, such as putrescine, spermidine and spermine. Though the mechanism of action of these bases is not known, their direct and/or indirect role in the stimulation of karyokinesis has been established [17, 24].

As in adult mammals, l-arginine is synthesized in a sufficient quantity in the liver by the enzyme system arginine synthetase, according to the common definition it cannot be considered an essential amino acid [3, 16, 20, 26]. None the less, an arginine-free diet causes a decrease in the number of sperms [10, 23]. l-arginine is known to enhance under *in vitro* conditions the motility of sperms [11, 12], and, as already mentioned, an impairment of arginine metabolism can be detected in a certain group of pathospermic patients.

The results of these investigations, while confirming our earlier observations, indicate that in some pathospermic patients a complex lesion of arginine-metabolism may be present. On the basis of the above described

results, the characteristic features of such disorders can be summed up as follows.

1. In pathospermia, the urea concentration of the sperm plasma is higher than normal. This increase was the most marked in patients with the clinical diagnosis of maximal oligospermatism and azoospermia.

2. Almost parallel to the increase of the sperm plasma urea concentration, the serum citrulline concentration was significantly lower in clinically oligospermic and maximally oligospermic patients.

3. In the sperm plasma of patients with maximal oligozoospermia and azoospermia, the citrulline concentration was significantly lower than in the normo- and oligospermic groups.

4. In pathospermias the apparent arginase activity of the sperm plasma is on the average one order of magnitude higher than the values in normozoospermic subjects.

These data, together with our earlier results and other data in the literature, indicate that for the elaboration of a rational causal therapy of pathospermia it is indispensable to clarify the apparently essential regulatory and/or modulating role in spermatogenesis, of the intermediaries ornithine, citrulline and arginine which are the keys to the urea-cycle. Our work now in progress aims at clarifying this problem.

References

1. Ballerio C, Giarcia A: Les tendances modernes dans le traîtement de l'infertilité masculine. Gynéc Prat 4:95, 1953
2. Borman A, Wood TR, Black HC, Anderson EG, Oesterling MJ, Womack M, Rose WC: The role of arginine in growth with some observation on the effects of argininic acid. J Biol Chem 166:585, 1946
3. Burroughs EW, Burroughs HS, Mitschel HH: The amino acids required for the complete replacement of endogenous losses in the adult rat. J Nutr 19:363, 1940
4. Ceriotti G: Optimal conditions for ornithine carbamyl transferase determination. A simple method without deproteinization. Clin Chim Acta 47:97, 1973
5. Gaman E, Fischer H.: The essentiality of arginine, lysine and methionine for the growing rabbit.
6. Giarola A, Pagani C: Azione degli aminoacidi in vitro sulla dinamica nemospermi umani. Ann Ostet Gynecol Med Perinat 72:1177, 1950
7. Giarcia A, Ballerio C: Trattamento di elezione nelle subfertilita seminali. Ann Ostet Gynecol Med Perinat 2:179, 1959
8. Hazard J: Arginine et infertilité masculine. Sem Hop Paris 30:984, 1954
9. Heinecke HR, Horper AE, Elukjem CA: Protein and amino acid requirements of the guinea pig. 1. Effect of carbohydrate, protein level and amino acid supplementation. J Nutr 57:483, 1955
10. Holt LE, Albanese A: Observation on amino acid deficits in man. Trans Assoc Am Physicians 58:143, 1944
11. Keller DW, Polaski KL: L-Arginine stimulation of human sperm motility *in vitro*. Biol Reprod 13:154, 1975
12. Krampitz G, Doepfner R: Determination of free amino acids in human ejaculate by ion exchange chromatography. Nature 194:684, 1962
13. Lowry CH, Rosebrough N, Farr AL, Randall RJ: Protein measurement with the folin-phenol reagent. J Biol Chem 193:265, 1951

14. McWard GW, Nicholson LB, Poulton BR: Arginine requirement of the young rabbit. J Nutr 92:118, 1967
15. Milner JA, Waheling AE, Visek WJ: Effect of arginine deficiency on growth and intermediary metabolism in rats. J Nutr 104:1681, 1974
16. Nakagawa I, Takashi T, Suzuki T, Kobayashi K: Amino acid requirements of children. Minimal needs of tryptophan, arginine and histidine based on nitrogen balance methods. J Nutr 80:305, 1963
17. Oka T, Perry JW: Arginase effects lactogenesis through its influence on the biosynthesis of spermidine. Nature 250:660, 1974
18. Papp Gy, Gróf J, Molnár J, Jémbor E: Az arginintartalom és arginázaktivitás szerepe a fertilitásban (The role of arginine content and arginase activity in fertility). Ur Nephrol Szle 4:189, 1978
19. Papp Gy, Gróf J, Molnár J, Jémbor E: The importance of arginine content and arginase activity in fertility. Andrologie 11:37, 1979
20. Rose WC, Rice EE: The significance of amino acids in canine nutrition. Science 90: 186, 1939
21. Rose WC, Haines WJ, Warner LT: The amino acid requirements of man. V. Role of lysine, arginine and tryptophan. J Biol Chem 206:421, 1954
22. Schachter A, Friedman S, Goldman J, Eckerling B: Treatment of oligospermia with the amino acid arginine. Int J Gynaecol Obstet 11:206, 1973
23. Silvestrani GF, Conti C: Arginine evaluation to verify sperm maturation in man. Arch Androl 1:363, 1978
24. Tabor H, Tabor CW: Biosynthesis and metabolism of 1,4-diaminobutane, spermidine, spermine and related amines. Adv Enzymol 36:203, 1972
25. Tanimura J: Studies on arginine in human semen. Bull Osaka Med Sch 13: 76, 1967
26. Wolf PA, Corley RC: Significance of amino acids for the maintenance of nitrogen balance in the adult white rat. Am J Physiol 127:589, 1939

Störung des Ureazyklus bei Pathospermien

GY. PAPP, J. GRÓF und J. MENYHÁRT

Im Rahmen der Analyse der andrologischen Rolle von Arginin und seiner Stoffwechselprodukte, wird in vorliegender Arbeit über die Gestaltung des Ureaspiegels des Präkursor-Zitrullins und des Endprodukts im Blutserum und im Spermaplasma pathospermischer Patienten berichtet.

Нарушение цикла мочевины при патоспермии

ДЬ. ПАПП, И. ГРОФ и Я. МЕНЬХАРТ

Авторы занимаются исследованием андрологической роли аргинина и продуктов его метаболизма. В настоящей работе они изучают формирование уровня предшественника цитруллина и конечного продукта мочевины в кровяной сыворотке и плазме спермы у больных с патоспермией.

Dr. György PAPP
Dr. József GRÓF
Dr. János MENYHÁRT

Division of Clinical Biochemistry and Cytobiology, Joint Research Organization of the Hungarian Academy of Sciences and of Semmelweis University Medical School, Budapest, Üllői út 78/a, H-1082

Acta Chirurgica Academiae Scientiarum Hungaricae, Tomus 23 (1), pp. 55—60 (1982)

Successful Vasoepididymoanastomosis by Microsurgery

GY. PAPP and ZSUZSA BALOGH

Division of Clinical Biochemistry and Cytobiology, Joint Research Organization of the Hungarian Academy of Sciences and of Semmelweis University Medical School, and Department of Urology, István Hospital, Budapest

(Received August 21, 1981)

A case of successful vasoepididymoanastomosis is described. Martin's microsurgery set used for the operation was found suitable and is therefore recommended for the treatment of obstructive andrological lesions.

According to Molnár [10], 12% of the pathospermias is caused by obstruction of the ejaculatory duct. In most cases these lesions are the results of inflammation (earlier mainly of gonorrhoea) or of scars or kinking caused by operations in the vicinity of the vas deferens, e. g. for inguinal hernia. A similar situation is created by the congenital absence of the vas deferens, or when the vas deferens ends in a blind pouch, or its atresia or when the corpus or tail of the epididymis is missing [2, 3, 6, 11, 14]. The obstruction is as a rule detected by deferentovesiculography, in simpler cases by palpation [9, 14]. Passage is restored by recanalization, i. e. vasoepididymostomy or vasovasostomy [3, 5, 6, 8, 12, 15, 18].

The first epididymovasostomy was performed by Martin in 1902 [7]. Subsequently, the method was widely adopted in Europe [2, 3], though, even according to the best statistics, the results yielded by the traditional surgical technique did not surpass 40% [2, 8, 12, 14].

This was partly due to the inadequate indication and choice of the method and partly to the scars caused by the operation. Since the introduction of microsurgery the results have greatly improved [2, 6, 19].

Report of a Case

N. N., a 24-year-old subject consulted our andrological clinic on April 15, 1981. He has been married for three years, and though they practised no contraception, his wife had not become pregnant. Four years ago he twice had gonorrhoea, followed by bilateral epididymitis. He had no systemic illness. He had been tested in three centres, the diagnosis was azoospermia.

The right testicle measured 9 cm^3, the left one, 11 cm^3, both appeared intact on palpation. Epididymis and vas deferens were normal on both sides but on palpation the tail parts of both epididymides appeared more compact than normal. The ejaculate was of normal appearance, pH 7.2, 2.1 ml in volume; it contained no sperm or spermatogenetic formation.

Diagnosis: the tests suggested azoospermia. Biopsy from the testicle was suggested.

Biopsy from the left testicle: the histological pattern showed a qualitatively normal spermatogenesis of a lower than normal rate Molnár, (Fig. 1).

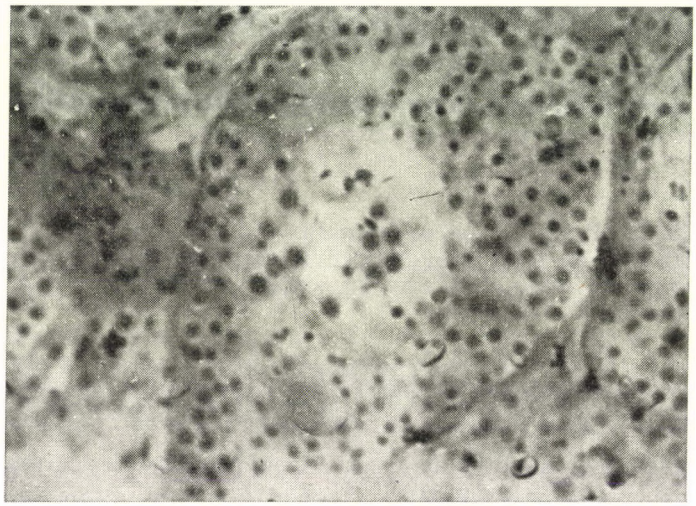

FIG. 1. Histological picture of left testicle

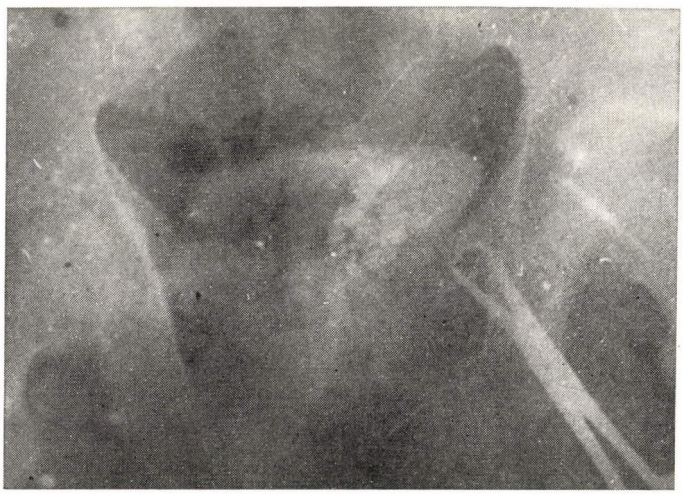

FIG. 2. Deferento vesiculography



FIG. 3. Martin's microsurgical set

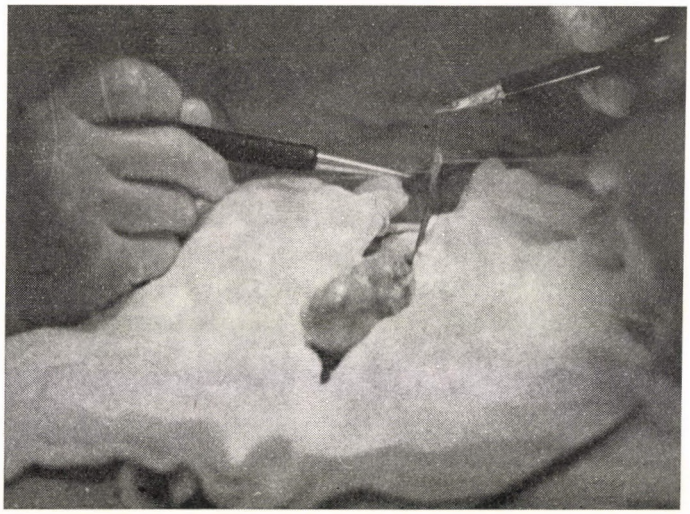

FIG. 4. Implantation of vas deferens (phase *a*)

These findings raised the possibility of an obstruction in the ejaculatory duct, primarily at the level of the epididymis. Deferentovesiculography showed free passage from the scrotal section of the vas deferens. (The contrast medium was introduced about 2.5 cm from the tail part of the epididymis.) (Fig. 2).

After assessment of the deferentogram, the operation was extended and the left epididymis complex exposed. Palpation revealed a scarred and compact tail part. It was decided for vasoepididymostomy.

On July 22, 1981, the vas deferens was implanted into the intact part of the epididymis by end-to-side anastomosis, using Martin's microsurgical

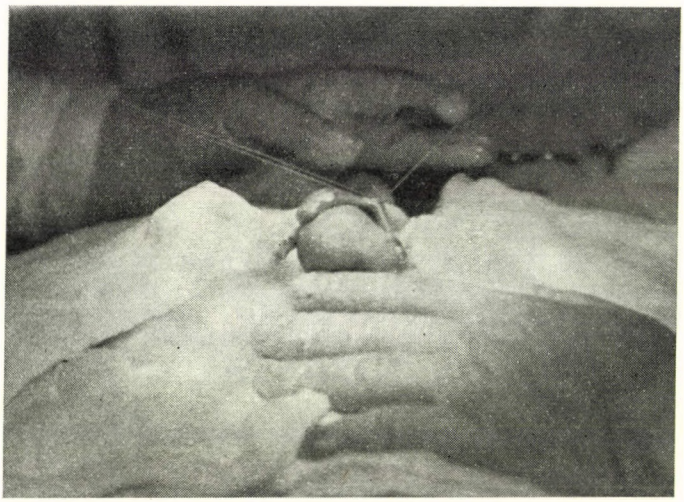

FIG. 5. Implantation of vas deferens (phase *b*). The obliquely opened end of the vas deferens was fixed to the adventitia in addition to three basic stitches by two rows of two stitches

instruments and spectacles. Deferentovesiculography and implantation were performed in one sitting (Figs 3, 4, 5). Six days later, the patient was discharged.

Andrological follow-up 12 days after the operation showed a healed wound, and no sensitivity. The ejaculate was usual in appearance, pH 7.2, volume 3.3 ml. In every visual field 8 to 10 sperms could be seen, 2 to 4 of which moved in a coordinated way. In addition 3 to 4 genetic formations, mainly spermatocytes, were detected per visual field.

Diagnosis: maximal oligospermia.

Check-up showed free passage and andrological treatment was to be introduced in three months, after spermatological control tests.

Discussion

Microsurgical treatment of pathospermia has ensured favourable results and has gained universal acceptance [4, 15, 16, 17, 18, 19, 20].

Today, such operations are indicated not only in the case of obstruction, atresia or replacement of the vas deferens, but also when subjects vasoectomized earlier for reasons of contraception have to be re-anastomosed. The number of the later cases is continuously increasing [5, 17, 18, 19].

In Hungary, the first andrological recanalization was performed by Babics in 1942 [1]. Thanks to Molnár's activity, this type of operation has spread in Hungarian andrological practice [9]. Today, recanalization is per-

formed in several Hungarian surgical departments, and though only Molnár [9] and Papp et al. [12] have reported on a relatively large material, we know that Scultéty and co-workers, too, have performed successful vas deferens implantations. Many of these subjects have become fertile within a short time. Thus, in Molnár's material, out of 33 cases, 6 induced pregnancy.

In the reported case, we have solved by microsurgical means an azoospermic state of three years standing. Many operations of this type will be required in the future by the increasing demand for reliable diagnosis of passage disorders of the ejaculatory duct, or for reverting the obstruction done for male contraception.

References

1. Babics A: Personal communication.
2. Dubin L, Amelar RD: Surgery for male infertility. In: Male Infertility, W. B. Saunders Co., Philadelphia 1977.
3. Ferster H, McLoughin MG: Epididymovasostomy for epididymal obstruction. In: Surgery of the Male Reproductive Tract, ed. Lipschutz, G, Martinus Nijhoff, Amsterdam 1980
4. Gomel V: Tubular re-anastomosis by microsurgery. Fertil Steril 28:59, 1977
5. Hee Yong Lee and members of the Vasectomy Study Project: Observations of the results of 300 vasovasostomies. J Androl 1:11, 1980
6. Hee Yong Lee: Corrective surgery of obstructive azoospermia. Arch Androl 1:115, 1978
7. Martin E: Surgical treatment of sterility. Penn Med Bull 15:2, 1902
8. Mohsenian M: Surgical treatment of male sterility. Proc. 7th World Congress on Fertility and Sterility. Japan 1971. Excerpta Med. Congr. Ser., No. Amsterdam 1973
9. Molnár J.: Általános spermatológia (General Spermatology). Akadémiai Kiadó, Budapest 1962
10. Molnár J.: Pathospermiás kórképek és endokrin kapcsolatok (Pathospermic disorders and endocrine relations). Orvosképzés 1:60, 1964
11. Molnár J, Papp Gy, Hazay L: Auf seltenen Entwicklungsanomalien beruhende Aspermia. Z. Ur Nephrol 69:41, 1976
12. Papp Gy, Molnár J, Lantos I: A műtéti beavatkozás értéke és helye az andrológiában (The value and place of surgical intervention in andrology). Magy Seb 32:188, 1979).
13. Papp Gy, Molnár J, Lantos I: Value and indications of surgery in andrology. Int Ur Nephrol 12:336, 1980
14. Papp Gy, Molnár J: A férfimeddőség okairól (The causes of male sterility). Orvosképzés (in press)
15. Schmidt SS: Anastomosis of the vas deferens. An experimental study. II. Success and failures in experimental anastomosis. J Ur 81:203, 1959
16. Silber SJ: Microsurgery in clinical urology. Urology 6:150, 1975
17. Silber SJ: Microscopic technique for reversal of vasectomy. Surg. Gynecol Obstet 143:630, 1976
18. Silber SJ: Perfect anatomical reconstruction of vas deferens with a new microscopic surgical technique. Fertil Steril 28:72, 1977
19. Silber SJ, Galle J, Friend D: Microscopic vasovasostomy and spermatogenesis. J Ur 177:299, 1977
20. Stangel JJ, Shettles HE, Reyniak JV, Freedman WL, Stone ML: Microsurgical anastomosis of the rabbit oviduct using 9.0 monofilament polyglycolic acid suture. Fertil Steril 30:210, 1978

Erfolgreiche Vasoepididymoanastomose (VEA) mit mikrochirurgischer Technik

Gy. Papp und Zsuzsa Balogh

Berichtet wird, zuerst in der einheimischen Literatur, über eine mit der mikrochirurgischen Technik erfolgreich angelegte Vasoepididymoanastomose (VEA).

Das zur Operation verwendete Martinsche „Mikrosurgery-Set" wird zur Behandlung von andrologischen Abweichungen obstruktiven Ursprungs für geeignet gehalten und angesichts seiner Vorteile auch aufrichtig empfohlen.

Результаты вазоэпididимонастомоз VEA — микрохирургической техникой

ДЬ. ПАПП и Ж. БАЛОГ

Авторы первыми в венгерской научной литературе сообщают о случае успешно проведенного с помощью микрохирургической техники вазоэпididимоанастомоза.

Использованный при операции „*Microsurgery-set*" Мартина они считают пригодным для лечения андрологических отклонений обструктивного происхождения, и основываясь на его преимуществах, рекомендуют для практического применения.

Dr. György Papp — Division of Clinical Biochemistry and Cytobiology, Joint Research Organization of the Hungarian Academy of Sciences and of Semmelweis University Medical School, Budapest, Üllői út 78/a, H-1082

Dr. Zsuzsa Balogh — Department of Urology, István Hospital, Budapest, Nagyvárad tér 1, H-1095

CONTENTS

Balogh, Á. Szlávy, L. Sulyok, Z. Tóth L. and *Besznyák, I.:* Diagnostic angiography in tumours of the neck 1

Csordás, T. and *Bertók, L.:* Effect of lead acetate on the endotoxin susceptibility of pregnant rats 9

Csata, S. Kulcsár, Gizella, Dán, P. Horváth, J. Nász, I. Ongrádi, J. and *Verebélyi, A.:* Adenovirus antibodies in tumorous diseases of the urogenital system 15

Galuska, L. and *Gervain, M.:* Investigation of the functioning of the ileum-ureter by means of camera renography 23

Szilágyi, I. Réffy, A. Demel, Zs. and *Józsa, L.:* Amyloidosis of bones 33

Szabó, V. Pajor, L. Sóbel, M. and *Balogh, F.:* Ultrasonic diagnosis of suprarenal adenoma 39

Papp, Gy. Gróf, J. and *Menyhárt, J.:* Disorders of the urea cycle in pathospermias 45

Papp, Gy. and *Balogh, Zsuzsa:* Successful vasoepididymoanastomosis by microsurgery 55

PRINTED IN HUNGARY
Akadémiai Nyomda, Budapest

The *Acta Chirurgica*, a periodical of the Hungarian Academy of Sciences in the field of medical sciences, publish original scientific treatises on surgery and related disciplines (general surgery, surgical aspects of gynecology, urology, oto-rhino-laryngology, orthopaedics, ophthalmology, as well as nerve and brain surgery, pulmonary, oral surgery, heart and blood-vessel surgery) in English, German, French or Russian, with abstracts in languages other than that of the paper.

The *Acta Chirurgica* appear in one volume per year, on some four hundred pages, divided into four fascicles issued quarterly.

Manuscripts should be addressed to

Acta Chirurgica
H-1096 Budapest, Nagyvárad tér 1. István Kórház, Urológia

Orders may be placed with "Kultura" Foreign Trading Company (H-1389 Budapest 62, P.O.B. 149) or its representatives abroad.

Les *Acta Chirurgica*, une revue de l'Académie des Sciences de Hongrie, publient des communications scientifiques originales du domaine de la chirurgie et ses disciplines voisines (chirurgie générale, gynécologie, urologie, oto-rhino-laryngologie, orthopédie, ophthalmologie, ainsi que la neuro-chirurgie, chirurgie du poumon, stomatologie, chirurgie du cœur et des vaisseaux sanguins, etc.). Les langues des communications sont: le français, l'anglais, l'allemand ou le russe, avec des résumés en d'autres langues que celle de la communication.

La revue *Acta Chirurgica* est un périodique publié en un volume par an — 400 pages environ — réparti en quatre livraisons: à paraître chaque trimestre.

On est prié d'envoyer les manuscrits destinés à la rédaction à l'adresse suivante:

Acta Chirurgica
H-1096 Budapest, Nagyvárad tér 1. István Kórház, Urológia

On peut s'abonner à l'Enterprise du Commerce «Kultura» (H-1389 Budapest 62, P.O.B. 149) ou Extérieur chez représentants à l'étranger.

Журнал Академии Наук Венгрии по медицинским наукам *Acta Chirurgica* публикует научные трактаты из области хирургических дисциплин (общая хирургия, гинекология, урология, ото-рино-ларингология, офтальмологиа, ортопедия, также как и нейрохирургия, легочная хирургия, стоматология, сосудистая хирургия, хирургия сердца и т. д.) на русском, английском, немецком или французском языках, с краткими резюме на языках, отличных от языка данной статьи. Авторами трактатов являются выдающиеся венгерские и зарубежные ученые.

Журнал *Acta Chirurgica* выходит по кварталам выпусками, составляющими один том. Приблизительные для публикации рукописи следует направлять по адресу:

Acta Chirurgica
H-1096 Budapest, Nagyvárad tér 1. István Kórház, Urológia

Заказы принимает предприятие по внешней торговле «Kultura» (H-1389 Budapest 62, P.O.B. 149) или его заграничные представительства и уполномоченные.

Periodicals of the Hungarian Academy of Sciences are obtainable at the following addresses:

AUSTRALIA
C.B.D. LIBRARY AND SUBSCRIPTION SERVICE
Box 4886, G.P.O., *Sydney N.S.W. 2001*
COSMOS BOOKSHOP, 145 Ackland Street
St. Kilda (Melbourne), Victoria 3182

AUSTRIA
GLOBUS, Höchstädtplatz 3, *1206 Wien XX*

BELGIUM
OFFICE INTERNATIONAL DE LIBRAIRIE
30 Avenue Marnix, *1050 Bruxelles*
LIBRAIRIE DU MONDE ENTIER
162 rue du Midi, *1000 Bruxelles*

BULGARIA
HEMUS, Bulvar Ruszki 6, *Sofia*

CANADA
PANNONIA BOOKS, P.O. Box 1017
Postal Station "B", *Toronto, Ontario M5T 2T8*

CHINA
CNPICOR, Periodical Department, P.O. Box 50
Peking

CZECHOSLOVAKIA
MAD'ARSKÁ KULTURA, Národní třída 22
115 66 Praha
PNS DOVOZ TISKU, Vinohradská 46, *Praha 2*
PNS DOVOZ TLAČE, *Bratislava 2*

DENMARK
EJNAR MUNKSGAARD, Norregade 6
1165 Copenhagen K

FEDERAL REPUBLIC OF GERMANY
KUNST UND WISSEN ERICH BIEBER
Postfach 46, *7000 Stuttgart 1*

FINLAND
AKATEEMINEN KIRJAKAUPPA, P.O. Box 128
SF-00101 Helsinki 10

FRANCE
DAWSON-FRANCE S. A., B. P. 40, *91121 Palaiseau*
EUROPÉRIODIQUES S. A., 31 Avenue de Versailles, *78170 La Celle St. Cloud*
OFFICE INTERNATIONAL DE DOCUMENTATION ET LIBRAIRIE, 48 rue Gay-Lussac
75240 Paris Cedex 05

GERMAN DEMOCRATIC REPUBLIC
HAUS DER UNGARISCHEN KULTUR
Karl Liebknecht-Straße 9, *DDR-102 Berlin*
DEUTSCHE POST ZEITUNGSVERTRIEBSAMT
Sraße der Pariser Kommüne 3-4, *DDR-104 Berlin*

GREAT BRITAIN
BLACKWELL'S PERIODICALS DIVISION
Hythe Bridge Street, *Oxford OX1 2ET*
BUMPUS, HALDANE AND MAXWELL LTD.
Cowper Works, *Olney, Bucks MK46 4BN*
COLLET'S HOLDINGS LTD., Denington Estate
Wellingborough, Northants NN8 2QT
WM. DAWSON AND SONS LTD., Cannon House
Folkstone, Kent CT19 5EE
H. K. LEWIS AND CO., 136 Gower Street
London WC1E 6BS

GREECE
KOSTARAKIS BROTHERS INTERNATIONAL BOOKSELLERS, 2 Hippokratous Street, *Athens-143*

HOLLAND
MEULENHOFF-BRUNA B.V., Beulingstraat 2,
Amsterdam
MARTINUS NIJHOFF B.V.
Lange Voorhout 9-11, *Den Haag*
SWETS SUBSCRIPTION SERVICE
347b Heereweg, *Lisse*

INDIA
ALLIED PUBLISHING PRIVATE LTD., 13/14 Asaf Ali Road, *New Delhi 110001*
150 B-6 Mount Road, *Madras 600002*
INTERNATIONAL BOOK HOUSE PVT. LTD.
Madame Cama Road, *Bombay 400039*
THE STATE TRADING CORPORATION OF INDIA LTD., Books Import Division, Chandralok
36 Janpath, *New Delhi 110001*

ITALY
INTERSCIENTIA, Via Mazzé 28, *10149 Torino*
LIBRERIA COMMISSIONARIA SANSONI, Via Lamarmora 45, *50121 Firenze*
SANTO VANASIA, Via M. Macchi 58
20124 Milano
D. E. A., Via Lima 28, *00198 Roma*

JAPAN
KINOKUNIYA BOOK-STORE CO. LTD.
17-7 Shinjuku 3 chome, Shinjuku-ku, *Tokyo 160-91*
MARUZEN COMPANY LTD., Book Department, P.O. Box 5050 Tokyo International, *Tokyo 100-31*
NAUKA LTD. IMPORT DEPARTMENT
2-30-19 Minami Ikebukuro, Toshima-ku, *Tokyo 171*

KOREA
CHULPANMUL, *Phenjan*

NORWAY
TANUM-TIDSKRIFT-SENTRALEN A.S., Karl Johansgatan 41-43, *1000 Oslo*

POLAND
WĘGIERSKI INSTYTUT KULTURY, Marszałkowska 80, *00-517 Warszawa*
CKP I W, ul. Towarowa 28, *00-958 Warszawa*

ROUMANIA
D. E. P., *Bucureşti*
ILEXIM, Calea Grivitei 64-66, *Bucureşti*

SOVIET UNION
SOJUZPECHAT — IMPORT, *Moscow*
and the post offices in each town
MEZHDUNARODNAYA KNIGA, *Moscow G-200*

SPAIN
DIAZ DE SANTOS, Lagasca 95, *Madrid 6*

SWEDEN
ALMQVIST AND WIKSELL, Gamla Brogatan 26
101 20 Stockholm
GUMPERTS UNIVERSITETSBOKHANDEL AB
Box 346, *401 25 Göteborg 1*

SWITZERLAND
KARGER LIBRI AG, Petersgraben 31, *4011 Basel*

USA
EBSCO SUBSCRIPTION SERVICES
P.O. Box 1943, *Birmingham, Alabama 35201*
F. W. FAXON COMPANY, INC.
15 Southwest Park, *Westwood Mass. 02090*
THE MOORE-COTTRELL SUBSCRIPTION AGENCIES, *North Cohocton, N. Y. 14868*
READ-MORE PUBLICATIONS, INC.
140 Cedar Street, *New York, N. Y. 10006*
STECHERT-MACMILLAN, INC.
7250 Westfield Avenue, *Pennsauken N. J. 08110*

YUGOSLAVIA
JUGOSLOVENSKA KNJIGA, Terazije 27, *Beograd*
FORUM, Vojvode Mišića 1, *21000 Novi Sad*

HU ISSN 0001—5431

Index: 26.008

Acta CHIRURGICA

ACADEMIAE SCIENTIARUM HUNGARICAE

8046

EDITORIAL BOARD

BABICS ANTAL (chairman of the board), CSATA SÁNDOR (managing editor), PETRI GÁBOR (president), GLAUBER ANDOR, IHÁSZ MIHÁLY, MÉREI F. TIBOR, PÁSZTOR EMIL, RADNÓT MAGDA, RUBÁNYI PÁL, SURJÁN LÁSZLÓ, SZÉCSÉNY ANDOR, ZOLTÁN IMRE, ZSOLNAI BÉLA

ACTA CHIR. HUNG. TOMUS XXIII • FASCICULUS 2

AKADÉMIAI KIADÓ, BUDAPEST
1982

ACTA CHIRURGICA

ACADEMIAE SCIENTIARUM HUNGARICAE

A MAGYAR TUDOMÁNYOS AKADÉMIA ORVOSTUDOMÁNYI FOLYÓIRATA

FŐSZERKESZTŐ:

Dr. BABICS ANTAL akadémikus

SZERKESZTŐ:

Dr. CSATA SÁNDOR, az orvostudományok kandidátusa

A SZERKESZTŐSÉG CÍME: H-1096 BUDAPEST, NAGYVÁRAD TÉR 1. ISTVÁN KÓRHÁZ, UROLÓGIA
KIADJA AZ AKADÉMIAI KIADÓ, H-1054 BUDAPEST, ALKOTMÁNY U. 21.

Az *Acta Chirurgica* német, angol, francia, ill. orosz nyelven tudományos értekezéseket közöl a sebészet (általános sebészet, nőgyógyászat, urológia, oto-rhino-laryngológia, orthopaedia, szemészet, agy- és idegsebészet, tüdősebészet, szájsebészet, szív- és érsebészet stb.) tárgyköréből.

Az *Acta Chirurgica* évente 1 kötetben jelenik meg, mintegy 400 oldal terjedelemben. A kötet 4, negyedévenként megjelenő füzet formájában kerül kiadásra.

A közlésre szánt kéziratok, valamint a szerkesztőségi levelezés az alábbi címre küldendők:

Acta Chirurgica

H-1096 Budapest, Nagyvárad tér 1. István Kórház, Urológia

Megrendelhető a belföld számára az Akadémiai Kiadónál (1363 Budapest Pf. 24. Bankszámla: 215-11448), a külföld számára pedig a „Kultura" Külkereskedelmi Vállalatnál (1389 Budapest 62, P.O.B. 149. Bankszámla: 218-10990) vagy annak külföldi képviseleteinél és bizományosainál.

Die medizinwissenschaftliche Zeitschrift der Ungarischen Akademie der Wissenschaften *Acta Chirurgica* veröffentlicht Originalbeiträge ungarischer und ausländischer Wissenschaftler aus dem Themenkreis der Chirurgie und der verwandten Gebiete (allgemeine Chirurgie sowie die chirurgischen Beziehungen der Gynäkologie, Urologie, Oto-Rhino-Laryngologie, Orthopädie, Ophthalmologie usw., ferner Neurochirurgie, Gehirnchirurgie, Herz- und Gefäßchirurgie usw.) in deutscher, englischer, französischer oder russischer Sprache, mit kurzen anderssprachigen Zusammenfassungen.

Die *Acta Chirurgica* erscheinen jährlich in einem Band — im Umfang von etwa 400 Seiten — vier in vierteljährlichen Heften.

Die zur Veröffentlichung bestimmten Manuskripte sind an folgende Adresse zu senden:

Acta Chirurgica

H-1096 Budapest, Nagyvárad tér 1. István Kórház, Urológia

Bestellbar bei »Kultura« Außenhandelsunternehmen (H-1389 Budapest 62, P.O.B. 149) oder seinen Auslandsvertretungen.

Acta Chirurgica Academiae Scientiarum Hungaricae, Tomus 23 (2), pp. 61—73 (1982)

Tissue Reaction to Histoacryl Blue Adhesive and Histological Investigation of its Disappearance in Various Organs

E. TARSOLY, GY. BORNEMISZA and I. FURKA

Institute of Experimental Surgery, University Medical School, Debrecen

(Received December 24, 1980)

The effect of the adhesive Histoacryl Blue on the abdominal organs (liver, stomach, intestines, colon, kidneys, bladder, aorta inferior vena cava and skin wounds) of 15 dogs was investigated histologically. The adhesive was applied in thin or thick layers in various ways: applied on intact or injured surfaces, or introduced into the parenchymal organs. The animals were killed 1, 2, 4, 8 weeks and 3 and 6 months after application of the adhesive and the organs containing Histoacryl Blue were processed histologically. The success of adhesion depended, irrespective of the organ, upon the technique of application and on the quantity of the adhesive used.

Experiments on studying the surgical application of adhesives have been in progress for decades, but so far no agreement has been reached as to the applied adhesives and their effects.

Various materials have been tried with different results. These included gelatin-resorcinol-formaldehyde (GRF) which, although considered an elastic and biologically satisfactory adhesive [21], its tissue fixing effect has been found inferior by some authors [13]. Others have, however, achieved excellent results with GRF and report even now about its successful application [30, 31].

The cyanoacrylate derivatives have opened a new era in the use of tissue adhesives [16, 26, 28]. Experiments were carried out first with methyl-2--cyanoacrylate, but the results were unfavourable due to the developing heat and the harmful effect on the tissue [11, 19, 26, 27, 28]. Today, of the cyanoacrylates the butyl derivative seems to be the most suitable. It has no harmful effect on the tissues and has been applied successfully on various organs and tissues [3, 4, 5, 6, 7, 8, 9, 10, 14, 17, 19, 24, 26]. In addition, the compound has a bactericidal and haemostatic effect [1, 10, 29]. Still, the currently used adhesives are not absolutely histophilic [12], and necrosis [32], lithogenesis [33] and, depending on the organ, various harmful reactions due probably to the toxicity of the cyan-group [22, 23] have been reported with butyl cyanoacrylate and, therefore, several authors give preference to suturing [2, 18].

There are considerable discrepancies between the published results which refer mainly to the suitability of the adhesive from the surgeon's point

of view. With the exception of a few cases, the histological tests, too, have attempted to support the surgical results and no convincing conclusions could be drawn from the published pictures.

The aim of the present study was therefore to clarify (*i*) the cause of the differences between the results obtained with one and the same adhesive; (*ii*) the kind of lesion caused by n-butyl-cyanoacrylate in the various organs and the way these lesions change with time; and (*iii*) the fate of the adhesive in the organism.

Material and Method

After opening the abdominal cavity of 15 dogs, Histoacryl Blue (B. Braun A. G. Melsungen) adhesive was applied to the liver, stomach, intestine, colon, kidneys, bladder, aorta, inferior vena cava and to skin wounds. Depending on the actual experiment, the adhesive was applied in different ways.

I. The adhesive was applied to the surface of the organs on the intact serosa or adventitia in the form of (*i*) a thin layer; (*ii*) a thick drop.

II. The serosa and subserosa, or the capsule of viscera was injured and the adhesive was applied in (*i*) a thin layer; (*ii*) in greater quantity.

III. Intestinal loops were made to adhere to one another, or the omentum was stuck to the surface of the parenchymal organs, the stomach, the bladder and, of the large vessels, with (*i*) a thin layer of adhesive, (*ii*) with a thick layer of adhesive.

IV. Incisions were made on the liver and kidneys and (*i*) small quantities or (*ii*) large quantities of the adhesive were introduced into the parenchyma.

The animals were killed 1, 2 and 4 weeks and 2, 3 and 6 months after the experiment. The organs were removed, fixed in formaldehyde and sections 8 to 10 μm thick were stained with Oil Red 0 [25, 27].

Results

In the animals killed after one week, mild inflammation was observed around the adhesive applied to the surface of organs. The inflammation was independent of the applied quantity of adhesive. A slight round-cell infiltration was visible in the adventitia of the large vessels, accompanied by vigorous growth of the granulation tissue which surrounded like a capsule the adhesive and started to break up the latter by penetrating into it at several points (Fig. 1*a*).

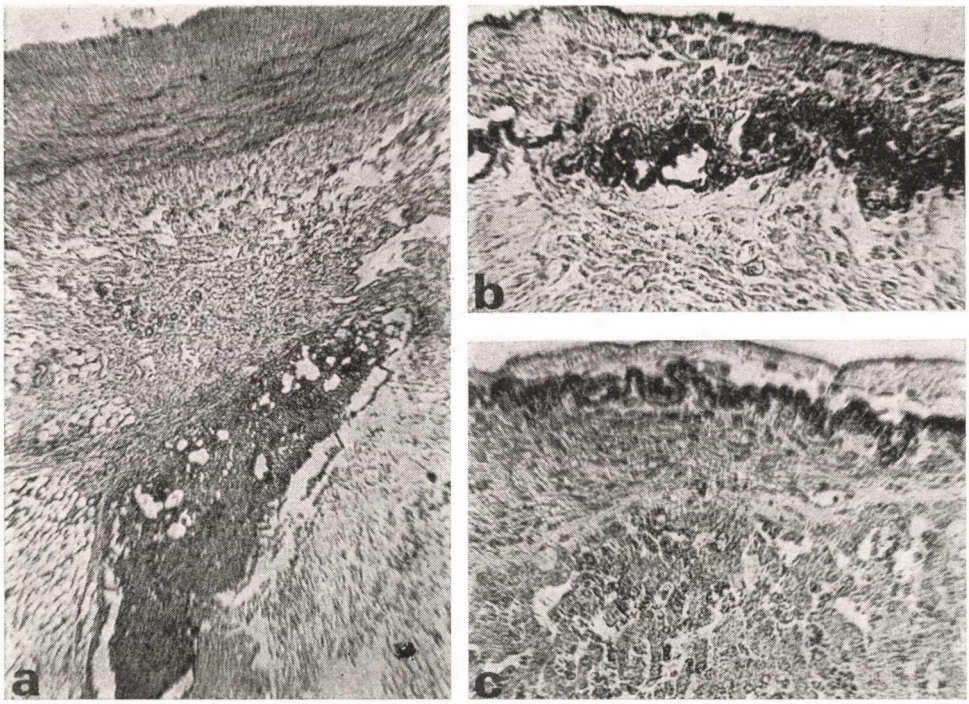

FIG. 1*a*. The large quantity of adhesive placed on the adventitia of the aorta is surrounded after one week by a capsule of granulation tissue which, in some places, has penetrated the adhesive (×10); *b*. Around the thin layer of adhesive applied to the surface of the intestine a mild inflammatory infiltration is seen and granulation tissue covered by mesothelium surrounds the adhesive after one week (×60); *c*. The thin layer of adhesive applied to the surface of the liver is surrounded by granulation tissue and a mild cellular infiltration appears after one week (×60)

A similar picture was obtained on the surface of the bowels; the granulation tissue surrounded the adhesive completely and was even coated by mesothelium (Fig. 1*b*). On the surface of the parenchymal organs, slight round-cell infiltration and a capsule of granulation tissue was seen surrounding the adhesive (Fig. 1*c*).

Around the adhesive introduced into the hepatic and renal parenchyma, independently of the quantity of adhesive, the cellular infiltration was insignificant but somewhat more marked than in the connective tissue. Instead, vigorous granulation tissue growth dominated, forming a capsule around the adhesive and separating the latter from the intact tissue.

The quantities of adhesive applied to the muscle layer after injury to the surface of the stomach, bowels, bladder and large vessels, caused in their surroundings an intense inflammatory reaction. The round-cell infiltration was marked, and here, too, a vigorous growth of granulation tissue was con-

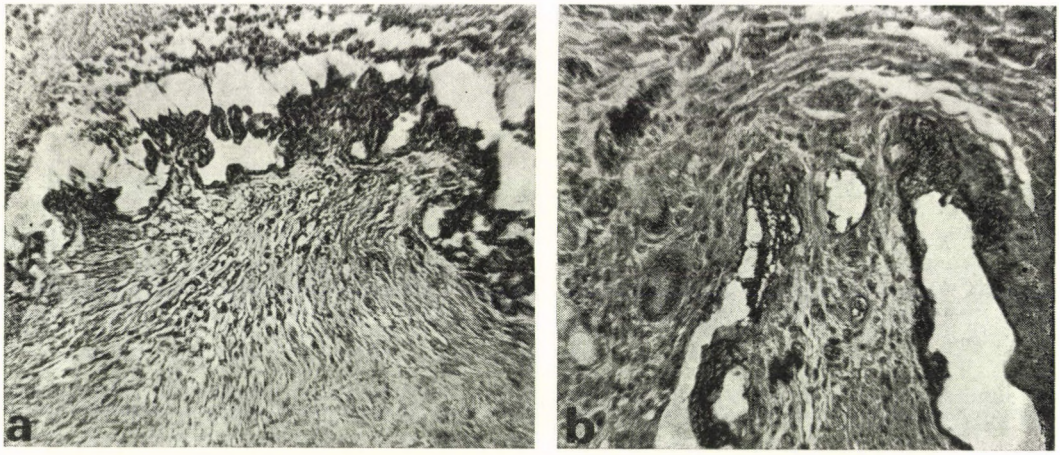

FIG. 2*a*. Injured serosa of the colon. After one week, around the adhesive applied to the muscular layer, round-cell infiltration and granulation proliferation surrounding and breaking up the adhesive can be observed (×60); *b*. Around the adhesive on the muscular layer of the intestine, giant cells appear after two weeks (×80)

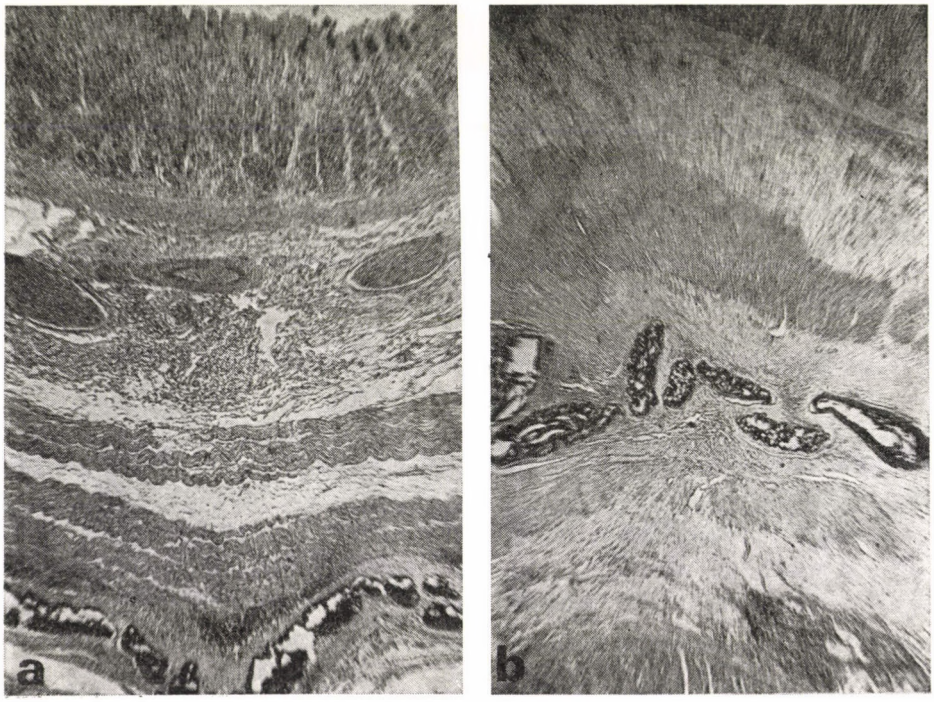

FIG. 3*a*. The omentum fixed by a thin layer of adhesive to the surface of the stomach adheres perfectly after two weeks when the adhesive is already broken up by granulation tissue (×10); *b*. After two weeks the two parts of the colon which had been united by means of a small quantity of adhesive have completely grown together; the adhesive has been broken up by connective tissue (×10)

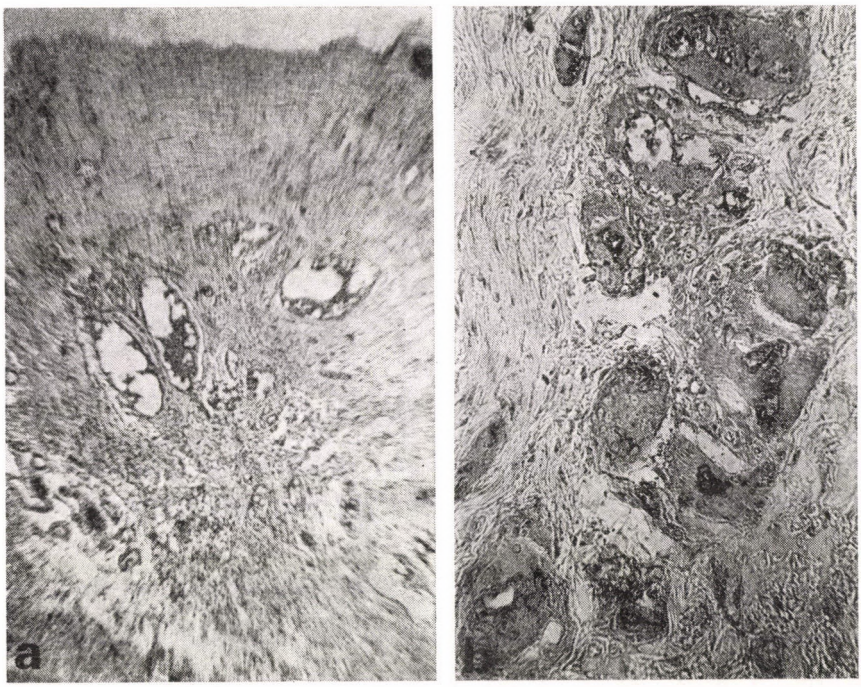

FIG. 4*a*. The skin incision has completely healed in four weeks, but the adhesive which had penetrated the corium and the subcutis is still visible in the form of small islets (×10); *b*. In the deeper layers of the skin shown in *a*, masses of giant cells are situated around the adhesive. In the giant cells phagocytosed parts of adhesive are visible (×60)

spicuous. The granulation tissue surrounded the adhesive like a capsule starting to break it up (Fig. 2*a*).

The skin wound healed within a week. The adhesive applied to the surface appeared only in traces, had not penetrated deeper and was visible mainly in the peeling horny layer.

By the second week the adhesive applied in small quantities had everywhere been broken up and interlaced by the richly vascularized, cell-rich connective tissue, so that the united surfaces were fixed by the latter (Figs 3*a* and *b*).

The mass of adhesive applied in a thick layer was also surrounded by a richly vascularized, cell-rich capsule of connective tissue which, however, could penetrate only the edges of the adhesive layer so that union was not perfect. The appearance of polynuclear giant cells on the surfaces of every organ under investigation could be observed for the first time in the material gained on animals which were killed after two weeks (Fig. 2*b*).

By the fourth week, the quantity of adhesive had considerably decreased in every organ. At this stage a large number of polynuclear giant cells characterized the histological pattern.

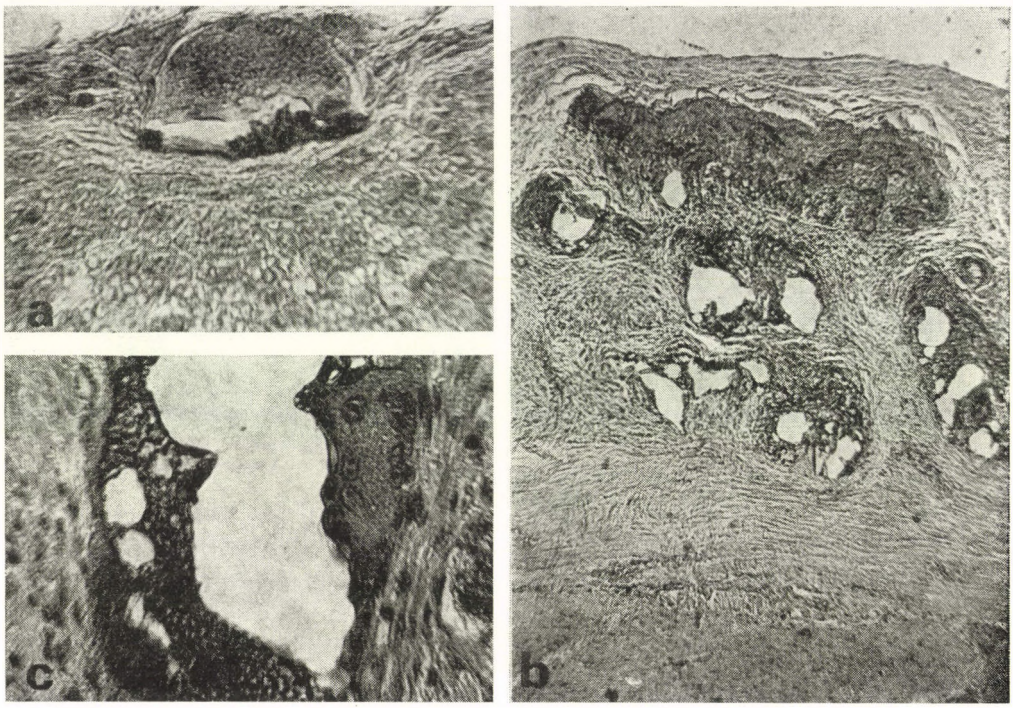

FIG. 5*a*. The residual adhesive in the liver parenchyma is surrounded, after eight weeks, by a thin capsule of connective tissue and giant cells are seen on its surface (×120); *b*. The omentum fixed to the surface of the stomach adheres well by the eighth week, the excess adhesive has been broken up by connective tissue rich in cells (×30); *c*. After eight weeks giant cells are situated on the surface of the adhesive islets formed when the stomach wound has been united and covered with omentum (*b*) (×120)

There was a simultaneous increase in connective tissues between the islets formed by the adhesive. In the parenchymal organs, beside the thin connective tissue capsule surrounding the adhesive, the cells of the organs were completely intact. In the wall of the large vessels and of the viscera the connective tissue reaction extended only as far as the muscle layer without penetrating the latter. Where the adhesive had penetrated into the muscular tissue, it became encapsulated and destroyed by the giant cells of the granulating tissue, before a further penetration into greater depth. The large number and the role of the giant cells are seen in Figs 4*a* and *b* which illustrate the union of a skin wound when the adhesive has been applied in large quantities and has penetrated the corium and even the subcutis. The wound healed, became epithelized without any complication, but the adhesive islets deep down were still detectable and in the giant cells the incorporated adhesive was still clearly visible.

On the eighth week the adhesive could still be detected in every organ. In the parenchymal organs giant cells were visible on the encapsulated rem-

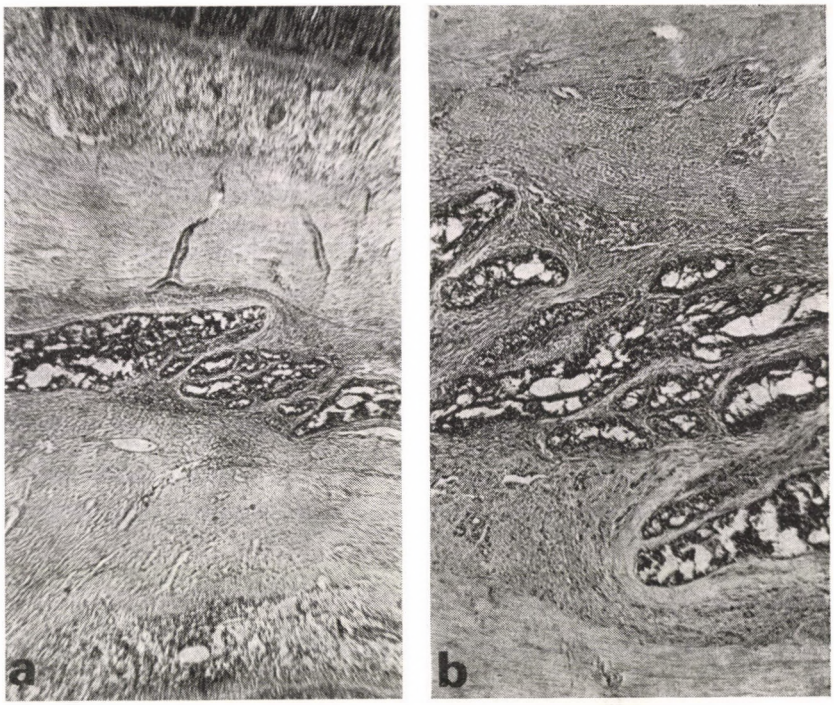

FIG. 6*a*. The intestinal loops united by means of a large quantity of adhesive have grown together in eight weeks and the adhesive has been broken up (×10); *b*. The united intestinal loops shown in *a* are joined by cell-rich connective tissue bridges. Breaking up of the adhesive islets is clearly seen (×30)

nants of the adhesive (Fig. 5*a*). The large drops of adhesive applied to the surface of the organs were surrounded by a connective tissue capsule. The omentum had become completely united with the organ where the adhesive had been applied, but remnants of adhesive applied in excess still formed islets on which giant cells appeared (Figs 5*b* and *c*).

The intestinal loops united by the adhesive were fixed by a network of connective tissue, in the spaces of which the remnants of the adhesive applied in a thick layer with giant cells on its surface were visible (Figs 6*a*, *b*).

Three months after the operation only small spots of adhesive applied in a small quantity were visible and the adhesive was replaced by connective tissue. A considerable part of the adhesive which had been applied in a thick layer was still present surrounded by a connective tissue capsule. Decomposition of the residual adhesive islets was in progress, as proved by the presence of a number of giant cells.

By six months small quantities of the adhesive have produced a perfect union. The intestines and the organs covered with omentum were joined by

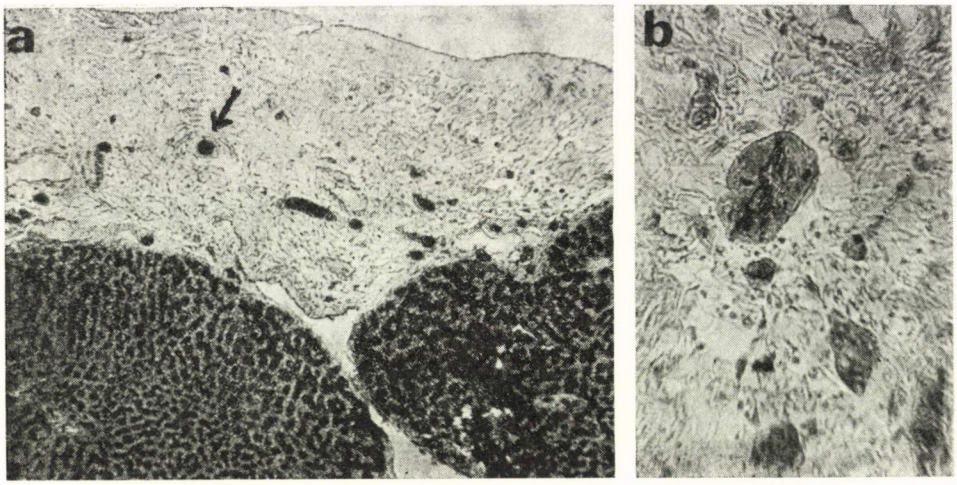

FIG. 7*a*. Union of the hepatic lobes covered by omentum and adhesive is complete at six months. At low magnification no adhesive is visible anywhere (×10); *b*. In the giant cell marked by an arrow in *a* can only some residue of adhesive be detected (×80)

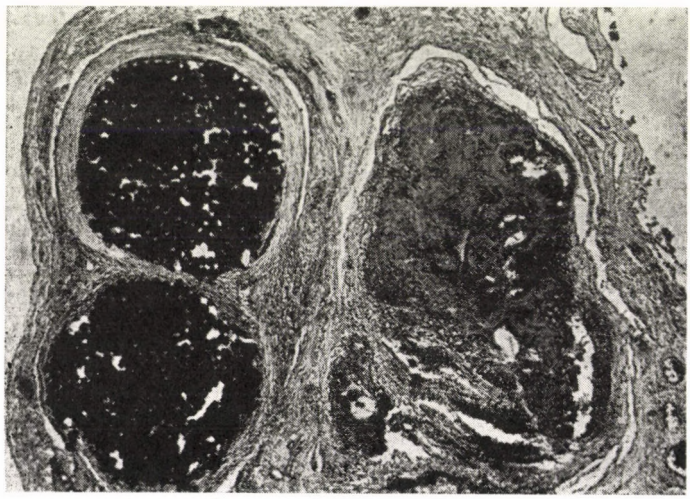

FIG. 8. Tissue reaction induced by Black Braided Silk suturing material and by Histoacryl Blue tissue adhesive, respectively, in the wall of the bladder after eight months (×20)

connective tissue. Only small spots of the adhesive or giant cells on its surface were visible (Figs 7*a* and *b*).

A thick layer of connective tissue or one or two adhesive-containing giant cells on the surface of organs indicated the site where the adhesive had been applied. The same was the case in the parenchymal organs. Where the adhesive had been applied in large quantities, it was still there, surrounded

by a connective tissue capsule, and being slowly broken up. Polynuclear giant cells were present in large numbers. When the tissue reaction induced by Histoacryl Blue is compared to that of Black Braided Silk suturing material used as an indicator (Fig. 8), it appears that, while the suture is surrounded by a bulky impenetrable connective tissue capsule, the capsule around the adhesive is looser and the connective tissue breaks up the adhesive by penetrating into it, thus promoting its removal and decay.

Discussion

The answer to the question of differences between the results obtained with one and the same adhesive, is that the efficiency of adhesion produced by Histoacryl Blue will depend on the technique of application and on the applied quantity.

Efficiency being inversely proportional to the applied quantity of adhesive, as little as possible should be used.

The united tissue was seen to influence only the initial stage in the first week of the reaction. The later course of the process and the efficiency of adhesion showed no significant histological differences. Everywhere in the organs an early proliferative reaction and connective tissue development around the adhesive was seen. Despite vigorous fibrinogenesis, large quantities of the adhesive hinder the perfect union of the surfaces.

As to the histological lesions caused by the adhesive, Histoacryl Blue, independently of the quantity used, caused no necrosis in any of the organs. This contradicted the findings of Lemperle et al. [21], Hartung and Staub [18], and of Weissenhofer and Passel [32]. Undoubtedly, the various types of tissues behaved in different ways towards the adhesive, but only in the first week was this difference noticeable and even then only in the form of inflammatory symptoms.

The inflammatory reaction was mildest in the connective tissue and so was the round-cell infiltration in the parenchymal organs. The inflammatory reaction was the most marked but still not intensive around the adhesive in muscle tissue. By the second week the difference in intensity of the reaction was no longer conspicuous. In all tissues and organs extensive granulation and proliferative processes dominated. The richly vascularized granulation tissue had formed a capsule around the adhesive breaking it up. The connective tissue capsule protected the surrounding cells against all eventual harmful effects.

In contrast to Endler's observation [15], fibrogenesis started in the first and second weeks. The adhesive was surrounded by a fibrous connective tissue capsule and the breaking up had already started. Weissenhofer and Passel [32]

found that the giant cells began to appear in the 4th week, while we could find polynuclear giant cells as early as in the second week. In contrast to Zinner et al. [33], no lithogenesis was apparent in the kidneys or other organs.

The histological changes more or less agreed with the descriptions of Ota et al. [26] and of Häring and Grohme [19].

The fate of the adhesive in the organism could be followed only partly. The rapidly proliferating granulation tissue broke up the pieces of adhesive and surrounded them like a capsule. After the second week the polynuclear giant cells appearing on the adhesive islets incorporated the pieces of adhesive till they had completely disappeared. This process was the most marked between the fourth and eighth weeks, when the number of giant cells was the greatest. It was not possible to detect histologically the fate of the adhesive incorporated by the giant cells and of the giant cells themselves.

The histological processes taking place during the closure of skin wounds have to be mentioned separately, because the majority of authors reported on good results with Histoacryl Blue [18, 19, 20]. According to our experience, the wound under the thin layer of adhesive healed within a week. If, however, the adhesive had been applied in a thick layer, which then penetrated into the dermis and the subcutis, though epithelization was complete in one week, adhesive islets and adhesive containing giant cells were visible in the deeper layers even after three months, indicating a delayed union of these layers.

Thus, Histoacryl Blue was found to be suitable for the union of tissues of the abdominal organs. The efficiency of the method depends upon the technique and the applied quantity of adhesive. The adhesive stimulates fibroplastic proliferation and consequent healing, and the organism decomposes the adhesive by means of polynuclear giant cells.

References

1. Awe WC, Robberts W, Braunwald NS: Rapidly polymerizing adhesive as a hemostatic agent: Study of tissue response and bacteriological properties. Surgery 54: 322, 1963
2. Berger A, Millesi H: Verwendung von Klebestoffen zum Verschluss von Hautwunden und zur Vereinigung durchtrennter peripherer Nerven. In: Kunststoffe in der Chirurgie, ed. Gottlob R. Verlag der Wiener Medizinischen Akademie, Wien 1970, p. 173
3. Blümel G, Gottlob R: Histologische Untersuchungen an mit Alkylcyanoakrylaten behandelten Gefässen. In: Adhesives in Surgery, ed. Gottlob R. Verlag der Wiener Medizinischen Akademie, Wien 1968, p. 181
4. Bornemisza Gy, Gyurkó Gy: Über die experimentelle Verwendung gewebsfreundlicher Klebestoffe. Zentralbl Chir 94: 258, 1969
5. Bornemisza Gy, Furka I: Restoration of the divided ductus deferens by adhesive material. Acta Chir Acad Sci Hung 11: 335, 1970
6. Bornemisza Gy, Gyurkó Gy: Experimental straightening of tendons by adhesive fixation. Acta Chir Acad Sci Hung 11:197, 1970
7. Bornemisza Gy, Czehelnik R: Closure of experimental hepatic wounds with adhesive and absorbable cellulose. Acta Chir Acad Sci Hung 13: 413, 1972

8. Bornemisza Gy, Furka I: End-to-end anastomosis of choledochal stumps by vessel suturing apparatus and adhesives. Acta Chir Acad Sci Hung 13: 303, 1972
9. Bornemisza Gy, Gyurkó Gy, Czehelnik R: Tracheal union by adhesive. Acta Chir Acad Sci Hung 14: 299, 1973
10. Bornemisza Gy, Furkó I, Mikó I: Treatment of gastric, intestinal and hepatic injuries with collagen and adhesive. Acta Chir Acad Sci Hung 16: 145, 1975
11. Chalupnik J, Hejda N, Dobias J: Zur Frage der biologischen Toleranz synthetischer Klebestoffe. In: Adhesives in Surgery, ed. Gottlob R. Verlag der Wiener Medizinischen Akademie, Wien 1968, p. 39
12. Chalupnik J, Buda J: Unsere Erfahrungen bei der Anwendung von Klebestoffen in der Gefäss- und Knochenchirurgie. In: Kunststoffe in der Chirurgie, ed. Gottlob R. Verlag der Wiener Medizinischen Akademie, Wien 1970, p. 145
13. Cooper CW, Grode GA, Falb RD: Surgical adhesives. In: Adhesives in Surgery, ed. Gottlob R. Verlag der Wiener Medizinischen Akademie, Wien 1968, p. 15
14. Domanig E jr, Eichelter P, Medricky O, Wagner O: Über die Verwendung von Gewebeklebern in der Herzchirurgie. In: Kunststoffe in der Chirurgie, ed. Gottlob R. Verlag der Wiener Medizinischen Akademie, Wien 1970, p. 139
15. Endler F: Der nahtlose Hautverschluss bei orthopädischen Operationen. In: Kunststoffe in der Chirurgie, Verlag der Wiener Medizinischen Akademie, Wien 1970, p. 187
16. Gottlob R, Blümel G, Pigisch E: Erfahrungen mit der Klebstoffanastomose und vergleichende Untersuchungen über die Toxizität eines GRF-Klebers und eines Cyanoacrylates. In: Kunststoffe in der Chirurgie, ed. Gottlob R. Verlag der Wiener Medizinischen Akademie, Wien 1970, p. 149
17. Gyurkó Gy, Bornemisza Gy, Furka I, Czehelnik R: Experience with tissue adhesives in 500 experimental vascular junctions. Am Surg 40: 210, 1974
18. Hartung H, Staub I: Vergleichende tierexperimentelle Untersuchungen über Wundheilung nach Anwendung von 2-Cyano-Acrylsäure-n-Butylester und Naht an verschiedenen Organen. In: Adhesives in Surgery, ed. Gottlob R. Verlag der Wiener Medizinischen Akademie, Wien 1968, p. 59
19. Häring R, Grohme S: Tierexperimentelle Untersuchungen zur Verwendung von Klebstoff an der Trachea. In: Adhesives in Surgery, ed. Gottlob R. Verlag der Wiener Medizinischen Akademie, Wien 1968, p. 81
20. Heiss W: Gewebeklebstoffe: Applikationen, Eigenschaften und Anwendungsmöglichkeiten. *Melsunger Med Mitt* 42:11 (1968).
21. Lemperle G, Köhnlein HE, Lindenmaier HL: Tierexperimentelle Untersuchungen mit einem neuen Gelatine-Resorzin-Formaldehyd-Klebstoff. In: Adhesives in Surgery, ed. Gottlob R. Verlag der Wiener Medizinischen Akademie, Wien 1968, p. 21
22. Lewers DT, Just Viera JO, Jeager OH: Lethal properties of a rapidly polymerising adhesive. Arch Surg 87: 4, 1963
23. Lick RF, Brückner W, Beck O: Histomorphologische Untersuchungen zur Heilung von geklebten Wunden im Tierexperiment. I. Die frühen Phasen der Wundheilung. Langenbecks Arch Chir 315:163, 1966
24. Matsumoto T, Hardaway RM, Pani KC, Leonard F, Heisterkamp CA, Margetis PM: Intestinal anastomosis with n-butyl-cyanoacrylate tissue adhesive. Surgery 61: 567, 1967
25. Mikó I: Histologic demonstrability of surgical adhesives. Polim Med 9: 39, 1979
26. Ota K, Mizuno K, Ueno A, Inou T: Basic studies on the cyanoacrylate adhesives. In: Adhesives in Surgery, ed. Gottlob R. Verlag der Wiener Medizinischen Akademie, Wien 1968, p. 33
27. Pani KC: Methods of localization of the implanted homologue series of alpha-cyanoacrylates in tissue sections. In: Adhesives in Surgery, ed. Gottlob R. Verlag der Wiener Medizinischen Akademie, Wien 1968, p. 29
28. Rickling J: Klebstoffe in der Chirurgie. In: Adhesives in Surgery, ed. Gottlob R. Verlag der Wiener Medizinischen Akademie, Wien 1968, p. 7
29. Uhlig R, Gitt HA, Wildführ W: Experimentelle Untersuchungen zur antimikrobiellen Wirkung von einigen Butylzyanoakrylatgewebeklebern. Z Exp Chir 11: 27, 1978
30. Vándor E, Jancsár L, Mozsáry P, Réffy A, Demel Zs: Experiences about the application of gelatin-resorcinol-formaldehyde tissue adhesive in experimental ruptured liver injury. Z Exp Chir 13: 52, 1980

31. Vándor E, Mozsáry P, Réffy A: A critical study of the preparation and application of gelatin-resorcinol tissue adhesive cross-linked by formaldehyde. Z Exp Chir 13: 43, 1980
32. Weissenhofer W, Passel R: Experimentelle Untersuchungen über die Reaktionen der Herzmuskeln auf die Applikation von Histoacryl. In: Kunststoffe in der Chirurgie, ed. Gottlob R. Verlag der Wiener Medizinischen Akademie, Wien 1970, p. 143
33. Zinner G, Streimel G, Gottlob R: Nierenparenchymveränderungen und Steinbildung beim Kaninchen nach Applikation verschiedener Klebstoffe zur Versorgung von Polresektionen. In: Adhesives in Surgery, ed. Gottlob R. Verlag der Wiener Medizinischen Akademie, Wien 1968, p. 241

Histologische Untersuchung der durch den Klebstoff Histoacryl-Blau ausgelösten Gewebereaktion und des Verschwindens des Klebstoffs in vershiedenen Organen

E. Tarsoly, Gy. Bornemisza, I. Furka

Die Wirkung des Klebstoffs Histoacryl-Blau wurde in den abdominalen Organen — Leber, Magen, Dünndarm, Dickdarm, Niere, Harnblase, Aorta, V. cava inferior und Hautwunde — von 15 Hunden histologisch untersucht. Der Klebstoff wurde in dünner bzw. dicker Schicht unterschiedlich angewandt: auf intakte oder lädierte Fläche aufgetragen, in das Innere von parenchymatösen Organen eingeführt bzw. zum Kleben. Die Tiere wurden nach 1, 2, 4, 8 Wochen und 3, 6 Monaten abgetötet und die Klebstoff enthaltende Organteile histologisch aufgearbeitet. Die Untersuchungen führten zu folgenden Feststellungen:

1. Der Erfolg des Klebens ist bei sämtlichen Organen die Funktion der Klebetechnik und der Menge des verwendeten Klebstoffs.

2. Durch den Klebstoff werden in den ersten Tagen milde entzündliche Erscheinungen kleingradiger zellulärer Infiltration herbeigeführt, wonach in kurzer Zeit kräftige Proliferationsreaktion auftritt. Durch das bildende Granulationsgewebe wird der Klebstoff kapselartig umgeben, umsponnen und zerstückelt. Nekrose war in keinen der untersuchten Organe zu beobachten.

3. Auf der Oberfläche des Klebstoffs erscheinen bereits in der zweiten Woche polynukleäre Riesenzellen, die die Klebstoffpartikel inkorporieren und den Klebstoff, von seiner Menge abhängig, früher oder später entfernen. Die Stelle des Klebstoffs nimmt ein zellreiches Bindegewebe ein. In Fällen, in denen große Klebstoffmengen verwendet wurden, spielt sich der beschriebene Prozeß nur nach langer Zeit ab, da durch die dicke Klebstoffschicht das Einwachsen des Granulationsgewebes, das Verwachsen der Organe und folglich auch die Heilung verzögert werden.

Тканевая реакция, вызванная применением клея (Histoacryl blue), и гистологическое исследование исчезновения клеящего вещества в различных органах

Э. ТАРШОЙ, ДЬ. БОРНЕМИСА и И. ФУРКА

Мы изучали действие тканевого клея *Histoacryl blue* на брюшные органы. У 15 собак были гистологически изучены следующие органы: печень, желудок, тонкая и толстая кишки, почка, мочевой пузырь, аорта, нижняя полая вена, а также ткань кожной раны. Тонкий или толстый слой клея мы применяли по-разному: помещали на интактную поверхность, на поврежденную поверхность, на внутреннюю поверхность паренхиматозных органов. Животных забивали в следующие сроки после применения клея: через 1, 2, 4 и 8 недель и 3 и 6 месяцев. Участки органов, содержащие клей, обрабатывали гистологически. Были получены следующие результаты:

1. Эффективность склеивания в каждом отдельном случае зависит от техники склеивания и количества примененного клея.

2. В первые дни клей вызывает слабые воспалительные явления с небольшой клеточной инфильтрацией, после чего во всех органах быстро развивается сильная реакция пролиферации. Образующаяся грануляционная ткань обволакивает это место как футляром, затем пронизывает и раздробляет клеевое вещество. Некроза не наблюдали ни в одном случае.

3. На поверхности клея, уже на второй неделе, появились многоядерные гигантские клетки, которые фагоцитируют частички клея и, в зависимости от массы клеющего вещества, раньше или позже удаляют его. Место клея занимает богатая клетками соединительная ткань. Этот процесс, в случае применения больших количеств клея, наступает довольно поздно, поскольку толстый слой клея задерживает врастание грануляционной ткани, срастание органов и выздоровление.

Dr. Emil Tarsoly
Dr. György Bornemisza
Dr. István Furka

Institute of Experimental Surgery,
University Medical School,
Debrecen, Pf. 12, H-4012

Acta Chirurgica Academiae Scientiarum Hungaricae, Tomus 23 (2), pp. 75—81 (1982)

Thermography in Artificially Induced Coronary Circulatory Disorders

L. PAPP,[1] B. MEZEI,[2] B. OSVÁTH[3] and Z. SZABÓ[1]

Department of Vascular and Heart Surgery, Semmelweis University Medical School Budapest[1]; Department of Intensive Therapy and Anaesthesiology, University Medical School, Pécs[2] and Instrumental and Metrotechnological Service of the Hungarian Academy of Sciences, Budapest[3]

(Received March 16, 1981)

In the open chest the heart loses more heat and its epicardiac temperature will fundamentally depend upon the temperature of the body and its environment, upon the flow in the coronaries and upon the actual state of myocardial metabolism.

The experiments were carried out with the AGA Thermovision Type 750 equipment. The epicardial temperature changes induced by reactive hyperaemia due to the temporary coronary ligation in 24 dogs, and by permanent coronary ligation in 70 dogs, as well as by the gradually reduced coronary flow of another 8 dogs were recorded by means of thermography. The results indicated a relationship between the changes in epicardial flow and epicardial temperature, consequently thermography is considered a method suitable for the study of myocardial flow.

Thermography, the depiction of temperature, is an accepted and widely applied method for examining the body surface (breast tumours, vascular diseases, arthritides, etc.) [1, 2, 3, 4, 7, 15]. Still, few papers have reported on thermographic tests performed on organs exposed in the course of surgical interventions.

The first thermographic tests of the heart were carried out by Seny et al. [13] in open dogs. They found that the area of the infarction was colder than its environment [13]. Later, Malm et al. studied the effect of breathing 100% oxygen and of air on the ischaemic heart and the coronary dilation induced by nitroglycerin and dipyridamole in acute myocardial infarction [8, 9]. According to the thermographic observations of Daniel et al., regional hypothermia induced by a reduction of the local coronary flow in the open chest dogs promoted the disturbance of impulse conduction [5]. On the basis of their experience in human heart operations and animal experiments the same authors suggested the use of thermography as a valuable method for recording the regional myocardial flow [6].

Robicsek et al. reported on similar observations. They showed that when cold blood or physiological saline is introduced into the coronary branch this will appear as a cold branched system of channels on the thermogram [11, 12]. Tzivoni et al. found a close resemblance between the thermographic

picture of myocardial infarction and the simultaneously recorded epicardial ECG map [14].

In the present investigations we have attempted to determine the thermographically measured epicardial temperature in artificially induced disturbances of the coronary circulation and studied the relationship of the changes in temperature and the degree of the coronary circulatory disorder.

Material and Method

Thermographic tests were performed on 78 mongrel dogs of both sexes with body weights varying between 8 and 35 kg, at 23–24 °C room temperature and 50–60% relative humidity, in an environment free of air currents. The animals were anaesthetized with 30 mg/kg of pentobarbital, intubated intratracheally and operated upon under artificial breathing.

On a continuously heated operating table the body temperature of the animals was maintained at 37 °C±0.5 °C. Complete transversal thoracotomy was performed in the IVth intracostal space, the pericardium was opened longitudinally and fixed to the chest. For the induction of ischaemia the anterior descending branch of the left coronary was ligated after the first or second branching.

In the experiments arterial blood pressure was continuously measured by a cannula led into the femoral artery. In some experiments left ventricular pressure was measured by a cannula introduced into the apex of the the left ventricle. Pulsatory and mean flow were determined in the anterior descending branch of the left coronary and in the ascending aorta, with a Godard–Statham electromagnetic flowmeter. The above parameters as well as the electronically produced dp/dt value of the left ventricle were recorded by Hellige 6400/6 multiscriptor.

The pictures were taken by the AGA Thermovision Type 750 which senses the infrared rays in the 2 to 5.6 μm wavelength range. The objective made of germanium or silicium projects these rays by means of a prism rotating around a horizontal and a vertical axis on an indium-antimonide detector. The crystal cooled with liquid nitrogen to −196 °C converts the infrared rays into electric signals and transmits them to the monitoring unit of a device working on the principle of a closed television chain. At any moment the colour-monitor depicts within the limits of the range of measurement ten temperature values of different colours from the surface under investigation [10].

With the help of a reference heat source the temperature pertaining to a given colour can be determined and the other colours are obtained by comparison to this colour. Between −20 °C and + 900 °C, when the temperature of the object is +30 °C, the smallest temperature which can still be sensed is 0.2 °C.

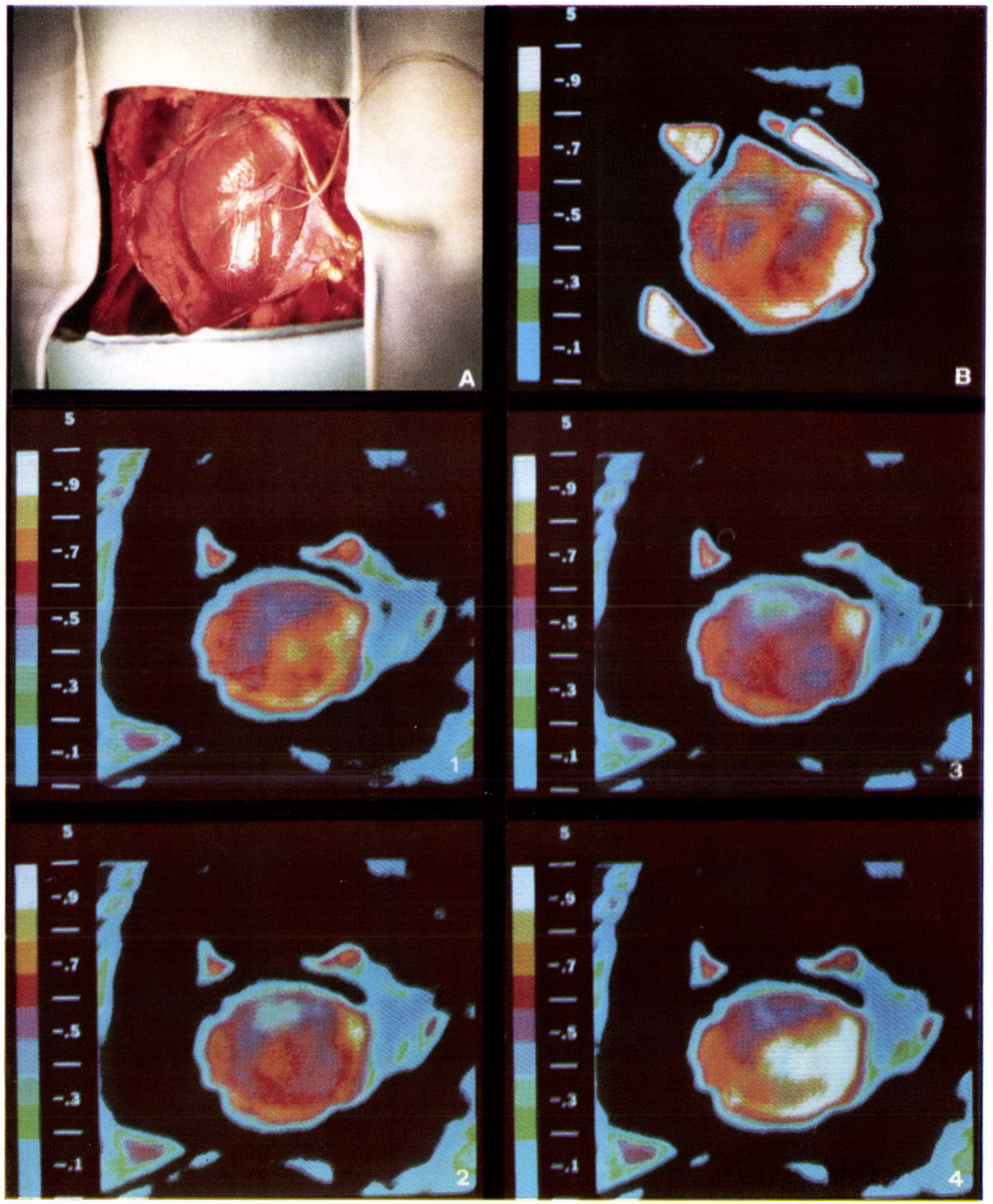

PLATE I. *a*. Dog heart in the open pericardium. A loop of thread below the anterior descending branch of the coronary. Next to it the thermogram of the same heart. *b*. Demonstration of reactive hyperaemia by means of thermography. 1. The coronary before ligation. 2. The coronary 30 s after ligation. 3. The coronary 3 min after ligation. 4. The coronary 2 min after removal of the ligature

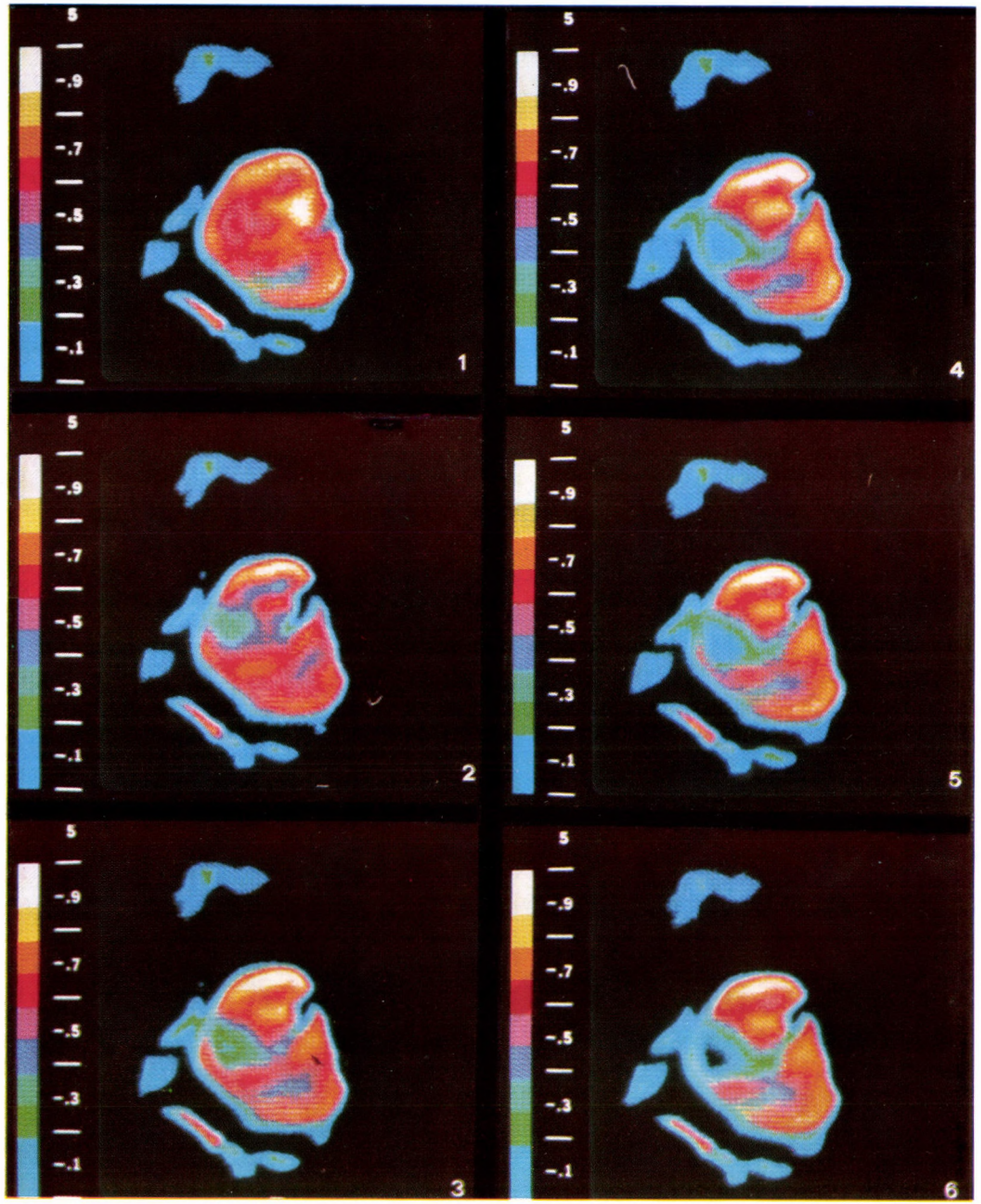

PLATE II. Thermographic changes following coronary ligation vs. time. Thermograms recorded 1, 5, 10, 15, 20 and 30 min after coronary ligation (1–6)

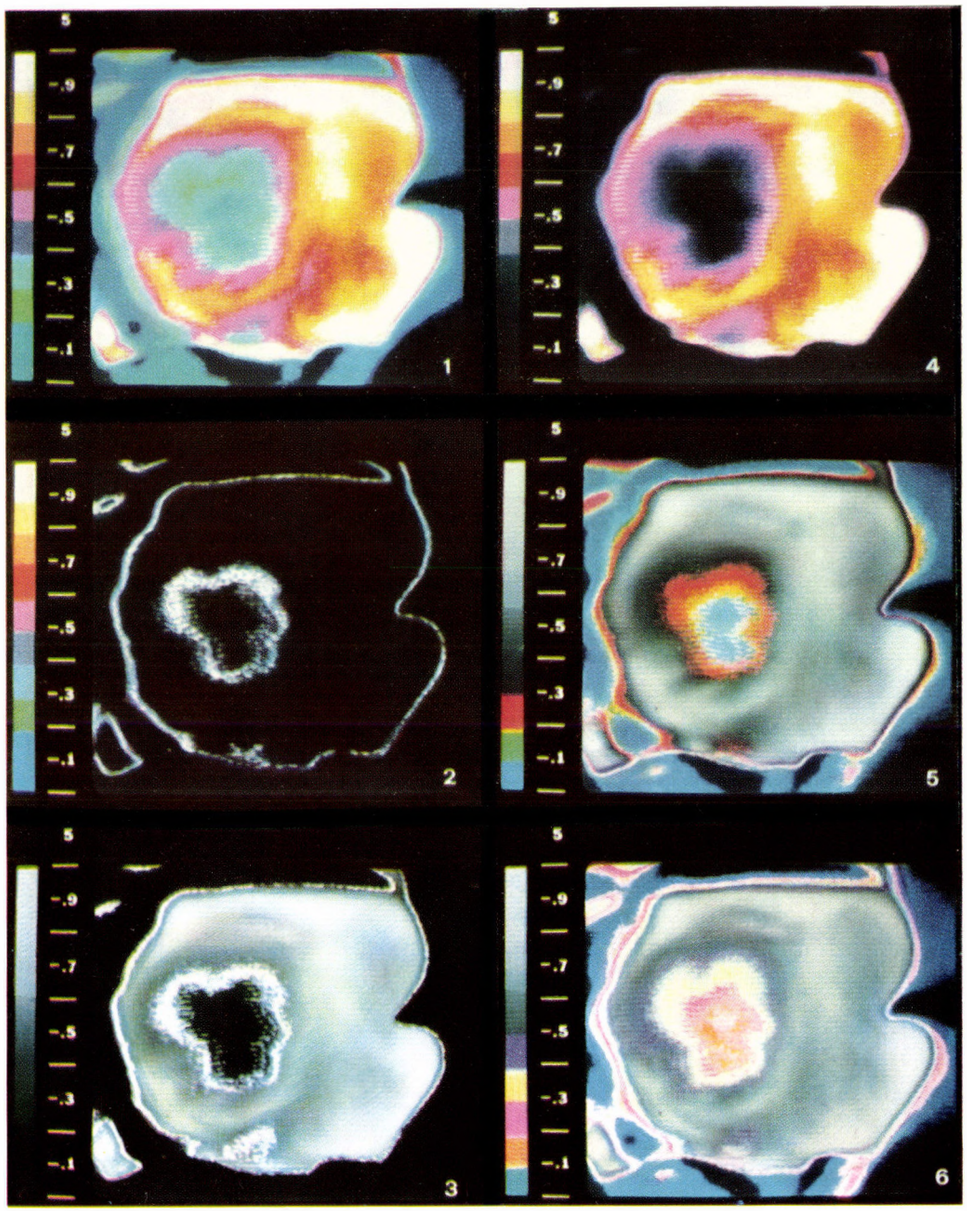

PLATE III. Illustration of the ischaemic area by highlighting the isotherms. 1. Colour picture of the heat distribution ('normal' thermographic picture). (2–6) Highlighting the isotherms, colour and black and white pictures

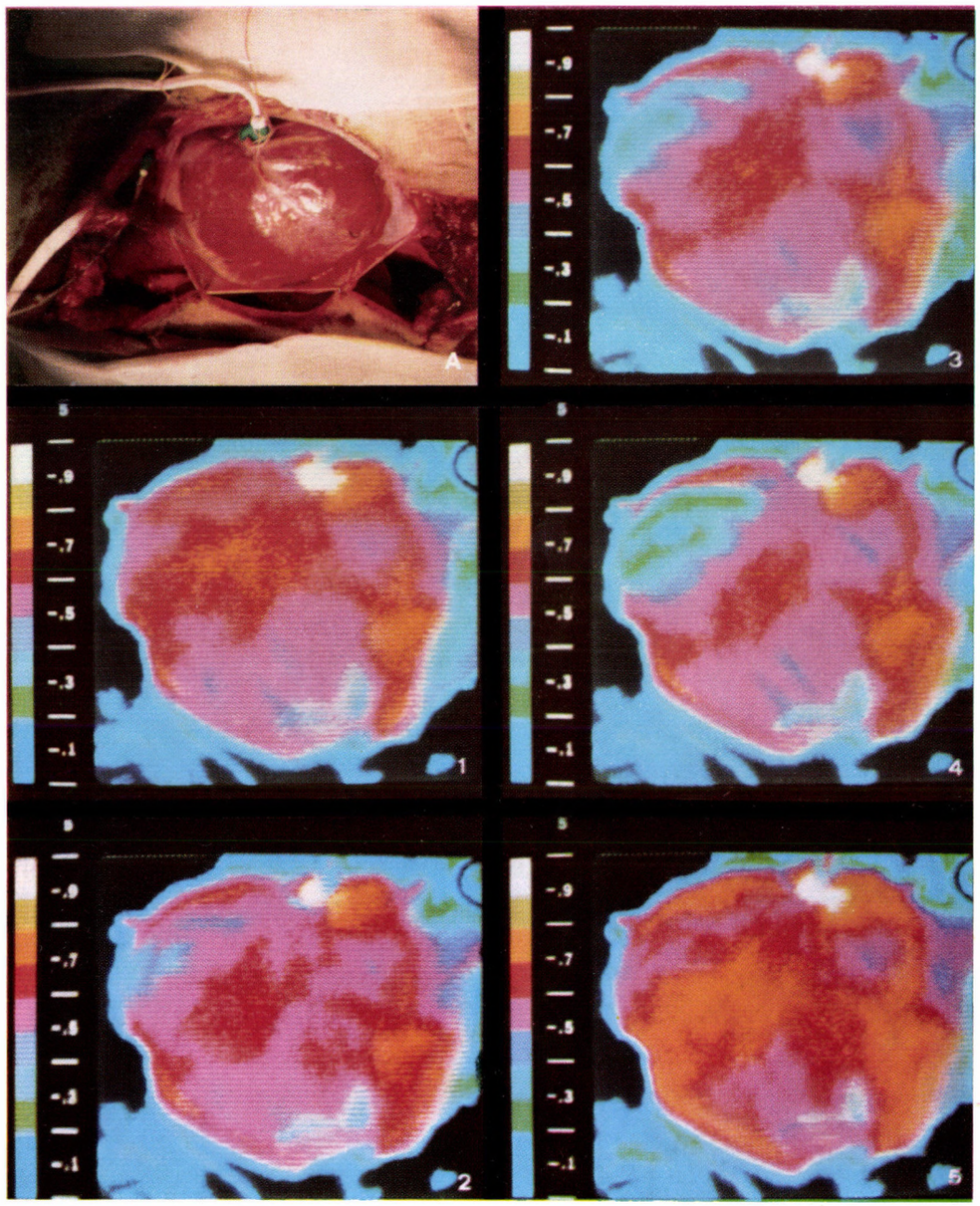

PLATE IV. Recording of the gradual reduction of coronary flow by means of thermography. Picture of the heart: flowmeter on the coronray, behind it the loop of thread led under the coronary. 1. Thermographic control picture taken before ligation. 2–4. Thermographic pictures taken when blood flow was reduced by 30%. 5. Thermographic picture taken one minute after removal of the coronary ligature

The camera was fixed on a Cabmo stand and in front of the optics a plane mirror set at an angle of 45° was placed so that the apparatus was aimed perpendicularly at the heart. A sensitivity of grade five was used, so that on the pictures each colour stands for 0.5 °C.

A Canon type AT-1 photographic camera provided with a motor continuously produced coloured negatives on Forte Color film.

Reactive hyperaemia was studied in 24 animals, the changes induced by prolonged coronary ligation in 70 animals and those caused by the gradually reduced flow in the coronary in another 8 dogs.

Results

Plate I*a* shows the photograph and thermographic picture of the dog heart prepared for the experiment. A loop of thread was led below the anterior descending branch of the left coronary below the second branching. In the top left corner of the thermographic picture the number 5 stands for the range of sensitivity, below it the colour scale is shown. The white-pale yellow colour corresponds to the warmest, the red-violet shades to the warm, the green-blue colours to the cold areas.

Each shade represents a temperature range of 0.5 °C. In our experiments the red colour corresponded to 34 °C. Every thermographic picture is the reflected image of the "normal" photograph, as a plane mirror set at an angle of 45° was placed between the heart and the objective.

The outflow region of the right ventricle and the apical area of the left ventricle are 1 to 1.5 centigrades colder than their environment. The first is due to the thick epicardial adipose tissue, the probable explanation for the second is the poorer vascularization of the apical area of the left ventricle.

The pictures in Plate I*b* illustrate a typical reactive hyperaemia. Induction of reactive hyperaemia is a widely used method for the assessment of the reactivity of the coronary system. The thermograms show a cooling after coronary ligation in the supply area. Cooling starts within 30 s and reaches 1.5 to 2 °C in three to four minutes. After removal of the ligature, rewarming is extremely rapid and after 1.5 to 2 minutes the temperature is, on the average 1–1.5 °C higher than before ligation.

The pictures in Plate II illustrate the state after prolonged coronary ligation as a function of time. Up to the 30th minute the temperature of the centre of developing necrosis decreases and then remains unchanged. Because of the increase of collateral flow between the 10th and 60th minute, the temperature of the edges slowly rises. Compared to the control, the temperature of the centre of necrosis is 3.8 ± 0.4 °C lower. In 70 dogs no significant haemodynamic change in the greater circulation occurred after application of the ligature.

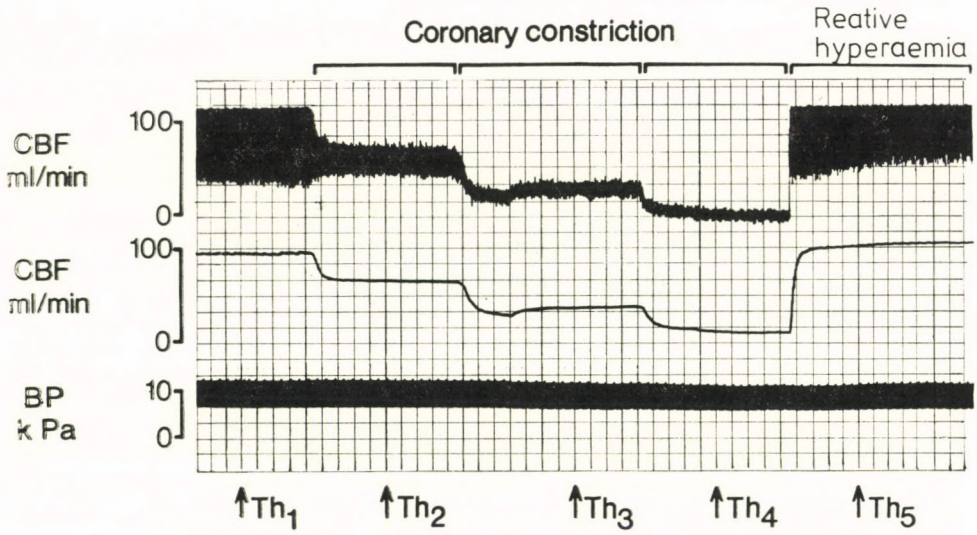

FIG. 1. Recording of the gradual reduction of coronary flow by means of electromagnetic flowmeter. The time at which the thermographic pictures have been taken are shown on the records. (Paper speed 25 mm/s)

The size and shape of the ischaemic area can be illustrated even better, i.e. be made more prominent, by leaving out certain colours during the test or by combining colour with black-and-white technique (Plate III). This method simplifies the calculation of the area and quantitative assessment.

A gradual decrease of coronary flow is followed by a proportional cooling of the supply area (Fig 1 and Plate IV). A 30% decrease of the flow was gradually produced by pulling the thread led below the anterior descending branch of the left coronary.

It was found that a 25 to 30% decrease of blood flow caused a temperature decrease of 0.5–1 °C in the epicardial area behind the ligature. Compared to the control state, an about 50% increase in reactive blood flow and a 1–2 °C rise in temperature was observed after removal of the ligature.

Discussion

In the open chest the heart loses more heat and the epicardial temperature will fundamentally depend upon the body temperature and the actual state of myocardial metabolism. The radiated heat can be measured thermographically in the middle range of the infrared spectrum.

Infrared radiation has its origin in the motion of charged elementary particles which can be detected in all bodies of various temperatures above absolute zero degree and follows the laws of electromagnetic waves. The

energy of radiated heat is determined according to the Stefan–Bolzmann law,

$$W = \sigma \varepsilon T^4$$

where W is the total irradiated energy, σ the Stefan–Bolzmann constant, $5.7 \times 1^{-}V^8$, ε the emission coefficient and T the absolute temperature of the object under investigation.

In emissivity, the 0-value refers to a completely transparent material and 1 to the completely absorbing black body.

The emissivity of the human or dog body is 0.99 in the infrared range thus it can be practically considered a black body, so that the energy of the irradiated infrared rays is proportional to the fourth power of the temperature. Consequently, the infrared radiation of the exposed heart is proportional to the surface temperature of the given part of the heart and to regional blood flow.

Thus, by means of thermography changes can be observed such as the epicardial tissue perfusion of the ischaemic myocardium. This could never be done with earlier methods. The method has the additional advantage that dynamic changes can be monitored continuously and that it offers the possibility of testing heart drugs, particularly those acting on coronary flow, even in the ischaemic parts of the heart.

Thermography enables not only the qualitative observation of changes but can also be used for quantitative assessment, as proved by our experiments in which coronary flow was reduced gradually.

By means of the method our team has supported the assumption, according to which the changes in temperature follow not the changes in myocardial metabolism but those in epicardial tissue perfusion [14].

As a drawback of the thermographic method it has to be mentioned that only the anterior and lateral walls of the heart can be tested continuously. The apical area and the posterior surface of the heart can be examined by lifting the apex which alone causes significant haemodynamic changes.

Large quantities of epicardial adipose and scar tissue can mask the changes in epicardial temperature and the heat map might become liable to misinterpretations.

The tests can be carried out only under standardized temperature conditions, in an environment free of air current. The method is not suitable for the investigation of blood flow in the deeper layers of the myocardium.

Further tests are needed to establish how far and to what degree the epicardial temperature can be followed by the temperature of the myocardial layer. By means of the currently known invasive and noninvasive procedures it has not been possible to accurately follow the changes in perfusion of the heart tissue.

As proved by our experimental results, for the investigation and continuous monitoring of regional coronary flow, thermography represents a method which is more suitable than those used previously.

References

1. Boas NF: Thermography in rheumatoid arthritis. Ann NY Acad Sci 121: 223, 1964
2. Capistrant TP, Gummit RJ: Thermography following a transient ischemic episode. J Am Med Assoc 211: 656, 1970
3. Connell JF jr, Ruzicska FF jr, Grossi CE, Osborne AW, Conte AJ: Thermography in the detection of breast cancer. Cancer 19: 83, 1966
4. Cooke ED, Pilcher MF: Thermography in the diagnosis of deep vein thrombosis. Br Med J 2: 523, 1973
5. Daniel WG, Svenson RH, Masters TN, Robicsek F: Electrophysiologic effects of partial coronary flow reduction in the exposed canine heart. The effects of ischemia and ischemic induced regional hypothermia on refractoriness and conduction delay. Circulation 58: 670, 1978
6. Daniel WG, Kelin H, Hetzer R, Heinisch H, Lichtlen PR: Thermocardiography, a method for continuous assessment of myocardial perfusion dynamics in the exposed animal and human heart. J Thorac Cardiovasc Surg 27: 51, 1979
7. Gershon-Cohen J, Haberman-Brueschke JD, Brueschke EE: Thermography of the breast. Am J Roentgenol 91: 919, 1964
8. Malm A, Arborelius M jr, Bormyr S, Lilja B, Gill RL: Effects of oxygen on acute myocardial infarction: a thermographic study in the dog. Cardiovasc Res 11: 512, 1977
9. Malm A, Arborelius M jr, Lilja B, Gill RL, Bornmyr S: Effect of nitroglycerin and dipyridamole on acute myocardial infarction: a thermographic study in the dog. Cardiovasc Res 13: 281, 1973
10. Nemes Z, Osváth B: Infratechnikai mérésekről röviden (Infratechnical measurements in brief). Műszerügyi- és Méréstechn Közl 28:13, 1980
11. Robicsek F, Masters TN, Svenson RH, Daniel WG: Experimental observation of coronary blood flow using the thermographic camera. Angiology 29: 911, 1978
12. Robicsek F, Masters TN, Svenson RH, Daniel WG, Daugherty HK, Cook JW, Selle JG: The application of thermography in the study of coronary blood flow. Surgery 84: 858, 1978
13. Seny KJ, Malm A, Bornmyr S: Intraoperative cardiothermography. Eur Surg Res 3:1, 1971
14. Tzivoni D, Cribier A, Kanmatsuse K, Chew C, Totten G, Ganz W: Epicardial blood flow during coronary occlusion studies by high speed cardiothermography. Am J Cardiol 41: 393, 1978
15. Winsor T, Bendeza J: Thermography and the peripheral circulation. Ann NY Acad Sci 121:135, 1964

Über die Anwendung der Thermographie bei der Untersuchung künstlich herbeigeführter Störung des Kranzgefäßkreislaufes

L. Papp, B. Mezei, B. Osváth und Z. Szabó

Im freigelegten Thorax kommt es zu einem bedeutenden Wärmeverlust des Herzens und die epikardiale Temperatur hängt grundlegend von der Temperatur des Körpers und seiner Umgebung, von der Koronardurchblutung und vom aktuellen Zustand des Myokardstoffwechsels ab.

Die Thermographie, die bildliche Darstellung der Temperatur, bietet eine Möglichkeit zur Registrierung der Änderungen der epikardialen Temperatur.

Zu den Untersuchungen kam ein AGA Thermovision-Apparat, Typ 750 zur Anwendung. Untersucht wurden die durch verschiedene, künstlich herbeigeführte Störungen des Kranzgefäßkreislaufes — sich nach provisorischer Kranzgefäßunterbindung entwickelnde reaktive Hyperämie (24 Hunde), Dauerunterbindung des Kranzgefäßes (70 Tiere) und graduell verringerte Koronardurchblutung (8 Tiere) — bedingten epikardialen Temperaturveränderungen. Da die Versuchsergebnisse auf einen engen Zusammenhang zwischen der Änderung der epikardialen Durchblutung und der Gestaltung der epikardialen Temperatur zeigten, scheint die Thermographie eine geeignete Methode zur Untersuchung der Durchblutungsänderungen des Myokardgewebes zu sein.

Применение термографии при исследовании экспериментально вызванных нарушений коронарного кровообращения

Л. ПАПП, Б. МЕЗЕИ, Б. ОШВАТ и З. САБО

В условиях открытой грудной клетки наблюдается повышенная потеря тепла сердцем, и эпикардиальная температура зависит в основном от температуры тела и окружающей среды, от коронарного кровотока и от актуального состояния обмена веществ в сердечной мышце.

Термография, как образное изображение температуры, делает возможным следить за изменениями эпикардиальной температуры.

Авторы пользовались для работы прибором *AGA Thermovision* типа 750. С помощью термографии прослеживали изменения эпикардиальной температуры, наступившие под влиянием реактивной гиперемии (24 собаки), возникшей после временного пережатия коронарного сосуда, после продолжительной перевязки коронарных сосудов (70 собак), затем в 8 случаях в ответ на ступенчато снижаемый коронарный кровоток. Согласно экспериментальным результатам, имеется тесная связь между изменением коронарного кровотока и изменением эпикардиальной температуры, поэтому они считают термограф пригодным для исследований изменений тканевого кровотока в сердечной мышце.

Dr. Lajos Papp
Dr. Zoltán Szabó
Department of Vascular Heart Surgery, Semmelweis University Medical School, Budapest, Városmajor u. 58, H-1122

Dr. Béla Mezei
Department of Intensive Therapy and Anaesthesiology, University Medical School, Pécs, Ifjúság útja 13, H-7624

Dr. Béla Osváth
Instrumental and Metrotechnological Service of the Hungarian Academy of Sciences, Budapest, Városház u. 1, H-1052

Acta Chirurgica Academiae Scientiarum Hungaricae, Tomus 23 (2), pp. 83—93 (1982)

Experimental Ureteroileal Anastomosis

M. GERVAIN[1], Gizella KARÁCSONY[1] and G. MOHÁCSI[2]

Institute of Experimental Surgery[1] and 1st Department of Medicine, University Medical School, Szeged[2]

(Received October 2, 1980)

The operational techniques of invaginational, two-layer and one-layer direct ureteroileal anastomoses were studied in 60 dogs. The results were checked by means of radiologic and histologic methods. When the stump of the ureter is intact, direct ureteroileal anastomosis seems to be more favourable from the aspect of restoration of the urine passage and protection of the renal parenchyma.

There are various possibilities of surgical intervention when a longer section of the urinary tract has suffered final damage. The possible solutions are direct ureteral anastomosis, transureteroureteral anastomosis, ureterocutaneostomy, ureteroneoimplantation, Boari's operation, replacement of the ureter by the small intestine, Bricker's ureteroileocutaneostomy [7], pyelovesicostomy [8] and autotransplantation of the kidney [15].

Of these operations direct ureteroureteral anastomosis and ureteroneocystostomy are the most suited for restoration of the original conditions. The basic requirement of both operations is that the anastomosis, defined by the length of the defect, must be free of strain. Pyelovesical anastomosis and autotransplantation of the kidney are now rarely applied [8, 15].

Transureteroureteral anastomosis, Boari's operation on the lower section of the ureter, and replacement by an isolated segment of the intestine make it possible to avoid external drainage of the urine.

Of the advantages of replacement of the ureter by the ileum the following have to be pointed out: The method is suitable for the replacement of any section or of the entire length of the ureter, and, at the same time, it ensures final internal drainage and peristaltic urine passage. Other aspects of the problem have been discussed earlier [5].

In the work to be reported we have investigated the effect of various types of ureteroileal anastomoses on urodynamics and on the renal parenchyma.

Material and Method

The ureter was replaced by the ileum in 60 female mongrel dogs.

In 25 cases the ureteroileal anastomosis was prepared by the invaginational method. After invagination of the ureteral stump the longitudinally

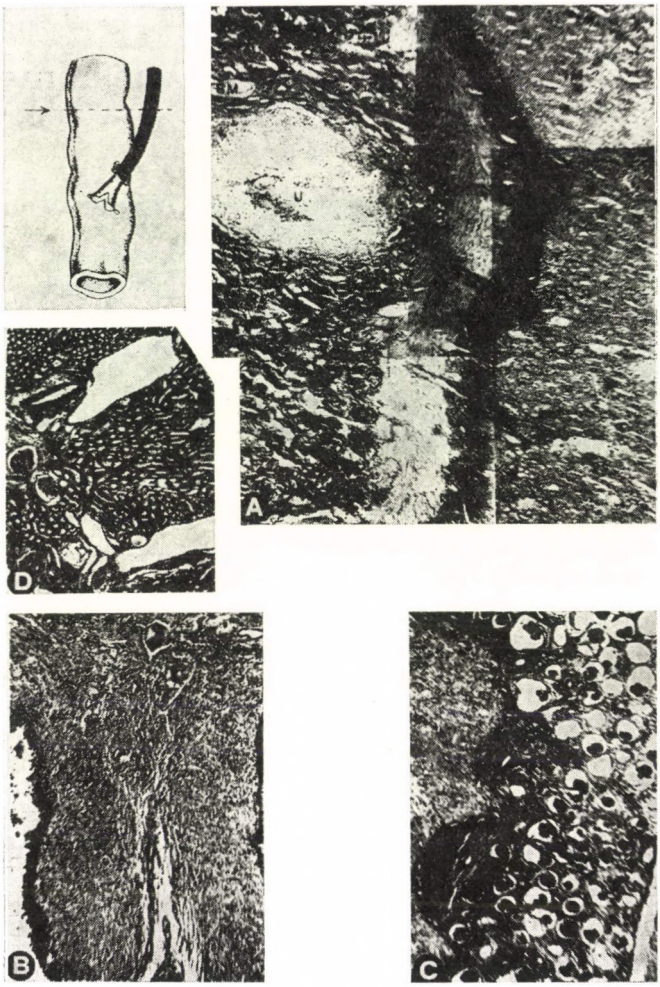

FIG. 1. Invaginational ureteroileal anastomosis and renal parenchyma. *A*. In the anastomosis the ureter (U) is surrounded by fibrotic submucosa (IM = intestinal mucosa). Van Gieson staining, ×40; *B*. Cicatrized renal papilla, H.E., ×16; *C*. Fibrotic medullary substance with atrophied cortical substance. Bowman's capsules are dilated, H.E., ×16; *D*. Dilated lymph spaces in the kidney of an animal lost in the early postoperative phase, H. E., ×40

slit ends were fixed by two 4/0 Mersilene thread corner sutures used for retraction. Subsequently, a seromuscular tunnel was prepared on the antimesenterial part of the intestine; this formed the second layer (Fig. 1).

In 17 cases urine passage was restored by double-layer proximal direct end-to-side ureteroileal anastomosis. Here again a seromuscular tunnel was formed from the ileum as the second layer above the ureteroileal anastomosis. The direct anastomosis was prepared by means of continuous chromium-



FIG. 2. Direct double-layer ureteroileal anastomosis and renal parenchyma. *A*. The constricted ureter (U) is surrounded by the wide muscular wall of the intestine (TM). (UM = muscle-wall of ureter). Van Gieson, ×16; *B*. Ulcerated papilla, H. E., ×160; *C*. In the cicatrized interstitium hydronephrosis and hyaline cylinders, and an artery with thick wall PAS, ×16

catgut sutures so that from the part of the ureter only the adventitia and the muscular layer, and from the part of the intestine only the serosa were joined (Fig. 2).

In 17 dogs the continuity of the urinary tract was restored by ureteroileal anastomosis. In these cases no second layer was formed from the intestine (Fig. 3). In none of the operations was a ureter catheter used for protection of the anastomosis.

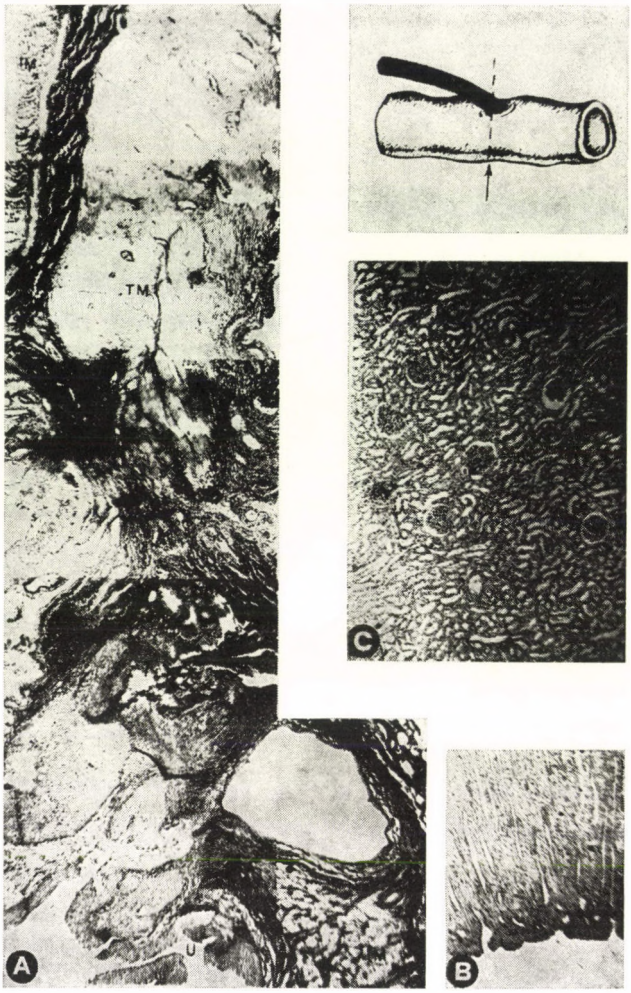

FIG. 3. Direct single-layer anastomosis and renal parenchyma. *A*. In the line of the anastomosis slight cicatrization, Van Gieson, ×16; *B*. Intact renal papilla, H. E., ×16; *C*. In the medullary substance of the kidney slight chronic focal inflammation, H. E., ×16 (For symbols see Fig. 2)

Excretory urography was performed between the 5th and 10th postoperative days and it was repeated depending upon the result. Renal function, the passage between 0 and 20 minutes, and the vesicoileal reflux were checked by an isotope gamma-chamber.

In 12 cases after sacrifice the longest diameter of the anastomosis was measured and the result was compared to the data obtained during operation.

From 25 animals specimens were taken for histology and fixed in formaldehyde diluted with 6% physiological saline. After routine embedding, the ipsilateral kidney, the ureteroileal anastomosis and the middle section of the

ileoureter were prepared. Haematoxylin-eosin, PAS and Van Gieson staining were used for the detection of collagenous fibres. For the study of the renal parenchyma, Prussian blue, Crossman's trichrome and Jones's silver-methamine staining were applied.

Results

Results of the operations and of X-ray

In the 60 animal experiments the average survival was 55.1 days (Table I). Three animals died on the day of operation, seven were living after more than one year. Survival was influenced by the fact that some animals were killed for histological examination.

TABLE I

Survival, days	No. of animals
0 to 6	16
7 to 13	12
14 or more	32

The ureteroileal anastomoses classified according to the type of operation are shown in Table II. After invaginational-type anastomosis, good renal function and free urine passage were observed in 5 animals (21%), while the scarred stricture of the invaginated ureter stump caused almost complete occlusion in 6 cases (26%). Double-layer direct anastomosis led less often to stricture, but stenosis developed in more than half of the animals surviving for several months. The X-ray pictures illustrate the degree of urine passage (Figs 4*a*, *b*). The results of single-layer direct anastomosis were entirely different (Fig. 5). In 76% (13 animals) the passage was quite free and, accordingly,

TABLE II

Ureteroileal anastomosis	Total	Insufficiency	Stricture	Stenosis	Free passage
Invaginational	23	2 (8.6%)	6 (26.6%)	10 (45%)	5 (21%)
Double-layer direct	17	1 (5.8%)	4 (23%)	9 (52%)	3 (17.6%)
Single-layer direct	17	1 (5.8%)	0 (0%)	3 (17.6%)	13 (76%)

a renal pelvis of normal width and good renal function were found. No strictures were observed after single-layer direct ureteroileal anastomosis. Urography performed between the 5th and 7th postoperative days revealed moderate dilation of the ureter stump in the renal pelvis which disappeared between

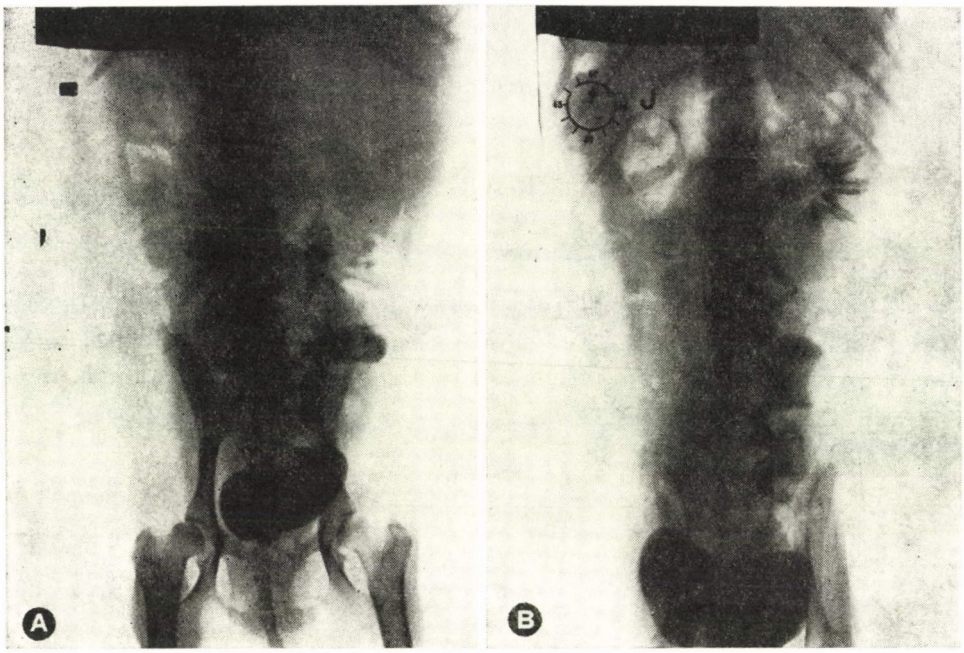

FIG. 4. Excretory urogram: *A.* invaginational ureteroileal anastomosis; *B.* double-layer direct ureteroileal anastomosis

FIG. 5. Excretory urogram: single-layer direct ureteroileal anastomosis



FIG. 6. Isotope renography with gamma-chamber in the case of single-layer direct ureteroileal anastomosis

the 14th and 21st postoperative days. Neither X-ray nor isotope gamma-chamber tests showed a difference between the pelvic systems and urine passage in the two kidneys (Fig. 6). Not even retrograde ileography could detect a vesicoileal reflux reaching the stump of the ureter.

Histology

In the ureteroileal anastomosis prepared by the invaginational technique (7 animals), beside a necrosis of the intestinal mucosa or protruding papillar granulation tissue, ureteral-epithelial proliferation developed. In animals which died within seven days, necrosis was found all along the line of anastomosis, accompanied by pus cell infiltration. In animals which survived the seventh postoperative day, more serious non-specific granulation tissue developed in the submucosa and subserosa as a function of time. Later, extensive fibrosis appeared in which sometimes only the trace of the ureteral stump could be detected (Fig. 1*A*). Examination of the parenchyma of the pertaining kidney before the 14th postoperative day showed a loose epithelium lining the dilated renal pelvis. In the papilla there was marked interstitial oedema with focal haemorrhages and starting diffuse fibrosis next to small round-cell infiltration. The medullary substance was thinner than normal. In the cortical substance the interglobular and subcapsular lymph vessels were dilated [1] and development of some connective tissue around the glomeruli could be observed (see Fig. 1*D*).

In the chronic phase (after 30th postoperative day), because of major fibrosis in the medullary substance, the tubules could only occasionally be detected above the necrosis of the papilla. In some places the basal membrane was sclerosed and in the cortical substance, too, diffuse fibrosis had developed. In Bowman's capsule and the still existing dilated cortical tubules a homo-



FIG. 7. Thickened muscle-wall of the ileoureter. *A*. Control: ileum; *B*. Upper section of ileoureter. H. E., ×16

geneous, occasionally fibrous, substance, probably with a high protein content, was visible (See Figs 1*B*, *C*).

In the 8 animals with double-layer direct anastomosis hypoxia and traces of fibrosis were discovered in both the early and the late postoperative stages, mainly without any inflammatory reaction (see Fig 2*A*). There occurred, however, also cases of complete recovery, accompanied by a minimum of complete recovery, accompanied by a minimum of cicatrization. The character and severity of renal lesions were similar to those observed with the invaginational technique. Ulceration on the papillae and ascending acute inflammation were visible in animals which died in the early postoperative stage. In the chronic stage the papilla was fibrotic, the epithelium of the ureter thinner than normal, in the fibrotic medullary substance some tubules had collapsed, in other places hydronephrosis had developed with thin dedifferentiated epithelium and hyaline cylinders in the lumen (see Figs 2*B*, *C*).

The 10 animals with single-layer direct anastomosis showed a minimum of cicatrization (See Fig. 3*A*). The ureteroileal anastomosis of the surviving animals was quite often covered all along by epithelium and healed with small papillae. One week after the operation the subepithelial part of the renal papillae was slightly oedematous with occasional focal haemorrhages, but no ulceration or inflammatory infiltration could be detected. Thirty-six days after operation the papilla was completely intact and no changes indicative of pyelonephritis were found (see Figs 3*B*, *C*).

When in 13 animals the thickness of the muscular wall of the ileum loop used for replacement of the ureter was compared to that of the ileum taken from the intestinal tract, no difference was found even in animals surviving

for more than ten months. Separate examination of three sections of the intestinal segment showed that the picture of the muscular layer of the lower section agreed with that of the control ileum, while in the middle section the picture was not uniform, and, in the top section, the inner circular muscular layer showed a 20 to 40% hyperplasia in comparison to the control (Fig. 7). The phenomenon was noted in nine cases.

Diameter of the anastomosis

As to the constrictions of anastomoses, during operation the largest diameter was between 14 and 16 Ch. This was confirmed in the course of autopsy in 12 cases of single-layer direct anastomosis. In 11 animals the difference did not exceed 2–4 Ch and in one dog a difference of 6–8 Ch was measured [4].

Discussion

Replacement of the ureter must meet the following requirements: (*i*) the organ used for replacement should have peristaltic activity; (*ii*) free passage of the urine must be ensured; (*iii*) reflux reaching the renal pelvis must be prevented [6, 9, 11, 13]. Whether these requirements can be met will depend upon the proximal anastomosis created in the urinary tract, in the case of replacement with ileum, upon the ureteroileal anastomosis.

Ureteroenteral anastomosis of the invaginational type is often used but in 20 to 30% of the cases it causes stenosis and stricture [12, 18]. Our results have also confirmed that this type of anastomosis does not produce the best results; beside ischaemia and infection of the stump, hyperplasia of the internal layer of the ileal segment might contribute to the development of stenosis and stricture [2].

After double-layer direct anastomosis stenosis appeared in 50% of the cases. It has to be noted that in our experiments the anastomosis was created on ureteral stumps normal in width. Farcon and Schwartz achieved good results with their seromuscular tunnel technique which was similar to ours. They found no obstacle in passage nor ileoureteral reflux, but the follow-up lasted only six weeks [3]. These data show that the seromuscular canal which represents the second layer acts as a valve.

With a dilated ureteral stump the size of the anastomosis will be determined by the lumen of the stump. As the degree of hyperplasia of the musculature cannot be predicted, in these cases the subserous technique is advisable for the prevention of reflux. In the literature there are several references to a variety of ureteroenteral operational techniques [10, 16, 17, 18, 19, 20]. Sometimes stenosis occurs but the cause of its extent and incidence could not

be found even in the course of re-operation or autopsy [6]. We suppose that the hyperplasia of the intestinal musculature might contribute to the development of functional stenoses of this type. Hyperplasia causes not only a constriction in the line of the anastomosis, but above the orifice the musculature of the intestine also narrows the ureteral stump. Necropsy often revealed a free passage through the orifice and the pelvic system and the ureteral stump was none the less dilated. In the hyperplasia of the intestinal musculature the neuromuscular transmitters (P-factor, etc.) which regulate the innervation and motion of the ileum, might also have a role. The toxins secreted with the urine and the constant changes of its pH are stimulating the intestine and may act as causative factors, since through the mesenterial loop the innervation of the intestinal segment used for ureter replacement has remained unchanged.

Effects influencing the fate of the anastomosis act also in the case of single-layer direct anastomoses, though in two-thirds of the cases the passage has been quite free (Table II, Fig. 6). After single-layer direct anastomoses, suture insufficiency was observed in a single case, so its incidence was not higher than with double-layer anastomoses.

In our experiments we observed no reflux reaching the renal pelvis, not even with retrograde filling [5]. We believe that the prevention of reflux depends not only on the surgical technique; the peristaltic activity influenced by the length of the ileal segment might be of almost equal importance [6]. In other experiments we found that the peristalsis of the ileum was related to the degree of urine flow from the kidney. When we reduced the capacity of the ileum by means of our tunnel method [5], the frequency and amplitude of the peristalsis followed the rate of urine flow. A reflux at the ileovesical orifice may elicit a peristaltic reflex, but when the ileal segment is sufficiently long, the regurgitating urine will not reach the ureteroileal orifice. A longer intestinal segment has, however, the drawback of an increased reabsorption. This is an apparent contradiction. The tunnelled intestinal segment, on the other hand, meets both requirements. Thus, in our opinion, in the case of undisturbed passage, the ureteroileal anastomosis can perform its task adequately only depending on the renal function and the peristaltic activity of the ileum [14].

References

1. Albertine KM, Morchoe Ch: Distribution and density of the canine renal cortical lymphatic system. Kidney Int 16: 470, 1979
2. Barthó L, Szolcsányi J: The site of action of capsaicin on the guinea-pig isolated ileum. Arch Pharm (Weinheim) 305: 75, 1978
3. Farcon E, Schwartz M: Antireflux ureteroileal anastomosis. Urology 14: 344, 1979
4. Furka I: Az ureter end-to-end anastomosisainál keletkezett szűkület biometrikus elemzése (Biometric analysis of the constriction occurring at the end-to-end anastomoses of the ureter). Magy Seb 4: 270, 1963

5. Gervain M: Ureterpótlás kirekesztett ileum kaccsal (Ureter replacement with strangulated ileal loop.) Magy Seb 32: 317, 1979
6. Goodwin WE, Winter CC, Turner RO: Replacement of the ureter by small intestine. J Ur 81: 406, 1959
7. Heise GW, Langkopf B, Ramthor W: Die Operation nach Bricker. Z Urol Nephrol 65: 881, 1972
8. Herwig KR, Konnak JW: Vesicopyelostomy. J Ur 109: 955, 1973
9. Hessein AA: Experience with the ileal ureter. Br J Urol 48:19, 1976
10. Itatani H, Sonoda T: New technique of antireflux ureteroileal anastomosis and its clinical experiences. J Ur 119: 735, 1978
11. Lichtenauer P: Zur Problematik der Uretero-Ileocystoplastik. Urologe [A] 14: 217, 1975
12. Mayor G, Zingg EJ: Urologische Operationen. Harnleiter. Thieme Verlag, Stuttgart 1973, p. 141
13. Mebel M: The problem of ureter replacement. Int Urol Nephrol 2: 99, 1970
14. Mohácsi L, Varga, J: Ileum-ureter alkalmazása retroperitonealis fibrosis megoldására (Application of ileum-ureter for solving retroperitoneal fibrosis). Orv Hetil 120: 2424, 1979
15. Pettersson S, Brynger S: Extracorporal surgery and autotransplantation for carcinoma of the pelvis and ureter. Scand J Urol Nephrol 13: 89, 1979
16. Schellhammer PF, Texter JH: An experimental uretero-ileal anastomosis to prevent reflux. Invest Urol 11: 319, 1974
17. Scott FB, Baum U: Uretero-ileal anastomosis: new antirefluxing technique. Urology 6: 215, 1975
18. Starr A, Rose DH: Antireflux uretero-ileal anastomosis in humans. J Ur 113:170, 1975
19. Starr A, Rose DH: Antireflux uretero-ileal anastomosis: two experimental techniques. Invest Urol 12:165, 1974
20. Richie JP, Skinner DG: Urinary diversion: the physiological rationale for non-refluxing colonic conduit. Br J Urol 64 (3), 345, 1975

Experimentelle Daten zu den ureteroilealen Anastomosen

M. Gervain, Gizella Karácsony und G. Mohácsi

Die Operationstechnik von ureteroilealen Anastomosen — Invaginations-, zweischichtige direkte und einschichtige direkte Anastomosen — wurde bei 60 Hunden untersucht. Zur Kontrolle der Ergebnisse wurden radiologische und histologische Methoden herangezogen. Im Falle eines intakten Ureterstumpfes scheint vom Standpunkt der Wiederherstellung der Harnpassage und des Schutzes des Nierenparenchyms aus, die einschichtige, direkte ureteroileale Anastomose vorteilhafter zu sein.

Экспериментальные данные к уретеро-илеальным анастомозам

М. ГЕРВАЙН, Г. КАРАЧОНЬ и Г. МОХАЧИ

В экспериментах, проведенных на 60 собаках, авторы изучали оперативную технику уретеро-илеальных анастомозов — инвагинационных, двухслойных прямых и однослойных прямых анастомозов, результаты которых проверяли радиологическим и гистологическим методами. При сохранной культе мочеточника более целесообразным кажется создание однослойного прямого уретеро-илеального анастомоза с точки зрения восстановления пассажа мочи и сохранения почечной паренхимы.

Dr. Mihály Gervain
Dr. Gizella Karácsony
Institute of Experimental Surgery, University Medical School, Szeged, Pécsi út 4. H–6720

Dr. Gábor Mohácsi
1st Department of Medicine, University Medical School, Szeged, Pécsi út 4. H–6720

Acta Chirurgica Academiae Scientiarum Hungaricae, Tomus 23 (2), pp. 95—115 (1982)

Carcinoid Tumours of the Gastrointestinal Tract

M. IHÁSZ[2], Márta BALÁZS[2], A. CSILLAG[2], K. SZABÓ[1] and F. HORKAI[1]

2nd Department of Surgery, Semmelweis University Medical School[1], and Department of Surgery, Municipal János Hospital[2], Budapest

(Received March 25, 1981)

Based on experience with patients with gastrointestinal carcinoid tumour in the recent ten years, the pathophysiology, symptoms, diagnosis, surgical and drug treatment of the disease as well as its prognosis are discussed.

Carcinoids of the gastrointestinal tract are rare tumours but their pathologic and symptomatologic peculiarities as well as the frequent diagnostic difficulties make it desirable to deal with this condition beyond simply reporting on the case.

The term carcinoid was first used by Obendorfer [65], who distinguished these tumours from carcinoma stressing their benign nature. Later he revised this view when the carcinoids were found to be potentially malignant. The term carcinoid was based on the finding that though the histological pattern is similar to that of carcinomas but their clinical course can be quite different. The tumour starts from the argentaffin or enterochromaffin (Masson or Schmith–Kultschitzky-type yellow) cells of the gastrointestinal mucosa in the fundus of the Lieberkühn crypts. Since these cells are present everywhere in the digestive tract with the highest number in the last section of the ileum and the ileocoecal region, carcinoids may be formed anywhere in the intestinal including the biliary system and the pancreatic ducts.

Several synonyms have been suggested for these cells: yellow cells [87], enterochromaffin cells [19], light and argentaffin cells [28, 32], APUD (Amine Precursor Uptake and Decarboxylation) cells [72, 107], etc. Kähler [44] recommended the term basal granulous cells in view of their manifold staining properties. Masson [cit. 70] called attention to the relationship between carcinoid tumours and nerve fibres and attributed a nervous origin to the tumours stressing their endocrine function, and called therefore the carcinoids neuroendocrine tumours. The endocrine activities of these tumours and of their metastases are currently known as the carcinoid syndrome [15]. Erspamer [25] and Rappart et al. [79] made important contributions to the clarification of the syndrome by the discovery of the biologically active substances enteramine and serotonin.

Though pushed more and more into the background, serotonin (5-HT) produced by the argentaffin cells is still considered the main active substance of carcinoids. Recent investigations have, however, showed that beside or, instead of, serotonin important roles have to be attributed to the quinines bradykinin, kallidin and kallikrein. Zeitlin and Smith [103] found a high bradykinin activity in the blood of carcinoid syndrome patients, though other authors failed to confirm this observation [55]. According to Oates and Sjoerdsma [64], the serotonin precursor 5-hydroxytryptophan (5-HTP) and histamine are more likely to be responsible for the syndrome than serotonin. Smith et al. [93] claimed that the tumour produces histamine and stressed the role of the vasoactive intestinal polypeptide (VIP), the gastric inhibitor polypeptide and of somatostatin, but Zammit and Modlin [102] were unable to confirm this assumption. These authors showed, on the other hand, an increased plasma polypeptide (PP) level in carcinoid patients. Since the enterochromaffin cells from which the tumour develops produce no polypeptides, the higher PP level is considered a secondary phenomenon unimportant from the point of view of diagnosis. Delmon and Rampal [22] pointed to the role of prostaglandin-type (PgE_2) substances. Bordi et al. [9] observed an increased serum gastrin level after gastrojejunostomy in patients with gastric carcinoid, confirming thereby Lemmer's [50] earlier observation of a relationship between gastrojejunostomy and gastric carcinoid. Other authors called attention to the simultaneous incidence of pernicious anaemia and gastric carcinoid [7, 33]. Based on experimental and clinical experience, Feyrter [27] emphasized the correlation between alcoholism and tumour development. It seems greatly probable that hormones not isolated so far or other chemicals in the organism might have a role in the genesis of the carcinoid syndrome [73]. The possibility cannot be excluded that the syndrome and some of its symptoms are caused by more than one substance. Thus, the aetiology of carcinoid tumours and of the carcinoid syndrome is unclear. The problem is complicated by the fact that a certain percentage of tumours of typical carcinoid structure contains no argentaffin granules. The structural and functional discrepancies of the tumours are greatly influenced by the situation of the organ from which the tumour had originated. Tumours with typical properties and structures start from the part of the intestine which has developed from the mesogaster. According to Rózsahegyi [83], tumours originating from the foregut (stomach, pancreas) have a minimal 5-HT content, but produce greater amounts of 5-HTP so that a considerable quantity of 5-hydroxyindole acetic acid (5-HIAA) is excreted with the urine. The same is true for carcinoids of the small intestine. Tumours starting from the hindgut (descending colon, rectum) do not secrete 5-hydroxyindole and thus cause no syndrome and neither do they secrete 5-HIAA. This rule, however, is far from being of general validity.

Incidence, Localization, Symptoms

According to published data, the incidence of carcinoids compared to that of all tumours of the digestive tract amounts to 1 to 1.8% [5, 48, 69, 71]. Palkoska and Schober [69] claim that 80 to 95% of the tumours are localized in the ileum and the appendix, but according to Reifferscheid [81], only about 61% of the tumours occur in these regions. The incidence of carcinoids decreases with the distance from the ileocoecal region. In the oral direction the stomach is the upper limit. Carcinoids in the oesophagus are extremely rare, only two such cases have been described in the literature [11, 13]. Carcinoids of the biliary duct and of the gall bladder are also rare. Two papers have been found to mention carcinoids of the biliary duct [75, 90] and two others describing carcinoids of the gall bladder [4, 61], but according to Schwesinger [90], six cases of cholecystocarcinoid have been published. Carcinoids of the ampulla of Vater are also rare; they amount to about 0.3% of the argentaffin tumours of the gastrointestinal tract. The case reported by Barber [3] in 1976 was the 13th such case in the literature, but for the one described by Kelényi [46].

Gastric Carcinoids

The low incidence of gastric carcinoids is indicated by the fact that even single diagnosed cases are published [9, 33, 48, 53, 69]. In the Hungarian literature Ondrejka et al. [66] have recently reported a case causing massive haemorrhage. According to Langhans et al. [48], gastric carcinoids amount to about 0.39% of all malignant gastric tumours. The same authors have described a rare case where the 31 polyps ranging in size from 0.4 to 2 cm removed from the gastric mucosa were carcinoids. It is typical of carcinoids that, as a rule, they are localized in the antral pyloris region [12, 60]. According to Bordi et al. [9], they do not occur in patients who have earlier been subjected to resection for duodenal ulcer or, if so, even in the case of regional metastases, they remain latent for a long time [49]. Argentaffin tumours of the digestive tract are usually not liable to ulceration, with the exception of those in the stomach which frequently exulcerate. Consequently, haemorrhages may occur in all possible forms [31]. The size of the tumour has no connection with the haemorrhage [38, 76].

The symptoms are not specific. Epigastric pains are the most frequent and are not relieved by antacids. Nausea, vomiting, loss of weight and bleeding occur also in ulcer patients. Since carcinoids are often associated with ulcers, the above symptoms can be attributed to the latter.

There was one case of gastric carcinoid in our material whose history was as follows.

P.M., a 53-year-old male patient was admitted for a gastroscopically confirmed gastric tumour. More than 30 years ago he had a thoracoplasty and for eight years hypertension, heart complaints and a chronic cor pulmonale. He had been anorexic for several years and had lost 3 kg weight and had occasionally dull epigastric pain, asphyxia on walking, nycturia and swollen ankles. Routine laboratory findings were normal.

The fiberoscope GIFD could be led smoothly into the duodenum. The duodenum and the mucosa of the bulb were intact. Bile regurgitation was observed, the antral mucosa was hyperaemic. Below the cardia, on the posterior wall of the lesser curvature an exulcerated haemophilic tissue proliferation of infant palm size covered by necrotic tissue was visible which gave the impression of malignancy. The greater curvature, the cardia and the oesophagus seemed normal.

Repeated biopsy (Dr. Bodó) of the lesion revealed, beside chronic inflammation, coarse granulation tissue and necrosis (Dr. Csermely).

On admission the skin and mucous membranes of the patient were somewhat pale, his tongue was furred, the chest deformed, with sluggishly deviating diaphragms and rough breathing. The heart size sounds were normal and so was the size of the abdomen. The liver was slightly enlarged, the spleen was not palpable. The epigastrium was sensitive to pressure.

After admission the patient ran a fever and an epigastric, rapidly growing painful resistance developed under the right costal arch. On transversal

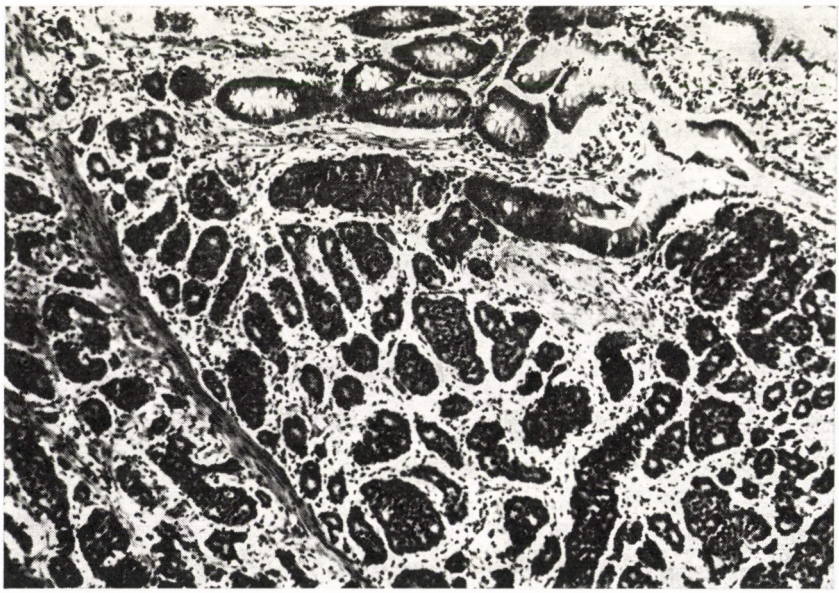

FIG. 1. Above, intact glands of gastric mucosa, elsewhere nests of dark, polygonal epithelial tumour cells (HE, ×120)

median laparotomy slightly opalescent ascites was discharged. Both lobes of the liver were enlarged, and nodular. On the lesser curvature of the stomach immediately below the cardia a 3×2 cm tumour was detected. The nodules contained fragmented gelatinous mass which macroscopically corresponded to sarcoma and microscopically to a cell-rich malignant sarcoma-like tumour. The lesion was considered inoperable, the abdomen was therefore closed.

Histologically, the tumour in the stomach had a trabecular structure, spread in fairly large nests, infiltrated the gastric wall and contained necrotic parts. The cells were polygonal, slightly polymorphous with round darkly staining nuclei, the nucleochromatin showed a rough clotted distribution (Fig. 1). The tumour had metastasized to the liver.

Subsequently, the patient could not be extubated because of respiratory failure and artificial breathing had to be applied. Despite adequate therapy, his condition deteriorated rapidly and on the third postoperative day the patient died with circulatory failure.

The post-mortem revealed in the trachea an about 1.5 cm ulcer of the mucosa, fibrosis in the left lung, cor pulmonale with dilated right ventricle, congestion in the systemic circulation, acute bronchitis and acute cystitis. The basic disease was a carcinoid of the stomach with metastases in the liver

Intestinal Carcinoids

Carcinoids of the duodenum have a comparatively higher incidence and amount to about 2.4 to 2.8 per cent of the carcinoids of the digestive tract [46, 67].

An operated case of argentaffin tumour starting from the head of the pancreas was described by Pataki et al. [cit. 83].

Carcinoids of the intestine have the highest incidence. According to the data of Berge and Linell [5] 90%, according to Langhans et al. [48] 32% of all carcinoids of the digestive tract are localized in the intestine, mainly in the middle and terminal ileum [71]. If the carcinoid protrudes into the lumen, is pedunculated or surrounds ring-like the intestine, the clinical symptoms typical of local stenosis will call for an early operation, consequently, the disease can be diagnosed at an early stage. This happens in about 25 to 30% of the cases [71]. Multiple localization and early metastases are characteristic of every third intestinal carcinoid. In addition, they often cause necrosis [77], perforation [24], massive haemorrhage [39] and sometimes invagination [48, 2, 104, 74, 29].

In our material there were three cases of intestinal carcinoid (Table I); the history of one of them is as follows.

TABLE I

Data of Carcinoid Patients

No.	Age (yrs) and sex	Preoperative diagnosis	Operation	Site of tumour	Site of metastasis	Histologic diagnosis	Postoperative phase
1	15 woman	Acute appendicitis	Appendectomy	Appendix	—	Carcinoid infiltrating the meso-appendix	No complaints at discharge from hospital
2	70 woman	Mechanical intestinal paralysis	Latero-lateral anastomosis	Middle section of ileum	Lymph nodes, peritoneum	Malignant carcinoid with metastases	Death
3	29 woman	Acute appendicitis	Appendectomy	Appendix	—	Carcinoid of the appendix	No complaints at discharge from hospital
4	67 man	Mechanical intestinal paralysis	Resection	Middle section of ileum	Lymph nodes of the mesenterium	Malignant intestinal carcinoid with metastases	Death
5	78 woman	Tumour of coecum	Hemicolectomy, ileotransversostomy	Coecum	—	Malignant carcinoid	No complaints at discharge from hospital
6	54 woman	Tumour of pancreas?	Explorative laparotomy	Appendix	—	Carcinoid in apex of appendix	Death
7	64 woman	Cholelithiasis	Ileoileostomy, then resection of ileum	Middle section of ileum	Mesenterial lymph nodes, liver	Carcinoid in ileum, metastases in lymph nodes and liver	Cured
8	73 woman	Tumour of coecum	Ileotransversostomy	Coecum	Omentum, mesenterium, peritoneum, liver	—	Death
9	65 woman	Tumour of coecum	Hemicolectomy, ileotransversostomy	Coecum	—	Malignant carcinoid in coecum, metastasis in lymph node	No complaints at discharge from hospital
10	53 man	Gastric tumour	Explorative laparotomy, liver biopsy	Lesser curvature of stomach	Liver	Malignant gastric carcinoid with liver metastases	Death

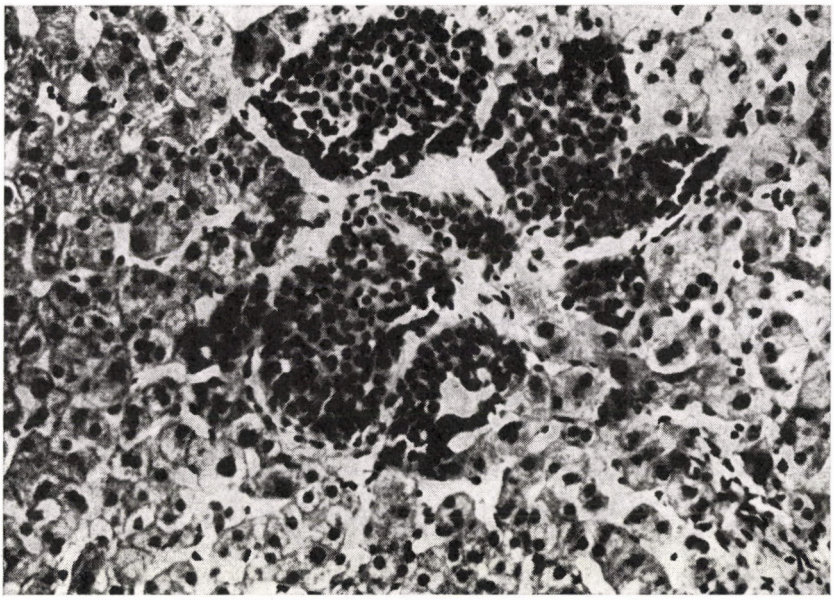

FIG. 2. Excised part of liver in a 74-year-old female patent. Cell groups characteristic of carcinoid metastasis (HE, ×160)

G.H., a 74-year-old female patient was referred to us for cholecystectomy indicated by painful cholelithiasis of several years standing confirmed by X–ray. Laboratory and other clinical findings were normal. Butterfly-wing facial erythema suggested systemic lupus erythematosus, but this could not be verified.

After supplementary tests and adequate preparation a cholecystectomy was planned (May 12, 1980). The abdominal cavity was exposed by subcostal incision on the right side. Palpation of the liver revealed a number of small calculi in the gallbladder and several metastatic nodules on the phrenic surfaces of both lobes. Further exploration found a tumour in the middle section of the ileum which greatly reduced the lumen. The intestine was wide above the tumour and slightly collapsed below it. In the mesenterium some enlarged lymph nodes were palpable. Instead of cholecystectomy, an anastomosis was created between the ileal loops above and below the tumour. A mesastatic node was removed from the right hepatic lobe and the abdomen was closed.

The postoperative phase was undisturbed, the wound healed smoothly. Histological examination showed a carcinoid tumour with metastasis in the liver (Fig. 2).

In view of this, the patient was re-operated (June 4, 1980). From medial laparotomy the anastomosis was explored; it was patent to three fingertips.

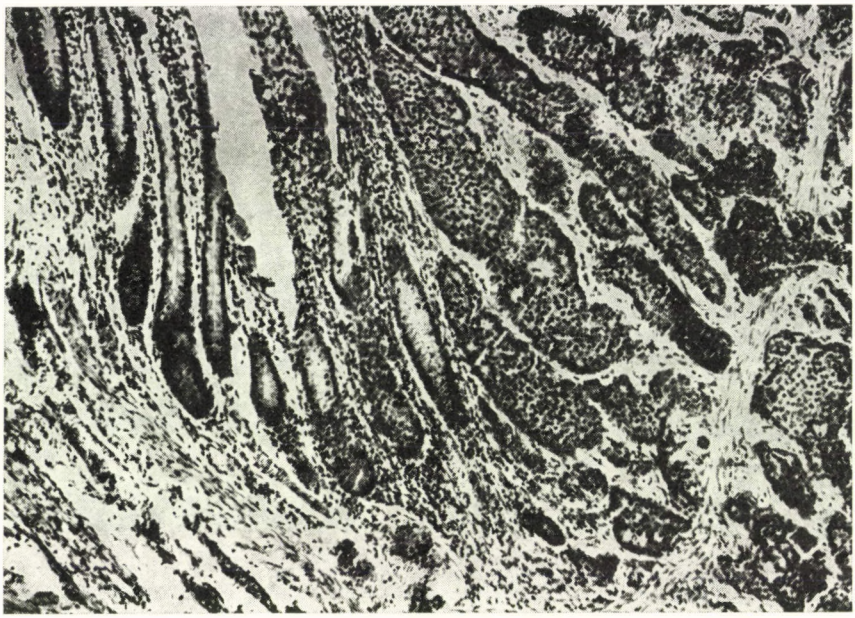

FIG. 3. Primary intestinal tumour of the same patient (HE, ×120)

The about 30 cm long bypassed section of the ileum was resected with the tumour and the mesenterium, the two ends of the ileum were anastomosed and the mesenterium was united by knotted sutures. The hepatic metastasis detected in the course of the first operation showed no progression.

The histological examination showed a carcinoid tumour in the ileum with lymph gland metastases (Figs 3 and 4).

The postoperative period was undisturbed, the wound healed smoothly. During this period, 5-HIAA excretion was repeatedly determined in the 24-hour urine; the average value was 64.8 mg or 336.9 μmol per day. (In our laboratory the normal value for 5-HIAA excretion was 2.8 to 8 mg daily.)

After the second operation fluorouracil treatment was introduced. The administration of 15.6 mg reduced 5-HIAA excretion to 26.4 mg per day, and after a total dose of 30.2 mg to 4 mg per day. Later, the patient was again admitted for cystostatic treatment. She had no complaints, had put on 8 kg and no noteworthy changes were discovered in her laboratory findings. On December 8, 1980, her 5-HIAA excretion was daily 201.6 mg.

The appendix is also a frequent site of carcinoids. Thirty to fifty per cent of carcinoids are localized in the appendix, though there are considerable discrepancies between the data of the various authors [48, 98]. The carcinoids are usually situated on the apical part, opposite to the mesenterium, less frequently at the root of the appendix. Usually, the tumour is of hazelnut size, but can sometimes extend to the entire vermiform appendage. Appendix carcinoids

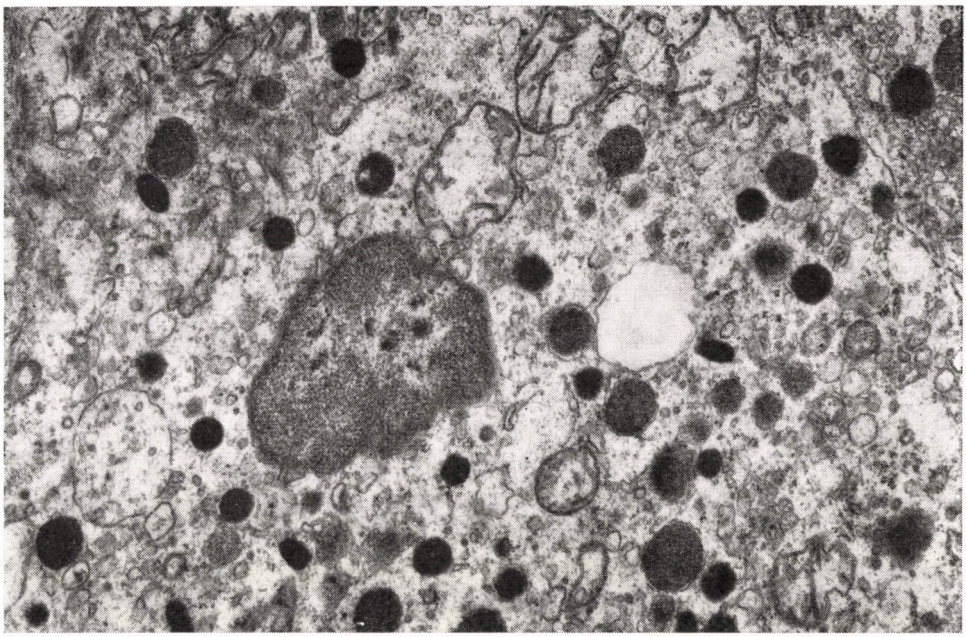

FIG. 4. Electron-microscopic picture of the same tumour. Nucleus and round neuro-endocrine granules of high electron density surrounded by a simple membrane in the cytoplasm

are, beyond all doubt, one of the most benign argentaffin tumours, but they cannot be accepted as completely benign. The histological pattern in itself is not reliable, the progress of the disease alone will decide the question of benignity or malignancy. They form late metastases, especially in the surrounding lymph glands and the liver, one of the probable causes of this being that the patients are operated on earlier, more often for chronic than for acute appendicitis. Warkel et al. [105] described a case of appendix carcinoid which had the characteristics of both carcinoid and adenocarcinoma as it contained argentaffin and mucin secreting cells. This tumour represents a special category for which the authors recommended the term adenocarcinoid.

In our material we encountered three cases of appendix carcinoid (Table I).

The incidence of carcinoids of the coecum and of the colon is 2 to 4%. They have the characteristic property to form metastases early, this being particularly true of coecum carcinoids. Despite the higher ratio of metastases of coecum carcinoids, survival in this group is higher than in the case of argentaffin tumours starting from other areas of the colon [50]. Generally speaking, the complications are the same as those described for intestinal carcinoids. Scaane and Bide [92] have described a coecum carcinoid which caused intussusception, Hay and Court [34] the simultaneous occurrence of ulcerative colitis

and carcinoid and Rózsa et al. [82] a simultaneous colon carcinoma and carcinoid.

In our material there were three patients with coecum carcinoid (Table I).

Rectum carcinoids, 99% of which are in the ampulla [71] make up 10 to 25% of all carcinoids. They have the highest incidence in the sixth decade of life which coincides with the performance of preventive prostate and rectum carcinoma tests. The apparent rise in the incidence of rectum carcinoma can be explained with the increasing number of tests and the longer life-span. The incidence, however, should be understood in such a way that, for example, Quan et al. [78] found among the 60 000 subjects examined by proctosigmoidoscopy carcinoids in 0.03% and, by taking into consideration Zakharia's [101] data, the number of cases might be around 500, so that even single cases are published [91]. Colbert [20] reported on the simultaneous occurrence of primary carcinoid in the rectum and the ileum.

There are discrepancies between the data published on the incidence of carcinoids, partly because the incidence of the tumour is probably different in the various parts of the world. Another cause might be the insignificance of a certain percentage of carcinoids and the fact that the tumour is often detected in the course of necropsy when the patients has died of some other illness. In other words, a certain percentage of patients die with, but not from, a carcinoid tumour. This explains why the data of surgeons on the incidence of the disease are lower than those of pathologists [5, 68].

Distribution of Patients According to Age and Sex

Carcinoids of the gastrointestinal tract occur at any age. Carcinoids of the appendix are usually detected in young people in the course of appendectomy, while the argentaffin tumours of the ileum, colon and rectum are more likely to be diagnosed in middle or old age when they cause complication. With the exception of appendix carcinoids, the incidence in the two sexes analysis of 2837 cases. Berge and Linell [5], too, found a higher incidence among men than among women. Among women carcinoids of the ileum, among men those of the appendix have a higher incidence. In this connection it is worth noting the conspicuous predominance of bronchus carcinoids among women; the ratio is 8 to 1 for women and men [5]. In the 44 cases of Schmidtler et al. [89] the average age of patients with carcinoid of the appendix was 29.1 years, which is much below the 54 years mean age of patients with other intestinal carcinoids. In the same material the ratio of men to women was 23: 21.

In our material the incidence of the tumour in the two sexes was 8 women and 2 men. The average age of patients with appendix carcinoid was 32.6 years, that of the others 56.9 years. Further data of the patients operated on between January 1, 1970, and December 31, 1980, are contained in Table I.

Size, Growth, Metastasis

It is difficult to determine the size of carcinoid tumours, since this depends, to some extent, on the time of diagnosis. In general, carcinoids are small tumours 1 to 2 cm in diameter, situated under the mucosa. They grow slowly, have an infiltrative character, and are less destructive than the cancers. A considerable part of carcinoids remains silent during the entire life and is detected only in the course of necropsy performed after the patient has died of some other disease [71]. Metastasis formation is a slow process and not more than 5 to 10% of the patients with metastases develop a carcinoid syndrome. On the other hand, once the symptoms have appeared, the carcinoid is, as a rule, no longer localized.

The ability to metastasize is in direct proportion with the size of the tumour, but it also depends on the section of the digestive tract from where the primary tumour had originated. Only 1 to 2% of the tumours smaller than 1 cm will form metastases, while about 50% of tumours 1 to 2 cm in diameter and 80 to 90% of tumours larger than 2 cm, will metastasize [30, 89]. The incidence of metastases is between 20 and 75% [5]. Intestinal and colon carcinoids readily metastasize. This is particularly true for the multiple carcinoids of the ileum. The primary sites of metastases are the regional lymph nodes, followed by the liver and the peritoneum, and less frequently the lungs, ovaries, testicles and bones [45, 86]. The disease may spread via the lymph ducts, the blood flow or through the perineural parts. We found metastases in five (50%) of our patients (Table I).

Moertel et al. [58] have pointed out that there must be a certain link or relationship between carcinoids and other malignant tumours. It is difficult to verify this statement as the carcinoids grow slowly and in the meantime other malignant tumours may develop. Berge and Linell [5] found malignant tumours in 44.5% of their necropsied material and this figure was almost the same (40.7%) in the case of carcinoid patients. Warren and Coyle [106] reported on a similarly high incidence (53%). According to Kuiper et al. [47], the incidence of simultaneously present malignant tumours is 31.9%. Hence, the data of these authors unambiguously confirm the absence of a link between carcinoids and other malignant tumours.

In carcinoid patients, on the other hand, a peptic ulcer is often observed as an intercurrent disease. MacDonald [52] found a duodenal ulcer in 38% of his 336 carcinoid patients, Stewart and Barlett [96] also in 38% and Berge and Linell [5] in 14.1%. So far, no equivocal explanation has been found for this correlation. It might be supposed that histamine release and the protracted ischaemia of the gastric mucosa have a certain role [98] but the possibility of a direct serotonin effect cannot be excluded. It is obvious that the higher incidence of other benign conditions may also be brought into relation with

carcinoids. Feyrter [27] as well as Schmidtler et al. [89] observed liver cirrhosis more often in patients with argentaffin tumour. Cholelithiasis, cholecystitis and nephrolithiasis are also more frequent [4]. According to certain authors, articular swelling and pain can also be attributed to the tumour [cit. 83].

Pathology

In general, carcinoids are hard without a regular capsule. They spread between the layers of the affected area so that the mucous membrane surface is often intact, as ulceration is rare. The colour of carcinoids is in most cases yellowish-white or grey but may also be haemorrhagic.

Histologically, the carcinoid tumours may be divided into four groups. In type A tumour the cells are arranged in nests divided by connective tissue septa-rich in fibres. In the tumours of type B the cells are arranged trabecularly, the bundles form a network, the stroma is richly vascularized. Of tumours of type C an acinus-like arrangement of the cells is characteristic, while in type D the cell-pattern is not differentiated, the arrangement is trabecular or medullar. These histological types may be present in one and the same tumour.

The Carcinoid Syndrome

Bohn and Feyrter [8] were the first to point to the correlation between this group of symptoms and intestinal carcinoids, but Cassidy [15, 16] was the first to describe the classical syndrome without being able to explain the clinical picture.

The symptoms of the carcinoid syndrome are explained by the paracrinous activity of argentaffin cells. Their hormone is serotonin (5-HT). Lately, the view has come into the foreground that in the development of symptoms the serotonin precursor 5-HTP, the quinines, and histamine play a far greater role than serotonin itself [6, 10, 64, 83].

Clinically, carcinoid tumours fall into two groups, the active and inactive endocrine groups. The latter are often detected only in the course of operations (appendix carcinoids). The active endocrine tumours occur mainly in the ileum and cause carcinoid syndrome in about 5% of the cases, while with metastases the incidence of the syndrome is 20 to 25%. The serotonin released from the carcinoids of the gastrointestinal tract reaches the liver through the portal vein and is inactivated in the liver (monoaminooxidase). Hence, the syndrome appears only when extensive metastases, usually located in the liver, empty their products directly into the caval system and there is no metabolism. This explains why urinary 5-HIAA excretion increases only when there are hepatic

metastases, although the presence of the syndrome without hepatic metastases has been reported [41].

Some of the symptoms are chronic, others appear in the form of attacks. The symptoms appear mostly together, but may also be present separately [83]. They may be classified into three groups.

The flush is the most frequent and most characteristic symptom. It appears in the form of attacks lasting 2 to 10 minutes, first on the face then it spreads to the upper part of the body and to the upper limbs and sometimes to lower limbs. Occasionally, it appears as a slight cyanosis. The hyperaemic area is warm and turns white when pressure is applied. Dyspnoce, tachycardia, headache, nausea and vomiting may occur. The frequency of the symptoms varies; they may appear several times a day, or once or twice weekly and sometimes only at intervals of several months. They are provoked by changes in position, different foods, emotional effects, by palpation of the tumour or of the liver. In chronic cases pigmentation and pellagra-like lesions appear on the skin.

Heart symptoms were first described by Isler and Hedinger [42] and are characterized by hypertrophy and dilation of the right ventricle, pulmonary stenosis, tricuspidal insufficiency and stenosis. All these symptoms are probably the results of a specific fibroplastic endocarditis which is part of the general connective tissue reaction caused by 5-HT [21], but the origin of these symptoms is still a discussed problem. X-rays reveal an enlarged right heart [83]. The ECG is not characteristic; it often indicates a right heart preponderance and sometimes a P-pulmonale. Among the causes of death of carcinoid patients, decompensation of the right heart may occur.

Increased gastrointestinal motility manifests with borborygmus, distention and diarrhoea with thin watery stools sometimes 10 to 20 times a day. It may appear periodically, alternating with constipation. Quite often cramps are experienced around the umbilicus. All these symptoms are caused by the intestinal effect of serotonin directly via the smooth muscles or indirectly via the ganglions [31]. X-ray examination shows accelerated passage. These enteral symptoms are often mistaken for primary diseases of the digestive organs, for example, the liver or pancreas. This was confirmed by one of our cases.

G.L., aged 54, was admitted for a suspected tumour of the pancreas. indicated by ultrasonography and ERCP tests. In May, 1979, she had had myocardial infarction of the anterior wall and first intermittent then constant diarrhoea.

On admission the diarrhoea was unchanged, the patient had lost 40 kg weight, she was in a poor, weak general condition, with ankle oedemas and hypoproteinaemia. After intensive drug treatment and normalization of the hyperproteinaemia exploratory surgery was performed on October 3, 1979. The abdominal cavity was free, examination of the pancreas revealed no tu-

mour. The gallbladder adhered to the hepatic flexure and contained no calculus. The stomach, duodenum, intestines and colon as well as the internal genitals were intact. In the mesenterium there were several enlarged lymph nodes. Histological testing showed acute lymphadenitis.

In the postoperative phase the patient's condition continued to deteriorate. On the third day there was blood in the stools, the oedemas increased and on the eighth postoperative day she died with circulatory failure.

At necropsy, a pea-sized carcinoid tumour was found on the tip of the appendix.

The long-standing diarrhoea, the loss of more than 40 kg weight, the hypoproteinaemia and oedema, all symptoms of the carcinoid syndrome, were assumed to have been elicited by a carcinoid tumour without liver metastases. This case was, at the same time, a warning that though carcinoid tumours are rare, they must be remembered in similar situations.

Oedemas are frequent on the lower limbs and are often painful. They may appear sometimes on the upper limb and face, too. Their cause is a serotonin induced increased permeability of the capillary vessels and a hypoproteinaemia which is part of the syndrome.

Disorders of renal function may also be caused by serotonin. Tubular reabsorption is enhanced, leading to oliguria. Sometimes on standing the urine turns dark red in colour [62].

Liver function tests are often positive, and often the liver is enlarged and there are nodules on its surface.

The prolonged presence of 5-HT causes teleangiectasia on the nose and face and dilation of the veins in the vicinity of the nose and sometimes on the upper limb and the chest. Permanent skin lesions are characteristic of the syndrome. Lasting erythroderma, cyanosis, skin atrophy, brownish-red pigmentation are also parts of the carcinoid syndrome.

With time, the symptoms become more and more frequent and intense and new symptoms may appear. A complete absence of symptoms does not exclude the presence of a carcinoid tumour.

Diagnosis

On the basis of the history and the clinical picture, it is usually impossible to diagnose carcinoids which have not metastasized and do not give rise to endocrine symptoms. It is easier to diagnose the tumour when the syndrome or at least the majority of its symptoms is present. In addition, some tests may help to form the correct diagnosis.

The results of gastrointestinal X-rays including irrigoscopy questionable as the carcinoids are, as a rule, small and situated in the submucosa. They give

smooth, demarcated round filling defects and are more like exophytically growing carcinomas [48]. Since gastric carcinoids are liable to ulceration, a filling surplus corresponding to the ulcerated area will be visible which cannot or, can hardly, be distinguished from a classical ulcer [48]. In differential diagnosis ectopic pancreas, polyps, leiomyoma, fibroma and polypoid carcinoma should be taken into consideration [51]. Carcinoids can be present in any area of the stomach, but occur most often on the lesser curvature of the antrum, corresponding to the presence of argentaffin cells [100]. In the case of carcinoids of the small bowel or the colon, the radiologist has to rely on indirect signs such as a stasis in front of the obstruction, dilated intestinal loops, slow emptying. On the basis of these symptoms it is, of course, impossible to distinguish between carcinoids and other tumours.

The next diagnostic step is gastroscopy. The gastroscopic picture of carcinoid tumours is not characteristic, it is like that of gastric polyps or polypoids. The size of gastric carcinoids varies between 0.2 and 2 cm. Bearing this in mind, when the discovered polyps are not larger, the diagnosis of carcinoid might be considered. The findings should be supported by biopsy. The most suitable technique is to take samples repeatedly from the same place by removing the intact mucous membrane covering the tumour and taking samples also from the deeper (submucous) tissues [35]. Langhans et al. [48] call this procedure buttonhole biopsy. The same is valid for rectoscopy.

Angiography of the superior mesenteric artery might help to diagnose intestinal carcinoids inaccessible to other tests [88]. The vessels around the tumour form a characteristic star [89]. Fluctuations in the width of the lumen, kinking of the vessels and thickenings in the shape of a pearl string due to fibrosis of the wall should be assessed as a general sign of the growth of the tumour [35, 84, 88].

Selective angiography of the hepatic artery serves first of all the detection of metastases. In contrast with the primary tumour, the metastases show intense vascularization, especially in the liver. The presence of strongly vascularized metastases in the liver always ensures the correct diagnosis.

Scintigraphy and sonography of the upper abdomen may help to find metastases in the liver.

With computer tomography experience is still not sufficient to diagnose carcinoids [89].

It is sometimes possible to achieve increased hormone flow from the tumour by means of provocation. This includes changes in temperature, alcohol, mechanical influences on the tumour (liver), administration of sympathomimetic amines, etc. Not more than 1 to 10 μg of intravenously applied adrenaline or noradrenaline is sufficient to produce flush in one or two minutes. A flush can also be elicited by the intravenous administration of reserpine (5 mg) or histamine (0.05 mg).

Increased urinary excretion of 5-HIAA points to the presence of a carcinoid [35, 37, 45]; under physiological conditions the quantity in 24-hour urine amounts to 2 to 10 mg. According to Rózsahegyi [83], 5-HIAA values above 25 mg are pathognomonic for carcinoid. Still the consumption of certain drugs, fruits and vegetables (nuts, strawberry, banana, tomato, etc.) considerably raises 5-HIAA excretion. Nicotine has a similar effect. Consequently, when higher than normal values are obtained the test has to be repeated under conditions which exclude all exogenous factors. Normal 5-HIAA values are not decisive and do not exclude the presence of carcinoid, since on certain days the excreted quantity may be normal. In this case, too, the test has to be repeated. Postoperative 5-HIAA excretion provides information on the effect of the operation.

Therapy

The old theory according to which carcinoids have benign and malignant forms, is no longer valid. It is now generally accepted that all carcinoid tumours have to be considered malignant and this determines at, the same time, the action to be taken: radical surgical removal of the tumour has to be attempted.

A considerable percentage of carcinoids of the appendix are diagnosed only in the course of the histological examination after the patient had been operated on for appendicitis. When in the course of the operation the presence of an argentaffin tumour is suspected an intraoperative histological examination has to be carried out. Has the suspicion been confirmed, the mesenteriolum, too, must be removed, the latter being the site of the first metastases [70]. Has the tumour penetrated the mucosa and is larger than 2 cm or if it has infiltrated the wall of the appendix, hemicolectomy must be performed on the right side [105].

Solitary carcinoids of the stomach, if they are less than 1 cm in diameter will be classified into the group of semi-malignant tumours, despite their infiltrative growth, and it will be sufficient to excise them deep in the intact region. In this case it will be necessary to carry out an intraoperative histological examination of the bounds(?) of the incision. There are cases in which subtotal resection is recommended [33]. When the tumour is larger than 1 cm, it has to be considered malignant since carcinoids of this size form metastases in the regional lymph nodes and haematogenous metastases in the liver [48]. The correct operation in these cases is resection or subtotal resection. Multiple carcinoids in the stomach call for gastrectomy.

Accidentally discovered or symptomless carcinoids of the small bowel and the colon call for resection of the whole affected section and removal of the pertaining mesenterium together with the enlarged lymph nodes.

When the process has caused intestinal paralysis and in the course of the life-saving operation metastases are found in the lymph nodes and the liver, and intraoperative biopsy confirms the presence of a carcinoid, once the state of the patient has normalized, it must be attempted to remove the primary tumour and the accessible metastases. In this way the life of the patient may be prolonged for years.

When the tumour cannot be extirpated or when, after its removal, the carcinoid syndrome persists under the effect of metastases, it must be attempted to reduce the products and outflow of hormonally active components. This is, in fact, the aim of drug therapy. The first trials were performed with serotonin antagonists such as methysergide, pirotifen, cyproheptadine, cinanserin, etc., which relieve first of all the abdominal symptoms. Reserpine and ergotonine were found ineffective. Cortisone derivatives, for example methylprednisolone, often reduce the intensity and incidence of flush [55]. Since even small doses of catecholamines provoke symptoms, sympathetic blocking agents (e.g. phentolamine) are recommended but opinions differ concerning the results [55, 97]. May reported on the favourable effect of ergot alkaloids [55]. Despite the theoretically well-founded indication, the quinine antagonist aprotinin has a negligible effect. Some authors prefer cytostatic treatment. Federlin et al. [26] achieved favourable results with 100 mg per day doses of cyclophosphamide. Some authors called attention to the favourable effects of 5-fluorouracyl and streptozotocin [188, 55], while according to others, cytostatics and radiotherapy fall short of expectations [36, 99].

New possibilities were offered by the drugs affecting 5-HTP metabolism: in both animal experiments and humans fenclonine blocked the formation of 5-HT from tryptophan. Stuidnitz and Waldenström [97] were the first to report therapeutic observations of this type. In some cases the application of the drug is limited by its various side-effects (eosinophilia, psychic disturbances).

Other drugs used in the treatment of patients with carcinoid are diuretics against oedema, heart drugs to support cardiac function, vitamins, nicotinamide to treat the pellagra-like skin lesions attributed to altered tryptophan metabolism.

Despite the manifold therapeutic possibilities, the treatment of patients suffering from carcinoid is unsatisfactory.

Prognosis

Though all carcinoids are considered potentially malignant, their prognosis is better than that of carcinomas, as patients even with extensive metastases may survive for years. On the basis of 2837 cases Godwin [30] compiled

the following five-year survival rate. Unequivocally, the appendix tumours have the highest survival rate (99%). Carcinoids of the gallbladder and of the biliary duct are also among the more benign tumours [17, 85]. In the case of intestinal and ileocoecal carcinoids the five-year survival rate is 40 to 60%, for carcinoids of the colon and of the stomach about 50%, but in the case of carcinoids of the sigmoid only 33%. The five-year survival rate of rectum carcinoids is about 80%. The differences in extension of the tumours are in themselves not enough to explain the discrepancies in survival of patients with carcinoid in various sections of the gastrointestinal tract, neither could the influence of race, sex or age on survival rate be proven.

References

1. Arosen KF, Torp A, Waldenström JG: A case of carcinoid syndrome followed for eight years adter palliative liver resection. Acta Med Scand 199: 328, 1976
2. Balázs M, Kertész T: A vékonybél daganatai (Tumours of the intestine). Orv Hetil 108:1218, 1967
3. Barber PV: Carcinoid tumour of the ampulla of Vater associated with cutaneous neurofibromatosis. Postgrad Med J 52: 514, 1976
4. Barnes TG: Argentaffinoma of the gallbladder. Surgery 32: 723, 1952
5. Berge T, Linell F: Über das Karzinoid-Syndrom. Acta Pathol Microbiol Scand [A] 84: 322, 1976
6. Biró L, Iván É, Szécsényi NL: A carcinoid syndromáról, klinikai eset kapcsán (Carcinoid syndrome related to a clinical case). Orv Hetil 102: 2472, 1961
7. Black WC, Haffner HE: Diffuse hyperplasia of gastric argyrophil cells and multiple carcinoid tunors. Cancer 21:1080, 1968
8. Bohn H, Feyrter F: Karzinoide des Verdauungstraktes. Verh Dtsch Ges. Inn Med 52: 454, 1940
9. Bordi C, Senatore S, Missale G: Gastric carcinoid following gastrojejunostomy Am J Dig Dis 21: 667, 1976
10. Böszörményi E: A carcinoid "flush" eredetéről (The origin of carcinoid flush). Orv Hetil 109: 413, 1968
11. Brenner S, Heinlich H, Widmann M: Carcinoid of the gastrointestinal tract. NY State J Med 69:1337, 1969
12. Brodman HR, Pai BN: Malignant carcinoid of the stomach and distal esophagus. Am J Dig Dis 13: 677, 1968
13. Broicher K, Hienz H: Über das Dünndarmkarzinoid. Gastroenterologie 12: 377, 1974
14. Cassidy MA: Carcinoid syndrome. Proc R Soc Med 24:139, 1930
15—16. Cassidy MA: Carcinoid syndrome. Proc R Soc Med 24: 920, 1930—31
17. Cheek RC, Wilson H: Carcinoid tumors. Curr Probl Surg 5: 31, 1970
18. Chernicoff D, Bukowski RM, Groppe CW, Hewlett JS: Combination chemotherapy for islet cell carcinoma and metastatic carcinoid tumors with 5-fluorouracyl and streptocotocin. Cancer Treat Rep 63: 795, 1979
19. Ciaccio C: Sopra speciali cellule granulose della mucosa intestinale. Arch Ital Anat Embriol 6: 482, 1907
20. Colbert PhM: Primary carcinoids of the ileum and rectum. J Am Med Assoc 236: 2201, 1976
21. Comree JH jr: Carcinoid and carcinoma. Am J Physiol 171: 715, 1952
22. Delmon J, Rampal P: Prostaglandins and carcinoid tumors. Br Med J 4:165, 1975
23. Editoral J: Diagnosis of malignant carcinoid syndrome. Br Med J 3:122, 1975
24. Ernst P, Koch P, Baileu E: Multiplex Dünndarmkarzinoid. Z Aerztl Fortbild (Jena) 73: 448, 1979
25. Erspamer V: Die enterochromaffinen Zellen der Gallenwege in normalen und pathologischen Zuständen. Rendic Sci Farmit 1: 874, 1954
26. Federlin KF, Wosegien H, Ditschuneit E: Verlaufsbeobachtungen bei Carcinoidkranken. Verh Dtsch Ges Inn Med 68: 234, 1962

27. Feyrter F: Über die zahlenmässige Häufigkeit pathologischer Organbefunden beim benignen enteralen Karzinoid. Wien Med Wochenschr 112: 21, 1962
28. Feyrter F: Lehrbuch der speziellen pathologischen Anatomie. De Gruyter und Co., Berlin 1969
29. Genvain M, Imre J, Tószegi A: Ileum-elhalással járó aregentaffin (carcinoid) tumour metastasis (Argentaffinoma (carcinoid) associated with ileum-necrosis). Orv Hetil 118: 640, 1977
30. Godwin JD: Carcinoid tumors. Cancer 36: 560, 1975
31. Gramlich F, Wiethoff FO: Karzinoide des Verdauungstrakter. Dtsch Med Wochenschr 85:1750, 1960
32. Hamprel H: Über argyrophile Zellen. Virchows Arch [Pathol Anat] 321: 482, 1952
33. Harris AI, Greenberg H: Pernicious anemia and the development of carcinoid tumors of the stomach. J Am Med Assoc 239:1160, 1978
34. Hay DJ, Curt JRN: Carcinoid tumors as a complication of ulcerative colitis. Postgrad Med 55: 430, 1979
35. Hedinger C: Karzinoide des Verdauungstraktes. Herkunft, Entwicklung und Komplikationen. Helv Chir Acta 40: 701, 1972
36. Heer K: Das Karzinoid des Magen-Darm-Traktes. Med Welt 26: 644, 1975
37. Hermanek P, Decker P: Carcinoide des Gastrointestinaltraktes. In: Indikation zur Operation, eds Heberer G, Hegeman G, Springer Verlag, Berlin 1974
38. Honig LJ, Weingarten G: A gastric carcinoid with massive bleeding. Am J Gastroenterol 61: 40, 1974
39. Hui K, Reza MJ, Busuttli RW: An unusual cause of massive gastrointestinal hemorrhage. Carcinoid tumor of the ileum. J Am Med Assoc 23: 2690, 1978
40. Ihász M, Füsy J, Erdős L: A vékonybél jó- és rosszindulatú daganatai (Benign and malignant tumours of the intestine). Orvosképzés 41: 260, 1966
41. Imre J: A carcinoid syndromáról (The Carcinoid syndrome). Orv. Hetil 105: 272, 1962
42. Isler P, Hedinger C: Metastasierendes Dünndarmkarzinoid mit schwerem, vorwiegend das rechte Herz betreffenden Klappenfehler und Pulmonalstenose —ein eigenartiger Symptomenkomplex. Schweiz Med Wochenschr 83: 4, 1953
43. Karsai Gy, Korányi A: Argentaffinoma okozta új klinikai syndroma (A new clinical syndrome induced by argentaffinoma.) Orv Hetil 96: 550, 1955
44. Kähler HJ: Das Karzinoid. Springer Verlag, Berlin 1967
45. Kähler HJ: Über das Karzinoidsyndrom. Chirurgie 38: 456, 1967
46. Kelényi G: A gyomor-bélrendszer carcinoid tumorairól (Carcinoid tumours of gastrointestimal tract). Orv Hetil 98: 1447, 1957
47. Kuiper DH, Graice AW, Pollard HM: Twenty years of gastrointestinal carcinoids. Cancer 25:1424, 1970
48. Langhans P, Clemes M, Schönleben A, Schlake W, Bassewitz DB: Das multiple Magencarcinoid. Chirurgie 49: 401, 1978
49. Lattes R, Grossi C: Carcinoid tumors of the stomach. Cancer 9: 698, 1950
50. Lemmer KE: Carcinoid tumours of the stomach. Surgery 12: 378, 1942
51. Luca RF, Ferrer JP, Gambescia RA, Raskin JB: Gastric carcinoid endoscopically simulating leiomyoma. Gastroenterology 70:163, 1978
52. MacDonald RA: A study of 356 carcinoids of the gastrointestinal tract. Am J Med 21: 867, 1956
53. Maempel PZ, Modlin I: Diagnosis and management of a gastric carcinoid tumour with hepatic metastases. Br J Surg 65: 516, 1978
54. Martin ED, Potet F: Carcinoid tumors of the stomach. Clin Gastroenterol 3: 511, 1974
55. May B: Karzinoid: Diagnostik und Therapie. Dtsch Med Wochenschr 100: 2163, 1975
56. Magyar F, Molnár J: A féregnyúlvány carcinoidról (The appendix carcinoid). Magy Seb 25:171, 1972
57. Máthé Z, Kisfaludy S, Potondi A: Halálos carcinoid krízis (Fatal carcinoid crisis.) Magy Belorv Arch 21:172, 1968
58. Moertel CG, Sauer WG, Dockerty MB, Baggenstoss AH: Life history of the carcinoid tumor of the small intestine. Cancer 14: 901, 1961
59. Morson BC: Pathology of the gastro-intestinal tract. Springer Verlag, Berlin 1976
60. Müller B, Charmion J: Contribution à l'étude des carcinoïdes de l'estomac. J Med Lyon 39: 247, 1958
61. Nizze H: Über das Karzinoid der Gallenblase. Zentralbl Allg Pathol 117: 61, 1973

62. Noble NR: Carcinoid tumours. Med J Aust 36: 589, 1961
63. Oates JA, Pettinger WA, Doctor RB: Evidence for the release of bradykinin in carcinoid syndrome. J Clin Invest 45:173, 1960
64. Oates JA, Sjoerdsma A: A unique syndrome associated with secretion of 5-hydroxytryptophan by metastatic gastric carcinoids. Am J Med 32: 333, 1962
65. Obendorfer G: Dünndarm-Karzinoid. Frankf Z Pathol 1: 426, 1907
66. Ondrejka P, Jakab F, János M, Benyó I: Masszív vérzést okozó gyomor-carcinoid operált esete (Operated case of gastric carcinoid causing massive haemorrhage). Magy Seb 39: 402, 1978
67. Ortiz H, Ortega JS, Bernát R, Sitges A: Carcinoids of the first part of the duodenum. Br J Surg 63: 235, 1976
68. Örlős I, Korényi BA: Carcinoid tumorokról (Carcinoid tumours). Morphol Igazságügyi Orv Szle 7: 224, 1967
69. Palkoska F, Schober KL: Karzinoid im Magen. Zentralbl Gynaekol 98: 1084, 1976
70. Papp Gy, Illés T: Az appendix tumorairól (The tumours of the appendix). Magy Seb 13: 297, 1960
71. Patzold K: Zum klinischen Bild des endokrin inaktiven Dünndarmkarzinoids. Z Ges Inn Med 33: 660, 1978
72. Pearse AGE: Common cytochemical and ultrastructural characteristics of cells producing polypeptide hormones (the APUD series) and their relevance to thyroid and ultimobranchial C-cells and calcitonin. Proc R Soc Lond [Biol] 170: 71, 1968
73. Peiper HJ, Creutzfeld W: Das multiple Magen-Karzinoid. Chirurg 46: 194, 1975
74. Petrás S, Krutsky M: Rosszindulatú vékonybél daganatok osztályunk 5 éves anyagában (Malignant intestinal tumours in a five-year material). Orv Hetil 119: 31, 1978
75. Pilz E: Über ein Karzinoid des Ductus choledochus. Zentralbl Chir 88: 1588, 1961
76. Postlethwait RW: Gastrointestinal tumors. Postgrad Med 40: 445, 1966
77. Qizilbasch AH: Carcinoid tumors, vascular elastosis and ischemic disease of the small intestine. Dis Colon Rectum 20: 554, 1977
78. Quan SHO, Bader E, Berg JW: Carcinoid tumors of the rectum. Dis Colon Rectum 7:197, 1964
79. Rappart MM, Green MA, Page IH: Carcinoid tumors. J Biol Chem 174: 735, 1948
80. Reifferscheid M: Der Dickdarmpolyp. Enke Verlag, Stuttgart 1959
81. Reifferscheid M: Darmchirurgie. Thieme, Stuttgart 1959
82. Rózsa I, Lengyel E, Kiss I: Synchrones Vorkommen von Kolonkarzinoid und Karzinom. Zentralbl Chir 101: 804, 1976
83. Rózsahegyi I: Carcinoid syndroma (Carcinoid syndrome). In: Ritka kórképek ed. Braun P, Medicina, Budapest 1964
84. Sanders RJ: Carcinoids of the gastrointestinal tract. Thomas, Springfield. Ill 1973
85. Sanders RJ, Extell HK: Carcinoids of the gastrointestinal tract. Surg Gynecol Obstet 119: 56, 1964
86. Sauer GW, Dearing WH: Carcinoid tumors of the stomach. Gastroenterology 34: 214, 1958
87. Schmidt JE:Beiträge zur normalen und pathologischen Histologie einiger Zellarten des menschlichen Darmkanals. Arch Mikrobiol Anat 66:12, 1905
88. Schmidt KR, Pfeifer KJ, Splesberg F: Entwicklung und Therapie des Karzinoids. Strahlentherapie 153: 668, 1977
89. Schmidtler F, Spelsberg F, Schmidt KR, Pfeifer KJ: Karzinoide des Verdauungstrakts. Münch Med. Wochenschr 112: 597, 1979
90. Schwesinger G: Das Karzinoid der Gallenwege. Z Aerztl Fortbild 72: 796, 1978
91. Scoma JA, Diego S: Carcinoid tumors of the rectum. Am J Surg 135: 708, 1978
92. Scaane P, Bide RJ: Malignant appendiceal carcinoid with intussusception of the base manifesting as a cecal tumor. Dis Colon Rectum 20: 511, 1977
93. Smith A, Nyhus L, Dagleish C: Further observations on the endocrine aspects of argentaffinomas. Scot Med J 2: 24, 1957
94. Soga J, Tazawa K: Pathologic analysis of carcinoids. Histologic re-evaluation of 62 cases. Cancer 28: 998, 1971
95. Sperlinger P, Röding H: Karzinoid der Papilla Vateri. Zentralbl Chir 105: 1069, 1980
96. Stewart WH, Barlett RM: Carcinoid tumors of the small intestine. Ann Surg Suppl 154:112, 1961

97. Stuidnitz W, Waldenström J: Pharmakologische und therapeutische (p-Chlorphenylalanin) Studien über das Carcinoidsyndrom bei 11 Fällen. Klin Wochenschr **49**: 748, 1971
98. Szappanos M: Carcinoid tumorokról (Carcinoid tumours). Orv Lapja 1: 3, 1947
99. Teitelbaum SL: Diagnosis of carcinoid syndrome. Am J Surg 123: 564, 1972
100. Thompson NW, Coon WW: Carcinoid of the stomach. Am J Surg 108: 798, 1964
101. Zakharia AT: Rectal carcinoid. A review of the literature and report of three new cases. Arch Surg 98: 8, 1969
102. Zammit M, Modlin I: Carcinoid tumors of the gastrointestinal tract. Br J Surg 65: 516, 1978
103. Zeitlin IJ, Smith AN: The gastrointestinal carcinoid and the carcinoid syndrome. Lancet *ii*: 986, 1966
104. Wallacher L: Az emésztőtractus carcinoidjairól (Carcinoids of the digestive tract). Orv Közl 1: 53, 1965
105. Warkel RL, Coopher PhH, Helwing EB: Adenocarcinoid of the appendix. Canrec 42: 2793, 1978
106. Warren KW, Coyle EB: Carcinoid tumors of the gastrointestinal tract. Am J Surg 82: 372, 1951

Chirurgische Beziehungen der karzinoiden Tumoren des gastrointestinalen Trakts

M. Ihász, Márta Balázs, A. Csillag, K. Szabó und F. Horkai

Die im 10jährigen Krankengut im gastrointestinalen Trakt vorgekommen karzinoiden Tumorfälle werden erläutert. Damit im Zusammenhang finden Pathophysiologie, Symptomatologie, diagnostische Probleme, chirurgische und medikamantöse Behandlung sowie die Prognose des Krankheitsbildes eine ausführliche Besprechung.

Хирургические аспекты карциноидных опухолей гастроинтестинального тракта

М. ИХАС, МАРТА БАЛАЖ, А. ЧИЛЛАГ, К. САБО и Ф. ХОРКАИ

Авторы знакомят с собственным материалом, собранным за 10 лет по поводу карциноидных опухолей желудочно-кишечного тракта. Обсуждают вопросы патофизиологии, симптоматики, диагностики, хирургического и лекарственного лечения, а также прогноза данного заболевания.

Dr. Mihály Ihász
Dr. Márta Balázs
Dr. Antal Csillag
Department of Surgery, Municipal János Hospital, Budapest, Diósárok út 1, H-1125

Dr. Károly Szabó
Dr. Ferenc Horkai
2nd Department of Surgery, Semmelweis University Medical School, Budapest, Nagyvárad tér 1, H-1096

Acta Chirurgica Academiae Scientiarum Hungaricae, Tomus 23 (2), pp. 117—126 (1982)

Simultaneous Occurrence of Graves' Disease with Endocrine Ophthalmopathy. Thyroiditis and Thyroid Carcinoma

G. Csáky[1], Gy. Balázs[1], G. Lukács[1], M. Szokol[2], I. Erdei[2], Cs. Balázs[2] and Éva Kincses[3]

1st Department of Surgery[1], Institute of Pathology[2], and Department of Ophthalmology[3], University Medical School, Debrecen, Hungary

(Received December 17, 1980)

The simultaneous occurrence of Graves' disease with ophthalmopath y lymphocytic and subacute de Quervains' thyroiditis has been observed in two male patients suffering from follicular-type thyroid carcinoma. In one of them Sjögren syndrome and a mild form of diabetes were also diagnosed. It is assumed, on the basis of indirect evidence, that the humoral and cellular lesions determined by genetic factors and influenced by prolonged thyrostatic and steroid treatment are jointly responsible for tumour genesis.

Graves' disease and Hashimoto's thyroiditis are classified as autoimmune diseases, although increased thyroid antibody titres and thyroiditis are frequently revealed in cases of thyroid carcinoma as well [1, 2, 3, 4]. Still, similarly as in immune diseases, where the circumstances of the induction of autopathogenic lymphocytes triggering the pathological course are unknown, it is unclear whether or not thyroid cancer can be induced in chronic thyroiditis [5].

The association of Graves' disease with endocrine ophthalmopathy and Hashimoto's thyroiditis [6], thyroid carcinoma and chronic thyroiditis [7], and on the other hand, the joint occurrence of Graves' disease and thyroid tumour [8] have been encountered on more than one occasion, the present paper is, nevertheless, one of the first to report on patients in whom thyroid carcinoma, thyroiditis, and thyrotoxicosis associated with endocrine ophthalmopathy were diagnosed simultaneously.

Material and Methods

The diagnosis of Graves' disease was based, beside clinical symptoms [9] on laboratory tests such as serum cholesterol; T_3 uptake (modified Hamolsky's test); TSH radioimmune-assay (Byk-Mallinkrodt); T_3 RIA (RCC Amersham); PBI; LATS determination; ^{131}I uptake and thyroid gland scanning; T_3 suppression test; TRH–TSH stimulation test; as well as on histological examinations.

Thyroiditis was diagnosed by laboratory examinations (estimation of antibody titre against nuclear factor, microsomal-, thyroglobulin-, and retrobulbar muscle antigen with tanned red cell technique), needle biopsy, and histological examinations [4]. The rheumatoid factor was determined with the Rose and Latex tests. Determination of lymphoblastic transformation against phytohaemagglutinin-P (Difco Laboratories) and human thyroglobulin was carried out by the modified Hadden liquid-scintillation technique [11], and HL–A typifying was performed by the NIH lymphocytotoxicity micromethod.

Endocrine ophthalmopathy was scored according to Werner's grouping [12].

DNA estimation was performed by cytofluorimetry [13].

Case Reports

Case 1, a 51-year-old male patient was referred to us with the suspicion of a thyroid tumour. His complaints had begun four months before when after a sudden thyroid enlargement he had had diarrhoea, heat-intolerance, nervousness, tremor. Loss of weight (10 kg) and exophthalmos had developed. Because of signs of thyrotoxicosis he had taken methimazole for three months. On admission (December 1977), a remarkably compact goose egg-size resistance could be palpated in the right lobe of the thyroid, but the left lobe was also moderately enlarged and compact. Along the right sternocleidomastoid muscle three bean-sized lymph nodes were noticed. By Werner's grouping: right eye: 2c, 3c, 4a, left eye: 2b, 3b, 4a alterations could be observed. Exophthalmos: right eye: 21 mm, left eye: 21.5 mm (Fig. 1). The scintigram of the right lobe showed decreased activity, and a needle biopsy from this area revealed thyroiditis. Pulse: 114 per min. Warm, wet skin, tremor. Serum cholesterol: 141 mg per dl; T_3 uptake: 1.32; PBI: 10.6 μg per dl; TSH RIA: 1.2 μUI per ml; ^{131}I uptake: 2 h: 50.7%, 24h: 76.2%, non-suppressible; LATS: positive; We: 24 per 50 mm/h. Antibodies against nuclear factor, microsomal antigen, thyroglobulin and retrobulbar muscle antigen: negative; Rose, Latex: negative: HL–A typing: A: 2, 9, B: 14, 35. Lymphoblastic transformation index: PHA: 7.4, Htg: 2.9. Because of the suspicion of malignancy, after preparation with Lugol solution an operation was performed. The intraoperative quick-freezing histological examination of the material removed from the right lobe revealed only lymphocytic thyroiditis and nodose colloid micro- and normofollicular struma. On the right side lobectomy and excision of lymph nodes, on the opposite side subtotal resection were carried out. In the course of the final histological serial examination, we found in some areas hyperfunctioning tissue formation, and, besides severe lymphocytic thyroiditis, well-differentiated

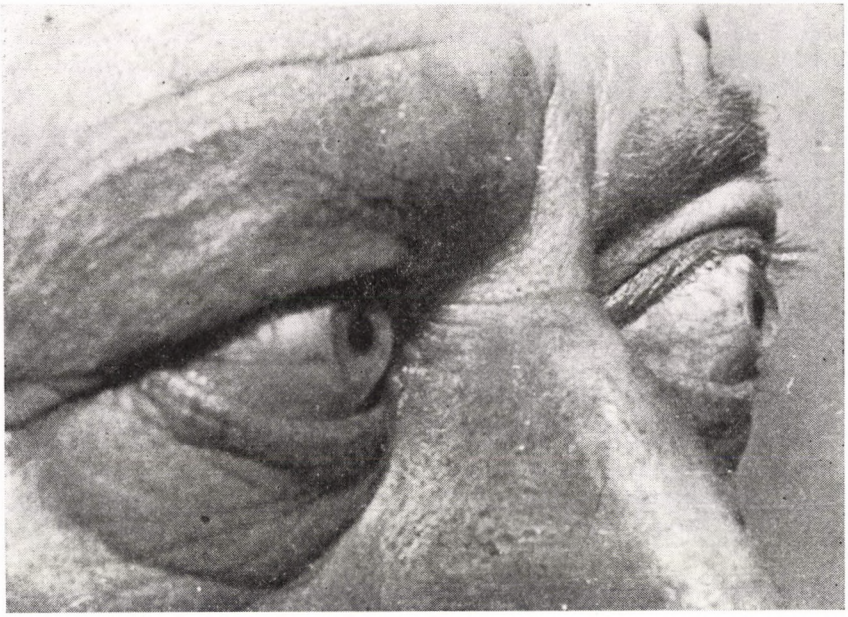

FIG. 1. Eye signs in Case 1

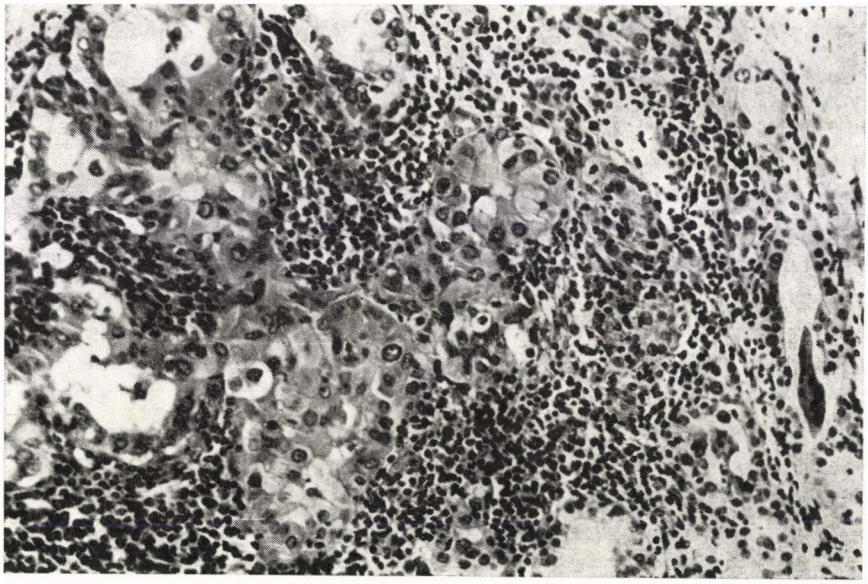

FIG. 2. Intensive lymphocytic infiltration between follicles and solid foci of carcinoma

follicular-type thyroid carcinoma with lymph node metastases (Figs 2, 3). In the subtotally resected left lobe there was no tumour. Cytofluorimetry showed a 68.2% increase in DNA content as compared to the normal thyroid

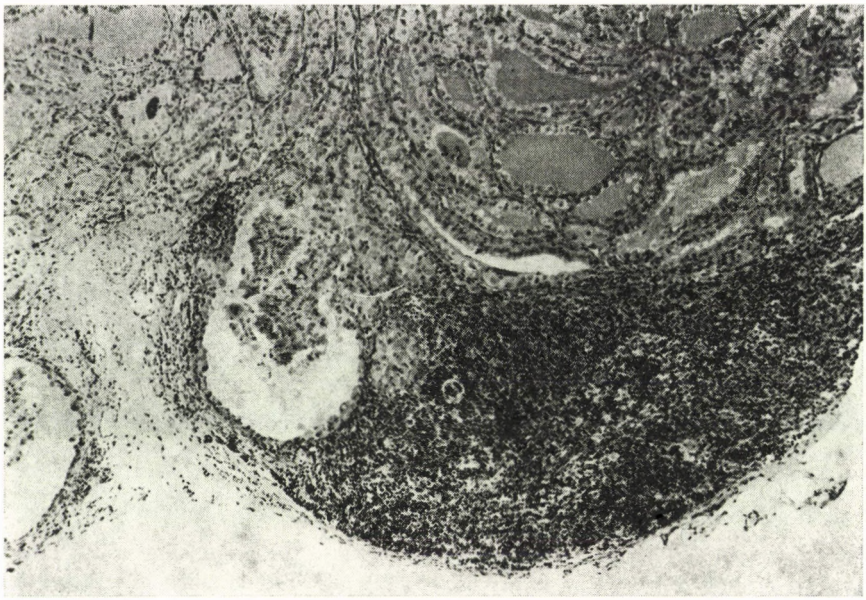

FIG. 3. Metastases of follicular thyroid carcinoma in a cervical lymph node

cell population. Since an undisturbed postoperative course of the disease, the patient has been regularly taking thyroid hormone. He has no complaints and the laboratory results have come near to normal. Local recurrence of tumour or regional lymph node and distant metastases cannot be found, ophthalmological examinations show no progression.

Case 2, a 43-year-old male patient had in 1972 exophthalmos on the right side; it disappeared spontaneously after some months. For polyuria and polydipsia the patient was examined in 1973 without any positive finding. Because of polyarthralgia he was treated for 3 weeks in 1975. Sjögren's syndrome and Hashimoto's thyroiditis were diagnosed in 1976, then later endocrine ophthalmopathy and thyrotoxicosis developed. On admission in January 1978: Pulse: 108/min. Tremor and hyperkinesis. ^{131}I uptake: 2 h: 34%, 24 h: 65%, non-suppressible. TSH RIA basal: 4.1 μUI/ml. On 200 μg TRH injection: TSH RIA max.: 4.9 μUI/ml. Serum cholesterol: 175 mg/dl; PBI: 6.5 μg/dl; T_3 RIA: 2.8 μg/ml. LATS: positive. No increase of anti-thyroid antibody titre was observed. Rose, Latex: negative. HL–A typing: A: 9, 10, B_w: 15, B: 35. Lymphoblastic transformation index: PHA: 6.8, Htg: 2.1. Scintigram: defective activity in the lower pole of the left lobe. Needle biopsy from this area: thyroiditis. Fasting blood sugar test: 161 mg/dl, glucose tolerance test: diabetoid curve. State of eyes: right: 2c, 3c, 4a, left: 2c, 3c, 4b (Fig. 4). Exophthalmos: right: 22 mm, left: 21 mm. Schirmer test: right eye: 2 mm/5', left eye: 3 mm/5', lacrimal output normal. Both lobes of the thyroid



FIG. 4. Eye signs in Case 2

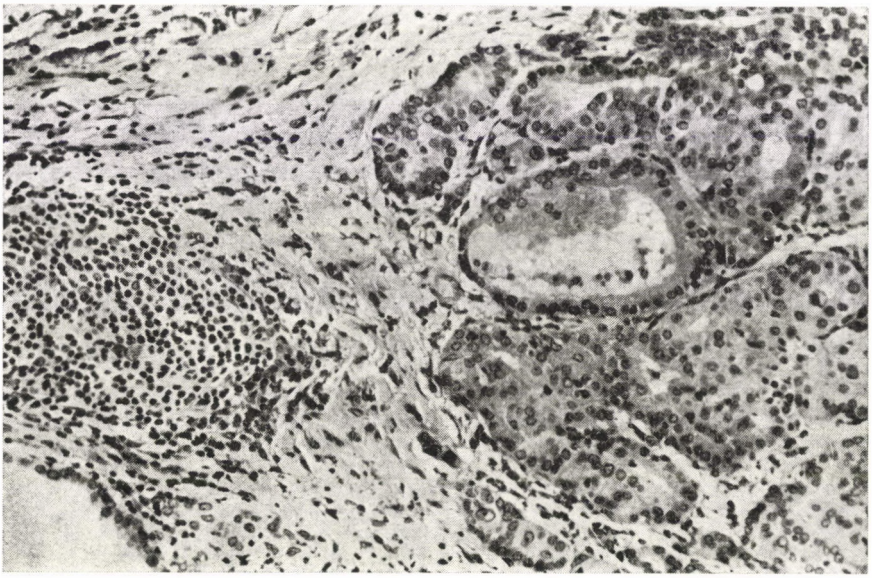

FIG. 5. A mass of lymphocytic and follicular carcinoma in the fibrotic substance of the thyroid gland

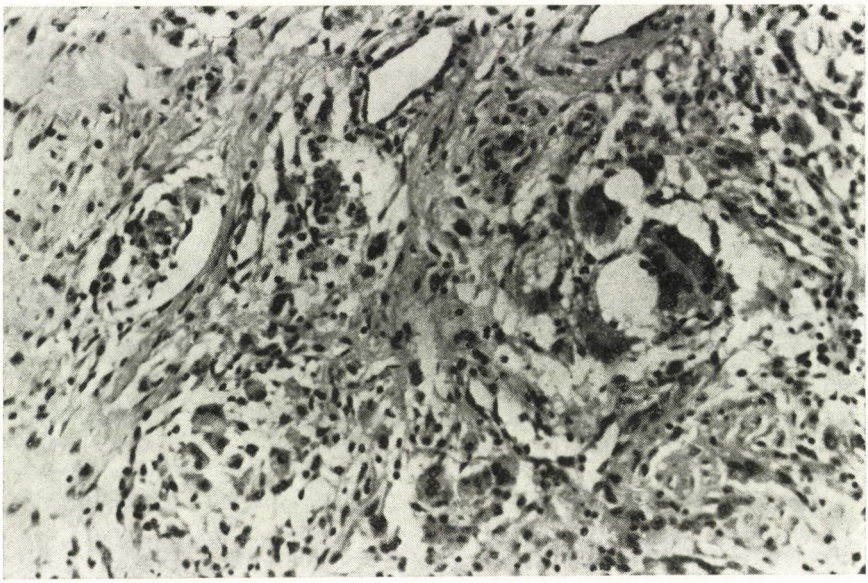

FIG. 6. Granulomatous foci containing foreign body giant cells, in other areas in subacute de Quervain's thyroiditis

are greatly enlarged, compact and nodular. Since methimazole, triiodothyronine and steroid treatment for nine months was ineffective, the patient was subjected to surgery. Histological examination of a specimen from the left lobe showed lymphocytic thyroiditis, so cuneiform portions were cut out from both lobes. As these showed chronic strumitis, in some places with granulomatous transformation of subacute de Quervain's thyroiditis and follicular carcinoma with an 87.7% increase in DNA content of the tumour cells, total removal of the left lobe and subtotal resection of the right one was performed. In the specimens there were no signs of malignancy (Figs 5, 6). After an eventless postoperative course the patient received thyroid hormone substitution, but in spite of this, symptoms of hypothyroidism developed. At a control check-up in November, 1979, TSH RIA was 10.1 μUI/ml; PBI: 2.8 μg/dl; T_3 uptake: 0.86. Tumour recurrence was not observed and there was no progression in the status of the eyes.

Discussion

Opinions differ on the significance of the HL–A antigens frequently present in autoimmune diseases of the thyroid gland and other organs (Addison's disease, Sjögren's disease, insulin-dependent diabetes mellitus, rheumatoid arthritis, etc.) [14, 15, 16], but it is generally accepted that cell-mediated

auto-immunity has a primary role in the development of Hashimoto's thyroiditis and Graves' disease [17, 18]. Presumably, owing to the decreased function of suppressor T cells, the plasma cells transformed from B cells produce an increased amount of antibodies of immunoglobulin nature [19]. Thyroglobulin and microsomal antibodies can be detected in 97% of untreated patients with Hashimoto's thyroiditis, in two-thirds of those with Graves' disease, and in 32% of the cases of thyroid carcinoma [1], although in thyrotoxicosis and thyroid carcinoma the lymphocytic infiltration is mostly focal. On the basis of the antibody titres, benign and malignant processes cannot be distinguished [20].

Polyarthritis, diabetes mellitus, Sjögren's syndrome and the autoimmune diseases of the thyroid, diagnosed in our second patient suggested the possibility of a common genetic origin. In subacute de Quervain's thyroiditis the frequently noticed HL–A B35 also supports this views. At the same time, we failed to find any antithyroid antibodies in spite of the definite lymphocytic infiltration and the de Quervain-type granulomatous transformations. Thus, inflammatory changes had probably occurred in the salivary glands and the retrobulbar connective tissue.

In both patients a thyrotoxicosis with ophthalmopathy was verified on the basis of the clinical picture and the laboratory examinations. There was LATS positivity, and the thyroid proved to be non-suppressible in the course of ^{131}I uptake. Thyrotoxicosis may be associated with a decrease ^{131}I uptake [21] also in subacute thyroiditis. In our cases the tissue changes were caused by lymphocytic thyroiditis and de Quervain-type subacute thyroiditis, the features characteristic of thyroiditis could have developed only in an atypical way.

Hirabayashi and Lindsay [7] and Dailey et al. [22], in contrast with Crile and Hazard [3] established a close connection between chronic thyroiditis and thyroid carcinoma. The divergent results can partly be ascribed to the differences in the way pathologists judge the characteristics of thyroiditis (focal-diffuse, lymphoid infiltration-lymphoid follicle formation) [5]. On the other hand, the methods of sampling (needle biopsy, open biopsy subtotal resection, lobectomy) were also different. The most distinct lymphocytic infiltrations could be observed around the benign papillary-type carcinomas, but long-term survival and the absence of distant metastases in the case of intrathyroid localization were interpreted by the particular biological behaviour of papillary-type carcinomas displaying fairly good antigenic properties rather than by the protective effect of thyroiditis. Considering chronic thyroiditis to represent a premalignant condition, some researchers suppose that carcinoma may develop from a proliferation of epithelial cells [7, 22]. Others refuse this view and, assuming that lymphocytic thyroiditis was a secondary feature, believe that the tissue changes caused by the carcinoma involve

antibody production and lymphocytic infiltration in consequence of their antigenicity [23]. There are many similarities in the pathogenesis of Graves' disease and Hashimoto's thyroiditis, and some authors suppose that the differences between the conditions are only in degree. Other authors, who regard the two processes to be contradictory in nature, are of the opinion that stimulation is characteristic of Graves' disease, while tissue destruction of chronic thyroiditis [24]. It is worth mentioning in connection with our second patient that Zulman et al. [25] found in 6 salivary glands of 9 patients with Sjögren's syndrome the evolution of a tumour with monoclonal B cells on the grounds of benign polyclonal lymphoproliferative changes.

The ratio of carcinomas occurring in thyrotoxicosis with endocrine ophthalmopathy is 0.15–9% [26]. An unexpected number of carcinomas can be detected in single adenomas (Hamburger 27); in cold nodules 10–35% malignant transformations [4, 28] can be reckoned with. Livadas et al. [29] found carcinoma in cold nodules in 21.5% of patients with hyperthyroidism. As to the tumours discovered in thyrotoxicosis, Rosen et al. [23] believes the tumour itself may cause signs of hyperfunction by destruction of healthy thyroid tissue, releasing normal and abnormal thyroid hormones and secreting them into the circulation. Previous X-ray irradiation had not been mentioned in the history of any of our patients. Searching for the possible cause of tumour development, beside mere coincidences, it may be ascribed to the intermittent epithelial proliferation induced by THS, which might result from methymazole treatment which has a papillarizing effect. In our cases, however, the immunosuppressive effect of the steroid administered for the ophthalmopathy was not negligible either. It ensured a suitable milieu for the persistence of tumour cells originating from abnormal mitoses. An elevated DNA level was found by cytofluorimetry in the tumour tissue, but concomitant thyroiditis might also produce the same result. There is no explanation for the differences in DNA content noticed in papillary- and follicular-type thyroid carcinomas as well as in thyroiditis, neither do we have a uniform interpretation for the significance of immunity in Graves' disease and for the spontaneous antitumour immunity occurring mainly in papillary-type thyroid carcinomas [30, 31, 32].

Indication for surgery was provided by the unsuccessful thyrostatic treatment and the suspicion of malignancy. We think it typical that the substances obtained from the suspicious area by needle biopsy and the specimens removed intraoperatively and examined by a highly skilled pathologist did not disclose a malignant process, and it was only the final serial histological examination that provided the correct diagnosis. In such cases needle biopsy has not proved to be an infallible method.

In summary, in our cases the genetic determination could be ascertained on the basis of indirect evidence. It is supposed that cellular and humoral

immunoreactions under the influence of thyrostatics and steriods administered for a long time, caused such tissue and hormonal changes that allowed the survival of tumorous cells proliferating as a consequence of abnormal mitoses.

Acknowledgement

Thanks are due to Mrs E. Stenszky for HL–A typing.

Refecences

1. Roitt IM, Doniach D: Thyroid auto-immunity. Br Med Bull 16:152, 1960
2. Kalderon AE, Bogaars HA: Immune complex deposits in Graves' disease and Hashimoto's thyroiditis. Am J Med 63: 729, 1977
3. Crile G jr, Hazard JB: Incidence of cancer in struma lymphomatosa. Surg Gynecol Obstet 115:101, 1962
4. Doniach D, Roitt IM: Autoimmune thyroid disease. In: Textbook of Immunopathology, eds Miescher PA, Müller–Eberhard HJ, Grune and Stratton, New York–London 1969, Vol. II, p. 516
5. Holmes HB jr., Kreutner A, Obrien PH: Hashimoto's thyroiditis and treatment Gynecol Obstet 144: 887, 1977
6. Buchanau WW, Alexander WD, Crooks J, Koutras DA, Wayne EJ, Anderson JR, Goudie RB: Association of thyrotoxicosis and autoimmune thyroiditis. Br Med J 1: 843, 1961
7. Hirabayashi RN, Lindsay S: The relation of thyroid carcinoma and chronic thyroiditis. Surg Gynecol Obstet 121: 243, 1965
8. Olen E, Klinck GH: Hyperthyroidism and thyroid cancer. Arch Pathol Lab Med 81: 531, 1966
9. Crooks J, Murray JPC, Wayne EJ: Statistical methods applied to the clinical diagnosis of thyrotoxicosis. Ouart J Med 28: 211, 1959
10. McKenzie JM, Williamson A: Experience with the bioassay of the long-acting thyroid stimulator. J Clin Endocrinol Metab 26: 518, 1966
11. Balázs Cs, Leövey A, Szerze P, Bordán L, Kovács L: Investigation of a suppressor T cell function in Graves' disease. Biomedicine (in press)
12. Werner SC: Modification of the classification of the eye changes of Graves' disease: Recommendations of the ad hoc committee of the American Thyroid Association. J Clin Endocrinol Metab 44: 203, 1977
13. Fujita S: DNA constancy in neurons of the human cerebellum and spinal cord as revealed by Feulgen cytophotometry and cytofluorimetry. J Comp Neurol 155: 195, 1974
14. Irvine WJ, Gray RS, Morris PJ, Ting A: Correlation of HLA and thyroid antibodies with clinical course of thyrotoxicosis treated with antithyroid drugs. Lancet ii: 898, 1977
15. Bech K, Nerup J, Thomsen M, Platz P, Ryder LP, Svejgaard A, Siersboek–Nielsen K: Hausen JEM: Subacute thyroiditis de Quervain: a disease associated with a HLA-B antigen. Acta Endocrinol (Kbh) 86: 504, 1977
16. Bech K, Lumholtz B, Nerup J, Thomsen M, Platz P, Ryder LP, Svejgaard A, Siersboek–Nielsen K, Hausen JM, Larsen JH: HLA antigens in Graves' disease. Acta Endocrinol (Kbh) 86: 510, 1977
17. Volpé R: The immunologic basis of Graves's disease. N Engl J Med 287: 463, 1972
18. Folb PI, Bank H: Evidence for an active immune response in acute hyperthyroidism (Graves' disease). Am J Med Sci 272: 269, 1976
19. Broder S, Waldmann TA: The suppressor-cell network in cancer. N Engl J Med 299: 1281, 1978
20. Nataf BM: Experimental research on thyroid cancer. Ann Radiol (Paris) 20: 703, 1977
21. Woolf PD, Daly R: Thyrotoxicosis with painless thyroiditis. Am J Med 60: 73, 1976
22. Dailey ME, Lindsay S, Skahen R: Relation of thyroid neoplasms to Hashimoto disease of the thyroid gland Arch Surg 70: 29, 1955
23. Rosen IB, Strawbridge HG, Walfish PG, Bain J: Malignant pseudothyroiditis: a new clinical entity. Am J Surg 136: 445, 1978

24. Buckingham BA, Costin G, Kogut MD, Isaacs H, Landing BH: Pathologic and immune factors in thyroid disease. J Pediatr 91: 728, 1977
25. Zulman J, Jaffe R, Talal N: Evidence that the malignant lymphoma of Sjögren's syndrome is a monoclonal B-cell neoplasm. N Engl Med 299:1215, 1978
26. Shapiro SJ, Friedman NB, Perzik SL, Catz B: Incidence of thyroid carcinoma in Graves' disease. Cancer 26:1261, 1970
27. Hamburger JI: Solitary autonomously functioning thyroid lesions. Am J Med 58: 740, 1975
28. Katz AD, Bronson D: Total thyroidectomy. Am J Surg 136: 450, 1978
29. Livadas D, Psarras A, Koutras DA: Malignant cold thyroid nodules in hyperthyroidism. Br J Surg 63: 726, 1976
30. Williams ED, Doniach J, Bjarnason O, Michie W: Thyroid cancer in an iodide rich area. Cancer 39: 215, 1977
31. Amino N, Pysher T, Cohen EP, De Groot LJ: Immunologic aspects of human thyroid cancer. Humoral and cell mediated immunity, and a trial of immunotherapy. Cancer 36: 963, 1975
32. Christov K, Thomas C, Sandritter W: DNA measurements on cell nuclei of normal proliferating and neoplastic thyroid tissues in rats. Neoplasma 22: 285, 1975

Gleichzeitiges Vorkommen mit endokriner Ophthalmologie einhergehender Graves-Krankheit, Thyreoiditis und Schilddrüsenkarzinom

G. Csáky, Gy. Balázs, G. Lukács, M. Szokol, I. Erdei, Cs. Balázs und Éva Kincses

Bei zwei, an Schilddrüsenkarzinom follikulären Typs leidenden Patienten war das gleichzeitige Vorkommen einer mit endokriner Ophthalmologie einhergehenden Graves-Krankheit und einer lymphozytären bzw. Quervain-Thyreoditis zu beobachten. In einem der Fälle entwickelten sich auch milder Diabetes sowie Sjörgen-Syndrom. Die indirekten Beweise scheinen dafür zu sprechen, daß für die Tumorgenese die durch die genetischen Faktoren determinierten und durch die thyreostatische bzw. Steroiddauerbehandlung beeinflußten humoralen bzw. zellulären Veränderungen, gemeinsam verantwortlich sind.

Одновременное наличие сопровождающейся эндокринной офтальмопатией болезни Graves, тиреоидита и карциномы щитовидной железы

Г. ЧАКИ, ДЬ. БАЛАЖ, Г. ЛУКАЧ, М. СОКОЛ, И. ЭРДЕИ, Ч. БАЛАЖ и Э. КИНЧЕШ

Авторы наблюдали одновременное наличие сопровождающейся офтальмопатией болезни *Graves* и лимфоцитарного тиреоидита, или тиреоидита *de Quervain*, у двух пациентов-мужчин с карциномой шитовидной железы фолликулярного типа. У одного из больных обнаружили кроме того слабый диабет и синдром *Sjögren*. На основании косвенных доказательств авторы полагают, что за генез опухоли ответственна совокупность гуморальных и клеточных изменений, предопределенных генетическими факторами и находившихся под продолжительным влиянием тиреостатической и стероидной терапии.

Dr. Gergely Csáky
Dr. György Balázs
Dr. Géza Lukács
1st Department of Surgery, University Medical School, Debrecen, Pf. 27, H-4012

Dr. Miklós Szokol
Dr. István Erdei
Institute of Pathology, University Medical School, Debrecen, Pf. 27, H-4012

Dr. Csaba Balázs
Dr. Éva Kincses
Department of Ophthalmology, University Medical School, Debrecen, Pf. 27, H-4012

Book reviews

Urologie bei Rückenmarkverletzen (Unter Berücksichtigung sexualpädagogischer, gynäkologischer und andrologischer Probleme)

Edited by M. Stöhrer

Springer Verlag, Berlin–Heidelberg–New York 1979. 185 pages with 97 figures and 35 tables. DM 54, $ 37

According to various statistical data, a high percentage of patients with spinal injuries due to sport or road accidents or accidents at work die of diseases of the efferent urinary tract. This experience necessitated the application of up-to-date diagnostic methods, the search for new therapeutic possibilities and the application of their results to therapy. At present the practising urologist's knowledge of this field is not satisfactory. This up-to-date book deals with all essential problems in an attempt to fill the gap. It has been highly successful in its aspiration.

The book contains five main parts. The chapter on anatomic and neurophysiological basic principles summarizes, in an easily understandable manner, the evolution, anatomy and physiology of the bladder, with special regard to the factors ensuring continence and to the mechanism of urination, as well as to the causes leading to development of the neurogenic bladder. The chapter on the special diagnostics of the neurogenic disorders of urination deals, in addition to the traditional urological methods, also with the most up-to-date procedures such as uroflowmetry, urethrometry, electromyography and the combined urodynamic tests. The chapter contains not only the description of the applied techniques and the evaluation of the methods, but, what is highly important, also the indications for the various tests, and the description of a modern urodynamic laboratory. The chapter on the therapy of the neurogenic disorders of urination is the most detailed and most interesting part of the book. The drugs used in conservative therapy can be divided into two groups, those with an indirect effect acting through the vegetative nervous system, and those reducing the symptoms by their direct action on the muscular elements. Noradrenaline, dopamine, reserpine, gamma-aminobutyric acid and acetylcholine belong into the first group, papaverine, imipramine, caffeine, indomethacin, histamine and digitalis act directly on the muscle. In many cases a surgical intervention is unavoidable. Detailed information is provided on the indications and technique of endoscopic operations and on the possibilities of urine deviation. In the future, various prostheses (sphincter-replacement, penis prosthesis) will no doubt play a greater role.

The chapter on general urologic complications deals with the possibilities of preventing urogenital infections and with the causes, therapy and prevention of lithogenesis. Beside the correction of organic lesions, treatment of the various psychic disorders has become absolutely necessary. The possibilities of psychological treatment are discussed at the end of the chapter on psychological and sexual-medical problems. Restoration of function is not an easy task, but persevering treatment, medication and psychotherapy may greatly improve the patients condition.

The pleasantly presented book written in a good style is the work of 23 coauthors. It is to be ascribed to the thoroughness, and familiarity with the subject, of the editor that, despite the large number of authors, a harmonious concept was realized. Every author is an outstanding, renowned authority of his profession who has summarized his experience in such a way that every urologist-surgeon and all specialists of spinal injuries will find the book a useful reading. Those who wish to go into details, will find ample references at the end of each chapter. The several high quality figures and carefully compiled tables provide a visual support for the text.

Á. Csontai

J. Triller and W.A. Fuchs

Abdominale Sonographie

Georg Thieme Verlag, Stuttgart–New York 1980. 181 pages with 184 diagrams, 314 photographs and 21 tables. DM 97, $ 68

In the up-to-date radiological diagnostics of abdominal organs gray-scale echography has become indispensable. The monograph was compiled for everyday practice. The most important indications of echography are discussed and the authors state their opinion concerning the place of echography among radiological examinations.

The monograph is divided into 10 chapters. The first two summarize the most important physical, technical and methodological information. The description of biopsy and puncture under ultrasonic control is of particular interest.

The subsequent chapters treat separately the examination of each abdominal organ. The method of examination is described and the normal anatomical conditions are presented. This is followed by a description of the pathological conditions. The chapters on the examination of the liver, gallbladder and biliary ducts of the pancreas and the spleen have been written in accordance with the above principle.

The last chapters deal with the echography of abdominal effusions, of renal diseases and the space reducing processes in the suprarenal gland and the retroperitoneum. Each chapter is completed with a detailed list of references.

The echo-recordings were taken with a gray-scale analogue compound apparatus and are of very high quality.

The monograph contains very useful practical information and will be of interest to those engaged in echography or any other field of radiology.

I. Irtó

W. Draf

Endoscopie der Nasennebenhöhlen (Technik — Typische Befunde — Therapeutische Möglichkeiten)

Springer Verlag, Berlin–Heidelberg–New York 1978. 102 Seiten mit 19 Abbildungen und 13 farbigen Tabellen. DM 30, $ 18

Das sehr schön ausgestattete, gut überblickbare Buch befaßt sich mit der endoskopischen Untersuchung und Therapie der Nasennebenhöhlen. Der über ein großes Krankenmaterial und reichliche Erfahrungen verfügende Verfasser berichtet ausführlich über seine mit dieser, sich in den letzten Jahren bedeutend entwickelten Methode — der Endoskopie — durchgeführten Untersuchungen und den ermittelten Ergebnissen.

Das erste Kapitel ist der Technik, den Indikationen, den verschiedenen Methoden und den Dokumentationsmöglichkeiten der Endoskopie gewidmet.

Im zweiten Kapitel finden die endoskopische Anatomie und die verschiedenen pathologischen Veränderungen der Nebenhöhlen eine Besprechung.

Die Methode bietet eine bedeutende Hilfe zur Frühdiagnose der entzündlichen und gutartigen Veränderungen sowie der malignen Tumoren der Nasennebenhöhlen bzw. der Kieferhöhlentumoren. Die röntgenologische Diagnose der bereits vorangehend operierten Nebenhöhlen ist äußerst schwierig, so daß der Endoskopie auch auf diesem Gebiet eine wesentliche Bedeutung zukommt.

In der Traumatologie findet die Endoskopie vor allem zur Diagnostizierung der Frakturen der Augenhöhlenbasis eine erfolgreiche Anwendung.

Nebst der Diagnostik eignet sich die Endoskopie in gewissen Fällen auch zu therapeutischen Eingriffen, wie z.B. zur Behandlung der solitären Kieferhöhlenzysten, der Maxillenentzündungen der Kinder sowie der konservativ erfolglos behandelten Stirnhöhlenentzündungen. Unter den Komplikationen können Blutung, Hautemphysem oder eventuell eine In-

fektion vorkommen. Im Zusammenhang mit der Untersuchung des Sinus sphenoidalis wird auf die Gefahr einer Liquorfistel hingewiesen.

Laut der Ansicht des Autors ist die endoskopische Untersuchung der Kiefer- und Stirnhöhle fast ungefährlich und sehr erfolgreich.

Am Ende des Buches findet man ein ausführliches Literaturverzeichnis und farbige Tabellen sowie Abbildungen.

Die Monographie wird sowohl den Ohren-, Nasen- und Kehlkopfspezialisten als auch jenen Kollegen, die die Nebenhöhlenendoskopie erlernen möchten, von großem Nutzen sein, sie dürfte aber auch im Universitätsunterricht eine nicht zu unterschätzende Hilfe bieten.

O. Ribári

H.R. Henche

Die Arthroskopie des Kniegelenks

Springer Verlag, Berlin–Heidelberg–New York 1978. 86 Seiten mit 86 Abbildungen und 20 Tabellen. DM 27, $ 15

Der schweizerische Chirurg Bircher war der erste, der 1921 die in vivo endoskopische Untersuchung des Kniegelenks anwandte. Seitdem hat sich die Methode im Besitz der modernen technischen und optischen Möglichkeiten — den übrigen endoskopischen Untersuchungsverfahren ähnlich — in bedeutendem Maße entwickelt. In der vorliegenden Monographie werden anhand der Erfahrungen von 500 eigenen arthroskopischen Untersuchungen die gegenwärtige Lage und die Ergebnisse der Arthroskopie zusammengefaßt.

Die wichtigste, sich im Zusammenhang mit jeder invasiven Untersuchungsmethode erhebende Frage ist, was für eine Gefahr ihre Anwendung für den Patienten bedeutet. Wie aus dem Vorwort der Monographie hervorgeht, meldete sich im Laufe der 4000, in sechs verschiedenen Kliniken durchgeführten Untersuchungen in keinem einzigen Fall eine infektiöse Komplikation, welcher Umstand den Wert der Methode in bedeutendem Maße steigert.

Das Hauptverdienst der Monographie ist die sich in jedem Kapitel äußernde didaktische Bereitschaft: Der Autor wünscht die diagnostisch-praktischen Vorteile der arthroskopischen Untersuchung des Kniegelenks im Interesse des erfolgreichen therapeutischen Eingriffes dem Leser bekanntzumachen.

Die Vor- und Nachteile der zur Untersuchung nötigen Instrumente, die Indikationsfragen, die Narkosemethoden sowie, nach Erläuterung der erforderlichen anatomischen Kenntnisse, die pathologischen Charakteristiken der vorkommenden Änderungen werden in 17 kurzen Kapiteln besprochen. In der Folge weist der Autor mit überzeugenden Argumenten darauf hin, daß die mit diagnostischem Ziel durchgeführte Arthroskopie stets auf die ausführliche klinische und radiologische — die Arthrographie inbegriffen — Untersuchung folgen muß — falls die erwähnten Verfahren keine sichere Diagnose lieferten und sich die Veränderung vermutlich auf die synoviale Gelenkmembran oder auf den oberflächlichen Knorpel oder auf die Menisci bzw. auf die Kreuzbänder lokalisiert hat. Mittels Serienarthroskopie kann der Effekt der einzelnen therapeutischen Einwirkungen registriert werden, und es kann sich sogar eine Möglichkeit zu kleineren therapeutischen Eingriffen — wie z.B. zur Entfernung von Freikörpern des Gelenks — bieten. Die didaktische Pedanterie des Verfassers ist auch dadurch gekennzeichnet, daß im Buch selbst über nebensächlich scheinende, aber trotzdem wichtige Frage — wie z.B. die Untersuchungsdokumentation oder die Vorbereitung der Operationsschwester besprochen werden.

Neben den arthroskopischen Aufnahmen findet man stets eine die anatomischen Verhältnisse darstellende schematische Zeichnung, die für den in der Anatomie versierten Fachmann auf den ersten Blick evident ist.

Die fachlichen Angaben sind korrekt, die arthroskopischen Aufnahmen und die danebenstehenden Abbildungen didaktisch und ausgezeichnet in Qualität. Die Monographie eignet sich sowohl als Grund als auch als Fortbildungsstudie und kann deshalb allen Fachleuten, die sich für Diagnostik und Therapie der Bewegungsorgankrankheiten interessieren, aufrichtig empfohlen werden.

Éva Borbás

Heidelberger Taschenbücher Basistext Medizin

Band 191

Chirurgie

Herausgeber: G. HEBERER, W. KÖLE und H. TSCHERNE

Springer Verlag, Berlin–Heidelberg–New York 1977. 870 Seiten mit 500 teils farbigen Abbildungen und 80 Tabellen. DM 117, $ 52

Das Buch will vor allem die Ansprüche der Medizinstudenten befriedigen und erfüllt diese Aufgabe, was das äußere Format, den Aufbau des besprochenen Materials, Behandlungsweise und auch seinen Inhalt anbelangt, vorbildlich. Das Autorenteam bietet einerseits den Medizinstudenten die zu den chirurgischen Universitätsprüfungen nötigen Kenntnisse, anderseits werden aber auch die Grundbedürfnisse der sich auf die chirurgische Fachprüfung vorbereitenden jungen Kollegen befriedigt.

Auf den ersten 180 Seiten werden folgende Themen aus dem Bereich der allgemeinen Chirurgie behandelt: Operationssaal, Instrumente, chirurgische Grundtechnik, Anästhesie, Physiologie der Wundheilung, Verbindungslehre, Schock, lebensgefährliche Zustände, Verbrennung, Operationsindikation, Intensivtherapie, Thrombose-Embolie, Onkologie, Immunologie.

Der nächste Teil ist der ausführlichen Chirurgie gewidmet. Die einzelnen Kapitel folgen in einer, den Körperregionen entsprechenden Aufteilung aufeinander, aber die Frakturen, die Endokrinorgane, die Gefäßchirurgie, die plastische Chirurgie, die Urologie, die Traumatologie, die Handchirurgie, die Gelenkskrankheiten sowie die Knochentumoren bilden separate Kapitel. Am Ende des Buches findet sich die Besprechung physikotherapeutischer, Rehabilitations-Versicherungs- und Expertisenfragen.

Ein besonderer Vorzug des Buches ist, daß die verschiedenen Themen mit entsprechender Prägnanz, in einer didaktisch gut gelungenen Aufteilung behandelt werden so, daß die dargebotenen Kenntnisse leicht zu überblicken und zu erlernen sind. Der Stil ist trotz der vielen Autoren überraschend einheitlich.

Die ausgezeichneten Zusammenfassungen und die wichtigeren Daten systematisch anführenden Tabellen (z.B. Ursachen der Peritonitis, Organperforationen usw.) stehen ebenfalls im Dienste des leichteren Lernens. Den Text bereichern außerdem rund 500, teils farbige, graphische, einheitliche, schematische Abbildungen.

Den zahlreichen kleinen Ratschlägen, nützlichen Anweisungen und praktischen Instruktionen ist es zu verdanken, daß das Buch eine angenehme Lektüre ist und man beim Lesen gar nicht den Eindruck hat, daß es sich um ein Lehrbuch handelt.

Das Buch erschien in Kleinformat, welches in jeder Handtasche Platz hat, der Kunststoffumschlag ist allen Belastungen gewachsen, welche Umstände es den Medizinstudenten ermöglichen, das Buch in jeder Situation aufzuschlagen.

Wie erwähnt, bietet das Buch genügend Kenntnisse für die chirurgische Fachprüfung, es wäre aber unrecht, z.B. im Zusammenhang mit der ausführlichen Besprechung einzelner Fragen, übermäßige Anforderungen zu stellen.

Durch die Herausgabe der Arbeit wurde das deutsche Sprachgebiet mit einem hervorragenden chirurgischen Lehrbuch bereichert.

J. CSENGŐDI

CONTENTS

Tarsoly, E., Bornemisza, Gy. and *Furka, I.:* Tissue reaction to Histoacryl Blue adhesive and histological investigation of its disappearance in various organs 61

Papp, L., Mezei, B., Osváth, B. and *Szabó, Z.:* Thermography in artificially induced coronary circulatory disorders 75

Gervain, M., Karácsony, Gizella and *Mohácsi, G.:* Experimental ureteroileal anastomosis 83

Ihász, M., Balázs, Mártha, Csillag, A., Szabó, K. and *Horkai, F.:* Carcinoid tumours of the gastrointestinal tract 95

Csáky, G., Balázs, Gy., Lukács, G., Szokol, M., Erdei, I., Balázs, Cs. and *Kincses, Éva:* Simultaneous occurrence of Graves' disease with endocrine ophthalmopathy, thyroiditis and thyroid carcinoma 117

Book reviews 127

PRINTED IN HUNGARY

Akadémiai Nyomda, Budapest

The *Acta Chirurgica*, a periodical of the Hungarian Academy of Sciences in the field of medical sciences, publish original scientific treatises on surgery and related disciplines (general surgery, surgical aspects of gynecology, urology, oto-rhino-laryngology, orthopaedics, ophthalmology, as well as nerve and brain surgery, pulmonary, oral surgery, heart and blood-vessel surgery) in English, German, French or Russian, with abstracts in languages other than that of the paper.

The *Acta Chirurgica* appear in one volume per year, on some four hundred pages, divided into four fascicles issued quarterly.

Manuscripts should be addressed to

Acta Chirurgica
H-1096 Budapest, Nagyvárad tér 1. István Kórház, Urológia

Orders may be placed with "Kultura" Foreign Trading Company (H-1389 Budapest 62, P.O.B. 149) or its representatives abroad.

Les *Acta Chirurgica*, une revue de l'Académie des Sciences de Hongrie, publient des communications scientifiques originales du domaine de la chirurgie et ses disciplines voisines (chirurgie générale, gynécologie, urologie, oto-rhino-laryngologie, orthopédie, ophthalmologie, ainsi que la neuro-chirurgie, chirurgie du poumon, stomatologie, chirurgie du cœur et des vaisseaux sanguins, etc.). Les langues des communications sont: le français, l'anglais, l'allemand ou le russe, avec des résumés en d'autres langues que celle de la communication.

La revue *Acta Chirurgica* est un périodique publié en un volume par an — 400 pages environ — réparti en quatre livraisons: à paraître chaque trimestre.

On est prié d'envoyer les manuscrits destinés à la rédaction à l'adresse suivante:

Acta Chirurgica
H-1096 Budapest, Nagyvárad tér 1. István Kórház, Urológia

On peut s'abonner à l'Enterprise du Commerce «Kultura» (H-1389 Budapest 62, P.O.B. 149) ou Extérieur chez représentants à l'étranger.

Журнал Академии Наук Венгрии по медицинским наукам *Acta Chirurgica* публикует научные трактаты из области хирургических дисциплин (общая хирургия, гинекология, урология, ото-рино-ларингология, офтальмологиа, ортопедия, также как и нейрохирургия, легочная хирургия, стоматология, сосудистая хирургия, хирургия сердца и т. д.) на русском, английском, немецком или французском языках, с краткими резюме на языках, отличных от языка данной статьи. Авторами трактатов являются выдающиеся венгерские и зарубежные ученые.

Журнал *Acta Chirurgica* выходит по кварталам выпусками, составляющими один том. Приблизительные для публикации рукописи следует направлять по адресу:

Acta Chirurgica
H-1096 Budapest, Nagyvárad tér 1. István Kórház, Urológia

Заказы принимает предприятие по внешней торговле «Kultura» (H-1389 Budapest 62, P.O.B. 149) или его заграничные представительства и уполномоченные.

Periodicals of the Hungarian Academy of Sciences are obtainable at the following addresses:

AUSTRALIA
C.B.D. LIBRARY AND SUBSCRIPTION SERVICE
Box 4886, G.P.O., *Sydney N.S.W. 2001*
COSMOS BOOKSHOP, 145 Ackland Street
St. Kilda (Melbourne), Victoria 3182

AUSTRIA
GLOBUS, Höchstädtplatz 3, *1206 Wien XX*

BELGIUM
OFFICE INTERNATIONAL DE LIBRAIRIE
30 Avenue Marnix, *1050 Bruxelles*
LIBRAIRIE DU MONDE ENTIER
162 rue du Midi, *1000 Bruxelles*

BULGARIA
HEMUS, Bulvar Ruszki 6, *Sofia*

CANADA
PANNONIA BOOKS, P.O. Box 1017
Postal Station "B", *Toronto, Ontario M5T 2T8*

CHINA
CNPICOR, Periodical Department, P.O. Box 50
Peking

CZECHOSLOVAKIA
MAD'ARSKÁ KULTURA, Národní třída 22
115 66 Praha
PNS DOVOZ TISKU, Vinohradská 46, *Praha 2*
PNS DOVOZ TLAČE, *Bratislava 2*

DENMARK
EJNAR MUNKSGAARD, Norregade 6
1165 Copenhagen K

FEDERAL REPUBLIC OF GERMANY
KUNST UND WISSEN ERICH BIEBER
Postfach 46, *7000 Stuttgart 1*

FINLAND
AKATEEMINEN KIRJAKAUPPA, P.O. Box 128
SF-00101 Helsinki 10

FRANCE
DAWSON-FRANCE S. A., B. P. 40, *91121 Palaiseau*
EUROPÉRIODIQUES S. A., 31 Avenue de Versailles, *78170 La Celle St. Cloud*
OFFICE INTERNATIONAL DE DOCUMENTATION ET LIBRAIRIE, 48 rue Gay-Lussac
75240 Paris Cedex 05

GERMAN DEMOCRATIC REPUBLIC
HAUS DER UNGARISCHEN KULTUR
Karl Liebknecht-Straße 9, *DDR-102 Berlin*
DEUTSCHE POST ZEITUNGSVERTRIEBSAMT
Sraße der Pariser Kommüne 3–4, *DDR-104 Berlin*

GREAT BRITAIN
BLACKWELL'S PERIODICALS DIVISION
Hythe Bridge Street, *Oxford OX1 2ET*
BUMPUS, HALDANE AND MAXWELL LTD.
Cowper Works, *Olney, Bucks MK46 4BN*
COLLET'S HOLDINGS LTD., Denington Estate
Wellingborough, Northants NN8 2QT
WM. DAWSON AND SONS LTD., Cannon House
Folkstone, Kent CT19 5EE
H. K. LEWIS AND CO., 136 Gower Street
London WC1E 6BS

GREECE
KOSTARAKIS BROTHERS INTERNATIONAL BOOKSELLERS, 2 Hippokratous Street, *Athens-143*

HOLLAND
MEULENHOFF-BRUNA B.V., Beulingstraat 2,
Amsterdam
MARTINUS NIJHOFF B.V.
Lange Voorhout 9-11, *Den Haag*

SWETS SUBSCRIPTION SERVICE
347b Heereweg, *Lisse*

INDIA
ALLIED PUBLISHING PRIVATE LTD., 13/14 Asaf Ali Road, *New Delhi 110001*
150 B-6 Mount Road, *Madras 600002*
INTERNATIONAL BOOK HOUSE PVT. LTD.
Madame Cama Road, *Bombay 400039*
THE STATE TRADING CORPORATION OF INDIA LTD., Books Import Division, Chandralok
36 Janpath, *New Delhi 110001*

ITALY
INTERSCIENTIA, Via Mazzé 28, *10149 Torino*
LIBRERIA COMMISSIONARIA SANSONI, Via Lamarmora 45, *50121 Firenze*
SANTO VANASIA, Via M. Macchi 58
20124 Milano
D. E. A., Via Lima 28, *00198 Roma*

JAPAN
KINOKUNIYA BOOK-STORE CO. LTD.
17-7 Shinjuku 3 chome, Shinjuku-ku, *Tokyo 160-91*
MARUZEN COMPANY LTD., Book Department, P.O. Box 5050 Tokyo International, *Tokyo 100-31*
NAUKA LTD. IMPORT DEPARTMENT
2-30-19 Minami Ikebukuro, Toshima-ku, *Tokyo 171*

KOREA
CHULPANMUL, *Phenjan*

NORWAY
TANUM-TIDSKRIFT-SENTRALEN A.S., Karl Johansgatan 41–43, *1000 Oslo*

POLAND
WĘGIERSKI INSTYTUT KULTURY, Marszałkowska 80, *00-517 Warszawa*
CKP I W, ul. Towarowa 28, *00-958 Warszawa*

ROUMANIA
D. E. P., *Bucureşti*
ILEXIM, Calea Grivitei 64–66, *Bucureşti*

SOVIET UNION
SOJUZPECHAT — IMPORT, *Moscow*
and the post offices in each town
MEZHDUNARODNAYA KNIGA, *Moscow G-200*

SPAIN
DIAZ DE SANTOS, Lagasca 95, *Madrid 6*

SWEDEN
ALMQVIST AND WIKSELL, Gamla Brogatan 26
101 20 Stockholm
GUMPERTS UNIVERSITETSBOKHANDEL AB
Box 346, *401 25 Göteborg 1*

SWITZERLAND
KARGER LIBRI AG, Petersgraben 31, *4011 Basel*

USA
EBSCO SUBSCRIPTION SERVICES
P.O. Box 1943, *Birmingham, Alabama 35201*
F. W. FAXON COMPANY, INC.
15 Southwest Park, *Westwood Mass. 02090*
THE MOORE-COTTRELL SUBSCRIPTION AGENCIES, *North Cohocton, N. Y. 14868*
READ-MORE PUBLICATIONS, INC.
140 Cedar Street, *New York, N. Y. 10006*
STECHERT-MACMILLAN, INC.
7250 Westfield Avenue, *Pennsauken N. J. 08110*

YUGOSLAVIA
JUGOSLOVENSKA KNJIGA, Terazije 27, *Beograd*
FORUM, Vojvode Mišića 1, *21000 Novi Sad*

HU ISSN 0001—5431 **Index: 26.008**

Acta CHIRURGICA

ACADEMIAE SCIENTIARUM HUNGARICAE

EDITORIAL BOARD

BABICS ANTAL (chairman of the board), CSATA SÁNDOR (managing editor), PETRI GÁBOR (president), GLAUBER ANDOR, IHÁSZ MIHÁLY, MÉREI F. TIBOR, PÁSZTOR EMIL, RADNÓT MAGDA, RUBÁNYI PÁL, SURJÁN LÁSZLÓ, SZÉCSÉNY ANDOR, ZOLTÁN IMRE, ZSOLNAI BÉLA

ACTA CHIR. HUNG. TOMUS XXIII * FASCICULUS 3

AKADÉMIAI KIADÓ, BUDAPEST
1982

ACTA CHIRURGICA

ACADEMIAE SCIENTIARUM HUNGARICAE

A MAGYAR TUDOMÁNYOS AKADÉMIA ORVOSTUDOMÁNYI FOLYÓIRATA

FŐSZERKESZTŐ:

Dr. BABICS ANTAL akadémikus

SZERKESZTŐ:

Dr. CSATA SÁNDOR, az orvostudományok kandidátusa

A SZERKESZTŐSÉG CÍME: H-1096 BUDAPEST, NAGYVÁRAD TÉR 1. ISTVÁN KÓRHÁZ, UROLÓGIA
KIADJA AZ AKADÉMIAI KIADÓ, H-1054 BUDAPEST, ALKOTMÁNY U. 21.

Az *Acta Chirurgica* német, angol, francia, ill. orosz nyelven tudományos értekezéseket közöl a sebészet (általános sebészet, nőgyógyászat, urológia, oto-rhino-laryngológia, orthopaedia, szemészet, agy- és idegsebészet, tüdősebészet, szájsebészet, szív- és érsebészet stb.) tárgyköréből.

Az *Acta Chirurgica* évente 1 kötetben jelenik meg, mintegy 400 oldal terjedelemben. A kötet 4, negyedévenként megjelenő füzet formájában kerül kiadásra.

A közlésre szánt kéziratok, valamint a szerkesztőségi levelezés az alábbi címre küldendők:

Acta Chirurgica
H-1096 Budapest, Nagyvárad tér 1. István Kórház, Urológia

Megrendelhető a belföld számára az Akadémiai Kiadónál (1363 Budapest Pf. 24. Bankszámla: 215-11448), a külföld számára pedig a „Kultura" Külkereskedelmi Vállalatnál (1389 Budapest 62, P.O.B. 149. Bankszámla: 218-10990) vagy annak külföldi képviseleteinél és bizományosainál.

Die medizinwissenschaftliche Zeitschrift der Ungarischen Akademie der Wissenschaften *Acta Chirurgica* veröffentlicht Originalbeiträge ungarischer und ausländischer Wissenschaftler aus dem Themenkreis der Chirurgie und der verwandten Gebiete (allgemeine Chirurgie sowie die chirurgischen Beziehungen der Gynäkologie, Urologie, Oto-Rhino-Laryngologie, Orthopädie, Ophthalmologie usw., ferner Neurochirurgie, Gehirnchirurgie, Herz- und Gefäßchirurgie usw.) in deutscher, englischer, französischer oder russischer Sprache, mit kurzen anderssprachigen Zusammenfassungen.

Die *Acta Chirurgica* erscheinen jährlich in einem Band — im Umfang von etwa 400 Seiten — vier in vierteljährlichen Heften.

Die zur Veröffentlichung bestimmten Manuskripte sind an folgende Adresse zu senden:

Acta Chirurgica
H-1096 Budapest, Nagyvárad tér 1. István Kórház, Urológia

Bestellbar bei »Kultura« Außenhandelsunternehmen (H-1389 Budapest 62, P.O.B. 149) oder seinen Auslandsvertretungen.

Acta Chirurgica Academiae Scientiarum Hungaricae, Tomus 23 (3), pp. 131—134 (1982)

Effect of Low-output He-Ne Laser Rays on the Colony-Forming Ability of the Cells of Mice Lymphoma

L. Kovács,[1] I. Pályi[1] and S. Tisza[2]

Hungarian Army Medical Corps[1] and National Institute of Oncology, Research Institute of Oncopathology,[2] Budapest

(Received January 30, 1981)

The effect of low-output He–Ne laser rays on the survival of mouse lymphoma P388 cell cultures was studied on the basis of the colony forming ability. Irradiation with 1.3 and 9 joule of 5 and 10 mW He–Ne lasers, respectively, seemed to cause a relatively low cell necrosis. The survival curve did not show the shape characteristic of ionizing radiation.

It is known from studies on photostimulation by Mester et al. [5, 6] that the healing of superficial wounds (crural ulcer, burns) can favourably be influenced by irradiation with low-output He–Ne laser rays. In earlier works [1, 2, 3, 4] we studied the beneficial effect of He–Ne laser on the healing of superficial benign lesions of the epithelium of the portio vaginalis (ectopium) with reduced reactivity. Cytologic, colposcopic and histologic examination of 148 cases has shown that by biostimulation, recovery of the connective tissue was solved in a physiologic manner. The results of treatments are given in Tables I and II.

Table I

Distribution of treated cases according to the number of laser-treatments

No. of treatments	No. of cases		Total
	on contraceptive pills	not taking contraceptives	
15	8	22	30
25	53	29	82
35	15	4	19
partial improvement after 35 treatments	7	4	11*
no improvement	—	—	—
treatment discontinued	—	—	6
Total			148

* Because of extensive laceration operation was done. Histological examination showed no epithelial lesion.

TABLE II

Cured cases reporting for check-up

Time since end of treatment	No. and condition of patients reporting for check-up		
	Intact epithelium Cytology P_1 P_2	Ectopium Cytology P_1 P_2	Pathologic epithelium Cytology higher than P_2
1	93	2	—
3	42	3	—
5	16	1	—

In the present paper we shall describe our experiments with low-output He–Ne laser of 632.8 nm wavelength in order to establish its inhibitory effect on cell multiplication.

The effect of light as an electromagnetic oscillation on cell multiplication is less clear than that of ionizing radiations. The ionizing radiations, depending on the dose and the duration of irradiation, damage or destroy all kinds of cells. The test of colony forming ability described by Puck et al. [8] is suitable for the quantitative determination of the irreversible damage of cells and of the degree of the loss of reproductivity. The number of colonies in the treated and untreated control cultures can easily be determined.

Material and Method

Mouse lymphoma P388 cells were stabilized in cell cultures as described earlier [7]. The cells were grown in Fischer's solution containing 20% of horse serum (GIBCO). The logarithmically growing cells after centrifugation were placed into sterile physiological saline which contained no phenol red indicator, since this might have interfered with the experiment. 0.5 ml of the cell suspension, having a concentration of 10^5 cells per cm^3, was placed into a small glass cuvette and exposed to laser. During irradiation the suspension was stirred once or twice with a finely drawn Pasteur pipette to ensure the same irradiation for each cell. The cells were irradiated with doses of 1, 3 and 9 joule of lasers of 5 and 10 mW output, for different times. Then, the cells were placed into a culture medium containing complete agar in a final concentration of 0.25%. One thousand cells exposed to the lowest dose were placed into each of 3 parallel dishes; 2000 and 4000 cells, respectively, were cultured for the higher doses. The cultures were then incubated at 37 °C in a 5% CO_2 atmosphere for 14 days. Each colony was counted under a stereomicroscope. The colony-forming power of the cells was determined by comparing the mean number of colonies in the control and the treated dishes, taking the control value as 100%. The results were plotted on a semi-logarithmic scale in the function of the laser dose and so a survival curve was obtained.

Results

The colony-forming ability of the untreated control cells varied between 32 and 40%. This low value was attributed to the fact that during irradiation the cells were in saline which has an unfavourable influence on survival.

One joule had no influence on survival, while 3 J caused a 60 to 76% and 9 J a 45 to 75% decrease in survival. Laser treatment did not result in the shoulder-curve characteristic of ionizing radiation (Fig. 1).

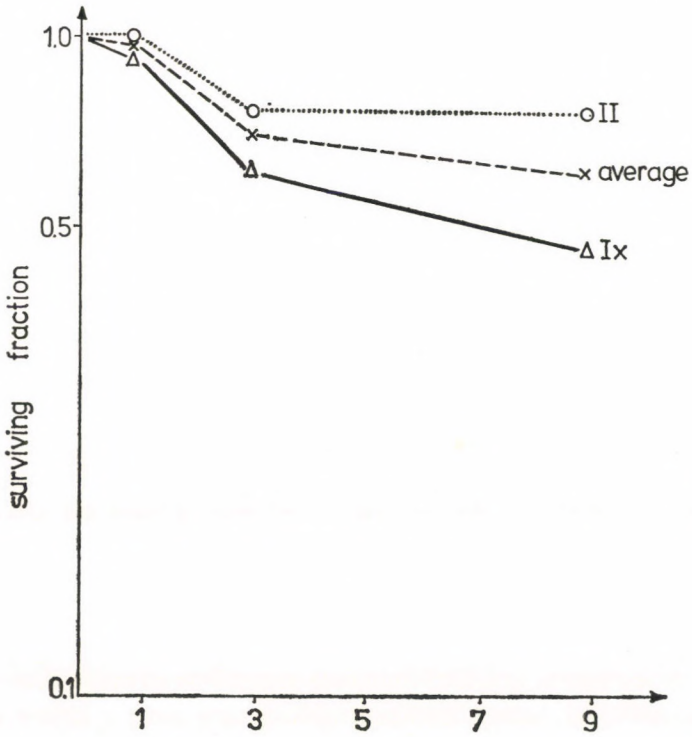

FIG. 1. P388 laser close response

Discussion

In the function of output there was a difference between the two experiments. Curve II is the result of irradiation with 5 mW and curve I is that of irradiation with 10 mW.

It appears from the shape of the curves that an exponential increase of the dose did not result in a proportional increase of cell destruction as can be observed with cytostatics or ionizing radiation. In the present case the shape of the curves seemed to indicate a transition to some sort of a plateau.

It appears from these experiments that the therapeutic dose (1 J/cm^2 with 5 and 10 mw He–Ne laser) caused no damage or destruction of the cells.

References

1. Kovács L: Stimulatory effect of laser ray on physiological healing process of surface of portio uteri. Proc. 9th World Congress of Gynaecology and Obstetrics, Tokyo 1979
2. Kovács L, Kirschner I, Martinás K, Lehoczky Gy, Tisza S, Molnár A: A lézer sugár a rákprevenció szolgálatában (Laser ray in cancer prevention.) Honvédorvos 30: 263, 1978
3. Kovács L, Mester E, Lehoczky Gy, Tisza S, Molnár A: Laserstrahlen im Dienste der Krebsvorsorge. Laser "Elektro-Optik" 3: 30, 1977
4. Kovács L, Tisza S: Treatment of ectopium with 102-output He–Ne laser. Neoplasma (in press)
5. Mester E, Korényi-Both A, Spiry T, Sher A, Tisza S: Stimulation of wound healing by means of laser rays. Acta Chir Acad Sci Hung 14: 347, 1973
6. Mester E, Tisza S, Csillag L, Mester A: Kumarin-Nekrose: Laserbehandlung. Chir Prax 22: 377, 1977
7. Pályi I, Turi G, Szikla K, Dallmann L: Drug resistance studies on intraspecific hybridomas. Arch Geschwulstforsch 51:119, 1981
8. Puck TT, Marcus PI, Cieciura SJ: Clonal growth of mammalian cell *in vitro*. Growth characteristics of colonies from single HeLa cells with and without a feeder-layer. J Exp Med 103: 273, 1956

Änderungen der Koloniebildungsfähigkeit von Mäuselymphomzellen unter Wirkung des Laserstrahles mit niedriger Leistung

L. Kovács, I. Pályi und S. Tisza

Untersucht wurde die Wirkung des He–Ne-Laserstrahles mit niedriger Leistung auf das Überleben der P388 Mäuselymphom-Zellkultur anhand der Koloniebildungsfähigkeit. Bei Anwendung einer Bestrahlung mit einer Energie von 1,3 und 9 J und He–Ne-Laserstrahl mit 5 und 10 mW war eine relativ niedrige Zellzerstörung zu finden. Die Überlebungskurve zeigt die auf die ionisierenden Strahlungen charakteristische Form nicht.

Изменение способности клеток лимфомы мышей к образованию колоний в ответ на воздействие гелиевонеонового лазерного луча с малой мощностью

Л. КОВАЧ, И. ПАЙИ и Ш. ТИСА

Авторы изучали воздействие маломощного гелиево-неонового луча на переживание культуры клеток мышиной P388 лимфомы, на основании их способности к образованию колоний. Облучение He–Ne лазерными лучами мощностью 5 и 10 мВт, с энергией 1,3 и 9 джоулей, вызывало гибель относительного небольшого числа клеток. Кривая переживания не имела характерную для ионизирующих облучений форму «плеча».

Dr. L. Kovács, Dr. I. Pályi — Hungarian Army Medical Corps

Dr. S. Tisza — National Institute of Oncology, Research Institute of Oncopathology, Budapest, Ráth Gy. u. 7/9, H-1125

Acta Chirurgica Academiae Scientiarum Hungaricae, Tomus 23 (3), pp. 135—143 (1982)

Metronidazole in the Chemoprophylaxis of Colon and Rectum Operations

L.E. Szabó, F. Csikós, L. Helembai, J. Karádi and A. Csiba

Department of General Surgery, Municipal Péterfy Street Hospital, Budapest

(Received February 18, 1981)

In the preparation of colorectal operations, beside the mechanical cleaning of the bowels, orally administered metronidazole, acting on anaerobic bacteria, was found to be highly effective. Compared to the controls, the drug considerably reduced the number and severity of postoperative infections, and, consequently, also the mortality. With metronidazole prophylaxis no wound suppuration indicating anaerobic infection was noted. The combined application of metronidazole with some antibiotic acting on the aerobic bacteria of the intestinal flora resulted in a significant reduction of postoperative infections.

The rich bacterial flora of the normal, and even more of the pathologic colon, often causes infections in the course of operations on the colon and rectum. The incidence of such infections is between 40 and 60% [4, 7, 11, 13, 23, 51, 54, 59]. In preoperative preparation the emptying and cleaning of the bowels, and the reduction of their bacterial flora is an old problem. The traditional methods are purgation, enema, administration of chemotherapeutics and antibiotics or of their combinations, and more recently a "complete washing of the bowels". Nevertheless, a completely satisfactory method is still not available.

The infectious complications after operations on the colon were earlier attributed to aerobic, and the more severe infections mainly to Gram-negative pathogens (*E. coli*, *Klebsiella*, *Proteus*, etc.). Non-sporular anaerobic strains make up the major part of the bacterial flora of the colon [7, 16, 45]. In recent years several papers have been published on the importance of these strains in postoperative infections [1, 3, 7, 8, 17, 25, 31, 33, 35, 40, 42]. In their prevention those preoperative measures proved effective which reduced the anaerobic bacterial flora of the colon and the possibility of infections caused by them.

The antibacterial effect of metronidazole was first reported by Füzy and Csukás [19, 20, 21]. Based on their investigations, the drug used originally for the treatment of vaginal trichomoniasis is now being applied with good results in diseases caused by anaerobic bacteria [6, 7, 14, 22, 31, 37, 40, 42, 49, 50]. According to Nagy et al. [45], such treatment significantly reduces the anaerobic flora of the colon and so it was obvious to apply the drug for chemoprophylaxis of colorectal operations [2, 22, 34, 35, 37, 45, 57, 59]. In this paper we shall report on our two-year experience in this field.

Material and Method

Comparative tests were carried out on three groups of randomly chosen patients prepared for colon and rectum surgery. There were 40 patients in each group. They all were fed a low-residue diet since their admission and only fluids on the day before the operation. On that day the bowels were emptied by magnesium sulphate purgation and enemas which were continued till clean water flowed out. Then, patients in Group I were given 5 g of neomycin orally, those in Group II before the operation and for three to four days after it 0.50 g of metronidazole (Klion, Richter, Budapest) every eight hours, and in Group III the same quantity of metronidazole plus 5 g of neomycin on the day before the operation.

According to Graber et al. [26], 0.50 g oral doses are sufficient for chemoprophylaxis, but in the case of systemic anaerobic infection intravenous administration will be necessary.

TABLE I

Distribution of patients according to sex, age and disease

Sex		Age, years	Malignant	Benign
Group I				
Women	23	51 to 81		
Men	17	average 67.4	39	1
Total	40			
Group II				
Women	16	29 to 88		
Men	24	average 57.6	38	2
Total	40			
Group III				
Women	19	41 to 84		
Men	21	average 68.0	38	2
Total	40			

TABLE II

Localization of disease

Site	Group I	Group II	Group III
Ascending colon	7	7	11
Descending colon	12	16	12
Transverse colon	2	2	1
Rectum	19	15	16
Total	40	40	40

The average age of the patients was almost the same (68 years) in Groups I and III, and about 10 years less in Group II which included some young patients. With the exception of a few cases (perforated diverticulum, megacolon, rectovaginal fistula) the operation was indicated by malignant tumour (Table I). The site of the tumour was in most cases the rectum. The incidence was lower on the left than on the right side of the colon and lowest in the transverse colon (Table II).

In all three groups three-fourth of the interventions were radical operations consisting in resection and anastomosis with abdominoperineal extirpation. In one-fourth of the cases palliative operations were performed: bypass anastomosis, preparation and closure of colostomy (Table III).

In cases of infectious complications antibiotics (penicillin, ampicillin, tetracycline, gentamycin, cephaloridine, cephalothin, streptomycin) were administered. In Groups II and III metronidazole treatment was continued and drainage was applied. After establishing the antibiotic susceptibility, aimed treatment was introduced.

TABLE III

Performed operations

Radical	Group I	Group II	Group III
	28	29	27
Resection + ileotransversostomy	5	5	8
Transverse resection	2	1	1
Resection + transversosigmoidostomy	2	3	2
Sigma resection	3	5	5
Hartmann's operation	1	2	1
Colectomy + ileosigmoidostomy	1	—	—
Resection — anterior section Dixon	2	2	1
Abdominoperineal extirpation	12	10	9
Gastrectomy + resection of splenic flexure	—	1	—
Palliative			
Ileotransversostomy	2	2	2
Transversosigmoidostomy	7	6	9
Closure of colostomy	2	3	—
Colostomy, sigmoidostomy	7	6	9
Total	40	40	40

Results

The prophylactic efficacy of the various preoperative measures was assessed by the comparison of postoperative wound and peritoneal infections (Table IV). In Group I abdominal and peritoneal infections occurred in 15 cases (37.5%) of which four were serious subfascial suppurations and one fatal sepsis starting from the abdominal wall. In Group II there were twelve (30%), in Group III nine (22.5%) infections of the abdominal wall and the perineum, but no serious subfascial infection was observed. In Group I four (10%). in Group II three (7.5%) and in Group III two (5%) cases of peritonitis, abdominal fistula or suture insufficiency occurred. The peritoneal symptoms were assessed on the basis of susceptibility, fever, meteorism and atony, bearing in mind the protracted ineffective bowel movements common after colon operations. This was observed in 14 (35%) cases of Group I, in 11 cases (27.5%) of Group II and six cases (15%) of Group III. The total number of complications was 33 (82.5%), in Group I, and 26 (65%) and 17 (42.5%) in Groups II and III, respectively. If we neglect the peritoneal symptoms on the basis that they are somewhat subjective complaints, the other two complications occurred in 19 (47.5%) cases in Group I, in 15 (37.5%) cases in Group II and in 11 (27.5%) cases in Group III. In relation to the number of patients, the overall number of infectious complications was higher, because abdominal

TABLE IV

Infectious postoperative complications

Complication		Group I	Group II	Group III
Suppuration				
Abdominal wound	subcutaneous	4	6	5
	subfascial	4	—	—
	sepsis	1	—	—
Perineal wound		6	6	4
Total		15 (37.5%)	12 (30.0%)	9 (22.5%)
Peritonitis				
(diffuse, circumscript, abscess, suture insufficiency)		4 (10.0%)	3 (7.5%)	2 (5.0%)
Total		19 (47.5%)	15 (37.5%)	11 (27.5%)
Peritoneal symptoms				
(sensitivity, atony, meteorism, fever)		14 (35.0%)	11 (27,5%)	6 (15,0%)
Total		33 (82.5%)	26 (65,0%)	17 (42.5%)

and perineal suppurations, peritonitis and perineal wound infections may have occurred in combination in one and the same patient. In cases of infections of the abdominal cavity, wound suppuration was not recorded separately as it was considered a consequence of peritonitis.

The mortality data (Table V) show that after 87 radical operations in Group I six, in Group II five and in Group III four, thus a total of 15 (17.2%) patients were lost. Wound infection caused the death of five patients (12.5%)

TABLE V

Mortality, cause of death

Mortality	Total	Group I	Group II	Group III
Radical operations: 87	15 (17.2%)	6	5	4
Palliative operations: 33	33 (33.3%)	5	2	4
Cause of death				
Circulatory failure	—	2	1	3
Myocardial infarction	—	—	—	1
Pneumonia	—	1	2	1
Pulmonary embolism	—	2	1	1
Renal failure	—	—	1	—
Tumour metastasis	—	1	—	—
Peritonitis	—	4	2	2
Infection of abdominal wound, sepsis	—	1	—	—

in Group I, of two (5%) in Group II and of another two (5%) in Group III. Of these we wish to mention separately a patient in Group I who died of sepsis due to a grave abdominal wall infection. The age of the lost patients varied between 58 and 82 years (average age 67.5 years). The relatively high mortality after palliative operations can be explained with the greater inclination to complications of elderly patients in poor general condition.

Apart from three patients who experienced nausea which ceased when administration was discontinued, no side-effect was observed. The three patients with nausea were not given further metronidazole and have therefore been omitted in the evaluation.

Discussion

After colorectal operations wound and intraperitoneal infections have an incidence of 40 to 60% [4, 7, 11, 13, 23, 40, 51, 54, 59]. The pathogens are, as a rule, facultative anerobic and Gram-negative aerobic pathogens but Gram-positive organisms also occur [3, 16, 17, 25, 39, 45]. There is a significant correlation between the bacteria isolated from the operated area and from the infection, indicating that intraoperative bacterial contamination is an important factor in infection [7].

The development of postoperative infections depends upon a number of factors in preoperative preparation, surgical technique and postoperative treatment. In their prevention, reduction of the bacterial flora of the colon is an important part of preparation. It is generally accepted that before elective operations a mechanical cleaning of the bowels somewhat reduces the infectious complications, but the value of antimicrobial prophylaxis is disputed. Parenteral antibiotic prophylaxis is usually rejected because of the risks involved, while the effect of orally administered antibiotics is unsatisfactory [9, 10, 12, 13, 15, 24, 27, 29, 30, 32, 38, 39, 43, 46, 47, 48, 53].

In our material we found some symptoms indicative of peritonitis. They ceased after conservative treatment, mainly (35%) in patients who were given neomycin (Group I); the incidence was 10% lower in the metronidazole (II) group and 15% less when both metronidazole and neomycin were given (Group III). Suppurating abdominal and peritoneal wounds, as well as purulence in the abdominal cavity, postoperative infection (47.5) and death (12.5%) had the highest incidence among patients who had been given neomycin; it was far lower in the groups which had received metronidazole (37.5% and 5%, resp.). The simultaneous administration of metronidazole and neomycin was found the most effective. Compared to Group I, the number of infections in Group III was 20%, of infections of fatal outcome 50% lower. Beside these numerical data, the lesser severity of infections was considerable. Suppurating wounds indicative of anaerobic infection and accompanied by septic fever, putrid pus and extensive tissue necrosis — one case of which ended in death — occurred only among patients who had been given neomycin. None of the patients administered metronidazole showed similar complications. The wound infections of these patients were more superficial, milder and healed a short time after exposure and the administration of supplementary antibiotics. This was confirmed by the number of average nursing days which was 20.8 in Group I, 18.4 in Group II and 15 days in Group III.

Thus, metronidazole was found to be efficacious in the prophylaxis of colorectal operations to prevent and reduce postoperative infections. In the metronidazole groups the number of suture insufficiency and peritonitis decreased and no severe suppuration pointing to an anaerobic infection was

detected. On the basis of the symptoms and the results of supplementary antibiotic therapy, the wound infections could be ascribed to Gram-positive and Gram-negative pyogens. Metronidazole significantly reduced the incidence and severity of postoperative infections even when administered alone, but it seems desirable to apply the drug in combination with an antibiotic which acts upon the aerobic bacterial flora. This was confirmed by the fact that propyhlaxis was the most effective when metronidazole was administered together with neomycin which in itself proved less effective than in combination.

Our trials currently in progress in which metronidazole is given in combination with an antibiotic more effective than oral neomycin, have raised the hope that the number of postoperative infections can further be reduced.

References

1. Anderson CB, Marr JJ, Ballinger WF: Anaerobic infections in surgery. Clinical review Surgery 79: 315, 1976
2. Araby Y, Dimock F, Burdon DW, Keighley MRB: Influence of bowel preparation on colonic microflora. Br J Surg 64: 831, 1977
3. Ágoston É, Boros M, Farkas Gy: Anaerob sepsis (Anaerobic sepsis). Orv Hetil 119: 3255, 1978
4. Barker K, Graham NC, Masson MC, de Dombat ET, Goliger JC: Relative significance of pre-operative oral antibiotics, mechanical bowel preparation and preoperative peritoneal companination in the avoidance of sepsis after radical surgery for ulcerative colitis. Br J Surg 58: 270, 1971
5. Boján M: Az anaerob baktériumok humán pathologiai szerepéről és jelentőségéről (Human pathological role and importance of anaerobic bacteria). Orvosképzés 51: 36, 1976
6. Brass C, Richards GK, Ruedy J, Prentis J, Hinchey EJ: The effect of metronidazole on the incidence of postoperative wound infection in elective colon surgery. Amer J Surg 135: 91, 1978
7. Burton CR: Postoperative wound infection in colonic and rectal disease. Br J Surg 60: 363, 1975
8. Clark LP, Marshall HA, Ackerman NB: Bacteroides as infectious organisms. Surg Gynecol Obstet 138: 562, 1974
9. Cohn, I: Intestinal antisepsis. Surg Gynecol Obstet 150:1006, 1970
10. Downing R, McLeish AR, Burdon DW, Alexander-Williams J, Keighley MRB: Duration of systemic prophylactic antibiotic cover against anaerobic sepsis in bowel surgery for diseases of the colon and rectum. Br J Surg 63: 664, 1976
11. Drasas BS, Shiner M, McLeod GM: Studies on the intestinal flora. Gastroenterology 56: 71, 1969
12. Evans C, Pollock AW, Rosenberg IL: The reduction of surgical wound infections by topical cephaloridine, a controlled clinical trial. Br J Surg 61:133, 1974
13. Everett MT, Brogan TD, Nettleton J: The place of antibiotics in colonic surgery. Br J Surg 56: 679, 1969
14. Eykyn SJ, Phillips I: Metronidazole and anaerobic sepsis. Br Med J 2: 1418, 1976
15. Feathers RS, Lewis AA, Sagor GR, Amirak ID, Noone P: Prophylactic systemic antibiotics in colorectal surgery. Lancet 2: 827, 1977
16. Fedor E, Sápy P, Gál I, Ézsely F, Varga L, Bodrogi T: Postoperativ diffus peritonitisek gyakorisága, kórjelzése és halálozása (Incidence, symptoms and mortality of postoperative diffuse peritonitis). Orv Hetil 119: 2255, 1978
17. Felner JM, Dowell VR jr: Bacteroides bacteremia. Am J Med 50: 787, 1971
18. Fiddian RYJ: Prophylaxis in colonic surgery. J Antimicrob Chemother 4: 39, 1978
19. Füzy M, Csukás Zs: A metronidazol egy eddig ismeretlen antibakteriális hatása (A hitherto unknown antibacterial effect of metronidazole). Orv Hetil 110:1605, 1969

20. Füzy M, Csukás Zs: Das antibacterielle Wirkungsspektrum des Metronidazols. Zentralbl Infektionskr Hyg 2: 258, 1970
21. Füzy M: A bacteriodes fragilis és az anaerob streptococcusok metronidazol érzékenysége (Metronidazole susceptibility of *Bacterioides fragilis* and of anaerobic streptococci.) Magy Nőorv Lapja 35: 559, 1972
22. Gillespie G, McNaught J: Prophylactic oral metronidazole in intestinal surgery. J Antimicrob Chemother 4: 29, 1978
23. Gillespie WA, Guy J: Bacteroides in intraabdominal sepsis. Lancet 1:1039, 1936
24. Goldring J, Scott A, McNaught W, Gillespie G: Prophylactic oral antimicrobial agents in elective colonic surgery. Lancet ii: 997, 1975
25. Gorbach SL, Barlett JG: Anaerobic infections N Engl J Med 290:1177, 1237, 1289, 1974
26. Graber H, Csiba A, Csikós F, Deutsch T: Farmakokinetikai vizsgálatok metronidazollal egészségeseken és vastagbél műtéten átesett betegeken (Pharmaco kinetic studies with metronidazole on healthy subjects and on patients after operation of the colon). (in press)
27. Grant RB, Barbara AS: Preoperative and postoperative antibiotic therapy in surgery of the colon. Am J Surg 107: 810, 1964
28. Griffiths DA, Shorey BA, Simpson RA, Speller DCE, Williams NB: Single-dose pre-operative antibiotic prophylaxis in gastrointestinal surgery. Lancet ii: 325, 1976
29. Gunn AA, Gould JC: Control of the intestinal flora by means of antibacterial drugs in the surgery of the colon. Gut 8: 582, 1965
30. Heter FF, Slenetz CA: Influence of antibiotic preparation of the bowel in complications after colon resection. Am J Surg 115:165, 1967
31. Hewitt J, Rigby J, Reeve J, Cox AG: Whole-gut irrigation in preparation for large-bowel surgery. Lancet ii: 337, 1973
32. Hollander LF, Calderoli H, Schoenahl C: Notre expérience de l'irrigation lavage ("wash-out") dans la chirurgie colique. Chirurgie 103: 769, 1977
33. Höjer H, Wetters J: Systemic prophylaxis with doxycycline in surgery of the colon and rectum. Ann Surg 187: 362, 1978
34. Ingham HR, Selkov JB, Sisson PR, Middleton RL: Metronidazole in large-bowel surgery. Lancet ii: 902, 1979
35. Keighley MRB, Crapp AR, Burdon DW, Cooke WT, Alexander-Williams J: Prophylaxis against anaerobic sepsis in bowel surgery. Br J Surg 63: 538, 1976
36. Keighley MRB: Prevention of wound sepsis in gastrointestinal surgery. Br J Surg 64 (5), 315, 1977
37. Keighley MRB, Arsby Y, Matheson D, Alexander-Williams SJ: Aspects of preventing sepsis in colo-rectal surgery: results of recent trials with lincomycin and gentamycin. J Antimicrob Chemother 4: 33, 1978
38. Kislak JN: The susceptibility of *Bacteroides fragilis* to 24 antibiotics. J Infect Dis 125: 299, 1974
39. Leight DA: Clinical importance of infections due to *Bacteroides propilis* and role of antibiotic therapy. Br Med J 3: 225, 1974
40. Leigh DA: Wound infections due to *Bacteroides fragilis* following intestinal surgery. Br J Surg 62: 375, 1975
41. Leigh DA: Indications for antibiotic prophylaxis and treatment in patients undergoing appendectomy. J Antimicrob Chemother 4: 15, 1978
42. MacKenzie L, Litten A: Bacteroides bacteriaemia in surgical patients. Br J Surg 61: 288, 1974
43. Marton T, Jakab F, Ondrejka P, Sugár I: A vastagbél előkészítésének új módszere colonoscopiához és resectióhoz (A new method for the preparation of the colon for colonoscopy and resection). Magy Seb 32: 273, 1979
44. Matheson DM: Randomized multicentre trial of oral bowel preparation and antimicrobials for elective colorectal operation. Br J Surg 65: 597, 1978
45. Nagy A, Ágoston É, Baradnay Gy: A Klion (metronidazol) hatása a vastagbél anaerob flórájára. (The effect of Klion (metronidazole) on the anaerobic flora on the colon) Orv Hetil 121:1071, 1980
46. Nichols RL, Condon RE: Preoperative preparation of the colon. Surg Gynecol Obstet 132: 323, 1971
47. Nichols RL, Gorbach SL, Condor LE: Alteration of intestinal microflora following pre-operative mechanical preparation of the colon. Dis Colon Rectum 14:123, 1971
48. Nichols RL, Broido P, Condon RE, Corbach SL, Nyhus LM: Effect of pre-operative neomycin-erythromycin intestine preparation on the incidence of infectious complications following colon surgery. Ann Surg 178:1973

49. Pashby N, Mee WM: Metronidazole prophylaxis and primary wound closure in appendectomy. J Antimicrob Chemother 4: 25, 1978
50. Percival A, Cunderland N: Antimicrobial susceptibilities of Gram-negative anaerobes. J Antimicrob Chemother 4: 3, 1978
51. Pollock AV, Evans M: Wound sepsis in colonic surgery. Br Med J 1.:840, 1977
52. Roy AD: The prophylactic use of antimicrobial agents in the surgery of the intestine. J Antimicrob Chemother 2: 233, 1975
53. Schiessel R: Orale Spülhandlung. Proc Kongr Dtsch Ges Chirurgie, München 1978, p. 101
54. Shatey CH, Lillehei RC: Septic shock associated with operations for colorectal disease. Dis Colon Rectum 21: 480, 1978
55. Stokes EJ, Waterworth PM, Franks V, Watson B, Clark CG: Short term routine antibiotic prophylaxis in surgery. Br J Surg 61: 739, 1974
56. Study Group: Metronidazole prophylaxis and treatment of anaerobic infections in surgical patients, J Antimicrob Chemother 1:393, 1975
57. Study group: Metronidazole in prevention and treatment of bacteroides infections in elective colonic surgery. Br Med J 1: 318, 1976
58. Taylor SA, Cawdery HM, Smith J: The use of metronidazole in the preparation of the bowel for surgery. Br J Surg 66:191, 1979
59. Watt-Boolsen S, Justesen T, Blichert-Toft M, Hansen JB: The prophylaxis of septic complications in colo-rectal surgery. A controlled trial of metronidazole and oxytetracycline. Acta Chir Scand 145: 263, 1979

Metronidazol (Klion®) in der Chemoprophylaxe von Dick- und Mastdarmoperationen

L. E. Szabó, F. Csikós, L. Helembai, J. Karádi und A. Csiba

Bei der Vorbereitung von Dick- und Mastdarmoperationen hat sich — nebst der üblichen Darmreinigung — das auf die nicht sporadische, anaerobe Bakterien einwirkende, oral verabreichte Metronidazol (Klion®) für äußerst wirksam erwiesen. Im Vergleich zu den Kontrollfällen wurden durch die Medikation die Zahl und die Schwere der postoperativen Infektionen sowie die dadurch bedingte Mortalität in bedeutendem Maße herabgesetzt. Bei den Patienten, die Metronidazol-Prophylaxe erhielten, meldeten sich keine, auf eine anaerobe Wundinfektion weisenden Wundeiterungen. Durch kombinierte Verabreichung von Metronidazol und eines, auf die aerobe Bakterien der Darmflora einwirkenden Antibiotikums, konnte eine weitere wesentliche Verringerung der postoperativen Infektionen erzielt werden.

Применение метронидазола (клион) для хемопрофилактики при операциях на толстой и тонкой кишках

Л. Э. САБО, Ф. ЧИКОШ, Л. ХЕЛЕМБАИ, Й. КАРАДИ и А. ЧИБА

В подготовке к операциям на толстой и тонкой кишках, помимо обычного механического очищения кишечника, считают эффективным пероральное применение метронидазола (клиона), который действует на аспорогенные анаэробные бактерии. Сравнительно с контролем это средство значительно уменьшило число постоперативных инфекций, а также их тяжесть, благодаря чему снизилась смертность. В случае профилактики метронидазолом не отмечали негноения ран, указывающего на анаэробную раневую инфекцию. Одновременное применение метронидазола с действующим на аэробную кишечную флору антибиотиком привело к дальнейшему снижению числа послеоперационных инфекций.

Dr. László E. Szabó
Dr. Ferenc Csikós
Dr. László Helembai
Dr. József Karádi
Dr. András Csiba

Department of General Surgery,
Municipal Péterfy Street Hospital,
Budapest, Péterfy Sándor u. 8–20, H-1076

Acta Chirurgica Academiae Scientiarum Hungaricae, 23 Tomus (3), pp. 145—152 (1982)

Limb Circulation after Deep Venous Thrombosis

F. SOLTI, L. SOLTÉSZ, Gy. UNGVÁRI, L. SZLÁVI and P. GLOVICZKI

Institute of Vascular Surgery, Semmelweis University Medical School, Budapest

(Received March 7, 1981)

The blood and oxygen supply of the limbs after deep venous thrombosis and the mechanism of the changes in limb circulation were studied. After deep venous thrombosis the circulatory disturbance develops progressively. The only effective method for prevention of the pathologic changes is an early relief of the venous obstruction.

Deep venous thrombosis in the lower limb is not a rare condition. After thrombosis the venous occlusion causes a rise in venous pressure below the occlusion and a failure of venous circulation develops. More than once venous occlusion is followed by trophic disorders in the lower limb. Though the clinical aspects of the disease are well known, there is but little information about the changes in flow in the limbs, in the regulation of limb circulation following venous occlusion.

We shall report in this paper on studies concerning the blood and oxygen supply of the limbs after venous thrombosis and the mechanism of the change of limb circulation.

Material and Method

Limb circulation was studied in 12 patients suffering from venous occlusion in one of the lower limbs. In all these cases venous occlusion developed after earlier deep venous thrombosis. The location and extension of venous occlusion detected by phlebography was the femoral vein in 9 cases and the popliteal vein in 3 cases. On the affected side the lower limb was considerably thicker and oedematous. The average age of the patients was 48.5 years (range 24–65 years), the sex distribution was 5 men and 7 women.

Limb circulation had to be tested to decide whether surgical or conservative therapy should be applied. Total limb blood flow was determined by the venous dilution method [14].

Limb oxygen uptake was obtained from the product of limb flow and the arteriovenous oxygen difference. The oxygen content of the femoral artery

and vein was determined from blood samples with the Kipp oxymeter. The circulations of both lower limbs were tested; the values for the intact limb served as control.

The mechanism of circulatory changes after venous occlusion was studied in animal experiments. Thirty mongrel dogs of both sexes weighing 14 to 22 kg were used in the experiments. To stimulate obstructed post-thrombotic circulation in one of the lower limbs the femoral vein was ligated in the middle third of the thigh. On the second or third day after ligation the limb was swollen and venous pressure in that limb had considerably risen. An intact limb served as control. Venous occlusion was confirmed phlebographically. The circulation was studied on the 7th to 12th days after ligation.

Nutritive (skin and muscle) flow in the limb was measured in 14 animals by Sapirstein's method [11], cardiac output by the intravenous injection of 2 mg/kg of Evans blue. Blood samples were taken from the femoral artery every second. Total limb circulation was measured on the basis of iliac venous outflow. To test arteriovenous shunt circulation in 6 dogs the vessels were filled with 5% polyvinylchloride through a cannula introduced into the common iliac artery and the limbs were corroded by means of concentrated HCl.

To study changes in microcirculation, samples taken from 16 animals were fixed in formaldehyde and the frozen sections were subjected to benzidine reaction. Specimens taken from both lower limbs were fixed in formaldehyde and after staining with Mallory, azan, haemotoxylin-eosin, PAS or Prussian blue examined under the light microscope. Results were evaluated by Student's one-sample *t* test; the control was always the intact limb.

Results

The effect on limb circulation of venous occlusion after deep venous thrombosis is shown in Fig. 1.

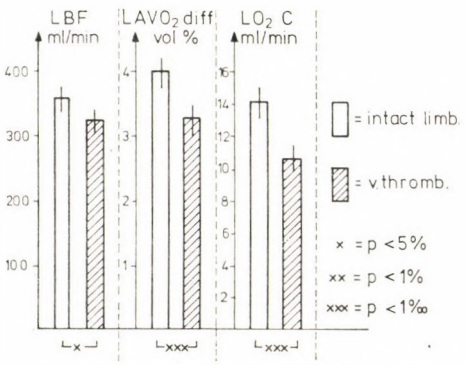

FIG. 1. Regulation of blood circulation after deep venous thrombosis. LBF = limb blood flow; $LAVO_2$ = limb arteriovenous O_2 difference; LO_2C = limb O_2 consumption

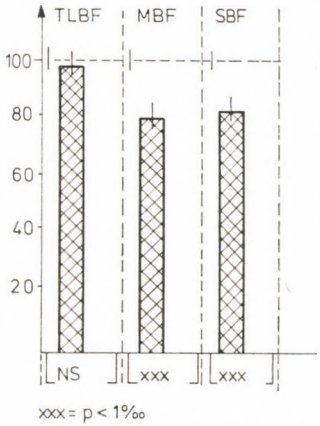

FIG. 2. Limb circulation after ligation of femoral vein. TLBF = total limb blood flow; MBF = nutritive muscle blood flow; SBF = nutritive skin blood flow

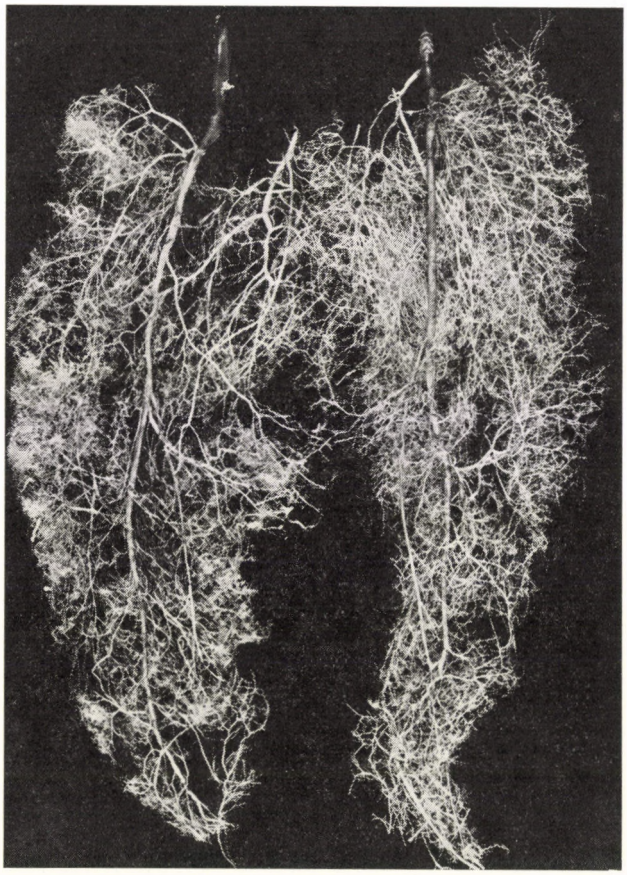

FIG. 3. Arteriovenous communication after ligation of the femoral vein. Polyvinyl chloride injected into the arterial branch fills not only the limb arteries but penetrates the venous trunks

Under the effect of deep venous thrombosis, limb blood flow (LBF) decreased slightly, but significantly. Oxygen consumption (LO_2C) of the limb with deep venous thrombosis decreased considerably and the limb arterio-venous oxygen difference ($LAVO_2$ diff.) was reduced. The results of dog experiments are shown in Fig. 2, where the values for the limb with venous occlusion are expressed in per cent of the same values for the intact limb.

After ligation of the femoral vein, total limb blood flow did not significantly differ from the flow in the intact limb, but nutritive muscle (MBF) and skin (SBF) blood flows were significantly reduced.

In addition, a significant change occurred in the microcirculation of the ligated limb. Development and opening of arteriovenous shunts were observed on the corrosion preparation of the affected limb. An arteriovenous communication of this type is shown in Fig. 3. The corrosion preparation was prepared by filling the dog limb with polyvinyl chloride seven days after ligation of the femoral vein. The efferent venous trunk filled directly from the arterial branch

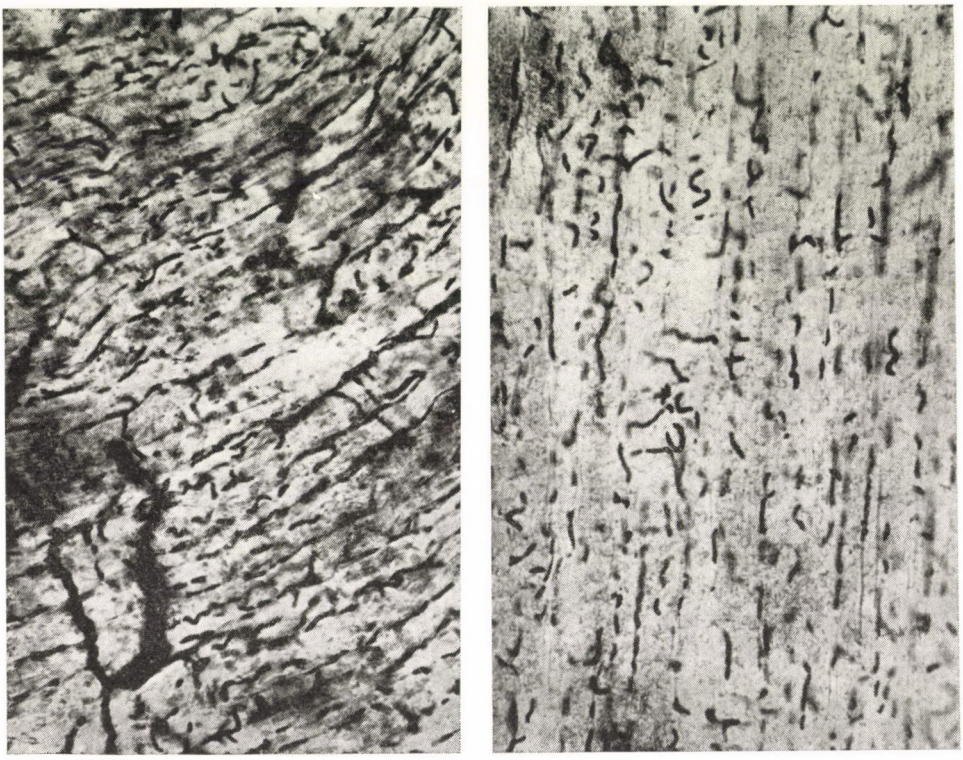

FIG. 4. Venous stasis caused by ligation of the femoral vein. Benzidine reaction, 40 μm section. In the upper part, specimen from normal limb. In the lower part, slide prepared after ligation of femoral vein. The density of the vascular sections giving a positive benzidine reaction increases after venous occlusion

through the shunt. Histological examination after benzidine reaction showed that ligation of the vein caused some interstitial oedema and considerable venous stasis, as shown in Fig. 4.

Discussion

After venous thrombosis, blood flow from the area of the affected vein is obstructed causing an increase in venous pressure distally from the occlusion. When venous thrombosis extends to the area of the main collecting veins, this being the well-known picture of deep venous thrombosis, there will be a considerable venous stasis in the affected limb and limb oedema will develop due to the venous insufficiency. Data are few concerning the modifications of limb circulation and on its regulation after venous occlusion. According to animal experiments, acute venous occlusion elicits a temporary but significant reduction in the quantity of blood flowing through the limb [1, 4, 7, 12, 13, 17, 18]. A decrease in the blood supply of the limb musculature after deep venous thrombosis was observed in tests carried out on human subjects [9, 10].

The present results indicate that considerable changes occur in limb circulation and its regulation after venous occlusion. According to our measurements, venous thrombosis causes a slight reduction of limb blood flow. This is probably due to the fact that as venous thrombosis spreads, as it usually does, a longer area of the affected section is occluded than after its ligation, so that effusion from the collateral veins meets a greater obstacle. This explains why in our animal experiments in which the femoral vein was ligated there was no decrease in total limb flow, but this decreased significantly after deep venous thrombosis. The most interesting finding was the development of an arteriovenous shunt circulation after venous occlusion; the arteriovenous oxygen difference decreased and nutritive blood flow was significantly reduced in both the muscles and the skin. While, after venous thrombosis, total limb flow was reduced only slightly, the reduction of limb nutritive flow was more expressed. The formation of arteriovenous shunts was demonstrated by the corrosion preparations. The specimens showed venous stasis and interstitial oedema, and also indicated changes in microcirculation: in the oedematous areas of the limb with venous occlusion, the major part of the capillaries was compressed and narrowed while the efferent venous branch — mainly the venules — were greatly dilated.

Some authors have already indicated that venous congestion causes the opening of arteriovenous shunts. Cooke and Pilcher [3] and McLahlin [8] observed a significant rise of skin temperature on the affected limb after deep venous thrombosis. Imao [6] found in the congested limb a decreased capillary

filtration and unchanged vascular resistance. Brookes and Sigh [2] ligated the femoral vein of rats and rabbits and detected a shunt circulation between the epiphysis and metaphysis. In the course of the arteriographic examination of 14 patients with venous occlusion, Haimovici [5] often observed early filling in spots, indicating arteriovenous communications.

Arteriovenous shunts develop not only after venous occlusion. Lymphoedema may also lead to arteriovenous shunts [15, 16] but there is a significant difference in the regulation of limb blood flow between lymphoedema and deep venous thrombosis. In lymphoedema, total limb blood flow rises considerably, by almost 60%, while nutritive blood flow is normal. On the other hand, after venous occlusion, nutritive blood flow drops by 20%. The arteriovenous oxygen difference decreases in the limb in both diseases. The special development of limb circulation explains why trophic disorders on the limb are rare in lymphoedema and frequent in venous thrombosis.

Though the mechanism of the changes in limb circulation accompanying a venous occlusion is not quite clear, the present results and the pertaining data permit to draw certain conclusions with respect to the origin of the circulatory changes. Venous occlusion causes a permanent increase in venous pressure in the region below the occlusion and to bypass the occlusion a collateral venous circulation develops. After an extensive thrombosis of the deep veins the collateral circulation is usually insufficient to ensure an adequate venous flow. As a result, venous stasis, oedema and a reduction of blood flow develop in the lower limb. The permanently higher venous pressure will cause the opening of short arteriovenous shunts (there are no data on the formation of new shunts). The result is a reduction of nutritive limb blood flow, and of the arteriovenous oxygen difference. The decrease in nutritive blood flow may cause trophic disorders, mainly when the limb arteries, too, are affected (obliterative arterial diseases) and the skin is tense because of the oedema.

After deep venous thrombosis the circulation in the limb deteriorates progressively. The only effective means to prevent the pathologic changes is the earliest possible treatment of venous thrombosis.

References

1. Barcia PJ, Nelson ThG, Whelan ThJ: Importance of venous occlusion in arterial repair failure: an experimental study. Ann Surg 175: 223, 1972
2. Brookes M, Sigh M: Venous shunt in bone after ligation of the femoral vein. Surg Gynecol Obstet 135: 85, 1972
3. Cooke ED, Pilcher MF: Thermography in diagnosis of deep venous thrombosis. Br Med J 2: 523, 1973
4. Fales JT, Heissey SR, Zierler KL: Blood flow from and oxygen uptake by muscle during and after partial venous occlusion. Am J Physiol 203: 470, 1962
5. Haimovici M: Abnormal arteriovenous shunts associated with chronic venous insufficiency. J Cardiovasc Surg 17: 473, 1976

6. Imao T: The influence of elevated venous pressure on blood tissue exchange of ^{22}Na in perfused hindlimbs of dogs. Jap Circulat J 3:1, 1971
7. Keaveny TV, White Cl, Belzer FO: Skin temperature, blood flow and venous occlusion. J Cardiovasc Surg 11: 219, 1970
8. McLahlin J: An evaluation of clinical signs in the diagnosis of venous thrombosis. Arch Surg 85: 738, 1962
9. Negus D: Calf pain in the post-throbotic syndrome. Br Med J 2:156, 1968
10. Puglionisi A, Pietrantoni F, Agrifoglio G, Giabbani V: Determinazione della clearance del radisodio (Na^{22}) iniettato nel musculo gastrocnemio. Minerva Cardioangiol 14: 981, 1961
11. Sapirstein LA: Regoinal blood flow by fractional distribution of indicator. Am J Physiol 193:161, 1958
12. Scheinberg P, Dennis EW, Robertson RL, Steed EA: The relation between arterial pressure and blood flow in the foot. Am Heart J 35: 405, 1948
13. Snyder MA, Adams JT, Schwartz SI: Sympathectomy in ileofemoral venous thrombosis. Surg Gynecol Obstet 125: 49, 1967
14. Solti F, Krasznai I, Iskum M, Rév J, Nagy J: Measurement of blood flow in the brain and lower extremities in man by venous dilution. Cor et Vasa 8:178, 1966
15. Solti F, Nagy J, Gergely J, Iskum M, Krasznai I, Hartai A, Csillag M: Über die Regulation der Extremitätdurchblutung bei Extremitätlymphödem. Acta Med Acad Sci Hung 27:15, 1970
16. Solti F, Ungváry Gy, Bálint A, Nagy Z: The regulation of the limb circulation in lymphoedema. Angiologica 8:117, 1971
17. Weber ThR, Lindenauer MS, Pozderac RV, Freedman W, Fry WJ: Venous occlusion and $Xenon^{133}$ muscle clearance. Surg Forum 25: 260, 1974
18. Wright CB, Sayre JT, Casterline PI, Swan KG: Haemodynamic effects of sympathectomy on canine femoral occlusion. Surgery 74: 405, 1973

Änderungen der Extremitätendurchblutung unter Wirkung des Venenverschlusses, der Tiefvenenthrombose

F. Solti, L. Soltész, Gy Ungvári, L. Szlávi und P. Gloviczki

Bei 12, an einseitiger Tiefvenenthrombose leidenden Patienten wurden die durch Venenverschluß bedingten Änderungen des Extremitätenkreislaufes mit der venösen Isotopen-Dilutionsmethode analysiert. Zwecks Ergänzung der Humanuntersuchungen wurde durch Unterbindung der einseitigen V. femoralis bei 30 Hunden einseitiger Dauervenenverschluß zustandegebracht. Bei einer Gruppe der Tiere (14 Hunde) wurde mittels Verabreichung von ^{86}Rb die nutritive (Haut, Muskel) Durchblutung der Extremitäten, während bei der anderen Gruppe (16 Hunde) mit der Polyvinylchlorid-Auffüllungsmethode bzw. der Benzidinreaktion die Untersuchung der Extremitäten-Mikrozirkulation stattfand.

Unter Wirkung der venösen Dauerokklusion haben sich die totale Durchblutung der Extremitäten nur kleingradig, die nutritive Durchblutung der Extremitäten dagegen in bedeutendem Maße verringert. Der Sauerstoffgehalt des venösen Extremitätenbluts stieg an, während sich die arteriovenöse Sauerstoffdifferenz der Extremitäten, wegen der Öffnung der arteriovenösen Shunts verringerte.

Die Entwicklung des arteriovenösen Shuntkreislaufs wurde mit Korrosionsuntersuchungen auch unmittelbar bestätigt. Anhand der Versuchsergebnisse und der diesbezüglichen Literaturdaten werden Reihenfolge und Pathomechanismus der sich nach Venenverschluß entwickelnden Änderungen des Extremitätenkreislaufs besprochen.

Изменение кровообращения в конечности при закупорке вены — глубоком венозном тромбозе

Ф. ШОЛТИ, Л. ШОЛТЕС, ДЬ. УНГВАРИ, Л. СЛАВИ и П. ГЛОВИЦКИ

У 12 больных, страдающих односторонним тромбозом глубоких вен конечности, авторы изучали изменения кровообращения в конечности, наступающие в ответ на венозную закупорку. Кровообращение исследовали методом разведения изотопа при внутривенном введении. Для дополнения клинических исследований выполнили опыты на 30 собаках, у которых вызывали одностороннюю венозную закупорку перевязкой бедренной вены на одной стороне. У 14 животных введением изотопа рубидия измеряли нутритивный (кожа и мышца) кровоток в обеих задних конечностях. У 16 собак изучали микроциркуляцию в конечности методом заполнения поливиналхлоридом или с помощью бензидиновой реакции.

Под влиянием продолжительной венозной окклюзии тотальный кровоток в конечности снижался лишь в небольшой степени, нутритивный же (мышца и кожа) кровоток в конечности уменьшался значительно. Содержание кислорода в венозной крови конечности возрастало, артериально-венозная разница в содержании кислорода уменьшилась вследствие открытия артериовенозных шунтов.

Dr. Ferenc Solti
Dr. Lajos Soltész
Dr. György Ungvári
Dr. László Szlávi
Dr. Péter Gloviczki

Institute of Vascular Surgery,
Semmelweis University Medical School,
Budapest, Városmajor u. 68, H-1122

Acta Chirurgica Academiae Scientiarum Hungaricae, Tomus 23 (3), pp. 153—162 (1982)

Elektrometrische Messungen (pH, pK) auf der Organoberfläche bei experimenteller Änderung des Leberkreislaufes

A. ANTAL und J. LANTOS

Institut für Experimentelle Chirurgie der Medizinischen Universität, Pécs

(Eingegangen am 24. April 1981)

Bei 26 Hunden wurden auf der Leberoberfläche die pH-Werte und die K^+-Konzentration kontinuierlich gemessen. Der A. hepatica-Ligatur zufolge erschienen dieselbe pH-Verringerung und derselbe Anstieg der K^+-Konzentration wie bei der Unterbrechung des arteriellen und portalen Kreislaufs. Durch Reperfusion wurden die beschriebenen Veränderungen auch nach 45minütigem provisorischem Kreislaufstillstand behoben. Durch Arterialisation der V. portae konnte die Wirkung der A. hepatica-Ligatur akut abgewehrt werden.

Die intrahepatische Verteilung des durch die Leber strömenden arteriellen und portalen Blutes gilt im wesentlichen für geklärt, obwohl sich betreffs der Rolle der doppelten Kapillarisation im Stoffwechsel keine einheitliche Meinung ausgebildet hat [3, 6, 10, 15]. Demnach scheint die weitere Untersuchung der Frage nicht nur von experimentell-pathologischer Sicht, sondern auch im Interesse der exakten Durchführung der extrakorporalen Leberperfusion bzw. ihrer Auswertung aktuell zu sein.

Eine Möglichkeit der direkten Untersuchung des Organstoffwechsels bieten — unter Versuchsverhältnissen — die elektrochemischen Verfahren [5, 12]. Mit Hilfe der auf die Organoberfläche angebrachten selektiven Elektroden können nämlich der Druck des zur Verfügung stehenden Sauerstoffs, die wichtigeren Parameter der Stoffwechselprozesse, pH oder irgendein indirekter Indikator der Zellregulation, z.B. die Kaliumkonzentration laufend gemessen werden. Durch die Befunde dieser Untersuchungen werden zur Charakterisierung der arteriellen und portalen Kreislaufstörungen der Leber brauchbare Daten geliefert [1, 13, 14].

In vorliegender Arbeit finden unsere auf der Leberoberfläche mit pH- und Kaliumelektroden während der provisorischen Unterbrechung, Wiederherstellung und vorübergehendem Austausch des arteriellen und portalen Kreislaufs ermittelten Daten eine Besprechung.

Material and Methodik

Die Experimente wurden an 26, 12 bis 24 kg wiegenden Mischlingshunden vorgenommen. 30 Minuten vor dem Eingriff erhielten die Hunde 0,03 mg/kg Fentanyl, 1 mg/kg Droperidol und 0,05 mg/kg Atropin i.m.; nach der i.v. Verabreichung von 20 mg/kg Hexobarbital-Natrium wurde endotracheal intubiert, sodann mit einem Narkoseapparat Medimorph (Leipzig) ein $N_2O + O_2$-Gemisch (3:1) beatmet und mit 0,25–0,3 mg/kg Tubocurarin relaxiert. Zwecks Verhinderung der intravasalen Blutgerinnung wurde den Tieren auch 0,8 mg/kg Heparin verabreicht.

Nach Medianthorakolaparotomie wurden je ein langer Abschnitt der A. hepatica und der V. portae herauspräpariert und ihr Kreislauf den Versuchsgruppen entsprechend reguliert. Zunächst wurden die Meßelektroden sorgfältig auf die ventrale, intakte Leberoberfläche placiert. Zur Messung des Gewebe-pH-Wertes diente eine dem präzisions-digitalen pH-Meßgerät Typ RADELKIS OP 208 angeschlossene Glaselektrode vom Typ RADELKIS OP 803 und zur Bestimmung der Kaliumkonzentration eine Kaliumelektrode vom Typ RADELKIS OP–K 71 11 D, die einem Präzisions-pH-Meßgerät vom Typ RADELKIS OP 205 angeschlossen war. Die Registrierung der gemessenen Werte erfolgte mit einem Kompensograph vom Typ RADELKIS OH 814/1. Die Elektroden wurden vor und nach dem Experiment mit einer Präzionspufferlösung kalibriert. Außer diesen Bestimmungen wurden auch die Temperatur der Leberoberfläche und die Kerntemperatur mit Hilfe von Elektrothermometern gemessen. Zu Beginn der Versuche wurden ferner auch die Säure-Basen- und Elektrolytwerte bestimmt. Der zentrale Blutdruck wurde während der gesamten Versuchsdauer registriert. Bei der Auswertung wurden nur die Daten jener Präparate berücksichtigt, deren arterieller Druckwert zu Beginn über 11 pKa lag. Auf dieselbe Weise wurden auch die Ausgangs-Blutgaswerte stabilisiert.

Versuchsgruppen

Gruppe I. Mit Hilfe eines rund um die A. hepatica geführten Fadens und eines Tourniquets wurde die arterielle Strömung provisorisch unterbrochen und die Folgen des Kreislaufstillstandes sowie die der darauffolgenden Reperfusion registriert. Nach der Normalisierung der Werte kam es erneut zur Abklemmung der Arterie (nach länger anhaltender Abklemmung konnten wir nur eine Beobachtung vornehmen; 26 Fälle).

Gruppe II. Die provisorische Unterbindung der V. portae wurde ähnlich wie in Gruppe I vorgenommen; die Dauer der Kreislaufunterbrechung betrug 30 und 45 Minuten. Während dieser Zeit entwickelte sich immer eine akute portale Stauung (präportaler Block) (10 Fälle).

Gruppe III. Unter denselben Versuchsverhältnissen, wie bei Gruppe II wurde zwecks Behebung der portalen Stauung mittels eines silikonisierten Kunststoffrohrs ein portofemoraler Shunt angelegt (3 Fälle).

Gruppe IV. Der portofemorale Shunt funktionierte auch während der 15-, 30- und 45minutigen Abklemmung beider Leber verlaufenden Gefäße (A. hepatica und V. portae) (13 Fälle).

Gruppe V. Portale Arterialisation: Aus einer systemischen Arterie wurde das arterielle Blut mit Hilfe eines silikonisierten Kunststoffrohrs mit Hochdruck in den Stumpf der V. portae geleitet, während sich zwischen dem distalen Stumpf der V. portae und der V. femoralis ein Shunt bildete (5 Fälle).

Die Auswertung der Ergebnisse erfolgte mit der *t*-Zweistichprobe.

Ergebnisse

Anhand der elektrometrischen Kontrollmessungen haben sich die Oberflächen-pH-Werte im Laufe der auf die Herauspräparierung der A. hepatica und V. portae folgenden 60minütigen Beobachtungsperiode, nebst intaktem Leberkreislauf als stabil erwiesen ($7{,}25 \pm 0{,}09$).

In Gruppe I wurde die Wirkung der Arterienligatur untersucht. Die pH-Werte haben sich in den ersten 5 Minuten nach der Ligatur ausgeprägt, sodann langsamer, aber laufend vermindert. Nach Lösung der Ligatur hörte die Senkung des pH-Wertes rasch auf und zwar unabhängig davon, ob die Kreislaufunterbrechung 5, 15, 30 oder 45 Minuten dauerte (Abb. 1).

In Gruppe II wurde die Wirkung des Strömungsstillstandes der V. portae untersucht. Die der Ligatur der V. portae zufolge bei dieser Gruppe zustandegekommenen Änderungen schienen bedeutend zu sein. Unter Berücksichtigung des durch die portale Stauung verursachten Blutvolumenmangels und seiner Konsequenz, namentlich der Hypotension von Schokintensität, ließ es sich feststellen, daß die primäre Ursache der beobachteten pH-Änderung aller Wahrscheinlichkeit nach die Verringerung der akuten arteriellen Perfusion war (Abb. 2).

In Gruppe III wurde die Wirkung der Ligatur der V. portae unter Eliminierung des Blutdruckabfalls untersucht. Es zeigte sich, daß durch Abklemmung der V. portae unter den gegebenen Verhältnissen keine wesentliche Verringerung des pH-Wertes herbeigeführt wird (Abb. 3).

Die Totalischämie der Leber geht dagegen mit ausgeprägten Veränderungen einher (Gruppe IV). Unter Wirkung der provisorischen Ligaturen entwickelten sich innerhalb der untersuchten Zeitintervallen markante, reversible Veränderungen (Abb. 4). Wie es aus den Abb. 1 und 4 hervorgeht, besteht zwischen den Wirkungen des totalen und partiellen (wenn nur die A. hepatica abgeklemmt war) Kreislaufstillstandes (im Laufe der Vergleichung der in

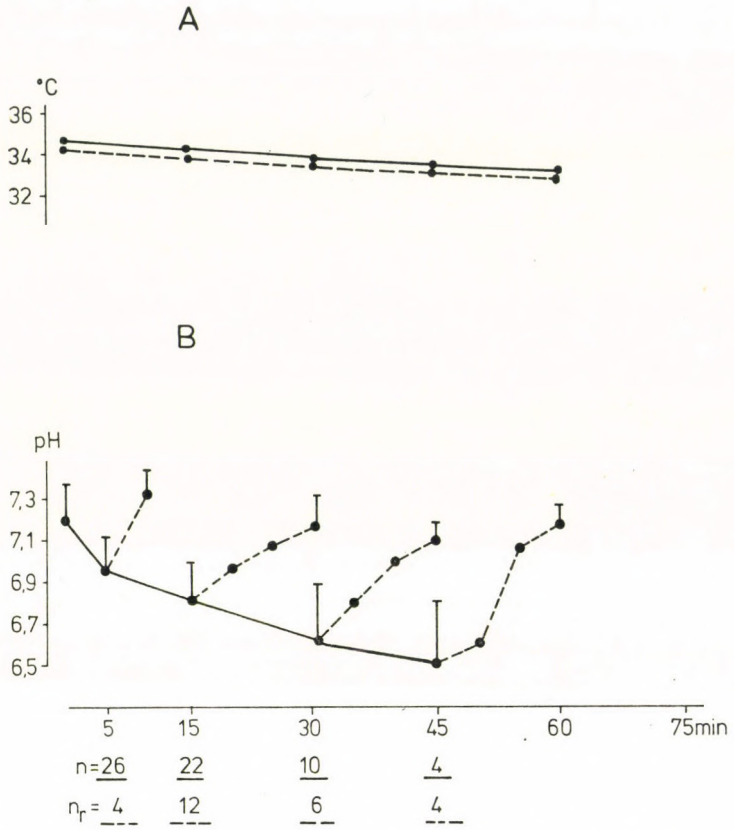

ABB. 1. Änderungen des Organoberflächen-pH-Wertes unter Wirkung der provisorischen Ligatur der A. hepatica. *A* ——— = Kerntemperatur; — — — — — Temperatur der Organoberfläche; *B* ——— = Ligaturzustand; — — — — — Reperfusionszustand

identischen Zeitpunkten irgendwelcher Untersuchungen beobachteten pH-Werte) kein Unterschied. Die Wirkungen des Perfusions-Druckabfalls und der mit Schockkreislauf einhergehenden V. portae-Ligatur sind einander äußerst ähnlich, d.h., daß die Verringerung der pH-Werte offensichtlich durch den Mangel der arteriellen Perfusion verursacht wird.

Schließlich untersuchten wir bei Gruppe V die Reversibilität des totalen Ischämiezustandes mittels Perfundierung der V. portae mit arteriellem Blut. Durch diesen Eingriff wurden die pH-Abnahme und die Erhöhung der Kaliumkonzentration (die sich in jeder Hinsicht den Vorangegangenen entsprechend entwickelten) nicht nur behoben, sondern es kam sogar zur Normalisierung der erwähnten Parameter (Abb. 5).

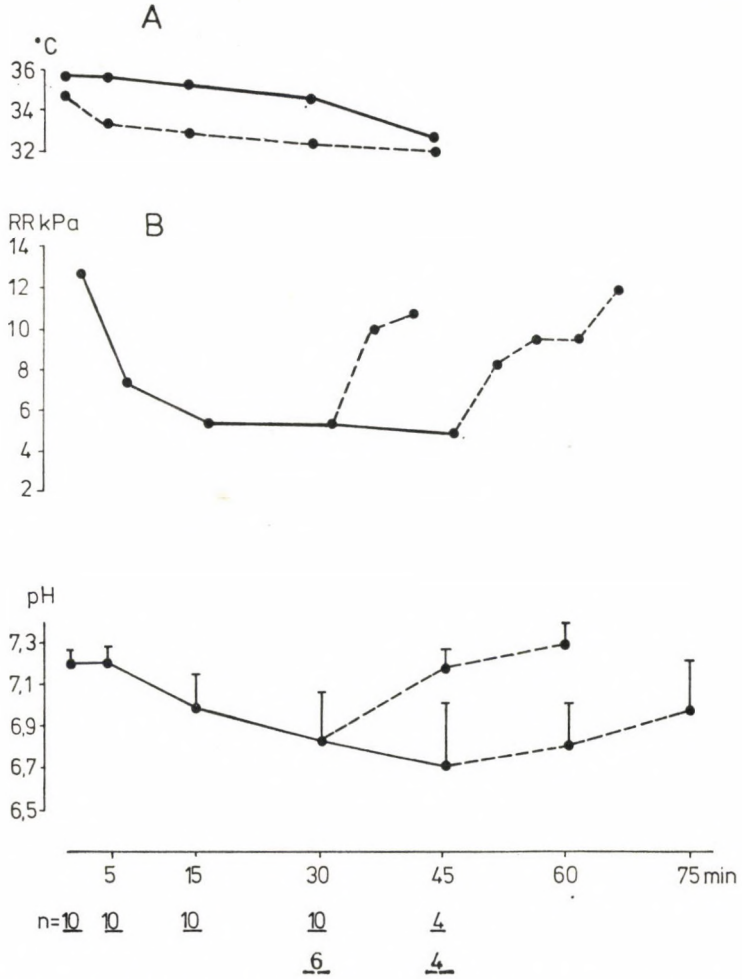

ABB. 2. Wirkung der Ligatur und der Reperfusion der V. portae. Die Markierungen sind dieselben, wie in Abb. 1

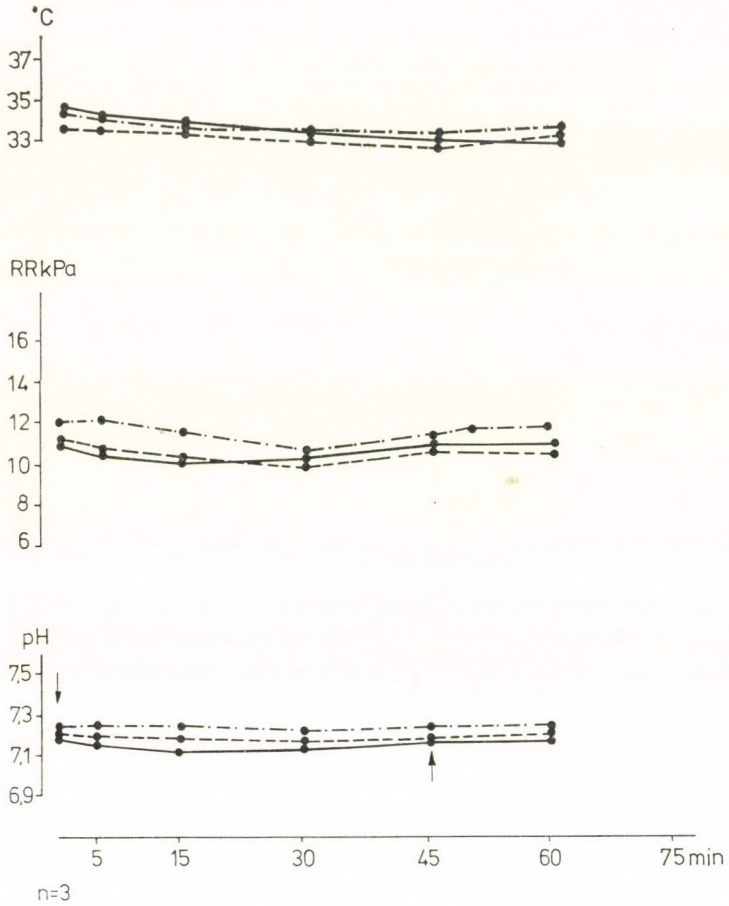

Abb. 3. Wirkung der provisorischen Ligatur der V. portae ohne Stauung. = Beginn der Ligatur; Fall = Lösung der Ligatur. Fall *a* = ————; *b* = — — — — —; Fall *c* = —.—.—.

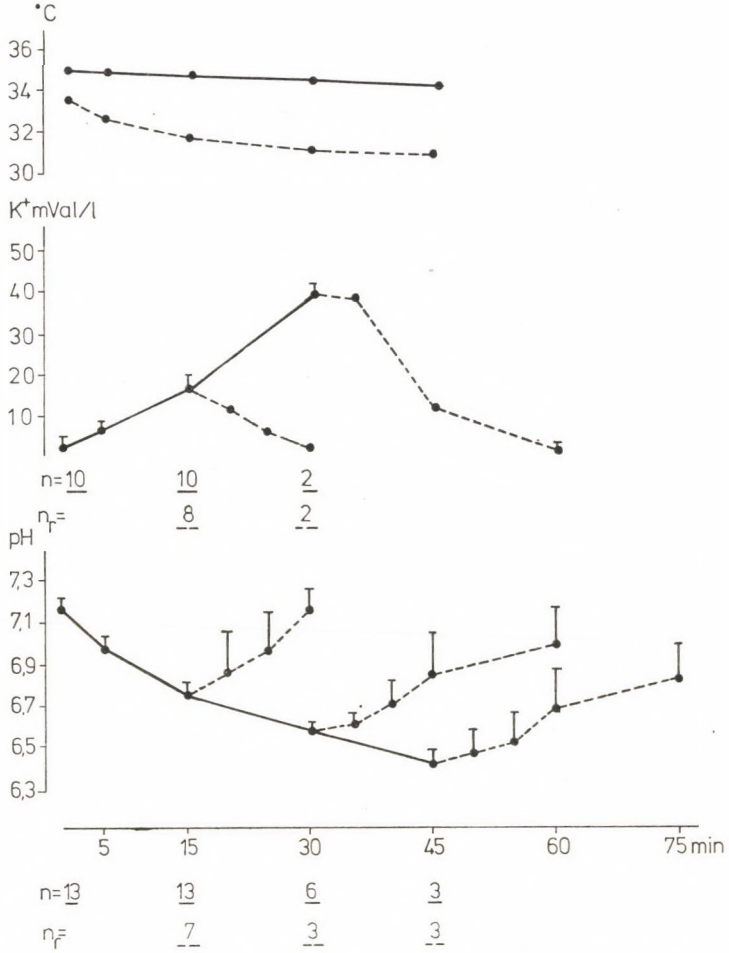

ABB. 4. Wirkung der provisorischen Sistierung des Leberkreislaufs. Die Markierungen sind dieselben wie in Abb. 1

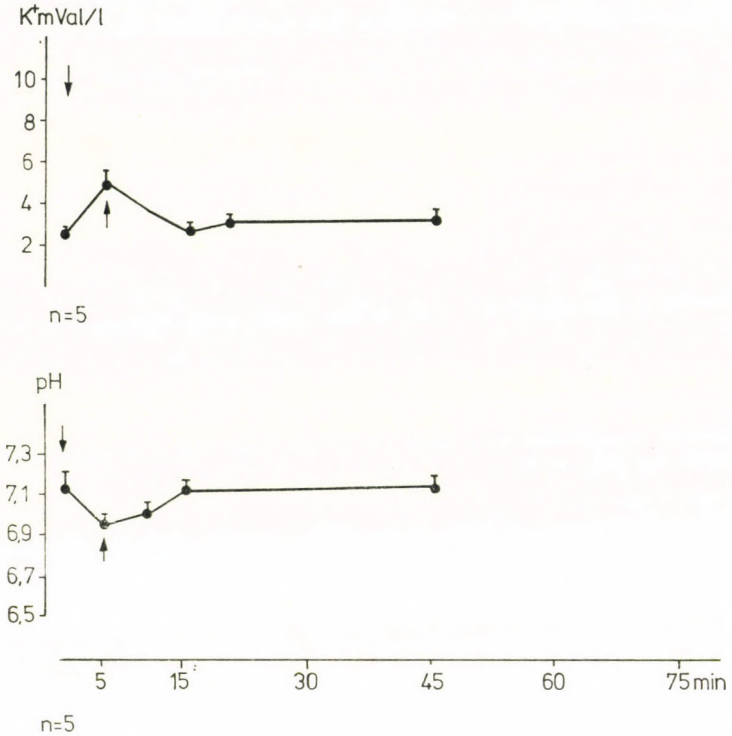

ABB. 5. Wirkung der nach 5minutiger Ischämie folgenden portalen Arterialisation = Ligatur der A. hepatica und der V. portae; = Arterialisation der V. portae

Beschprechung

Unsere Versuchsdaten liefern einen Beweis dafür, daß zwischen der aktuellen Gewebeperfusion der Leber und der auf der Organoberfläche meßbaren Wasserstoff- und Kaliumionkonzentration eine enge Korrelation besteht — welche Feststellung mit den bei isolierter Rattenleber mit ähnlichen Methoden ermittelten Daten von Höper und Mitarb. [8] übereinstimmt. Die Änderungen der sich auf Ischämie und Reperfusion beziehenden pH-Oberflächenwerte zeigen eine große Ähnlichleit mit den bei ischämischen und reperfundierten Nieren gewonnenen früheren Daten [4]. Die im beobachteten Zeitintervall als reversibel gefundenen pH-Änderungen sind mit den sich auf die Ischämietoleranz der Leber beziehenden Daten identisch [2, 9, 11].

Insofern nur die arterielle Strömung sistiert und die portale Zirkulation ungestört ist, findet man dieselbe pH-Verringerung, wie beim Verschluß beider Gefäße. Das bedeutet offensichtlich soviel, daß das in großen Mengen und über

einen bedeutenden Sauerstoffgehalt, aber mit niedrigem Druck strömende portale Blut im Zellstoffwechsel bzw. in der Zellvolumenregulation eine nur geringe akute Rolle spielt.

Nach der provisorischen Ligatur der V. portae melden sich entscheidende Unterschiede davon abhängig, ob vom hinter der Ligatur liegenden Gebiet das stauende Blut abgeleitet oder nicht abgeleitet wurde. Die Stauung eines bedeutenden Teiles der zirkulierenden Blutmenge hat nämlich Blutmangel und Blutdruckabfall zur Folge, wodurch die arterielle Perfusion verständlicherweise beeinflußt wird. Die Hypotension herbeiführende Wirkung der portalen Ligatur und so auch die Verringerung der arteriellen Perfusion können mit einem portofemoralen Shunt vollkommen eliminiert werden, während dessen sich nicht einmal die pH-Oberflächenwerte wesentlich ändern. Durch diese Beobachtung wird die primäre Rolle der A. hepatica in der Blutversorgung unterstützt.

Mit Hilfe der portalen Arterialisation können die Ausgangswerte des Oberflächen-pH-s und Kaliums normalisiert bzw. auf dem Ausgangsniveau gehalten werden, welche Beobachtung einen Beweis für die normale Funktion des Leberzellstoffwechsels und der Regulation liefert. Dieser Befund scheint die Ansicht jener Autoren zu unterstützen, laut der die portale Arterialisation die Leberstruktur zu schützen vermag [7, 16].

Aus unseren Experimenten lassen sich folgende Konsequenzen ziehen:

1. Unter intakten Verhältnissen wird der zum Leberstoffwechsel nötige Sauerstoff durch die A. hepatica transportiert;

2. durch die Arterialisation der V. portae können die normale Konzentration des Oberflächen-pH-s und der Kaliumione akut gesichert werden.

Vorliegende Untersuchungen waren auf die Klärung der Einzelheiten der von Richtung des portalen System her stattfindenden Sauerstoffversorgung (Zusammenhänge mit dem Blutdruck und dem Blutsauerstoffniveau) gerichtet.

Literatur

1. Broelsch CHE, Gruen M, Andrcejewsky W, Kessler M: Hemodynamics and local oxygen tension of the rat liver following various portosystemic shunting procedures. Europ Surg Res 11: Suppl. 2, 18, 1979
2. Farkouh EF, Daniel AM, Beaudoin IG, MacLean LD: Predictive value of liver biochemistry in acute hepatic ischemia. Surg Gynecol Obstet 36: 833, 1971
3. Greenway CV, Stark RD: Hepatic vascular bed. Physiol Rev 51: 23, 1971
4. Halmágyi Gy, Lantos J, Havas J: Elektrometriás felszíni pH-mérés ischaemizált és reperfundált kutyaveséken (Elektrometrische oberflächliche pH-Messung der ischämisierten und reperfundierten Hundennieren.) Orvos Techn 14: 97, 1976
5. Halmágyi Gy, Lantos J, Török B: pH-map of the stomach of normal and vagotomized dogs. Acta Chir Acad Sci Hung 19: 343, 1978
6. Hasselgren PO, Almersjö O, Gustavsson B, Torsten S: Liver circulation and oxygen metabolism during short time ligation of the hepatic artery in the dog. Acta Chir Scand 145: 471, 1979

7. Hemptine B, Mello M, Bollet TH, Lambotte L, Otte B: Immediate modification of liver function after porto-caval shunt and arterialization. Europ Surg Res 11: Suppl. 2, 25, 1979
8. Höper J, Kessler M, Simon W: Measurements with ion-selective surface electrodes (pK, pNa, pCa, pH) during no-flow anoxia. In: Ion and Enzyme Electrodes in Biology and Medicine, ed. Kessler M, Clark LC jr, Lübbers DW, Silver IA, Simon W. Urban und Schwarzenberg, München–Berlin–Wien 1976, p. 331
9. Huguet C, Nordlinger B, Bloch P, Conarad I: Tolerance of the human liver to prolonged normothermic ischaemia: A biological study of 20 patients submitted to extensive hepatectomy. Arch Surg 113:1448, 1978
10. Imamura M, Suzuki T, Nakase A, Honjo I: Hemodynamic changes in the liver of the rabbit after hepatic dearterialization. Surg Gynecol Obstet 140: 412, 1975
11. Kupcsulik P, Szekeres M: Kísérletes modell az ischaemiás májkárosodás tanulmányozására patkányon (Versuchsmodell zur Untersuchung der ischämischen Leberschädigung bei Ratten.) Magy Seb 30: 231, 1977
12. Lantos J, Halmágyi Gy: A szöveti oxigéntenzió amperometriás meghatározása saját készítésű Clark-típusú membránnal borított elektróddal (Amperometrische Bestimmung des Sauerstoffdrucks der Gewebe mit selbsterzeugter, mit Membran von Typ Clark bedeckter Elektrode.) Kísérl Orvostud 29: 298, 1977
13. Kessler M, Höper J: Possible influence of local ion activities on redistribution of microcirculation. Arzneim Forsch 28: 869, 1978
14. MacDonald AC, Marble AE, Perkins IG: Hepatic blood flow and metabolism. Arch Surg 114: 616, 1979
15. Magna A, Lars I: Decrease of oxygen consumption in the dog liver during temporary arterial occlusion. Acta Physiol Scand 98:103, 1976
16. Saric J, Faugan H, Belliard R, Perissat I, Balabaud C, Bioulac P: Beneficial effect of portal arterialization on bile flow and hepatic ultrastructure in rats with portocaval shunt. Europ Surg Res 12:1, 1980

Electrometric Measurements (pH, pK) on the Surface of the Liver during Experimental Changes of Hepatic Circulation

A. Antal und J. Lantos

In 26 dogs, pH and K^+-concentration measured continuously on the surface of the liver. The same decrease of pH and increase of the K^+-concentration was found after ligation of the hepatic artery as when arterial and portal circulations were suspended. Reperfusion restored normal conditions even after 45 minutes of circulatory arrest. Arterialization of the portal vein abolished the effect of the ligation of the hepatic artery.

Электрометрическое измерение pH и pK на поверхности органов при экспериментальных изменениях кровообращения в печени

А. АНТАЛ и Й. ЛАНТОШ

В 26 экспериментах на собаках авторы непрерывно измеряли электрометрическим методом pH и концентрацию ионов калия на поверхности печени. После перевязки почечной артерии наблюдалось такое же уменьшение значения pH и увеличение концентрации K^+, как и во время прекращения артериального и портального кровообращения. Повторные перфузии после временной — даже 45-минутной — остановки кровообращения нормализовали развившиеся изменения. Артериализация портальной вены была способна моментально предотвратить воздействие лигатуры печеночной артерии.

Dr. András Antal
Dr. János Lantos
Institut für Experimentelle Chirurgie der Medizinischen Universität, Pécs, Kodály u. 20, H-7643

Acta Chirurgica Academiae Scientiarum Hungaricae, Tomus 23 (3), pp. 163—171 (1982)

Angioneurotisches Ödem und Hypokomplementämie bei Schilddrüsenkarzinom

K. VALLENT,[1] J. FEHÉR,[2] Anikó SOMOGYI[2] und Ágnes JOÓS[3]

I. Chirurgische Klinik[1], III. Medizinische Klinik[2] und I. Pathologisch-Anatomisches Institut[3] der Medizinischen Universität Semmelweis, Budapest

(Eingegangen am 13. August 1981)

Nach Erläuterung der Ätiologie und der Symptome des mit der Störung des Komplementsystems einhergehenden angioneurotischen Ödems und der malignen Tumoren wird betont, daß sich nach der chirurgischen Entfernung der bösartigen Geschwulst der pathologische Komplementspiegel normalisieren und das angioneurotische Ödem ausheilen kann. Im dargestellten Fall wiesen auf die Anwesenheit des Schilddrüsenkarzinoms das angioneurotische Ödem, die Störung der Komplementkomponenten und die mit Schilddrüsenszintigraphie beobachtbare Abweichung hin. Nach der Thyreoidektomie waren die klinische Heilung des angineurotischen Ödems und die Normalisierung der Störung des Komplementkomponenten zu verzeichnen. Der dargestellte Fall ist ein überzeugendes Beispiel dafür, daß im Hintergrund des erworbenen angioneurotischen Ödems nebst lymphoproliferativer Krankheit, Autoimmunkrankheit oder Mastdarmkrebs auch ein Schilddrüsenkarzinom stehen kann.

Das sowohl in angeborener, als auch in erworbener Form bekannte angioneurotische Ödem ist eine mit der Störung des Komplement- und Protease-Inhibitorsystems und konsekutivem akuten Ödem einhergehende Krankheit [3, 9, 21]. Was die klinischen Symptome anbelangt, ist das erworbene angioneurotische Ödem der hereditären Form ähnlich, das ersterwähnte Krankheitsbild ist aber nicht erblich, und in der Anamnese des Patienten können häufig irgendeine Allergie oder eine andere Krankheit nachgewiesen werden. Das klinische Bild beider Formen ist durch periodisch zurückkehrende, 6–24 Stunden lang anhaltende, ein akutes Ödem der subakutanen Gewebe, des hinteren Rachens und der Atemwege herbeiführende, akute Symptome charakterisiert [1, 6, 10, 11, 14, 18]. Bei der sog. abdominalen Form des angioneurotischen Ödems dominieren die durch das Ödem der Darmschleimhaut bedingten Symptome, sowie Brechreiz, Erbrechen, Bauchschmerzen und Ileus [2, 18, 20].

Ein weiterer, gemeinsamer, charakteristischer Zug der beiden angioneurotischen Ödemformen manifestiert sich darin, daß sich unter den Komplementkomponenten der Spiegel des Cl-Esteraseinhibitors verringert [14, 17, 20], was die Aktivierung der Cl Komplementkomponente und die gesteigerte Verwertung der Komplementkomponenten C2 und C4 zur Folge hat [12, 15, 16]. Für die Entwicklung der Symptome sind die aus der Komponente C2

freiwerdenden vasoaktiven Polypeptide verantwortlich. In den vergangenen Jahren machten einige Autoren darauf aufmerksam, daß das erworbene angioneurotische Ödem und maligne Tumoren auch gleichzeitig vorkommen können [1, 5]. Weitere Mitteilungen berichteten darüber, daß sich bei den Autoimmun- und Tumorkranken auch der Spiegel des Komplementkomponenten C3 ändert [8, 22]. Ein angioneurotisches Ödem wurde bei lymphoproliferativen Erkrankungen (Lymphosarkom, Myelofibrose, chronisch lymphatische Leukämie), systemischem Lupus erythematosus und sonstigen Gammopathien beobachtet [3, 4, 7, 8, 17, 21, 24, 25].

Die Leitsymptome, die unsere Aufmerksamkeit im dargestellten Fall auf die Möglichkeit einer malignen Tumorkrankheit lenkten, waren das angioneurotische Ödem und die pathologische Änderung des Komplementkomponenten-Spiegels. Die komplexen klinischen, immunologischen und Isotopenuntersuchungen wiesen auf eine Schilddrüsenkrankheit hin, während die tumoröse Infiltration des Prozesses anhand der Aspirationszytologie diagnostiziert werden konnte. Die im Besitz des Befundes durchgeführte totale Schilddrüsenexstirpation war erfolgreich, das angioneurotische Ödem hörte auf und der Spiegel der Komplementkomponenten normalisierte sich.

Falldarstellung

In der Anamnese der 43jährigen Patientin J.P. kamen Varizektomie, Kaiserschnitt, Lungen- und Lungenfellentzündung vor, während aus ihrer familiären Anamnese das Asthma bronchiale des Vaters hervorzuheben ist.

Die etwa 4 Monate vor der stationären Aufnahme aufgetretenen unangenehmen Erscheinungen – symmetrische Anschwellung und Röte der periorbikularen Regionen, dunkelrote Hautverfärbungen, Ermüdbarkeit, Herzklopfen, anfallartiges spastisches Schweratmen – veranlaßten Patientin ihren Arzt zu konsultieren. Davon ausgehend, daß es sich um allergisch bedingte Beschwerden handelt, wurde ihr bei dieser Gelegenheit eine Prednisolon-Kur verordnet. Die Beschwerden, die Hautsymptome inbegriffen, zeigten eine vorübergehende Besserung. Die Klinikaufnahme erfolgte zwecks Klärung des allergischen Ursprungs.

Aufnahmezustand

Physikalische Untersuchung: Fettsucht. Die Haut beider geschwollenen Augenlider ist dunkelrot. Über den Lungen Zellatmen, Pfeifen und Giemen; keine Herzvergrößerung, reine Herztöne. Puls: 80/min, normal; BR: 160/100 mm Hg. Weicher, gut palpierbarer Bauch, geheilte Narbe einer unteren Medianlaparotomie. Leber und Milz nicht palpierbar. Nervensystem: mäßiger Exophthalmus, regere Sehnenreflexe.

Thoraxröntgen: Normale Zwerchfellbewegungen, der linke Zwerchfellbogen ist lateral- und dorsalwärts hochgezogen; im Sinus ein querfingerbreiter, sich der Thoraxwand entlang verschmälender Pleuralschatten. Im linken Hilus einige kleinere, kalkige Lymphknoten. Form und Größe des Herzens, Aorta und Retrokardium entsprechen der Norm.

Magen-Darmröntgen: Ungehindertes Schlucken, Verlauf und Weite des Ösophagus sind normal, die Konturen intakt. Guter Tonus des hackenförmigen, hoch im Epigastrium liegenden Magens.

Irrigoskopie: Das Kolon kann restlos aufgefüllt werden. Auf dem aboralen Abschnitt des Sigmas, das eine lange sich kranialwärts beugende Schlinge bildet, kann während der Auffüllung mäßige Irritation beobachtet werden. Normale Anordnung, intakte Konturen der Gedärme.

Rektale Digitaluntersuchung: negativ.

Rektoskopie: Bis 22 cm kann das Instrument ungehindert eingeführt werden, keine organischen Veränderungen.

Gynäkologische Untersuchung: Innere und äußere Genitalien sind normal, Portion: o.B.

Laboruntersuchungen: Harn: spez. Gewicht: 1016–1022, Eiweiß: negativ, Sediment: vereinzelte Leukozyten, VDRL: negativ.

Blutsenkungsgeschwindigkeit: 16 mm/St, Hgb: 8,8 mmol/l, Leukozytenzahl 8300, qualitatives Blutbild: keine Abweichung. Blutzucker: 4,5 mmol/l, Serum-Bilirubin: 16,6 μmol/l, Serum-Natrium: 136 mmol/l, Serum-Kalium: 4,9 mmol/l, BUN 4,3 mmol/l, Kreatinin-Clearance: 1,56 ml/min, Serum-Kreatinin: 74 μmol/l, Serum-Gesamteiweiß: 76 g/l, Serum-Cholesterin: 4,5 mmol/l, Serum-Triglyzerid: 1,53 mmol/l.

Bencard–Prick-Tests: *a.* sehr stark positiv (++++): B2 (Gras) und A3 (Getreide), *b.* positiv (+): 14 sonstige Tests. Immunkomplex: negativ, Kryoglobulin: negativ.

EKG: Sinusrhythmus, vertikale R-Achse.

Komplement- und Eiweißuntersuchungen: siehe Tabellen I und II.

TABELLE I

Ergebnisse der Komplementuntersuchungen

	Präoperativ	Postoperativ	Normalwert
Gesamt-komplement	87,0 CH_{50}/ml	72 CH_{50}/ml	48– 103 CH_{50}/ml
C4	33 300 CH_{63}/ml	88 000 CH_{63}/ml	5000–7000 CH_{63}/ml
C3	40 mg/dl	71 mg/dl	70– 180 mg/dl

TABELLE II

Mengen der Se-Eiweiße

	Postoperativ	Präoperativ
Se-Gesamteiweiß	72 g/l	74 g/l
Elfo-Albumin	46 g/dl	45 g/dl
Alfa-1-Globulin	2 g/dl	2 g/dl
Alfa-2-Globulin	12 g/dl	12 g/dl
Beta-Globulin	5+ 13 g/dl	5+11 g/dl
Gammaglobulin	22 g/dl	23 g/dl
Immunglobuline IgA	128 mg/dl	112 mg/dl
IgG	1 800 mg/dl	1600 mg/dl
IgM	140 mg/dl	124 mg/dl
Coeruloplasmin	28 mg/dl	27 mg/dl
Alfa-2-Makroglobulin	385 mg/dl	322 mg/dl
Beta-1-C Globulin (C3 Komp.)	54 mg/dl	103 mg/dl
Transferrin	340 mg/dl	348 mg/dl
Haptoglobin	184 mg/dl	177 mg/dl
Orosomukoid	102 mg/dl	97 mg/dl

Isotopen Untersuchung der Schilddrüse:

1. Jodumsatz

a. Jodaufnahme nach 2 Stunden 21%
nach 5 Stunden 32%
nach 24 Stunden 43%
nach 48 Stunden 33%

b. 48stündige Serumaktivität: 1,25 Dosis % 1, zu 80% Eiweiß gebunden.

2. T-3-Aufnahme: 0,91
3. T-4-RIA: 77 nmol/l
4. Szintigraphie: s. Abb. 1.

Aspirationszytologie: mäßig polymorphe, stellenweise ausdrücklich atypische Drüsenepithelzellen. Malignität wahrscheinlich (Onkopathologisches Forschungsinstitut, Dr. Gábor).

Anhand der angeführten Untersuchungsergebnisse wurde Patientin zwecks Durchführung der Thyreoidektomie in die I. Chirurgische Klinik der Medizinischen Universität Semmelweis verwiesen.

Aufnahme: 6.1.1980, Entlassung: 19.1.1981.

Diagnose: Schilddrüsentumor, angioneurotisches Ödem.

Operative Vorbereitung: Diazepam, Clemastin, Diaphyllin, Ca-Thenalidin, Plummersche Vorbereitung, Vitamin-C, Heparin sc.

Narkose: Intratracheal Lachgas + O_2.

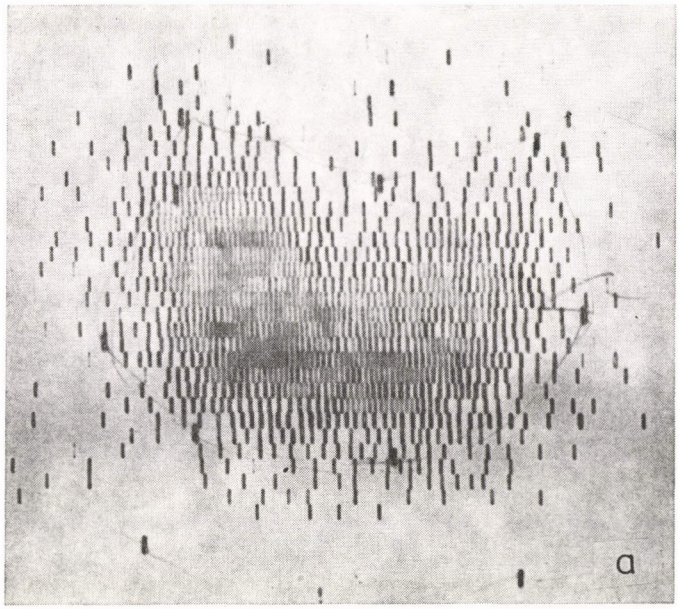



Abb. 1. Schilddrüsenszintigraphie vor und nach der Thyreoidektomie. *a*. Schilddrüse mit breiterem Isthmus, inhomogene Aktivitätsverteilung, verringerte Aktivität im linken Lappen. *b*. Keine bewertbare Aktivitätsaufnahme im Bereich der Schilddrüse

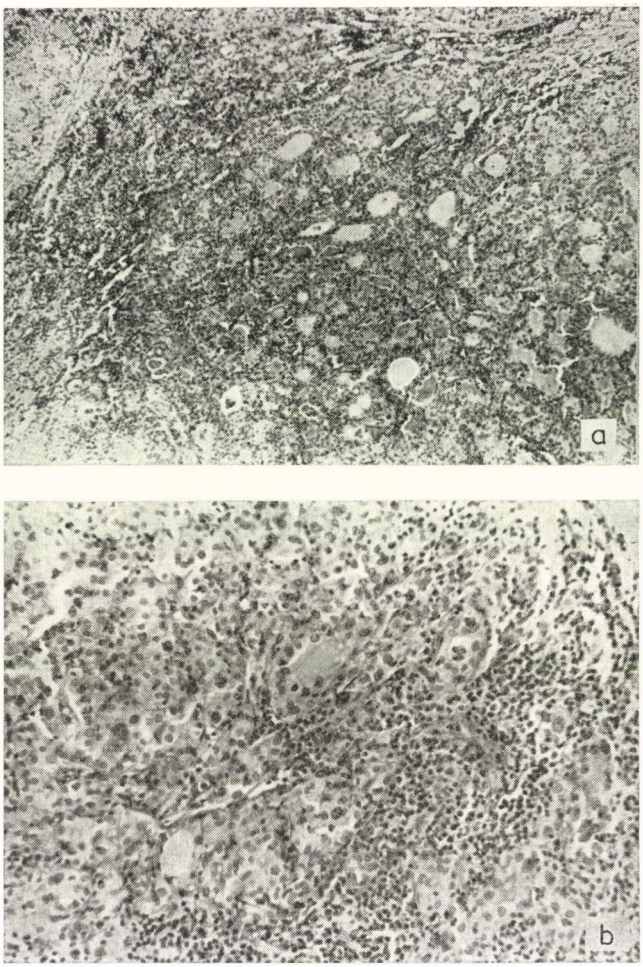

Abb. 2. Histologisches Bild des follikulären Karzinoms. *a*. Übersichtsbild (Häm.-Eo. ×25). *b*. Atypische follikuläre Epithelzellen, unter den Epithelelementen intensive rundzellige Infiltration (Häm.-Eo. ×63)

Operation: totale Thyreroidektomie am 13. 1. 1981.

Kragenschnitt nach Kocher. Die kurzen und langen Halsmuskeln werden in der Mittellinie ohne Durchschneiden getrennt; aus einem der in den Schilddrüsenlappen palpierbaren, zahlreichen harten Knoten wird Material entnommen.

Gefrierschnitt: follikuläres Karzinom.

Nach beidseitiger Unterbindung und Durchtrennung der A. thyreoidea superior werden die A. thyreoidea inferior, die Nebenschilddrüse sowie die extrakapsulär verlaufenden Fasern freigelegt. Isthmisierung in der Mittel-

linie und Totalexstirpation der Schilddrüse. Vereinigung der Halsmuskeln, Saugdrainage, Platysma-Naht, Klammern, Verband.

Histologische Diagnose: Carcinoma folliculare glandulae thyreoidae (Dr. Joós). In Lappen gegliedertes Tumorgewebe mit follikulärer Struktur. Die Follikel sind mit atypischen Epithelzellen ausgekleidet. Im Lumen tritt stellenweise eosinophile, homogene Substanz in Erscheinung, an anderen Stellen sind die Lumina eng und enthalten kein Sekret. In dem die Substanz zergliedernden, in unterschiedlichen Mengen beobachtbaren Gewebsstroma ist rundzellige Infiltration ersichtlich und auch im Tumor sieht man eine fokale bzw. diffuse lymphoidzellige Infiltration (Abb. 2).

Postoperativer Krankheitsverlauf: Nach dem Eingriff wurde Patientin in geregeltem Kreislauf- und Atmungszustand zuerst in der Intensivstation gepflegt. Therapie: Täglich 3-mal Dihydroergotoxin (Redergam)-Cocktail, (Plummersche Lösung in abnehmenden Dosen, Ca-Sandosten, zwecks Thromboseprävention 2×5000 IE Heparin sc. Sobald ihr Zustand es zuließ, erfolgte die Verlegung der Patientin in die Abteilung für Allgemeinchirurgie und später, nach Wundheilung per primam und Entlassung der Patientin, in geheiltem Zustand, zwecks weiterer Behandlung und Durchführung der Kontrolluntersuchungen in die III. Medizinische Klinik.

Besprechung

Die ersten Beschreibungen des angioneurotischen Ödems stammen aus 1872 und 1888 aus der Feder von Quincke [10] und Osler [23]. Landerman [19] stellte anhand der Analyse des Schrifttums fest, daß die Mortalität des Krankheitsbildes zwischen 15% und 30% liegt. Die Geschlechtsverteilung zeigt keine nennenswerten Unterschiede. Im Pathomechanismus der Krankheit spielen der verringerte Komplementkomponenten-Spiegel und die Störung des Protaease-Enzymsystems eine wichtige Rolle. Die jüngsten Literaturangaben wiesen auf den zwischen den malignen Tumoren und den angioneurotischen Ödem bestehenden Zusammenhang hin [3, 5]. Im dargestellten Fall waren es ebenfalls das angioneurotische Ödem und die Abweichung der Komplementkomponenten, die den Verdacht eines bösartigen Tumors erweckten. Die Tatsachen, daß nach der chirurgischen Entfernung die klinischen Symptome des angioneurotischen Ödems aufhörten, sich der pathologische Spiegel der Komplementkomponente C3 normalisierte und auch der C4 Spiegel anstieg, bekräftigen ebenfalls die Möglichkeit eines Zusammenhanges zwischen Tumor und angioneurotischem Ödem. Bei unserer Patientin vermochten wir den Mangel des Esterase-Inhibitors C1 nicht nachzuweisen, welcher Umstand dafür spricht, daß es sich in diesem Fall um die erworbene Form des angioneurotischen Ödems handelte; dies dürfte als eine Teilerscheinung der durch das Tumorgewebe ausgelösten Immunantwort betrachtet werden.

Mit der Darstellung unseres Falles wollten wir darauf aufmerksam machen, daß im Hintergrund des angioneurotischen Ödems auch ein Schilddrüsenkarzinom stehen kann, dessen Verifizierung oder Ausschließung eine vorrangige Aufgabe bedeutet.

Literatur

1. Agostoni A, Bergamaschini L, Martignoni G, Cicardi M, Marasini B: Treatment of acute attacks of hereditary angioedema with Cl-inhibitor concentrate. Ann Allergy 44:299, 1980
2. Beck P, Willis D, Davi GT, Lahmann PJ, Sussmaen M: A family study of hereditary angioneurotic oedema. Quart J Med 42:317, 1972
3. British Medical Journal Editorial: Treatment of angioedema 1:1950, 1979
4. Caldwell JR, Ruddy S, Schur PH, Austen KF: Acquired Cl inhibitor deficiency in lymphosarcoma. Clin Immunol Immunopathol 1:39, 1972
5. Cohen SH, Koethe SM, Kozin F, Rodey G, Arkins JA, Sink JN: Acquired angioedema associated with rectal carcinoma and its response to Danazol therapy. J Allergy Clin Immunol 62:217, 1978
6. Donaldson VH, Rosen FS: Hereditary angioneurotic oedema: the clinical syndrome and its management. Ann Intern Med 84:580, 1976
7. Donaldson VH, Hess EV, McAdams AJ: Lupus erythematosus-like disease in three unrelated women with hereditary angioneurotic oedema. Ann Intern Med 88: 312, 1977
8. Donaldson VH, Hess EV: Effect of Danasol on lupus erythematosus-like disease in hereditary angioneurotic oedema. Lancet ii:1145, 1980
9. Eftekhari N, Milford Ward A, Greaves MW: Protease inhibitor profiles in urticaria and angio-oedema. Br J Dermatol 103:33, 1980
10. El-Chazali AMS: Hereditary angioneurotic oedema. J Laryngol Otol 94: 1075, 1980
11. Frank MM, Gelfard JA, Atkinson JP: Hereditary angioedema: The clinical syndrome and its management. Ann Intern Med 84:580, 1976
12. Füst Gy: A komplementrendszer biológiai szerepe és vizsgálatának klinikai jelentősége (Biologische Rolle des Komplementsystems und die Klinische Bedeutung deren Untersuchung). Orvosképzés 54:163, 1979
13. Füst Gy: Az immun komplexek és a komplement rendszer kölcsönhatása (Wechselwirkung zwischen den Immunkomplexen und dem Komplementsystem). Habilitationsschrift, Budapest 1981
14. Gadek JE, Hosea SW, Gelfand JA, Santaella M, Wickerhauser M, Triantaphyllopoulos DC, Frank MM: Replacement therapy in hereditary angioedema. N Engl J Med 302:542, 1980
15. Gergely J, Ott HH: Az elméleti és klinikai immunológia alapjai (Grundlagen der theoretischen und klinischen Immunologie). Medicina, Budapest 1974, S. 116
16. Gergely J: Immunbiológia (Immunbiologie). Medicina, Budapest 1979, s. 109
17. Hauptmann G, Lang JM, North ML, Oberling F, Mayer G, Lachmann P: Acquired Cl-inhibitor deficiencies in lymphoproliferative diseases with serum immunoglobulin abnormalities. Blut 32:195, 1976
18. Hosea SW, Frank MM: Danazol in the treatment of hereditary angioedema. Drugs 19: 370, 1980
19. Landerman NS: Hereditary angioneurotic oedema. 1. Case reports and review of literature. J Allergy Clin Immunol 33:316, 1962
20. Lancet Editorial: Treatment of hereditary angioedema. 1:417, 1979
21. Nilsen A, Matre R: Acquired angioedema and hypocomplementemia in a patient with myelofibrosis. Acta Med Scand 207:123, 1980
22. Nishioka K, Kawamura K, Hirayama T, Kawashima T, Shimada K, Kogure M: The complement system in tumour immunity: Significance of elevated levels of complement in tumor bearing hosts. Ann NY Acad Sci 276:303, 1976
23. Osler W: Hereditary angioneurotic oedema. Am J Med Sci 95:362, 1888
24. Rosenfeld SI, Staples PJ, Leddy JP: Angioedema and hypocomplementemia: Unusual features of lymphoma. J Allergy Clin Immunol 55:104, 1975
25. Schreiber AD, Zwiman B, Atkins P: Acquired angioedema with lymphoproliferative disorder: association of Cl inhibitor deficiency with cellular abnormality. Blood 48:567, 1976

Angioneurotic Oedema and Hypocomplementaemia in Patients with Thyroid Cancer

K. Vallent, J. Fehér, Anikó Somogyi and Ágnes Joós

The combination with a malignant tumour of angioneurotic oedema (ANO) elicited by a disturbance of the complement system was studied. After surgical removal of the tumour the pathologic complement component level may become normal and the angioneurotic oedema may disappear. In the reported case an angioneurotic oedema, the disturbance of the complement component and scintigraphic deviations of the thyroid suggested the presence of a thyroid carcinoma. After thyroidectomy the ANO disappeared and the complement component returned to normal. This case draws attention to the possibility that, beside lymphoproliferative and autoimmune diseases and cancer of the rectum, carcinoma of the thyroid may also be in the background of angioneurotic oedema.

Клиническая картина ангионевротического отека н гипокомплементемия у вольных с карциномой щитовидной железы

К. ВАЛЛЕНТ, Й. ФЕХЕР, АНИКО ШОМОДИ и АГНЕШ ЙООШ

Авторы анализируют встречаемость ангионевротического отека (АНО) и злокачественных опухолей, сопровождающихся нарушениями в комплементарной системе. Показывают, что, после хирургического удаления злокачественной опухоли, уровень патологического комплементарного компонента может нормализоваться, отек может исчезнуть. В материале авторов на наличие рака щитовидной железы обратили внимание следующие моменты: ангионевротический отек, нарушение комплементарного компонента и отклонения на сцинтиграмме щитовидной железы. После операции тиреоидектомии АНО клинически прошел, нормализовался комплементарный компонент.

Сообщая о своих наблюдениях, авторы обращают внимание на то, что, на заднем плане приобретенного отека (АНО), возможны лимфопролиферативное заболевание и аутоиммунная болезнь, при раке прямой кишки может иметься и карцитома щитовидной железы.

Dr. Károly Vallent — I. Chirurgische Klinik, Medizinische Universität Semmelweis, Budapest, Üllői út 78, H-1082

Dr. János Fehér, Dr. Anikó Somogyi — III. Medizinische Klinik, Medizinische Universität Semmelweis, Budapest, Eötvös u. 12, H-1112

Dr. Ágnes Joós — I. Pathologisch-Anatomisches Institut, Medizinische Universität Semmelweis, Budapest, Üllői út 90, H-1082

Acta Chirurgica Academiae Scientiarum Hungaricae, Tomus 23 (3), pp. 173—181 (1982)

Transvesikale Prostatektomie und ihre Komplikationen

P. MAGASI, B. RUSZINKÓ und A. VÉGH

Urologische Klinik des Institutes für Ärztliche Fortbildung

(Eingegangen am 17. September 1981)

Es werden 750 transvesikale Prostatektomien und ihre Komplikationen ausgewertet. Da die Methode zur Entfernung der mehr als 30 g wiegenden Adenome verwendet wird, sind die Bestimmung der Größe des Adenoms und seines Verhältnisses zu den umgebenden Organen von Wichtigkeit. Die Verringerung der Zahl der Komplikationen sowie die verkürzte Operations- und Pflegedauer werden der modifizierten chirurgischen Methode zugeschrieben; darunter werden die den Rand des Prostatabettes zusammenziehende fortlaufende, blutstillende multifilamentsynthetische Naht, der 3-Wege-Spülkatheter dessen Ballon in die Blase eingeführt wird, die Blasenspülung im geschlossenen System, die Mobilisierung des Patienten am ersten postoperativen Tag, die Verwendung sich resorbierender, synthetischer Nähte und die Frühentfernung des Katheters verstanden. Bei der Herabsetzung der Komplikationen spielt auch die entsprechende Anästhesie eine bedeutende Rolle.

Zur chirurgischen Lösung der 30–40 g wiegenden oder schwereren Blasenhalsadenome wird auch heute noch am häufigsten die transvesikale Prostatektomie gewählt. Der Wert der nahezu 100 Jahre bekannten Operationsmethode wurde durch die von uns entwickelte, sich in der Verkürzung der Operationsdauer, der postoperativen Hospitalisationszeit bzw. der Verringerung der Komplikationen manifestierenden Modifikation erhöht [7, 8, 18].

In Anbetracht dessen, daß die transvesikale Prostatektomie an unserer Klinik nur zur Entfernung der großen Blasenhalsadenome eine Anwendung findet, trachten wir sämtliche Möglichkeiten, die sich zur Bestimmung der Größe des Adenoms und seines Verhältnisses zu den umgebenden Organen eignen, auszunützen. Der Größe des Adenoms wird bei der Auswahl der Operationsmethode auch von anderen Autoren eine Bedeutung beigemessen [15], d.h., daß

1. die Adenektomie im allgemeinen im Falle von mehr als 3 cm langen bzw. mehr als 30 g wiegenden Adenomen und
2. die TUR zur Entfernung von Adenomen kürzer als 3 cm und von weniger als 30 g Gewicht herangezogen wird.

Obwohl mittels rektaler Palpation der hintere und Seitenlappen der Prostata gut abgetastet werden können, bietet die Untersuchung betreffs

der Größe des kranialen, sich blasenwärts erstreckenden Abschnitts keine Aufklärung. Zur Eliminierung dieses Mangels wurden in Zusammenarbeit mit unserem Röntgenologischen Institut die Prostatagröße bei je 20 randomisierten Patienten mit Komputertomographie sowie mit Sonographie bestimmt und die Ergebnisse miteinander verglichen. Durch die Komputertomographie wird der beliebige Durchmesser des Querschnitts des Prostataadenoms bestimmt; das Verfahren ist der Sonographie insoweit überlegen, daß mit seiner Hilfe sowohl die Entfernung zwischen zwei beliebigen Punkten des Adenoms als auch die Länge der Strecke bestimmt werden kann, die zwischen der knöchernen Wand des kleinen Beckens und dem Adenom liegt. Kalis und Mitarb. [14] bestimmten, mit Hilfe der Gammakamera auch die Harnretention; ihre postoperativ genau durchgeführten Messungen sprachen für die Zuverläßlichkeit der Sonographie. Auch Harada und Mitarb. [10] berichteten über die Vorteile der transrektalen Ultraschalluntersuchung: benigne Hyperplasie konnte mit 91%, Karzinom mit 84%iger Genauigkeit diagnostiziert werden und es gelang ihnen auch die Prostatasteine sichtbar zu machen. So halten sie die Sonographie auch zur intraoperativen Kontrolle der TUR und der Kryokaustik als geeignet.

Die Prostatagröße kann auch mit Isotopen bestimmt werden [23]. Die markierte Substanz erscheint bei Normalpersonen, hyperplastischen und karzinomatösen Patienten sowohl in der Prostata als auch in der Leber. Bei unseren Patienten findet diese Methode keine Anwendung.

Durch die Infusionsurographie werden bereits indirekte Aufklärungen betreffs des vergrößerten Prostataadenoms geliefert, wir greifen aber zu diesem Verfahren eher zwecks Diagnostizierung von Hohlsystemanomalien. In Übereinstimmung mit den Daten mehrerer Autoren [3, 19] betrug die Prozentzahl der von uns gefundenen verschiedenen Anomalien 18,2 bis 20,1%.

Die Zystourethroskopie eignet sich zur Beurteilung der Länge der Pars prostatica und des räumlichen Aufbaus der Prostata. Wir indizieren jedoch diese Untersuchung nur dann, wenn sich der Verdacht irgendeiner sonstigen Blasenkrankheit erhebt [2, 21].

Bei den Patienten, die seit Jahren an schweren dysurischen Beschwerden bzw. Retention leiden, ist eine Zystometrie erforderlich. Die Untersuchung gibt Aufklärungen über den Zustand der Blasenmuskulatur und informiert darüber, ob postoperativ eventuell dysurische Beschwerden bzw. partielle Retention zurückbleiben [16]. Die bei 24 Patienten gefundene Detrusorinstabilität und die in 5 Fällen festgestellte Hypotonie boten eine Erklärung für die postoperativen Beschwerden.

Nachdem die Untersuchungsdaten ausgewertet wurden, findet die Operation statt.

Operationsmethode

Wir wenden die von De la Pena und Alcina [5] und Hencz [12] entwickelte und von uns modifizierte Methode an. Nach Freilegung der Blasenkuppel wird die Blase mit einem Querschnitt geöffnet, rund um das Orificium internum ein Schnitt geführt, das Adenom ausgeschält und entfernt. Die venöse Blutstillung erfolgt mit einer Blase und Prostatabett voneinander hermetisch agrenzenden fortlaufenden, sich nicht resorbierenden, synthetischen Multilamentnaht, die auf die Bauchwand ausgeführt und über dem Tampon verknotet wird [18]. Diese Fäden besitzen eine große Reißfestigkeit, sie sind biegsam und passen sich den Geweben gut an; Fadenbrüche waren in keinem der 750 operierten Fälle zu beobachten. 4–6 Stunden nach dem Eingriff wird der Faden gelockert, da eine länger als 24 Stunden dauernde Zusammenziehung zur Blasenhalsnekrose und später zur Striktur führen kann. Am ersten postoperativen Tag wird nebst Blasenspülung im geschlossenen System der Faden entfernt.

Zur Stillung der arteriellen Blutungen kamen stets synthetische, sich resorbierende Fäden bzw. Polyglykolsäure (Dexon®) oder Polyglaktin 910 (Vicryl®)-Nähte zur Anwendung, weil durch sonstige Fäden mitunter entzündliche Reaktionen, Steinbildung und fallweise Vernarbungen verursacht wurden. Diese Veränderungen vermochten wir auch in unseren an Kaninchenblasen durchgeführten Experimenten nachzuweisen. Die Blase wird mit sich resorbierenden Fäden und Tabakbeutelnaht verschlossen. Der Patient wird am ersten postoperativen Tag mobilisiert, der Katheter am 4. Tag entfernt.

Klinische Daten

Mit der dargestellten Methode wurden zwischen September 1972 und Mai 1981 750 Patienten operiert. Der jüngste Patient war 52jährig, der Älteste 84 Jahre alt. Durchschnittliches Lebensalter: 64,5 Jahre. Patienten älter als 75 Jahre repräsentierten 10% des Gesamtmaterials. Die Altersverteilung des Krankenguts veranschaulicht Abb. 1.

Die Komplikationen haben wir, dementsprechend ob sie innerhalb von 15 Tagen oder danach auftraten, in 2 Gruppen — Früh- und Spätkomplikationen — eingeteilt (Abb. 2).

Vom Standpunkt der Blutungsprophylaxe aus halten wir die Auswahl der entsprechenden Anästhesie als äußerst wichtig.

Bei unseren Eingriffen wendeten wir die Epidural- oder Spinalanästhesie an, narkotisiert wurden nur Patienten die eigens diesen Wunsch äußerten (in diesen Fällen wählten wir die Neuroleptanästhesie). Die von Thorud und Mitarb. [24] bei 213 Patienten im Laufe verschiedener Anästhesien — Neuro-

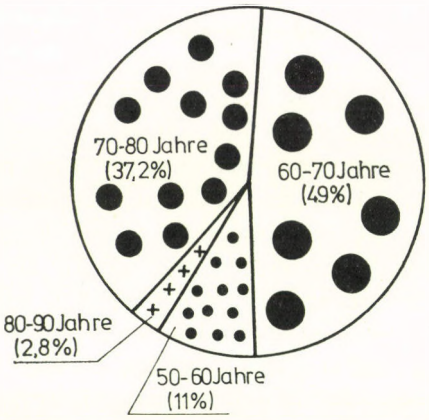

Abb. 1. Prozentuale Altersverteilung der adenomektierten Patienten

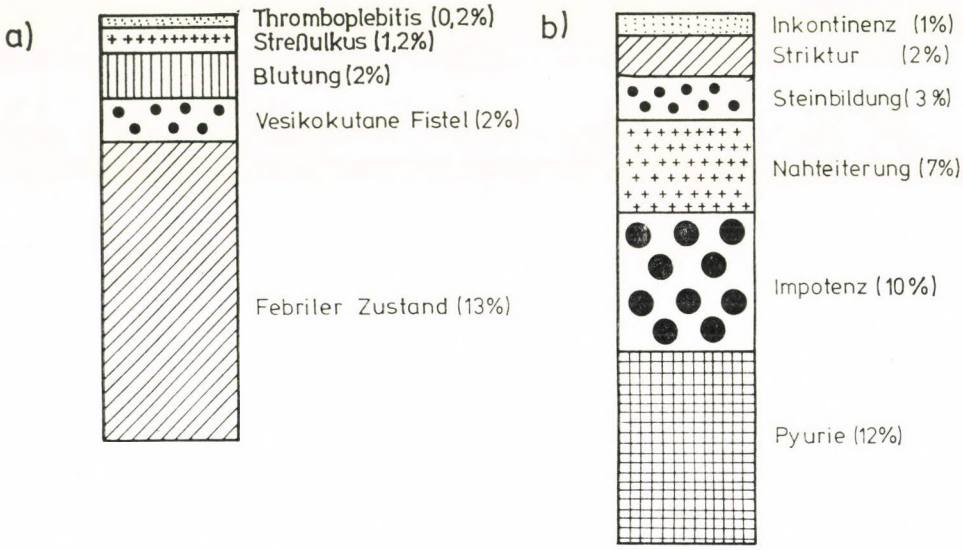

Abb. 2*a*. Innerhalb von 15 Tagen aufgetretene Frühkomplikationen; *b*. Nach dem 15. postoperativen Tag aufgetretene Spätkomplikationen

lept (Droperidol-Fentanyl)-, Halothan- und Epiduralanästhesie — vorgenommenen Blutverlustmessungen ergaben, daß der durchschnittliche intraoperative Blutverlust bei

Neuroleptanästhesie	8,2 ± 5	ml/min
Halothananästhesie	6,6 ± 6,3	ml/min und
Epiduralanästhesie	3,8 ± 3	ml/min betrug.

Der zwischen der allgemeinen und epiduralen Anästhesie bestehende Unterschied ist stark signifikant.

Beschprechung

Unter den Komplikationen nahmen wir vor allem jene Fälle unter die Lupe, in denen sich ein intraoperativer Blutersatz erforderlich war. Die Bestimmung des Blutverlustes erfolgte mit der direkten Methode. In der Altersgruppe zwischen 50–60 Jahren, in der Begleitkrankheiten zu 15% vorkamen (Hypertonie, chronische Pyelonephritis, Zuckerkrankheit usw.), waren 8% der Patienten auf einen Blutersatz angewiesen. In der Altersgruppe der 60–70jährigen betrug die Prozentzahl der auf einen Blutersatz angewiesenen Patienten, die zu 20,2% an Begleitkrankheiten litten, 10% (maximal 1200 ml, minimal 400 ml), während in der 70–80jährigen Altersgruppe 6% der Patienten einen Blutersatz erhielten, obwohl die Prozentzahl der Begleitkrankheiten 42% ausmachte. Schwere postoperative, eine Freilegung erfordernde Blutung trat in 1% der 750 transvesikalen Prostatektomiefällen auf, Blutungen mit intermittierender Intensität meldeten sich in 2% der Fälle [20] (Abb. 3).

Was die übrigen Komplikationen anbelangt, waren in 13% der Fälle postoperative fiebrige Zustände, in 2% Epididymitis acuta [1], in 9% akute Aufflackerung einer chronischen Pyelonephritis, in 2% Fadenfistel und in 5% der Fälle Pneumonie zu beobachten. Durch die für die akute Pyelonephritis vornehmlich verantwortlich vorübergehende Katheter-Leitungsstörung kann eine aszendierende, kanalikuläre Infektion herbeigeführt werden. Zur Vorbeugung dieser Komplikation wenden wir die Blasenspülung mit Gentamycin

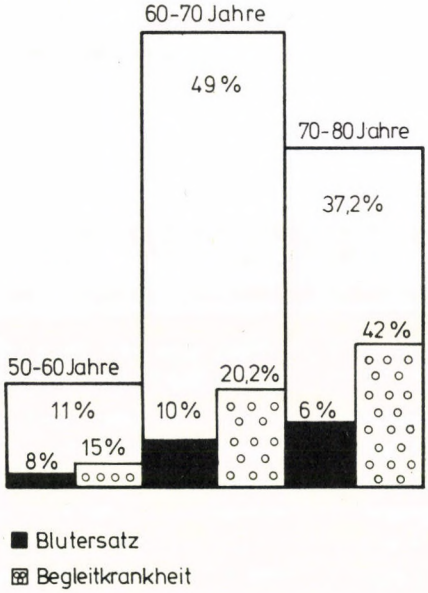

ABB. 3. Prozentuale Verteilung der intraoperativ auf einen Blutersatz angewiesenen Patienten und der Begleitkrankheiten

im geschlossenen System mit gutem Erfolg an. Die akute Exazerbation der chronischen Pyelonephritis kann sich auch einer hämatogenen Infektion zufolge entwickeln.

Zur Vorbeugung der in 2% der Fälle vorgekommenen vesikutanen Fistel dient die von Hryntschak [13] empfohlene blasenverschließende Tabakbeutelnaht, nötigenfalls mit einer »Z«-Naht verstärkt. Die Dichte des Blasenverschlusses wird mit 1000 ml Spülflüssigkeit kontrolliert. Für die sich in der postoperativen Phase entwickelte Fistel ist unseres Erachtens ein Pflegefehler bzw. die nicht entsprechende Kooperation des Patienten verantwortlich.

Den Umstand, daß sich keine tödliche Embolie meldete, haben wir der frühen, schon am ersten Tag stattfindenden Mobilisation der Patienten zu verdanken [6].

Crawford und Mitarb. [4] behaupteten, daß allein anhand der klinischen Symptome die postoperativen thrombotischen Komplikationen nicht immer diagnostiziert werden können; im Material der erwähnten Autoren betrug die Prozentzahl der mit Niederdrucktransducer non invasiv beobachteten postoperativen Komplikationen 4,6%.

Streßulkus kam in der postoperativen Frühphase in 1,2% der Fälle vor; die dadurch herbeigeführte Mortalität belief sich im Vergleich zum Gesamtmaterial auf 0,6%.

Unter den Spätkomplikationen stand die anhaltende, in 12% der Fälle selbst nach zwei Monaten bestehende Pyurie an erster Stelle. Als geeignete präventive Maßnahmen haben sich die aseptische Blasenspülung im geschlossenen System und die Frühentfernung (am 4. postoperativen Tag) des Katheters erwiesen. Die gezielte antibiotische bzw. Desinfektions-Behandlung wird bis zum Aufhören der Pyurie fortgesetzt.

Zur Vorbeugung der in 7% unseres Materials vorgekommenen Fadenfistel empfehlen wir die Verwendung von multifilen Polyester- oder Polyamidfäden zu den Muskel- und Faszianähten bzw. monofile synthetische Fäden zur Hautnäht.

Die Prozentzahl der Strikturen belief sich auf 2% (Karscher [15] berichtete über eine 3,24%-ige Häufigkeit), die der Steinbildungen auf 3%. Wegen der letzterwähnten Komplikation halten wir es für wichtig, daß zur Stillung arterieller Blutungen in der Blase ausschließlich sich resorbierende, synthetische, d.h. Polyglykolsäure- (Dexon®) oder Polyglaktin 910 (Vicryl®)-Fäden verwendet werden, zumal auf den Katgut- und den sich nicht resorbierenden, synthetischen monofilen und multifilen Fäden am Rand des Prostatabettes sowie in der Kuppel, auf der Tabakbeutelnaht wiederholt Sekundärsteine zu beobachten waren; diese Steine können zu 80% transurethral entfernt werden.

Die unangenehmste postprostatektomische Komplikation ist die Inkontinenz. Die sich nach der provisorischen Inkontinenz mitunter entwickelnde

schwere Inkontinenz klingt im allgemeinen zwischen der 2. und 4. postoperativen Woche ab. In unserem Material betrug die Häufigkeit dieser Komplikation 1% [9].

Über Impotenz berichteten nach einem halben Jahr 10% unserer Patienten; diese Angabe steht im Einklang mit den Erfahrungen von Hargreave und Stephenson [11]. Laut Madorsky und Mitarb. [17] sind für die postoperativen Potenzstörungen in erster Linie subjektive Faktoren verantwortlich.

Die Erhöhung des praktischen Wertes einer chirurgischen Lösung kommt in der Verringerung der Komplikationszahl sowie in der Verkürzung der Operationsdauer und der postoperativen Hospitalisationszeit zum Ausdruck. Nicoll und Mitarb. [20] benötigten zur Operation in der Periode vor der entfernbaren Fäden im Durchschnitt 69 Minuten und in der Fadenperiode nur 57,1 Minuten. Wir beenden die chirurgische Manipulation gegenwärtig durchschnittlich in 30–35 Minuten.

Die postoperative Hospitalisationszeit gilt vielleicht für den objektivsten Maßstab der Operationstechnik. In der Verkürzung dieser Periode widerspiegelt sich deutlich wieviel das Einüber und die partielle Vervollkommung des gegebenen Operationstypes bedeuten; unsere Daten zeigen daß zwischen 1972 und 1975 die durchschnittliche Pflegezeit 15,8 Tage, zwischen 1975 und 1978 14,1 Tage und zwischen 1978 und 1981 11,8 Tage ausmachte (Abb. 4).

Dank der gründlichen Durchuntersuchung und Vorbereitung der vor einer Prostatektomie stehenden Patienten, der Auswahl der geeigneten Anästhesie und der Verbesserung der Operationstechnik haben sich in unserem Material die Zahl der Komplikationen verringert und die Operations- bzw. Pflegedauer verkürzt. Unseres Erachtens spielt in dieser vorteilhaften Ge-

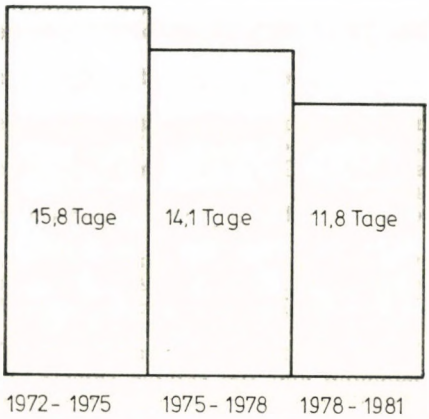

ABB. 4. Verringerung der Zahl der postoperativen Hospitalisationstage zwischen 1972 und 1981

staltung der Ergebnisse die komplexe Anwendung von drei Faktoren die entscheidende Rolle:

1. Aseptische Durchuntersuchung, mit besonderer Rücksicht auf die Bestimmung der Adenomgröße;
2. spinale bzw. epidurale Anästhesie,
3. operationstechnische Maßnahmen:

a) den Rand des Prostatabettes zusammenziehende, multifile, synthetische, fortlaufende Naht;

b) Blasenspülung im geschlossenen System durch einen 3-Wege-Katheter, dessen Ballon sich in der Blase befindet;

c) Mobilisierung des Patienten am ersten postoperativen Tag;

d) sich resorbierende, synthetische Fäden;

e) Frühentfernung des Katheters (am 4. postoperativen Tag).

Literatur

1. Anger G, Bednarek K: Practical value of resection of the vas deferens for prevention of epididymitis in cases of bladder neck adenoma. Z Urol Nephrol 69: 395, 1976
2. Balogh F: A prostata adenoma diagnosztikája és a műtéti indikáció. Prostata hyperplasia (Diagnostik und Operationsindikation des Prostataadenoms. Prostata hyperplasie). V. Kongreß der Ungarischen Urologengesellschaft, Debrecen 1979
3. Boerema WJ: Intravenous pyelography before prostatectomy. Aust NZ J Surg 42: 35, 1972
4. Crawford ED, Dumbadze I, Ratledge HW: Deep venous thrombosis following transurethral resection of the prostate: Diagnosis by phleborheography. J Ur 120:438, 1979
5. De la Pena A, Alcina E: Suprapubic prostatectomy, a new technique to prevent bleeding. J Ur 88:86, 1962
6. Denis P: La prostatectomie sous depression. J Urol Nephrol 76: 663, 1970
7. Freyer PJ: Total exstirpation of the prostate for radical cure of enlargement of that organ. Br Med J 1: 249, 1902
8. Fuller E: Six successful and successive cases of prostatectomy. J Cutan Genitourin Dis 13: 229, 1895
9. Gonzales PC, Ballesteros JJ, Figuls J, Benitez C: Transvesikale Adenektomie mit präliminärer Blutstillung. Urologe [A] 15:113, 1976
10. Harada K, Igari D, Tanahasi Y: Gray scale transrectal ultrasonography of the prostate. J Clin Ultrasound 7: 45, 1979
11. Hargreave TB, Stephenson TP: Potency and prostatectomy. Br J Urol 49: 683, 1977
12. Hencz L: Über eine neue Methode der Blutstillung bei transvesikaler Prostatektomie mit primärem Blasenverschluß. Acta Chir Acad Sci Hung 3:161, 1962
13. Hryntoschak T: Die suprapubische Prostatektomie. W. Maudrich Verlag, Wien 1951
14. Kalis E, Likourinas M, Dermentzoglou F: Measurement of the volume of residual urine using 131 J-λippuran and the gamma camera. Br J Urol 47: 567, 1975
15. Karcher P: Das Prostataadenom — Indikation, Behandlung und Ergebnisse. Med Welt 24:435, 1973
16. Lipsky H, Ralph G, Petschnigg R: Über die Ursachen der Dysurie nach Prostatektomie. Urologe [A] 19:32, 1980

17. Madorsky ML, Ashamalla MG, Schussler I: Post prostatectomy impotence. J Ur 115:401, 1976
18. Magasi P, Végh A: A hólyagnyakadenoma sebészeti megoldásának fejlődése (Entwicklung der chirurgischen Lösung des Blasenhalsadenoms). Urol Nephrol Szle 2:137, 1975
19. Marshall V, Singh M, Blandy JP: Is urography necessary for patients with acute retention of urine before prostatectomy? Br J Urol 47:73, 1975
20. Nicoll GA, Riffle GN, Andersen FO: Suprapubic prostatectomy. The removable purse string: a continuing comparative analysis of 300 consecutive cases. J Ur 120:702, 1979
21. Sallai Zs, Szomor L, Major L: A hólyagnyak adenoma aszeptikus kivizsgálásáról (Über die aseptische Untersuchung des Blasenhalsadenoms). V. Kongreß der Ungarischen Urologengesellschaft, Debrecen 1979
22. Szabó V, Sobel M, Légrádi J, Balogh F: Hólyagdaganatok ultrahang diagnosztikája (Ultraschalldiagnostik der Blasentumoren.) Urol Nephrol Szle 3:160, 1976
23. Szendrői Z, Kocsár L, Karika F: Isotope scanning of the prostate. Lancet i:1252, 1973
24. Thorud T, Lund J, Holme J: The effect of anaesthesia on intraoperative and postoperative bleeding during abdominal prostatectomies: a comparison of neurolept anesthesia, halothane anaesthesia and epidural anesthesia. Acta Anaesth Scand 19:83, 1975

Transvesical Prostatectomy and Its Complications

P. Magasi, B. Ruszinkó and A. Végh

Seven hundred and fifty transvesical prostatectomies are evaluated from the aspect of complications. The method is used for the removal of adenomas of more than 30 g weight. Consequently, it is considered important to exactly determine the size of the adenoma and its relation to the neighbouring organs. The decrease in the number of complications, as well as the shorter time of operation and of postoperative care are attributed to the surgical method modified by the authors which involves the use of synthetic multifilament continuous suture pulling together the edges of the base of the prostate, a three-bore catheter placed with its balloon into the bladder, washing of the bladder in a closed system, mobilization of the patient on the first postoperative day, application of easily absorbed synthetic threads and early removal of the catheter. In order to lower the number of complications, the importance of the properly chosen anaesthesia is stressed.

Трансвезикальная простатэктомия в зеркале осложнений

П. МАГАШИ, Б. РУСИНКО и А. ВЕГ

Авторы оценивают 750 операций трансвезикальной простатэктомии с точки зрения осложнений. Настоящий оперативный метод они применяют при удалении аденом, если их вес превышает 30 г, поэтому они считают важным точное определение размеров аденомы и отношения ее к окружающим органам. Уменьшение числа осложнений, укорочение времени операций и послеоперационного ухода авторы приписывают усовершенствованному ими оперативному методу: мультифильному, синтетическому, кровоостанавливающему шву, стягивающему края ложа простаты, далее помещенному с баллоном в мочевой пузырь катетеру с тремя отверстиями, промыванию пузыря с помощью закрытой системы, мобилизации больного в первый день, применению рассасывающегося синтетического шовного материала и раннему удалению катетера. Подчеркивают значение для уменьшения числа осложнений соответственно выбранного анализа.

Dr. Péter Magasi
Dr. Barnabás Ruszinkó
Dr. Attila Végh
Urologische Klinik des Institutes für Ärztliche Fortbildung, Budapest, Szabolcs u. 33–35, H-1135

Acta Chirurgica Academiae Scientiarum Hungaricae, Tomus 23 (3), pp. 183—191 (1982)

Early Recognition of Cutaneous Malignant Melanomas

L. Lukács and S. Péter

First Department of Surgery, University Medical School, Pécs

(Received January 8, 1982)

On the basis of studies performed during the past two decades primary malignant melanoma can now be recognized in over 90% of the cases. The clinician, the nurse and even the patient can be taught to recognize the lesions early while histology is able to reveal the important prognostic factors, such as growth phase, depth of invasion and tumour thickness. This allows to identify the patients at high risk of developing occult metastases in regional lymph nodes. Early diagnosis and surgical treatment of melanoma are now the only acceptable approach and therefore all physicians must be on the alert for the condition.

The morbidity of malignant melanoma of the skin has been increasing rapidly in the past decades so that now melanoma has a higher occurrence than Hodgkin's disease [27]. While comprising only 3% of all primary cutaneous malignancies, it is responsible for two-thirds of the deaths attributed to skin cancer [9, 18]. In over 90% of the melanomas the prognosis and clinical course can, however, be predicted on the basis of the primary lesion [15, 19, 22, 26]. Several widely accepted concepts concerning the development, recognition and management of malignant melanoma have been published over the past two decades. These studies correlated the gross pathology with the microscopic findings and the most important aspects of therapy and prognosis were shown to be related to the depth of tumour invasion into the dermis and the subcutaneous tissue [4, 6, 10].

This paper will deal with the importance of early recognition of malignant melanoma, in order to provide the clinician with a short guideline concerning early management of the tumour.

Guidelines for Early Diagnosis

The clinical signs which raise suspicion and call attention to the development of a malignant melanoma are, in order of importance:

1. They differ in colour. The colours that suggest malignancy in a brownish or black lesion are shades of red, white and blue [24]. The shades of blue are the most ominous because they are due to the Tyndall effect of light scattering

from brown melanin pigment deep withing the dermis. Pinks and reds reflect an inflammatory process, while white, pink and grey shades may indicate a spontaneous partial regression [23, 32]. Unexpected changes in colour and size of a pigmented lesion will mostly be noted by the patient.

2. There may be reticulated pigment in one area of the tumour, while in another the pigment appears to be dense and clumped and in a third area it may even be absent (Fig. 1).

3. The border of malignant melanoma may be irregular and display an angular indentation or notch especially in the superficially spreading type, in the lentigo maligna melanoma type and in the acral-lentiginous type.

4. Irregular topography may be palpable or visible especially in oblique light. The occurrence of irregular elevations on the surface is, however, infrequent. More common and frequent is the growth of a secondary nodule within a pre-existing pigmented lesion which means, as a rule, the onset of a more invasive growth phase. Papillomatous array and haired surface, further a skin-like soft consistence of the tumour are all signs which speak in favour of a benign lesion [32].

FIG. 1. SSM: apparent irregular centrifugal spread associated with regression; angular indentation or notch; the surface of the lesion is irregular with numerous nodules that vary in colour from melanotic to black and brown

5. Oozing, bleeding and itching are symptoms which finally alarm the patient to consult a dermatologist or a surgeon. Unfortunately, these signs are related to an unfavourable prognosis and indicate the vertical growth phase of the melanoma [20, 21, 25, 28, 29, 30] (Table I).

TABLE I

Important clinical features of malignant melanoma

	Patients of Eldh et al. [14] n = 324 per cent (No.)	Own patients n = 103 per cent (No.)
Changes in size and colour	65 (211)	73 (75)
Disarray of pigmentation	42 (187)	51 (53)
Irregular border (indentation)		40 (41)
Irregular topography	30 (97)	31 (32)
Oozing, bleeding		16 (16)
Itching	31 (100)	42 (43)

Based on the above criteria, a malignant melanoma can be diagnosed, in 64% of the cases [19]. False-positive diagnoses based on the same feature, occurring sometimes with other pigmented lesions such as pigmented basalioma seborrhoeic keratoses, compound nevi, blue neve, some vascular lesions, etc. are much less dangerous than overseeing a melanoma [21].

Clinicopathologic Classification of Primary Melanoma

There are four clinically and pathologically unique forms in which cutaneous malignant melanoma is known to occur and each of them has a distinctive history [10].

Superficial spreading melanoma (SSM)

There is an initial radial growth phase with melanocytic proliferation confined to the epidermis and the papillary dermis. This precursor phase lasts for several months or years and is followed by the appearance of a secondary nodule, showing the onset of vertical invasion.

Nodular melanoma (NM)

There is no intraepidermal radial component, the lesion grows rapidly and presents as a rather uniformly blue-black or dark brown papule or nodule. The sheets of malignant cells of an erratic morphology extend into the dermis.

FIG. 2*a*. LMM situated in the left frontal region. Macular radial growth phase with highly irregular border and pigment pattern. A prominent nodule represents the vertical growth phase.

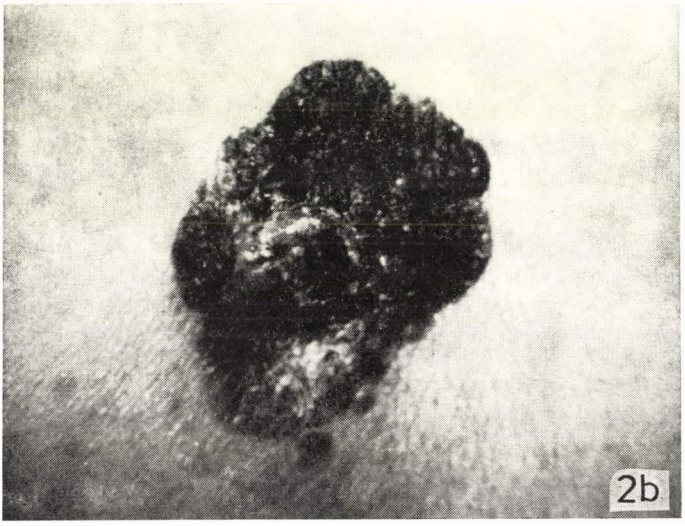

FIG. 2*b*. SSM in the interscapular region. Irregular border and surface, variegated colour. Serpiginous spread and a central nodules indicate the vertical growth phase.

Lentigo maligna melanoma (LMM)

The prolonged radial growth phase exhibits proliferation of variably atypical melanocytes which are confined to the dermal-epidermal interface region. The nodules are usually single and appear when the lesion has assumed a size of 5 to 7 cm. LMM nodules comprise cell sheets of uniformly atypical, often spindle-shaped cells with a granular cytoplasm. The overlying epidermis is usually severely atrophic (Fig. 2).

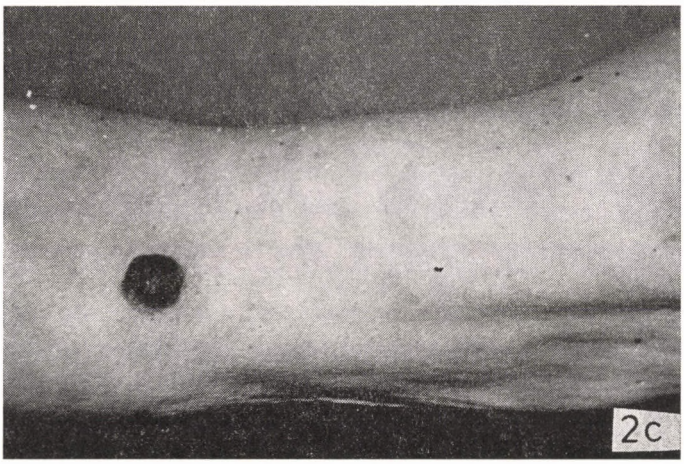

FIG. *2c*. NM on the volar aspect of the right arm. A uniformly blue-black lesion of polypoid form, often mistaken for a blood blister or a haemangioma

Acral-lentiginous melanoma (ALM)

This occurs on the palms, soles, nail beds and mucous membranes. While its history in some respects resembles that of LMM, the nature of the condition appears to be more virulent and, like SSM, it is associated with a striking propensity for metastatic spread.

The benefits of early recognition and treatment of melanomas during their radial growth phase are reflected in higher cure rates and prolonged survival [9, 16, 30].

Refinement of Histologic Investigation and Its Implications for the Treatment

The prognosis of each tumour type is related to the depth of invasion [10] and tumour thickness [5, 6]. Clark et all. have staged melanomatic lesions according to their level of invasion [10] (Table II).

TABLE II

Clark's classification and prognosis of SSM in clinical stage I

Level of invasion	5-year-survival rate per cent
1. Intraepidermal	100
2. Tumour that extends to the papillary dermis	95
3. Interface region between levels 2 and 4	73
4. Infiltration of reticular dermis	60
5. Invasion into subcutis	40

Breslow [5, 6] has shown that tumour thickness gives the best prognostic estimate: lesions less than 0.75 mm in thickness have a good prognosis, while those thicker than 2.25 mm have a substantially poorer one. The thickness is measured by means of an ocular micrometer, from the granular layer (or downward from the ulcer base, if exulcerated) to the deepest tumour cell in the thickest section [2, 3, 4, 5]. Donellan et al. [12] were the first to show that there was a striking correlation between the depth of dermal invasion according to Clark's microstaging and the incidence of eventual lymph node metastases: 6% for level 2; 29% for level 3; 32% for level 4 and 63% for level 5. Breslow [5] observed that prophylactic dissection doubled the 5-year disease-free survival rate for patients with melanomas thicker than 1.5 mm, but not for those with thinner lesions (64% vs 31%, $p < 0.03$) (Table III).

TABLE III

Cumulative 5-year-survival rate vs level of invasion and incidence of nodal disease related to number of elective dissections + level of invasion (103 cases, 1966–1979)

Clark's level of invasion No. of cases	5-year-survival rate per cent	No. of elective dissections vs nodal metastases (per cent)
Level 2 (42 cases)	88.5	—
Level 3 (28 cases)	72	12/18 (66)
Level 4 (23 cases)	59	15/19 (79)
Level 5 (10 cases)	51	4/ 5 (80)

In our institute, biopsy is done in the case of suspicious lesions, and radical excision if the clinical signs confirm the diagnosis of melanoma. For the pathologist, there should at least be sections through the so-called radial growth phase (surrounding collar) and if it exists through the vertical growth phase in order to classify the lesion according to the type and level of invasion and/or tumour thickness. Frozen sections taken intraoperatively are insufficient for a differentiation between malignant melanoma and a benign pigmented lesion [11]. Intraoperative cryostatic sections, if feasible, give the best information to determine future operative measures [2].

Guidelines for Biopsy and Surgery

A. *Biopsy:* total excisional biopsy with narrow margins if only possible

B. *Radical excision + dissection of regional lymph nodes LMM* (all levels)

1. Radical excision with a 1–3 cm margin beyond the lesion down to the fascia or the underlying muscle where there is no fascia.

2. No elective lymph node dissection unless nodes are palpable.

SSM

1. Excise or re-excise the lesion with at least a safety margin of 3–5 cm, down to the fascia. Grafting as needed.
2. No elective lymph node dissection unless nodes are palpable.
3. For levels 3–5 and thickness more than 0.75 mm, elective node dissection is optional.

NM

1. Excise or re-excise with a 4–5 cm margin from the edge of the lesion. Graft as needed.
2. Prophylactic node dissection optional.

Drzewiecki et al. [13] have observed that neither biopsy nor non-radical operation influence the prognosis if followed by radical excision within about 4 weeks [8, 13]. Still, a policy of waiting and watching suspicious nodules has little place in the management of pigmented lesions in which the timing excision can be life-saving and in which surgery is still the only effective modality of a cure [31].

Discussion

In the 1940s and 1950s there was a prevalent conviction on the unclear origin of the cell line in melanomas. Melanomas were said to be unpredictable in their course and were believed to arise from premalignant junction nevi [1]. There was, however, always the problem whether the lesion should be removed or a biopsy be done. The clinician was told to watch for growth, bleeding and ulceration of nevi. While the colour and an increase in size are useful signs in early diagnosis, since they are found in the preponderant majority of early lesions [16, 21, 30], bleeding and ulceration are late signs and serve little purpose in early recognition [16, 30]. The final histologic diagnosis can only be made if detailed clinical data on the biologic behaviour of the tumour are put at the pathologist's disposal [32]. A lack of the necessary data will result in an uncertain determination of the clinicopathologic type in about 14% of cases. Several histologic factors of the primary lesion such as the depth of invasion, the degree of lymphocytic infiltration [17] the mitotic rate [7, 26], vascular and lymphatic invasion, etc., are important for modifying the prognostic index of melanoma. Braun–Falco [2] emphasized that intraoperative cryostatic sections have ensured an accuracy of diagnosis in 85% of his patients. This diagnostic means should, however, be reserved for the cases where clinical diagnosis is impossible and immediate diagnosis of the lesion is necessary to determine further treatment. In other instances one can rely on paraffin sections which are of the highest diagnostic value and offer the best informa-

tion on tumour growth, type and invasion. As to the timing of radical excision or re-excision and lymph node dissection, those if needed must be performed within 3 weeks after the biopsy [8, 13].

References

1. Allen AC, Spitz S: Malignant melanoma — a clinicopathologic analysis of the criteria for diagnosis and prognosis. Cancer 6:1, 1953
2. Braun-Falco O: Intraoperative Kryostatschnittdiagnostik bei Verdacht auf malignes Melanom. Münch Med Wochenschr 122:193, 1980
3. Braun-Falco O: Maligne Melanome der Haut. Einschätzung der Prognose, Vorgehen bei Verdacht. Münch Med Wochenschr 122:191, 1980
4. Balch CM, Murad TM, Soong SJ, Ingalls AL, Halpern NB, Maddox WA: A multifactorial analysis of melanoma: I. Prognostic, histopathological features comparing Clark's and Breslow's staging method. Ann Surg 188: 732, 1978
5. Breslow A: Prognostic factors in the treatment of cutaneous melanoma. J Cutan Pathol 6:208, 1979
6. Breslow A: Thickness, cross-sectional area and depth of invasion in the prognosis of cutaneous melanoma. Ann Surg 182:902, 1970
7. Cady B,Lagg MA, Redfern AB: Contemporary treatment of malignant melanoma. Am J Surg 129:472, 1975
8. Cascinelli N, Balzarini CP, Fontana V, Morabito A, Orefice S: Long-term results of surgical treatment of melanoma of the limbs. Tumor 62:233, 1976
9. Chanda JJ: Primary cutaneous malignant melanoma. Primary Care 5:325, 1978
10. Clark WH, From L, Bernardino E, Mihm MC: The histogenesis and biologic behaviour of primary human malignant melanomas of the skin. Cancer Res 29: 705, 1969
11. Das Gupta TK: In: Surgery Annual 1970, eds Cooper P, Nyhus LM, Appleton-Century-Crofts. New York 1970, pp. 183–206
12. Donellan MJ, Seemayer T, Huvos AG, Miké V, Strong EV: Clinicopathologic study of cutaneous melanoma of the head and neck. Am J Surg 124: 450, 1972
13. Drzewiecki KT, Ladefoged C, Christensen HE: Biopsy and prognosis for cutaneous malignant melanoma in clinical stage I. Scand J Plast Reconstr Surg 14:141, 1980
14. Eldh W, Boeryd B, Peterson LE: Prognostic factors in cutaneous malignant melanoma in stage I. Scand J Plast Reconstr Surg 12:243, 1978
15. Everall JD, Dowd PM: Diagnosis, prognosis and treatment of melanoma. Lancet ii: 286, 1977
16. Gábor Zs, Sugár J, Gulbert A, Venkei T: Melanoma malignum pathologiai sajátságainak és prognózisának összefüggése (Relationship between the pathological characteristics and prognosis of malignant melanoma). Magy Onkol 18:72, 1974
17. Hansen MG, McCarten AB: Tumour thickness and lymphocytic infiltration in melanoma. Am J Surg 128:557, 1974
18. Kopf AW, Bart RS, Rodriguez-Sains RS: Malignant melanoma. A review. J Dermatol Surg Oncol 3:41, 1977
19. Kopf AW: The prognostic index in malignant melanoma. J Amer Med Assoc 239: 2695, 1978
20. Lukács L: Malignant melanoma at unusual sites. Acta Chir Acad Sci Hung 21: 319, 1980
21. Lukács L, Bárdosi L, Péter S: A melanoma malignum diagnosztikája és kezelése (Diagnostics and treatment of malignant melanoma). Orv Hetil 122: 2081, 1981
22. Les Ysu-Tsu N: Diagnosis, treatment and prognosis of early melanoma. Ann Surg 191: 87, 1980
23. McLean DI, Law RA, Sober AJ, Mihm MC jr, Fitzpatrick CB: On the prognostic importance of white depressed areas in the primary lesions of superficial spreading melanoma. Cancer 43:157, 1979
24. Mihm MC jr, Fitzpatrick CB, Lans-Brown NM, Raker JW, Malt RA, Kaiser JS: Early detection of primary cutaneous malignant melanoma. A color atlas. N Engl J Med 289:989, 1973

25. Rodé I: Clinical and Radiobiological Properties of Melanoblastoma. Akadémiai Kiadó, Budapest 1962
26. Schmosckel Ch, Kaviani Nejad K, Braun-Falco O: Der prognostische Index beim malignen Melanom. Pathologe 1: 71, 1980
27. Silverberg F: Cancer statistics 1979. Cancer 29: 6, 1979
28. Venkei T, Sugár J: A bőr rosszindulatú daganatai (Malignant tumours of the skin). In: Klinikai Onkologia (Clinical Oncology), ed Eckhardt S, Medicina, Budapest 1977, pp. 363–366
29. Venkei T, Sugár J, Gulbert A, Bihari Ö, Tapolcsányi L, Gábor Zs, Hindy I, Szegő P, Eckhardt S: A melanoma malignum klinikai sajátságainak és prognózisának összefüggése (Relationship betwen the clinical characteristics and prognosis of malignant melanoma). Magy Onkol 18:65, 1974
30. Venkei T, Sugár J: Early Diagnosis, Pathohistology and Treatment of Tumours of the Skin. Akadémiai Kiadó, Budapest 1965
31. Veronesi U, Cascinelli N: Surgical treatment of malignant melanoma of the skin. World J Surg 3:279, 1979
32. Weidner F: Maligne Melanome der Haut. Früherkennung und Differentialdiagnose. Fortschr Med 35:1815, 1980

Frühdiagnose der malignen Hautmelanome

L. Lukács und S. Péter

Die Forschungsergebnisse und klinische Beobachtungen der vergangenen beiden Jahrzehnte haben die sich auf die klinischen und pathologischen Beziehungen des Melanoms beziehenden Anschauungen wesentlich geändert. Als eine der wichtigsten Feststellungen ergab sich, daß das primäre, maligne Melanom heute bereits in mehr als 90% der klinischen Fälle diagnostiziert werden kann. Die Erkennung der Frühzeichen können der Kliniker, die Pflegeschwester und sogar auch der Patient leicht erlernen, die weiter verfeinerte histologische Technik eignet sich indessen zum Nachweis der wichtigsten prognostischen Faktoren, wie z.B. Wachstumphase, Invasionstiefe, Dicke des Tumors, außerdem können mit Hilfe dieser Untersuchungen okkulte Metastasen rechtzeitig erkannt werden. Da in der Primärversorgung des Melanoms zur Zeit allein von der auf der Frühdiagnose beruhenden chirurgischen Behandlung eine Hilfe zu erwarten ist, muß die je frühere Erkennung des malignen Gebildes im Vordergrund unserer Bestrebungen stehen.

Ранняя диагностика злокачественных меланом кожи

Л. ЛУКАЧ и Ш. ПЕТЕР

Результаты исследований, выполненных в два последних десятилетия, резко изменили наши представления о клинике и патологии меланомы. Одно из самых важных из них связано с ранней диагностикой меланомы: в настоящее время больше, чем в 90% клинических случаев удается диагностировать первичную злокачественную меланому. Как клинического врача, так и медсестру и даже больного можно научить распознавать ранние изменения, усовершенствованная же гистологическая техника, в свою очередь, способна показать главные прогностические факторы, как, например, фазу опухолевого роста, глубину проникновения и толщину опухоли. Больные, у кого с большой долей вероятности должны быть скрытые метастазы, могут быть во время распознаны. Авторы последовательно подчеркивают, что, в настоящее время, ранний диагноз и хирургическое лечение представляют единственный способ воздействия на первичную меланому, и именно поэтому каждый врач должен стараться диагностировать меланому как можно раньше.

Dr. László Lukács
Dr. Sándor Péter

First Department of Surgery,
University Medical School, Pécs,
Ifjúság útja 131, H-7621

Acta Chirurgica Academiae Scientiarum Hungaricae, 23 Tomus (3), pp. 193—198 (1982)

Über das Nieren-Angioleiomyolipom

S. Csata, A. Verebély und A. Gorka

Urologische Abteilung des István Krankenhaus- und Ambulatoriums, Budapest

(Eingegangen am 15. Januar 1982)

In dem wegen seiner Seltenheit für veröffentlichungswert gehaltenen Fall, handelte es sich um eine, an Angioleiomyolipom leidende Patientin. Die Therapie bestand aus Nephrektomie; Sclerosis tuberosa lag nicht vor. Anschließend werden im Spiegel der Literaturdaten Ätiopathologie und Klinik des gutartigen Krankheitsbildes kurz überblickt.

Das Angioleiomyolipom ist eine selten vorkommende, gutartige Geschwulst der Niere. Die ersten sich auf das Gebilde beziehenden Daten finden sich im Zusammenhang mit der Sclerosis tuberosa in der 1880 erschienenen Mitteilung von Bourneville [2]. 1911 veröffentlichte Fischer eine sich mit dem Angioleiomyolipom befassende Mitteilung, auf die dann wesentlich später, 1951, die dasselbe Thema behandelnde Arbeit von Morgan und Mitarb. folgte.

Aus dem Schrifttum der jüngsten Jahre sind die Publikationen von Alföldi, Szabó und Mitarb. [2] sowie Brasch und Mitarb. [3] zu erwähnen.

Der Anteil der an Angioleiomyolipom leidenden Frauen ist mit 80% wesentlich höher als der der Männer. Durch den, meistens in der Nierenrindensubstanz lokalisiertern, manchmal aber auch das perineale Fettgewebe infiltrierenden Tumor, werden weder das Nierenbecken noch das Nierenparenchym durchbrochen, fallweise lassen sich aber Hohlsystemdeformationen beobachten [5, 7].

In dem aus 8401 Fällen bestehenden Sektionsmaterial (zwischen 1968 und 1957) von Steven erwiesen sich zwei Nierentumoren histologisch für Angioleiomyome und 13 Geschwulste für Leiomyome.

In unserem Fall war der Tumor von der Nierensubstanz durch eine Kapsel getrennt.

Falldarstellung

Frau F. H., die 42jährige Patientin wurde auf unserer Abteilung vom 20.10.1980. bis zum 16.11.1981. behandelt.

Wichtigere anamnestische Daten: 1975 Pneumonie, seit 1957 Hypertonie. 1980 stationäre Behandlung wegen Diabetes mellitus an einer internistischen Abteilung. Die dort vorgenommene intravenöse Röntgenuntersuchung zeigte rechts eine tumorähnliche Veränderung. Patientin nahm im Verlauf von 2 Monaten 13 kg ab, sie ist appetitlos. Am Tag uriniert sie 4–5mal, in der Nacht 4mal. Fieber, Krämpfe, Hämaturie meldeten sich nicht.

Aufnahmebefund: Mittelmäßig entwickelte, magere Patientin. Herz, Lunge: o.B. Bauch: weich, einpalpierbar, keine pathologische Resistenz. In der Fortsetzung des unteren Pols der rechten Niere eine etwa frauenfaustgroße, den Atembewegungen folgende, glatte Resistenz; keine Druckempfindlichkeit der Niere. Die linke Niere ist nicht palpierbar und nicht empfindlich. Patientin ist fieberlos. Blutdruck: 134/80 mm Hg, Pulszahl: 75/min.

Unter den Laborbefunden ist nur der pathologische Blutzuckerwert — 8,8 mmol/l (Azeton negativ) erwähnenswert.

Thoraxröntgen: Dem Lebensalter und dem Körperbau entsprechende Organe.

Intravenöse Urographie: Leeraufnahme: kein Steinschatten 10'-Aufnahme: Links intensive Ausscheidung, intaktes Hohlsystem, freier Abfluß: rechts ebenfalls intensive Ausscheidung, die untere und mittlere Kelche sind aber auseinandergeschoben, der untere Pol kann wegen des raumeinengenden Prozesses nicht beurteilt werden.

Diagnose: Ru., cysta ren. l.d.? (Abb. 1).

Nach Einstellung der Zuckerkrankheit, Operation: rechtsseitige schräge Lumbalinszision. Da vom unteren Pol ausgehend ein faustgroßer Tumor zu palpieren ist (lipomatös, sanguinolent) Hilusabklemmung und Nephrektomie. Der Hilus ist frei, Lymphknoten sind nicht zu palpieren. Über dem Drain, schichtweiser Wunderverschluß (Abb. 2).

Pathohistologischer Befund: In der Nierensubstanz Tumorgewebe mit retikulärer Struktur, das aus Glattmuskelfasern, Fettgewebe und einer Viel-

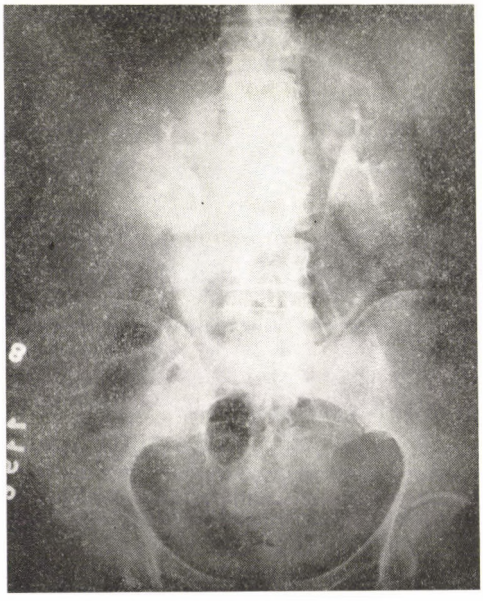

Abb. 1. Intravenöse Urographie

zahl von Gefäßen mit unterschiedlichem Kaliber besteht. Die Kerne der Glattmuskelzellen sind polymorph, hie und da treten mitotische Formen in Erscheinung. Der Tumor ist von der Nierensubstanz stellenweise durch eine Kapsel abgegrenzt. In den vakuolisierten Zellen befindet sich eine, mit Sudan III färbende, neutrale Fette enthaltende Substanz. Das aus dem beschriebenen Bündel bestehende Gebiet färbt sich mit Van-Giesen-Färbung gelb und enthält keine Kollagenfasern (Abb. 3).

Diagnose: Angioleiomylipom.

Nach ungestörter postoperativer Periode wird Patientin am 16. Tag mit per primam geheilter Wunde entlassen. 1 Jahr hindurch wurde sie noch regelmäßig kontrolliert, wonach Nierenfunktions- und sonstige Werte normal waren

Abb. 2. Makroskopisches Bild des entfernten Tumors

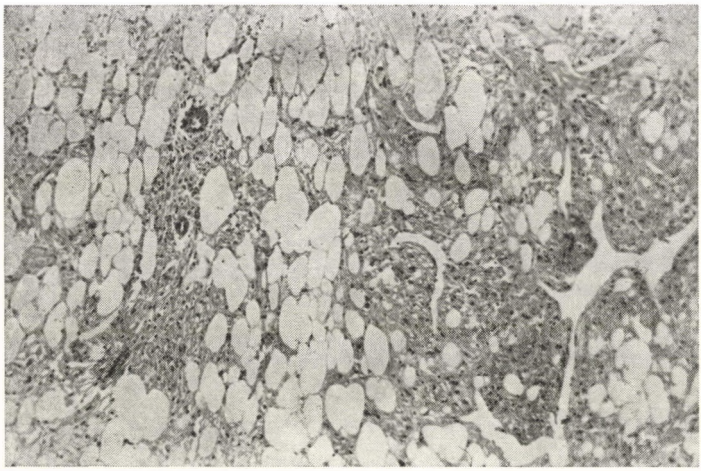

Abb. 3. Histologisches Bild des entfernten Tumors

Beschprechung

Patientin wurde wegen eines Nierenzysten-bzw. Nierentumorverdachts aufgenommen; diese letzterwähnte Verdachtsdiagnose erhob sich anhand der beträchtlichen Körpergewichtsabnahme (laut der Anamnese nahm sie im Verlauf von 2 Monaten 13 kg ab) und des Röntgenbefundes. Später stellte es sich heraus, daß im Hintergrund der Abmagerung die Zuckerkrankheit und nicht die tumoröse Veränderung stand.

Als gutartige Geschwulst bleibt das Nieren-Angioleiomyolipom — falls es die Umgebung nicht komprimiert oder keine Beschwerden verursacht — symptomfrei. Mitunter wird die Veränderung — wie das auch in unserem Fall geschah — im Laufe einer in anderer Richtung durchgeführten Untersuchung entdeckt. Die durch die großen Geschwülste hervorgerufenen Symptome — Hämaturie, palpabler Tumor, wegen der Kompression der benachbarten Organe aufgetretene Schmerzen — können den, durch maligne Tumoren verursachten Beschwerden ähnlich sein [3, 9, 13].

Wegen im Tumor entstandenen Blutungen treten mitunter Fieber, Blutverlust und Schock auf, beschleunigte Blutsenkungsgeschwindigkeit, Kachexie melden sich jedoch im allgemeinen nicht [10]. Im Material von Ross und Dickerson [11] war die prozentuelle Verteilung der Symptome wie folgt: Lendengegendschmerzen 87%, palpabler Tumor 47% und Hämaturie 40%.

In unserem Fall war der physikalisch palpable Tumor das einzige Symptom, Fieber oder Schmerzen meldeten sich nicht. Aus der Literatur ist der hereditäre Charakter der Krankheit wohlbekannt; die Krankheit wird wahrscheinlich durch ein autosomales, dominantes Gen übertragen, es kommt aber auch vor, daß eine Generation ausbleibt [3, 8, 11].

Die Nierenveränderung ist— vor allem wenn sie sich nicht zur Sclerosis tuberosa gesellt — im allgemeinen einseitig. Sie tritt meistens im 3–4. Dezennium auf und kommt bei Kindern nur selten vor.

Laut Brasch und Mitarb. [3] gesellte sich zur tuberösen Sklerose in 80% der Fälle ein Angioleiomyolipom, diese Prozesse waren bilateral und multipel. 50% der Angioleiomyolipome erschienen als Begleitkrankheiten der Sklerosis tuberosa [4]. Für die Epilepsie bzw. die Mentalretardation sind die in der Umgebung der Gehirnkammern oder der basalen Ganglien oft beobachtbaren tuberösen Knoten verantwortlich [3]. In 87% der Fälle zeigt das Elektroenkephalogramm keine pathologische Veränderung. Manchmal treten im Herz ein Rhabdomyom, in den Knochen zystische Veränderungen oder Lungenzysten in Erscheinung [3, 6, 7, 8, 9].

In unserem Fall lagen weder zerebrale Schädigungen, noch pathologisches EEG oder tuberöse Sklerose vor.

50, der in der Literatur dargestellten rund 200 Angioleiomyolipom-Kranken litten gleichzeitig auch an einer tuberösen Sklerose [3].

Zur Diagnostizierung des Angioleiomyolipoms eignen sich die üblichen urologischen Untersuchungsverfahren. Bei einseitiger Nierenveränderung stellt die Nephrektomie die Therapie der Wahl dar. Die Diagnostizierung, genauer gesagt die Differentialdiagnostizierung der beidseitigen Angioleiomyolipome gegenüber die Polyzystenniere ist ziemlich schwierig. Die Therapie besteht aus, sich auf den bioptischen Befund gestützte Resektion.

Mikroskopisch ist das Nieren-Angioleiomyolipom ein gemischter Tumor, in dem die einzelnen Bestandteile — Gefäßelemente, Glattmuskel- und Fettzellen — in unterschiedlicher Proportion vorkommen. Der vaskuläre Komponent besteht aus gewundenen, miteinander Anastomosen bildenden Gefäßen unterschiedlichen Kalibers. Die die Muskelemente bildenden Zellen sind, was ihre Größe und Form anbelangt, ebenfalls variabel, mit hyperchromen Kernen. Die reifen Fettzellen enthalten große, lipide Vakuolen und seitlich gedrängte Kerne. Die Muskelfasern, die die ganze Tumorsubstanz durchweben, stehen vermutlich im Zusammenhang mit den Gefäßwänden [1, 3, 5, 6, 7]. Die Angioleiomyolipome sind Entwicklungsanomalien zufolge entstandene Hamartome, es wäre aber verfehlt, die sog. malignen Angiomyolipome »maligne Hamartome« zu nennen, da es sich viel eher um gemischte, mesenchymale Tumoren handelt. Die Frage ob im angioleiomyolipomösen Hamartom eine maligne Entartung zustandekommen würde, gilt bisher noch als unentschieden. Die chirurgische Entfernung bzw. Exzision des Hamartoms führen zur definitiven Heilung. Insofern sich auf eine Suffusion in den Tumor, die Niere oder in das perirenale Fettgewebe weisende Symptome melden, ist selbstverständlich der unverzügliche chirurgische Eingriff indiziert [8].

Literatur

1. Balázs M, Juhász J, Brasch J: Vese angiomyolipoma elektronmikroszkópos struktúrája (Elektronmikroskopische Struktur des Nieren-Angiomyolipoms). Morphol Igazságügyi Szle 12:241, 1972
2. Bourneville DM: Contribution a l'étude de l'idiotie; Idiotie et épilepsie, hémiplégie. Arch Neurol 1: 81, 1880
3. Brasch J, Merényi J, Balázs M: A vese angiomyolipomájáról (Über das Nieren-Angiomyolipom). Magy Onkol 17:101, 1973
4. Crosett AD: Roentgenographic findings in the renal lesion of tuberous sclerosis. Am J Roentgenol 98:739, 1966
5. Endes P: Pathológia (Pathology). 3rd ed. Medicina, Budapest 1978
6. Farrow GM, Harrison EG, Utz DC, ReMine WH: Sarcomas and sarcomatoid and mixed malignant tumors of the kidney in adults. Part I. Cancer 22: 545, 1968
7. Farrow GM, Harrison EG, Utz DC, Jones DR: Renal angiomyolipoma. A clinicopathologic study of 32 cases. Cancer 22: 584, 1968
8. Klapproth BJ, Poutasse EF, Hazard JB: Renal angiomyolipomas. Report of four cases. AMA Arch Path 67:400, 1959
9. Kauffmann G, Bischoff W, Rau W: Multiple Hamartome–Vorläufer des Hypernephroms? Radiologie 19:483, 1979
10. Price EB and Mostofi FK: Symptomatic angiomyolipoma of the kidney. Cancer 18: 761, 1965
11. Ross AT, Dickerson W: Arch Neurol Psychiatr 50: 233, 1964

12. Szabó V, Verebélyi A: Veseangioleimyolipoma operált esete (Ein Operierter Fall von Nieren-Angioleiomyolipom). Magy Seb 25: 201, 1972
13. Vadon G, Engloner L: Nieren-Angiomyolipom. Fortsch Röntgenstr 131 (50): 561, 1979
14. Vasco JS, Brockmann SK, Bomar RL: Renal angiomyolipoma. A rare cause of spontaneous massive retroperitoneal haemorrhage. Ann Surg 161 (4):577, 1965

Angioleiomyolipoma of the Kidney

S. Csata, A. Verebélyi and A. Gorka

The case of a woman with angioleiomyolipoma is reported. In the light of published data a brief review is presented on the aetiology, pathology and clinical aspects of this extremely rare disease. Angioleiomyolipoma is a benign disease which can be cured by removal of the kidney. In the case at issue, there occurred no tuberous sclerosis in the patient.

Об ангиолейомиолипоме почек

Ш. ЧАТА, А. ВЕРЕБЕЙИ и А. ГОРКА

Авторы сообщают о случае ангиолейкомиолипоме почки у женщины. Делают краткий обзор этио-патологии и клиники данного заболевания в свете литературных данных. Болезнь имеет доброкачественное течение, лечение состоит в удалении больной почки, с описываемом наблюдении процесс не сопровождался sclerosis tuberosa Вследствие заболевания авторы считают, что его следовало опубликовать.

Dr. Sándor Csata
Dr. András Verebélyi
Dr. András Gorka

Urologische Abteilung,
István Krankenhaus und Ambulatorium,
Budapest, Nagyvárad tér 1, H-1096

Acta Chirurgica Academiae Scientiarum Hungaricae, Tomus 23 (3), pp. 199—203 (1982)

Book Reviews

F. LÖFFLER, P.F. MATZEN and E.W. KNÖFLER

2nd revised edition
Verlag Volk und Gesundheit, Berlin 1979. 617 pages with 558 partly coloured figures.
DM 104, $ 61

This handbook of orthopaedic surgery was first published in two volumes in 1971. This 2nd revised edition is a single volume, 100 pages shorter than the first one, but contains 20 figures more. The cutting of the text and the simultaneous increase of the number of figures was probably to the advantage of the book, as its surgical character has become more pronounced.

Revision did not alter the structure of the book. A decimal system, advantageous for those used to it, is applied as before. The basic principle of dealing with the material also remained unchanged: the operative methods — which make up almost two-thirds of the book — are described according to the authors' system. This is followed by the description of operations suitable for the treatment of diseases occurring in certain regions of the body. This system requires repeated turning of the pages and the publication of the work in one volume is, therefore, a great help to the reader.

All the latest methods have been included some of the earlier illustrations have been replaced with new ones. They have strictly observed their intention to rely on their own experience and to describe first of all those methods which they have used or are using with success. This gives a special character to the book, providing a link between the reader and the authors.

Like its first edition, the book will be a valuable help to all those who wish to study the basic principles of orthopaedics, and at the same time, it will give a picture of the experiences of the Leipzig orthopaedic shool with its rich traditions.

G. BERENTEY

W.J. WESTON and D.G. PALMER

Soft Tissues of Extremities. A Radiologic Study of Rheumatic Diseases

Springer Verlag, New York–Berlin–Heidelberg 1978. 121 pages, $ 17 DM 41

This book by the New Zealand authors makes up for a long-felt and urgent need, which can best be realized by reading this short but very up-to-date book. In spite of the many excellent books on radiology, X-ray anatomy, orthopaedics, and traumatology, there was none which summed up the radiology of the soft tissues of the extremities and even less the lesions observed in rheumatic diseases. To quote just one example: Matzen's excellent orthopaedic roentgenology does not even mention the tissues round the joints and discusses only the lesions of the bone, while some recently published diagnostics refer only to sclerotic phenomena.

The book deals in 8 chapters with the normal and pathologic lesions of all articular and soft parts in general and according to regions, stressing the symptoms observed in rheumatic diseases.

The first chapter describes in detail methods of examination used by the authors and the films suitable for taking X-ray pictures of the soft parts. Xeroradiography, though not used by the authors, is considered to become one of the most important methods of the future. Subsequently, in 10 sub-chapters, the radiological symptoms corresponding to basic clinical, pathollogical and anatomical phenomena and the significance of these symptoms are treated one by one: oedema, haemorrhage, lymph channels and lymph nodes, synovial mass, rheumatic symptoms, rheumatic nodes, sclerosis, etc. The other 8 chapters discuss the regions of the shoulder, elbow, wrist, hand, hip, knee, ankle and the foot, and of the leg. Each chapter describes the X-ray symptoms of the soft parts of the region and the methods of detection and identification of the special diseases of the bursae, lymph nodes, joints and their environment, e.g. rupture of the bicipital or quadriceps tendon, popliteal cysts, etc. A ub-chapter discusses the lesions observed in rheumatoid arthritis of every joint i.e. region, and the significance of these lesions.

The references are presented in a form which can easily be surveyed and which extends beyond the field of radiology to all related disciplines, first of all to orthopaedics and rheumatology.

The style is concise, and the editing simple. Understanding is based mainly on the large number of figures, excellent X-ray pictures in their majority.

The book can be read quickly but can also be used as a handbook because of the logical construction of the chapters and sub-chapters and the same logical line being followed all along.

Though it is basically a radiological work, the book can be recommended to orthopaedists and rheumatologists too, since it contains information which they cannot find anywhere else. In addition, the book might be useful to physicians who might occasionally have to face diagnostic problems related to rheumatism or to the soft tissues of the extremities, thus internists, particularly those engaged in rheumatism, traumatologists and surgeons.

A. Richter jr.

H. Gremmel, H.H. Löhr, K. Kaiser and H. Vieten

Handbuch der medizinischen Radiologie

Vol. 10, Part 2/c

Springer Verlag, Berlin–Heidelberg–New York 1979. 421 pages with 102 figures. DM 7 $ 35

The book is divided into two parts. The first deals with the open, the second with the obtuse injuries of the heart and of the large vessels. The two parts are arranged in the same way. After a short introduction on the incidence of injuries and on the therapeutic possibilities, the mechanism and clinical aspects of injuries are discussed in detail, followed by a brief survey of the therapeutic principles. The extremely thorough description of the pathomechanism of obtuse injuries of the heart and of the aorta, made easily understandable by several illustrations, deserves to be mentioned separately.

In the first part this is followed by a discussion of the general basic principles of X-ray diagnostics and of the special methods of examination. The problem of the localization of foreign bodies is given much thought, and attention is called to the apparent migration of foreign bodies when the tube or the screen is moved or the patient is turned over; this will help accurate localization. The importance of narrow-beam examination in the localization of foreign bodies (4 marks method) is stressed. The parameters of foreign bodies found during examination in the cavity or wall of the heart or in the pleural cavity, etc., are given and the possibilities of computer tomography, isotope and ultrasound diagnostics are discussed.

In the next part, the open injuries, first of the pericardium and then of the heart and of the large vessels, and the

damages caused by foreign bodies are discussed. The descriptions according to the type and location of the injuries go into the smallest details and include a great variety of combined injuries. The chapter on heart and vascular injuries of iatrogenic origin is of outstanding importance. Because of the increasing number of thoracic operations, new therapeutic methods (pacemakers) and the constantly spreading use of invasive examinations, this group of injuries is gaining in significance. In connection with iatrogenic foreign body (pieces of heart catheter, fragments of the leading wire, etc.) induced embolism, some useful therapeutic methods are suggested.

The first part ends with a chapter on the late consequences of open injuries and on the results of surgical treatment.

In the second part on obtuse injuries of the heart, after an introduction these types of injuries of the heart, of the aorta, of the large vessels originating from the aorta and of other large vessels are described in separate chapters.

The concept of commotio or contusio cordis is defined in detail. Clinical, radiologic and ECG changes are thoroughly discussed, offering far more than might be expected from the title of the book, including traumatic valvular defects which are rare consequences of the obtuse injuries of the heart. The obtuse injuries of the large vessels are treated with similar thoroughness.

The text is made easily understandable by 102 perfect figures and a great number of summarizing tables. The bilingual (German and English) index, the detailed list of authors, the huge list of references with more than 1500 items are all of great help to the reader.

It seems that not only the radiologist will have to study this book, but it cannot be missing from the library of the heart surgeon, of the traumatologist and of the specialist of haemodynamics either. From the aspect of the radiologist and without claim for completeness it also deals with surgical, medical and general therapeutic principles. In this way it creates a direct link between these disciplines and will fill a long-felt used in every sense of the word.

I. Vécsey

W. Hager und A. Seling

Praxis der Schrittmachertherapie

Zweite, neuerarbeitete Auflage
F.K. Schattauer Verlag, Stuttgart–New York 1978. 211 Seiten mit 106 Abbildungen und 10 Tabellen. DM 19, $ 8

Man schrieb 1952, als Zoll einem an atrioventrikulärem Block dritten Grades leidenden Patienten, bei dem zeitweise auch schwere Adams–Stokessche Anfälle auftraten, den ersten Schrittmacher einpflanzte. Im Laufe der seitdem vergangenen mehr als vierteljahrundertigen Periode hat sich die Pacemaker-Therapie in unvorstellbarer Weise entwickelt und gilt heute bereits als ein Routineverfahren der Kardiologie. Die Zahl jener Patienten, bei denen sich wegen irgendeiner akuten Leitungsstörung die Einpflanzung eines provisorischen Schrittmachers als erforderlich erweist, kann im Mangel genauer Daten nicht geschätzt werden.

Die Arbeit bietet den praktizierenden Ärzten nützliche Kenntnisse im Zusammenhang mit der Behandlung der an atrioventrikulärer Leitungsstörung leidenden bzw. einer Schrittmacher-Einpflanzung unterworfenen Patienten. Die Autoren hielten vor allem praktische Anforderungen vor Auge, indem sie sämtliche Gesichtspunkte ausführlich erläutern, die dem sich nicht mit Kardiologie befassenden Arzt bei der Festlegung der Indikationen der Pacemakertherapie, der Diagnostizierung der häufigeren oder selteneren Komplikationen bzw. bei der Betreuung der Patienten eine Hilfe leisten können; anschließend werden auch die verschiedenen Pacemaker-Typen beschrieben.

Á. Hoffmann

K.P. Kretschmer

The Intestinal Stoma

G. Thieme Verlag, Stuttgart 1978. 119 Seiten mit 61 Abbildungen und 16 Tabellen. DM 27, $ 12

Die Monographie gliedert sich in 3 Hauptteile: 1. Indikationen der intestinalen Stomata, 2. Operationsverfahren und 3. Komplikationen der verschiedenen Stomata, ihre Vorbeugungsmöglichkeiten und Therapie.

Nach einer kurzen physiologischen Einleitung finden die Indikationsgebiete der Jejunostomie bzw. der Ileostomie, auch die angeborenen Mißbildungen und die erworbenen Krankheiten (Mekonium-Ileus, Dünndarmobstruktion, Colitis ulcerosa usw.) inbegriffen, eine ausführliche Besprechung. In der Folge werden der angeführten Aufteilung entsprechend die Indikationen der Zökostomie und der Kolostomie erörtert.

Der zweite Teil befaßt sich mit den verschiedenen Operationsverfahren, namentlich mit den einzelnen Formen und Typen der Anlegung der Ileostomie nach der Jejunostomie, mit der Herstellungsweise der am Dickdarm anlegbaren entlastenden Stomata (Zökostomie, Transversostomie, Sigmoideostomie) bzw. mit dem Operationsgang ihres Verschlusses. In diesem Abschnitt beschränkt sich der Text auf die Erklärung der schematischen Zeichnungen.

Im dritten Teil werden die Komplikationen der oben besprochenen Stomata sowie ihre Vorbeugungsmöglichkeiten und therapeutischen Verfahren kurz in Punkte eingereiht erörtert.

Die letzten Seiten enthalten nützliche Kenntnisse in bezug auf die Diät der Stoma-Kranken, der Stomatherapie und der Rehabilitationsmöglichkeiten.

Das Buch darf in erster Linie den jungen Chirurgen empfohlen werden, es bietet aber auch den älteren Kollegen nützliche Kenntnisse.

M. Ihász

Neue Untersuchungen mit Gamma-Hydroxybuttersäure. Anasthesie und Intensivbehandlung

Band 110

Herausgeber: R. Frey

Springer Verlag, Berlin–Heidelberg–New York 1978. 150 Seiten mit 63 Abbildungen. DM 27, $ 11

Dieses Buch enthält das Material des am 5.5. 1977 im Schloß des Kurfürsten von Mainz veranstalteten Kolloquiums, welches sich mit den mit Natrium-4-hydroxybutyrat gewonnenen pharmakologischen und klinischen Erfahrungen befaßte; das Mittel ist auch unter dem Namen γ-OH-Buttersäure bekannt und wird unter dem Fabriknamen Somsanit® in den Handel gebracht.

Prof. Dr. Frey sagte in seinem einleitenden Referat, daß er dieses hypnotische Mittel, über das er zuerst von Frau Laborit hörte so interessant fand, daß er es mitsamt seinen Mitarbeitern in Selbstversuchen erprobte. Seiner Ansicht nach steht vor dem Präparat eine vielversprechende Zukunft, da es das nicht toxische Derivat einer im Organismus vorkommenden Verbindung ist und der Patient nach einem durch das Mittel herbeigeführten kurzen Schlaf sofort aufstehen, essen und sogar arbeiten kann. Diesen Umständen zufolge dürfte dem Präparat eine große Bedeutung zukommen.

Im Laufe der Vormittagssektion haben die holländischen Forscher van der Kleijn, Vree, van den Bogert und van Dalen über ihre pharmakokinetische Untersuchungen berichtet.

Die Entleerung des 4-Hydroxybutyrats (4-HB) ist die Funktion der Kapazität des Alkoholdehydrogenase-Enzyms. Das Aufwachen erfolgt bei einer Plasmakonzentration von 90 mg/l. Ein Steady-state kann theoretisch mit wiederholten peroralen Dosen von 100 mg/kg oder mit

Infusionsdosierung oder mit einer auf die i.v. Bolusdosis folgenden Infusion (z.B. 40 mg/kg i.v. sodann 10–20 mg/kg/Stunde in der Infusion) und schließlich mit einem aus 4-HB und einer seiner Muttersubstanzen z.B. 1,4 Butandiol oder Butyrolacton bestehenden Gemisch erreicht werden. Die Kombination i.v. Bolus + Infusion führt auch beim Menschen eine Sedierung von entsprechender Tiefe herbei. Zu einer tagelang dauernden Sedierung kann aber 4-HB wegen der übermäßigen Na-Zufuhr trotzdem nicht empfohlen werden. In diesen Fällen kommt Butandiol 1,4 in Frage, welches sich im Organismus in wenigen Minuten zu 4-HB umwandelt und auf die bereits beschriebene Weise entleert wird. Das geeignete Dosierungsschema von Butandiol muß noch genau erarbeitet werden.

Butandiol gelangt in 6 Minuten durch die Plazenta, in der Nabelvene liegt aber seine Konzentration niedriger als im mütterlichen Blut. Aus dem Neugeborenen wird das Mittel sehr rasch ausgeschieden. Beim Kaiserschnitt wird durch 24–45 mg/kg 4-HB — ohne die Furcht zu deprimieren — eine adäquate mütterliche Anästhesie herbeigeführt.

In der Nachmittagssitzung kamen die Vorträge der über ihre klinischen Erfahrungen berichtenden Forscher der Bundesrepublik — Heller, Junger, Kämmerer, Hofmeister, Wüst und Steingass an die Reihe.

Durch 4-HB werden Leber, Myokard, Skeletmuskulatur, Blutzellen nicht geschädigt und die Blutgaswerte bzw. das Säure-Basen-Gleichgewicht nicht beeinträchtigt. Herz-Blutkreislauf und Atmung werden unter Wirkung des Mittels ökonomischer, der Widerstand im kleinen Kreislauf sowie der zentrale Venendruck steigen aber etwas an, während sich der ATP-Spiegel dauerhaft verringert und sich eine Kalium-Depletion entwickelt.

Die Anwendungsgebiete von 4-HB sind wie folgt: Sedierung von Respirator-Patienten, Operationsnarkose, Anästhesie beim Kaiserschnitt, Lösung schwieriger Intubationsverhältnisse nebst Spontanatmung, Ergänzung der epiduralen Anästhesie und Sicherung der Akinesie des Patienten bei der Komputer-Tomographie. Es empfiehlt sich die Medikation mit Analgetika zu kombinieren.

Das bei der Einleitung auftretende Erbrechen kann mit Atropin-Prämedikation, der extrapyramidale Myoklonus mit Barbiturat oder Diazepam und der sich beim Aufwachen meldende Tremor mit Pethidin behoben werden.

In seinem Schlußwort äußerte Frey die Ansicht, daß 4-HB uns näher zum idealen Narkotikum brachte. Am Ende der einzelnen Vorträge findet sich ein reiches, insgesamt 109 Daten enthaltendes Literaturverzeichnis, darauf folgt die kurze Erörterung der Diskussion und eine ausführliche Zusammenfassung.

Das Buch bietet dem Leser Anregungen und Hilfe zur Erprobung dieses über günstige Eigenschaften verfügenden Hypnotikums. F. INCZE

H. VALTIN

Funktion der Niere; Mechanismen zur Regulation des Wasser- und Elektrolythaushalts im gesunden Organismus

F.K. Schattauer Verlag, Stuttgart–New York 1978. 188 pages with 61 illustrations and 8 tables. DM 382, $ 17

This is a short textbook of renal physiology designed for medical students. It represents the views of the author concerning the essential elements of renal fluid and electrolyte physiology and particular emphasis is given to recent research.

The book consists of 11 chapters dealing with the questions of components of renal function, the body fluid compartments, renal haemodynamics, sodium and water balance, hydrogen ion balance as well as the renal excretion of potassium and hydrogen.

This valuable book gives a comprehensive survey of the most important theoretical and practical problems concerning electrolyte metabolism.

Many chapters are supplemented by one or more quantitative problems that amplify the material in the text. The answers, as well as the explanations of how the answers were obtained are given in the section "Lösungen der Aufgaben" following the text.

It is a book to be recommended to all doctors concerned with the problems of renal physiology and pathophysiology. There is no doubt that it will be welcomed by the majority of physiologists who teach medical students. G. KÖVÉR

CONTENTS

Kovács, L., Pályi, I. and *Tisza, S.:* Effect of low-output He–Ne laser rays on the colony-forming ability of the cells of mice lymphoma 131

Szabó, L.E., Csikós, F., *Helembai, L., Karádi, J.* and *Csiba, A.:* Metronidazole in the chemoprophylaxis of colon and rectum operations 135

Solti, F., Soltész, L., Ungvári, Gy., Szlávi, L. and *Gloviczky, P.:* Limb circulation after deep venous thrombosis 145

Antal, A. und *Lantos, J.:* Elektrometrische Messungen (pH, pK) auf der Organoberfläche bei experimenteller Änderung des Leberkreislaufes 153

Vallent, K., Fehér, J., Somogyi, Anikó und *Joós, Ágnes:* Angioneurotisches Ödem und Hypokomplementämie bei Schilddrüsenkarzinom 163

Magasi, P., Ruszinkó, B. und *Végh, A.:* Transvesikale Prostatektomie und ihre Komplikationen 173

Lukács, L. and *Péter, S.:* Early recognition of cutaneous malignant melanomas ... 183

Csata, S., Verebélyi, A. und *Gorka, A.:* Über das Nieren-Angioleiomyolipom 193

Book reviews 199

PRINTED IN HUNGARY
Akadémiai Nyomda, Budapest

The *Acta Chirurgica*, a periodical of the Hungarian Academy of Sciences in the field of medical sciences, publish original scientific treatises on surgery and related disciplines (general surgery, surgical aspects of gynecology, urology, oto-rhino-laryngology, orthopaedics, ophthalmology, as well as nerve and brain surgery, pulmonary, oral surgery, heart and blood-vessel surgery) in English, German, French or Russian, with abstracts in languages other than that of the paper.

The *Acta Chirurgica* appear in one volume per year, on some four hundred pages, divided into four fascicles issued quarterly.

Manuscripts should be addressed to

Acta Chirurgica
H-1096 Budapest, Nagyvárad tér 1. István Kórház, Urológia

Orders may be placed with "Kultura" Foreign Trading Company (H-1389 Budapest 62, P.O.B. 149) or its representatives abroad.

Les *Acta Chirurgica*, une revue de l'Académie des Sciences de Hongrie, publient des communications scientifiques originales du domaine de la chirurgie et ses disciplines voisines (chirurgie générale, gynécologie, urologie, oto-rhino-laryngologie, orthopédie, ophthalmologie, ainsi que la neuro-chirurgie, chirurgie du poumon, stomatologie, chirurgie du cœur et des vaisseaux sanguins, etc.). Les langues des communications sont: le français, l'anglais, l'allemand ou le russe, avec des résumés en d'autres langues que celle de la communication.

La revue *Acta Chirurgica* est un périodique publié en un volume par an — 400 pages environ — réparti en quatre livraisons: à paraître chaque trimestre.

On est prié d'envoyer les manuscrits destinés à la rédaction à l'adresse suivante:

Acta Chirurgica
H-1096 Budapest, Nagyvárad tér 1. István Kórház, Urológia

On peut s'abonner à l'Enterprise du Commerce «Kultura» (H-1389 Budapest 62, P.O.B. 149) ou Extérieur chez représentants à l'étranger.

Журнал Академии Наук Венгрии по медицинским наукам *Acta Chirurgica* публикует научные трактаты из области хирургических дисциплин (общая хирургия, гинекология, урология, ото-рино-ларингология, офтальмологиа, ортопедия, также как и нейрохирургия, легочная хирургия, стоматология, сосудистая хирургия, хирургия сердца и т. д.) на русском, английском, немецком или французском языках, с краткими резюме на языках, отличных от языка данной статьи. Авторами трактатов являются выдающиеся венгерские и зарубежные ученые.

Журнал *Acta Chirurgica* выходит по кварталам выпусками, составляющими один том. Приблизительные для публикации рукописи следует направлять по адресу:

Acta Chirurgica
H-1096 Budapest, Nagyvárad tér 1. István Kórház, Urológia

Заказы принимает предприятие по внешней торговле «Kultura» (H-1389 Budapest 62, P.O.B. 149) или его заграничные представительства и уполномоченные.

Periodicals of the Hungarian Academy of Sciences are obtainable at the following addresses:

AUSTRALIA
C.B.D. LIBRARY AND SUBSCRIPTION SERVICE
Box 4886, G.P.O., *Sydney N.S.W. 2001*
COSMOS BOOKSHOP, 145 Ackland Street
St. Kilda (Melbourne), Victoria 3182

AUSTRIA
GLOBUS, Höchstädtplatz 3, *1206 Wien XX*

BELGIUM
OFFICE INTERNATIONAL DE LIBRAIRIE
30 Avenue Marnix, *1050 Bruxelles*
LIBRAIRIE DU MONDE ENTIER
162 rue du Midi, *1000 Bruxelles*

BULGARIA
HEMUS, Bulvar Ruszki 6, *Sofia*

CANADA
PANNONIA BOOKS, P.O. Box 1017
Postal Station "B", *Toronto, Ontario M5T 2T8*

CHINA
CNPICOR, Periodical Department, P.O. Box 50
Peking

CZECHOSLOVAKIA
MAD'ARSKÁ KULTURA, Národní třída 22
115 66 Praha
PNS DOVOZ TISKU, Vinohradská 46, *Praha 2*
PNS DOVOZ TLAČE, *Bratislava 2*

DENMARK
EJNAR MUNKSGAARD, Norregade 6
1165 Copenhagen K

FEDERAL REPUBLIC OF GERMANY
KUNST UND WISSEN ERICH BIEBER
Postfach 46, *7000 Stuttgart 1*

FINLAND
AKATEEMINEN KIRJAKAUPPA, P.O. Box 128
SF-00101 Helsinki 10

FRANCE
DAWSON-FRANCE S. A., B. P. 40, *91121 Palaiseau*
EUROPÉRIODIQUES S. A., 31 Avenue de Versailles, *78170 La Celle St. Cloud*
OFFICE INTERNATIONAL DE DOCUMENTATION ET LIBRAIRIE, 48 rue Gay-Lussac
75240 Paris Cedex 05

GERMAN DEMOCRATIC REPUBLIC
HAUS DER UNGARISCHEN KULTUR
Karl Liebknecht-Straße 9, *DDR-102 Berlin*
DEUTSCHE POST ZEITUNGSVERTRIEBSAMT
Sraße der Pariser Kommüne 3-4, *DDR-104 Berlin*

GREAT BRITAIN
BLACKWELL'S PERIODICALS DIVISION
Hythe Bridge Street, *Oxford OX1 2ET*
BUMPUS, HALDANE AND MAXWELL LTD.
Cowper Works, *Olney, Bucks MK46 4BN*
COLLET'S HOLDINGS LTD., Denington Estate
Wellingborough, Northants NN8 2QT
WM. DAWSON AND SONS LTD., Cannon House
Folkstone, Kent CT19 5EE
H. K. LEWIS AND CO., 136 Gower Street
London WC1E 6BS

GREECE
KOSTARAKIS BROTHERS INTERNATIONAL BOOKSELLERS, 2 Hippokratous Street, *Athens-143*

HOLLAND
MEULENHOFF-BRUNA B.V., Beulingstraat 2,
Amsterdam
MARTINUS NIJHOFF B.V.
Lange Voorhout 9-11, *Den Haag*

SWETS SUBSCRIPTION SERVICE
347b Heereweg, *Lisse*

INDIA
ALLIED PUBLISHING PRIVATE LTD., 13/14
Asaf Ali Road, *New Delhi 110001*
150 B-6 Mount Road, *Madras 600002*
INTERNATIONAL BOOK HOUSE PVT. LTD.
Madame Cama Road, *Bombay 400039*
THE STATE TRADING CORPORATION OF INDIA LTD., Books Import Division, Chandralok
36 Janpath, *New Delhi 110001*

ITALY
INTERSCIENTIA, Via Mazzé 28, *10149 Torino*
LIBRERIA COMMISSIONARIA SANSONI, Via Lamarmora 45, *50121 Firenze*
SANTO VANASIA, Via M. Macchi 58
20124 Milano
D. E. A., Via Lima 28, *00198 Roma*

JAPAN
KINOKUNIYA BOOK-STORE CO. LTD.
17-7 Shinjuku 3 chome, Shinjuku-ku, *Tokyo 160-91*
MARUZEN COMPANY LTD., Book Department,
P.O. Box 5050 Tokyo International, *Tokyo 100-31*
NAUKA LTD. IMPORT DEPARTMENT
2-30-19 Minami Ikebukuro, Toshima-ku, *Tokyo 171*

KOREA
CHULPANMUL, *Phenjan*

NORWAY
TANUM-TIDSKRIFT-SENTRALEN A.S., Karl Johansgatan 41-43, *1000 Oslo*

POLAND
WĘGIERSKI INSTYTUT KULTURY, Marszałkowska 80, *00-517 Warszawa*
CKP I W, ul. Towarowa 28, *00-958 Warszawa*

ROUMANIA
D. E. P., *Bucureşti*
ILEXIM, Calea Grivitei 64-66, *Bucureşti*

SOVIET UNION
SOJUZPECHAT — IMPORT, *Moscow*
and the post offices in each town
MEZHDUNARODNAYA KNIGA, *Moscow G-200*

SPAIN
DIAZ DE SANTOS, Lagasca 95, *Madrid 6*

SWEDEN
ALMQVIST AND WIKSELL, Gamla Brogatan 26
101 20 Stockholm
GUMPERTS UNIVERSITETSBOKHANDEL AB
Box 346, *401 25 Göteborg 1*

SWITZERLAND
KARGER LIBRI AG, Petersgraben 31, *4011 Basel*

USA
EBSCO SUBSCRIPTION SERVICES
P.O. Box 1943, *Birmingham, Alabama 35201*
F. W. FAXON COMPANY, INC.
15 Southwest Park, *Westwood Mass. 02090*
THE MOORE-COTTRELL SUBSCRIPTION AGENCIES, *North Cohocton, N. Y. 14868*
READ-MORE PUBLICATIONS, INC.
140 Cedar Street, *New York, N. Y. 10006*
STECHERT-MACMILLAN, INC.
7250 Westfield Avenue, *Pennsauken N. J. 08110*

YUGOSLAVIA
JUGOSLOVENSKA KNJIGA, Terazije 27, *Beograd*
FORUM, Vojvode Mišića 1, *21000 Novi Sad*

HU ISSN 0001—5431 **Index: 26.008**

Acta CHIRURGICA

ACADEMIAE SCIENTIARUM HUNGARICAE

EDITORIAL BOARD

BABICS ANTAL (chairman of the board), CSATA SÁNDOR (managing editor), PETRI GÁBOR (president), GLAUBER ANDOR, IHÁSZ MIHÁLY, MÉREI F. TIBOR, PÁSZTOR EMIL, RADNÓT MAGDA, RUBÁNYI PÁL, SURJÁN LÁSZLÓ, SZÉCSÉNY ANDOR, ZOLTÁN IMRE, ZSOLNAI BÉLA

ACTA CHIR. HUNG. TOMUS XXIII * FASCICULUS 4

AKADÉMIAI KIADÓ, BUDAPEST
1982

ACTA CHIRURGICA

ACADEMIAE SCIENTIARUM HUNGARICAE

A MAGYAR TUDOMÁNYOS AKADÉMIA ORVOSTUDOMÁNYI FOLYÓIRATA

FŐSZERKESZTŐ:

Dr. BABICS ANTAL akadémikus

SZERKESZTŐ:

Dr. CSATA SÁNDOR, az orvostudományok kandidátusa

A SZERKESZTŐSÉG CÍME: H-1096 BUDAPEST, NAGYVÁRAD TÉR 1. ISTVÁN KÓRHÁZ, UROLÓGIA
KIADJA AZ AKADÉMIAI KIADÓ, H-1054 BUDAPEST, ALKOTMÁNY U. 21.

Az *Acta Chirurgica* német, angol, francia, ill. orosz nyelven tudományos értekezéseket közöl a sebészet (általános sebészet, nőgyógyászat, urológia, oto-rhino-laryngológia, orthopaedia, szemészet, agy- és idegsebészet, tüdősebészet, szájsebészet, szív- és érsebészet stb.) tárgyköréből.

Az *Acta Chirurgica* évente 1 kötetben jelenik meg, mintegy 400 oldal terjedelemben. A kötet 4, negyedévenként megjelenő füzet formájában kerül kiadásra.

A közlésre szánt kéziratok, valamint a szerkesztőségi levelezés az alábbi címre küldendők:

Acta Chirurgica
H-1096 Budapest, Nagyvárad tér 1. István Kórház, Urológia

Megrendelhető a belföld számára az Akadémiai Kiadónál (1363 Budapest Pf. 24. Bankszámla: 215-11448), a külföld számára pedig a „Kultura" Külkereskedelmi Vállalatnál (1389 Budapest 62, P.O.B. 149. Bankszámla: 218-10990) vagy annak külföldi képviseleteinél és bizományosainál.

Die medizinwissenschaftliche Zeitschrift der Ungarischen Akademie der Wissenschaften *Acta Chirurgica* veröffentlicht Originalbeiträge ungarischer und ausländischer Wissenschaftler aus dem Themenkreis der Chirurgie und der verwandten Gebiete (allgemeine Chirurgie sowie die chirurgischen Beziehungen der Gynäkologie, Urologie, Oto-Rhino-Laryngologie, Orthopädie, Ophthalmologie usw., ferner Neurochirurgie, Gehirnchirurgie, Herz- und Gefäßchirurgie usw.) in deutscher, englischer, französischer oder russischer Sprache, mit kurzen anderssprachigen Zusammenfassungen.

Die *Acta Chirurgica* erscheinen jährlich in einem Band — im Umfang von etwa 400 Seiten — vier in vierteljährlichen Heften.

Die zur Veröffentlichung bestimmten Manuskripte sind an folgende Adresse zu senden:

Acta Chirurgica
H-1096 Budapest, Nagyvárad tér 1. István Kórház, Urológia

Bestellbar bei »Kultura« Außenhandelsunternehmen (H-1389 Budapest 62, P.O.B. 149) oder seinen Auslandsvertretungen.

Acta Chirurgica Academiae Scientiarum Hungaricae, Tomus 23 (4), pp. 205–208 (1982)

Die Epidermoidzyste des Hodens

J. HÜBLER,[1] M. ISTVÁN,[2] L. GIMES[1] und Z. NAGY[1]

Urologische Klinik[1] und Institut für Pathologische Anatomie[2] der Medizinischen Universität, Pécs

(Eingegangen am 4. Februar 1982)

Nach einem Überblick der Literatur der selten vorkommenden Epidermoidzyste des Hodens und der Darstellung eines eigenen Falles, wird die therapeutische Stellungnahme erläutert, laut der die Therapie der Wahl die Kastration darstellt.

Die Kriterien der Epidermoidzyste des Hodens hat Price [7] 1969 zusammengefaßt. Demnach handelt es sich hierbei um eine Zyste, die im Hodenparenchym sitzt, in ihrem Innenraum eine keratinisierte Masse enthält und eine fibrotische mit Epithel bedeckte Wand hat. Durch das mehrschichtige Plattenepithel, in dem keine akzessorischen Hautelemente (Talgdrüsen, Haarbälge, Schweißdrüsen) sichtbar sind, wird die Zyste vollkommen oder teilweise ausgekleidet. Anhand dieses Plattenepithels kann die Epidermoidzyste von der Dermoidzyste abgesondert werden. Als weiteres wichtiges Kriterium hält Price [7], daß die Hodensubstanz nebst der mit Epidermoid ausgekleideten Zyste keine teratomatösen Teilchen enthalte.

Die Epidermoidzyste kommt im Hoden nur selten vor. Laut der Daten der American Testicular Registry betrug ihre Häufigkeit 1% der Hodentumoren. Barnhouse [2] sammelte bis 1972 23 epidermoide Hodenzysten aus der amerikanischen Literatur zusammen. Gilbaugh und Mitarb. [5] fanden in der Weltliteratur bis 1967 27 Epidermoidzysten, während in der 1972 erschienenen Arbeit von Valerio [10] diese Zahl sich bereits auf 97 erhöhte. Schätzungsweise wurden aber, auch die Mitteilung von Mikuz und Attlmayr [6] berücksichtigen, nicht mehr als 100 Fälle beschrieben.

Von Wichtigkeit ist die Differenzierung der einfachen und der komplizierten Epidermoidzyste. Die Kriterien der einfachen Epidermoidzyste sind anhand der Arbeiten von Price [7] bekannt. Als kompliziert nennt man die Epidermoidzyste dann, wenn im Hodenparenchym außer der Epidermoidzyste auch ein Teratom vorhanden ist. Cook und Kimbrough [4] sowie Azzopardi und Mitarb. [1], in deren Material solche Fälle, außerdem aber auch in Begleitung von Karzinommetastase, Teratokarzinom und Choriokarzinom beobachtbare Epidermoidzysten vorkamen, vertraten die Meinung, daß die Epidermoidzyste des Hodens immer ein Teil eines komplexen Teratoms ist.

Was die Behandlung anbelangt, betrachten sämtliche Autoren die Kastration als die Therapie der Wahl. Barnhouse [2] erklärte diese Stellung-

nahme damit, daß unsere Kenntnisse betreffs der Eigenart der Epidermoidzyste lückenhaft sind: Betrachtet man sie als ein Teratom, so dürfte sie in die Gruppe der malignen Tumoren eingereiht werden. Dies wurde von Collins und Pugh [3] unterstützt, die in ihrem Material von 995 Hodentumoren nur 13 Fälle von differenziertem Teratom registrierten, unter denen 2 Patienten mit Tumormetastasen starben. In einem Fall von Weitzner [11] meldeten sich nach einer 7jährigen Beobachtungszeit choriokarzinomatöse Metastasen. Laut Pugh und Smith [8] ist die Epidermoidzyste als ein ausgereiftes, bei Erwachsenen zur Metastasebildung neigendes Teratom zu betrachten. Versäumt man die Kastration, können nicht einmal die sog. komplizierten Epidermoidzysten erkannt werden. Nach Barnhouse [2] soll der Hoden nur bei in Anwesenheit eines entzündlichen Prozesse konserviert werden.

Falldarstellung

F. H. der 35 jährige Patient meldete sich wegen Induratio penis plastica zur Untersuchung.

Urologischer Befund: Am hinteren lateralen Teil des rechtsseitigen Hodens kann ein sich dicht anfühlendes, fingerbeerengroßes Gebilde palpiert werden. Intravenöse Urographie: Normalverhältnisse. Laborergebnisse: o.B.

Freilegung des Hodens aus linksseitiger skrotaler Inzision; der Nebenhoden zeigte keine pathologische Veränderung, in der Hodensubstanz sah man eine von der Hodensubstanz mit einer Kapsel abgegrenzte Zyste mit blätteriger Struktur und einem Durchmesser von 2 cm; die Schnittfläche war gelblich-grau, das Zysteninnere füllte eine gelblich-graue weiche Masse aus. Wir entschieden uns zur Kastration (Abb. 1).

Histologischer Befund: Reaktionsfreier Nebenhoden, die von der Zyste nicht infiltrierten Hodenparenchym-Abschnitte sind intakt (Abb. 2). Diagnose: Mit Epidermis ausgekleidete, Hornmassen enthaltende Cysta epidermoides.

Nach dem Eingriff wurde Patient 2 Jahre lang regelmäßig kontrolliert, ohne daß sich Malignisationszeichen gemeldet hätten, dessen ungeachtet wurde er aber angesichts der bekannten Malignisationsgefahr in onkologische Betreuung genommen. Die Induratio penis plastica wurde, da Patient in die Operation nicht einwilligte, konservativ behandelt.

Den Fall hielten wir wegen seiner Seitenheit als interessant. Bei gutartigen Hodentumoren trachten wir ebenfalls die inguinale Kastration durchzuführen. Bei der Epidermoidzyste des Hodens betrachten wir im Einklang mit der Weltliteratur die Kastration als die Therapie der Wahl.

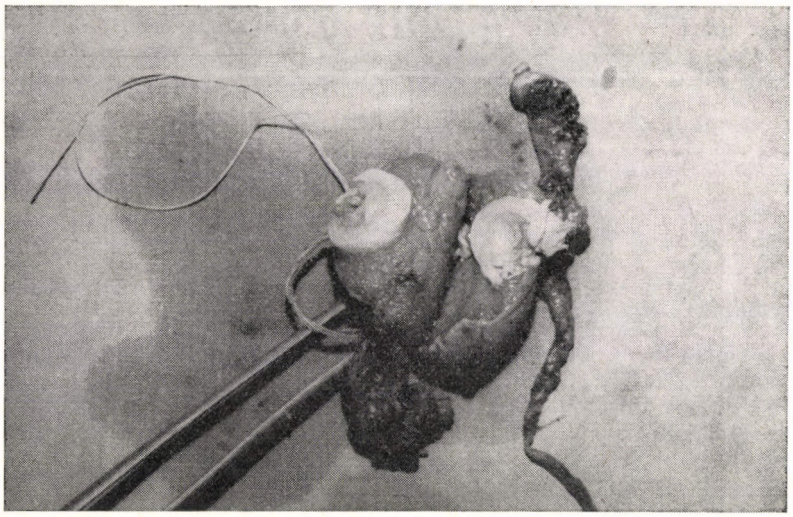

ABB. 1. Der entfernte Hoden mit Epidermoidzyste im Parenchym

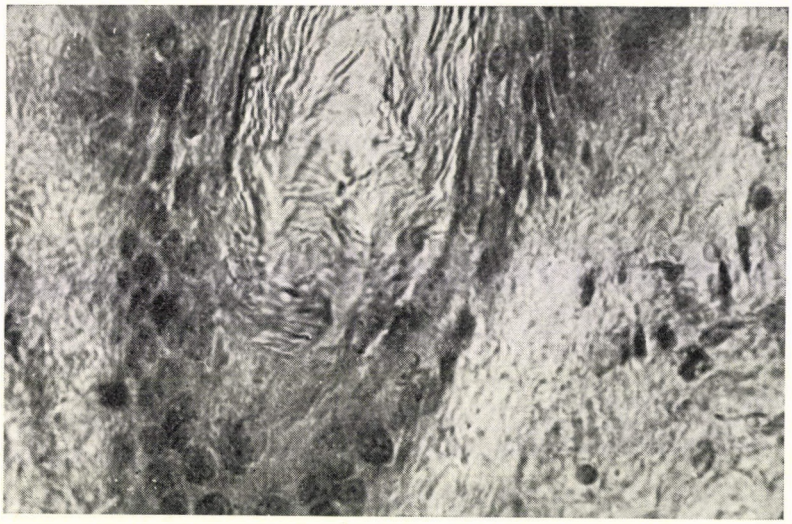

ABB. 2. Epithelbelag der Epidermoidzyste

Literatur

1. Azzopardi JG, Mostofi FK, Theiss EA: Lesions of the testes observed in certain patients with widespread choriocarcinoma and related tumours. The significance in genesis of hematoxylin-staining bodies in the human testis. Am J Pathol 38:207, 1961
2. Barnhouse, DH: Epidermoid cyst of the testicle. Br J Urol 33: 364, 1972

3. Collins DH, Pugh RCB: The pathology of testicular tumors. Br J Urol 36: Suppl June, 1964
4. Cook FE Jr, Kimbrough JC: Epidermoid cysts of testicle. J Ur 72: 236, 1954
5. Gilbaugh JH Jr, Kelalis PP, Dockerty MB: Epidermoid cysts of the testes. J Ur 97: 876, 1967
6. Mikuz G, Attlmayr G: Die Epidermoidcyste des Hodens. Zentralbl Allg Pathol 118: 235, 1974
7. Price EB Jr: Epidermoid cysts of the testis: A clinical and pathologic analysis of 69 cases from the testicular tumor registry. J Ur 102: 708, 1969
8. Pugh RCB, Smith JF: Teratoma. In: The Pathology of Testicular Tumors, eds: Colling DH and Pugh RCB. 2nd ed. Livingstone, Edinburgh and London 1965
9. Sigel A, Kriegner F: Scrotal operation or biopsy of testicular tumors. A fatal mistake. In: Recent Results in Cancer Research, eds Grundman E and Vahlensieck W. Springer Verlag, Berlin—Heidelberg—New York 1977
10. Valerio RA: Epidermoid cyst of the testis. Br J Urol 44: 3616, 1972
11. Weitzner S: Epidermoid cyst of testis: Report of five cases and review of the literature. J Ur 91: 380, 1964

Epidermoid Cyst of the Testicle

J. Hübler, M. István, L. Gimes and Z. Nagy

After a brief review of the literature on the epidermoid cyst of the testicle, the aspects of the disease are discussed. It stressed that castration is an unavoidable part of the treatment of this type of cyst.

Об эпидермоидной кисте семенников

Я. ХУБЛЕР, М. ИШТВАН, Л. ГИМЕШ и З. НАДЬ

Авторы занимаются редкой эпидермоидной кистой семенников. После обзора литера туры знакомят с собственным взглядом на данной заболевание.

Подчеркивают, что при лечении эпидермоидной кисты семенников необходимо производить кастрацию.

Dr. János Hübler
Dr. Lajos Gimes
Dr. Zoltán Nagy
Urologische Klinik der Medizinischen Universität, Pécs, Munkácsy M. u. 2, H-7621

Dr. Mihály István
Institut für Pathologische Anatomie der Medizinischen Universität, Pécs, Szigeti út 12, H-7625

Acta Chirurgica Academiae Scientiarum Hungaricae, Tomus 23 (4), pp. 209–216 (1982)

Comparison of Suture Materials in the Pancreas

P. SÁPY, I. MIKÓ and I. FURKA

First Department of Surgery and Institute of Experimental Surgery, University Medical School, Debrecen

(Received May 14, 1981)

Comparative tests were performed in animal experiments with traditional and new suture materials placed into the pancreas. Dexon and polyester caused the least tissue reaction and their reaction indices were the most favourable. These threads therefore appear the most suitable for making sutures in the pancreas.

Research and comparison of surgical suture materials have not lost their actuality, there being no ideal surgical thread which would keep the wound together till complete healing and then disappear from the organism. Lacking such a material we can only postulate the requirements which the surgical threads have to meet. These are an adequate tensile strength, good sterilizability, appropriate flexibility, smooth surface; the threads should be easy to handle, and keep the knots. In addition, the thread should cause a minimum of foreign body reaction, should not be toxic, induce allergy or have a carcinogenic action, it should be resistant to acids, alkalis, enzymes and other active substances of the tissue and remain unaltered in an environment infected by fungi or bacteria, and should not drain the tissue. Conn et al. [2] postulate additional demands for absorbable suture. At the beginning, the absorbable thread should possess a high adhesive strength which ought to decrease at an appropriate rate during the healing of the wound, and its absorption must not depend upon enzymatic processes.

Miller [7] proposed further requirements with respect to synthetic threads: polymeric suture materials should consist of stable components, the synthetic polymer should have no influence on the physiologic processes of the tissue and should, if possible, be a monofilament to ensure resistance to bacteria.

The choice of surgical threads the most suitable for suturing different organs raises new problems. In this respect a number of papers have dealt with comparative examinations and the practical application of suture materials. In gastroenterologic surgery, for suturing wounds of the oesophagus, stomach, bowels and of the liver, experiments were performed with various suture materials and several among them have been tried in practice. Imre [5] achieved excellent results with stainless steel sutures of the oesophagus and the stomach. Littmann et al. [6] are also of the opinion that the use of single-

row steel wire sutures is advantageous in the surgery of the digestive tract from the oesophagus to the rectum. On the basis of comparative experiments, Bornemisza et al. [1] recommended Dexon and polyester threads for the preparation of intestinal anastomoses. Gyurkó [4] recommended synthetic threads for suturing wounds of the liver. With respect to the pancreas, only Mizuma et al. [8] investigated under conditions *in vitro* the tensile strength of a few suturing materials exposed to the effect of pancreatic juice. In the literature at our disposal we found, however, no data on the surgical threads most suitable for preparing sutures in the pancreas under conditions *in vivo*. The problem is of practical importance as surgical interventions on the pancreas are often performed.

Material and Method

Experiments were carried out on 24 mongrel dogs, without respect to age, sex or weight. According to a plan, stitches were placed three to four cm apart into the pancreas including the glandular substance, with 000 thickness thread fixed in atraumatic needles. The threads were knotted.

The materials used were as follows:

I.1. Traditional, natural non-absorbable suture materials: flax, silk;
2. traditional natural absorbable suture material, catgut;
II.1. synthetic non-absorbable suture materials: polyamide (Supramide) polyethylene (Prolone), polyester;
2. synthetic absorbable suture material: polyglycolic acid (Dexon).

The animals were re-operated on the 3rd, 7th, 14th and 21st postoperative days. In the course of the operation the pancreas and its environment were examined for oedema, inflammatory reaction and adhesions. Visual inspection was followed by histologic assessment of slides prepared from sections of the pancreas stained with haemalum-eosin and by Van Gieson's method. The microscopic tests formed the basis of the calculation of the reaction index [3, 4] which provides identical conditions for the comparison of suture materials (Fig. 1).

Results

Surgical technique

With respect to the practical applicability of the threads, it was found that all threads were easy to knot and none posed a problem to the surgeon. Compared to the others, the suture materials made of polyamide and polypropylene are somewhat rigid, but this was no obstacle to their application.

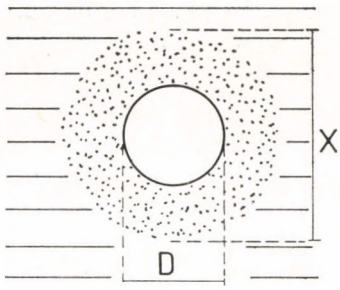

$$R_i = \frac{D}{X}$$

FIG. 1. Calculation of the reaction index. R_i = reaction index; D = diameter of thread; X = size of the reaction halo

Visual inspection

Around the silk, flax and catgut stitches marked swelling and oedema were observed on the third postoperative day. The swelling hardly regressed up to the 21st day. In a few cases, easily separable adhesions were found in the environment of the pancreas. Around the synthetic threads there was almost no tissue reaction.

Microscopic examination

I.1. On the third and seventh postoperative days some oedema and marked round-cell infiltration were observed around silk and flax threads. The width of the round-cell halo was greater around the flax thread. On the 14th and 21st postoperative days, beside cellular infiltration, connective tissue fibres appeared around the suture; these surrounded the flax thread like a broad capsule. The capsule around the silk thread was smaller (Figs 2 and 3).

I.2. Around the catgut marked oedema and a wide round-cell halo was observed on the third and seventh postoperative days. Disintegration of the thread was clearly visible on the 14th, and quite marked on the 21st day (Fig. 4).

II.1. Around the synthetic non-absorbable suture materials only a slight oedematous halo was observed on the third day; it disappeared by the seventh postoperative day. The cellular reaction was the least significant around the polyester; it was more expressed around polyethylene and even more marked in the vicinity of polyamide threads. On the 14th and 21st postoperative days hardly any cellular infiltration was visible around polyester threads and the number of connective tissue fibres was quite small. The appearance of connective tissue fibres was not significant around the other two sutures either (Figs 5 and 6).

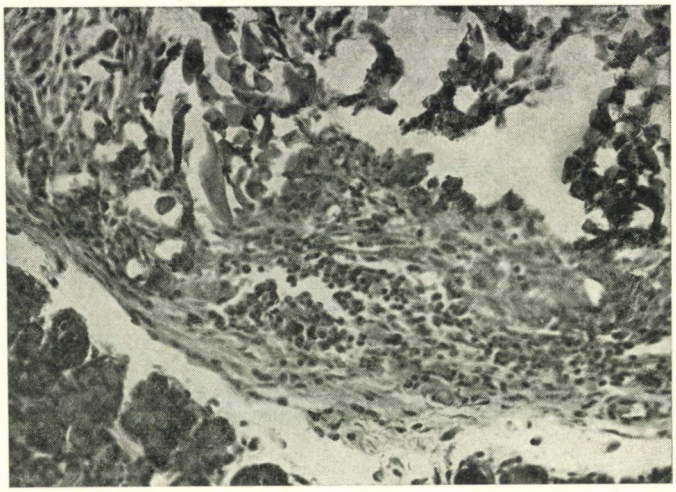

FIG. 2. Wide and cell-rich capsule-like connective tissue formation around flax on 21st postoperative day (haemalum-eosin staining, ×110)

II.2. On the third postoperative day hardly any oedema could be observed around the polyglycolic acid thread, and the cellular reaction was negligible. Disintegration of the thread was apparent by the 14th day and on the 21st postoperative day the thread residues stained only faintly. By this time the cellular reaction and the thin capsule-like connective tissue practically disappeared (Fig. 7).

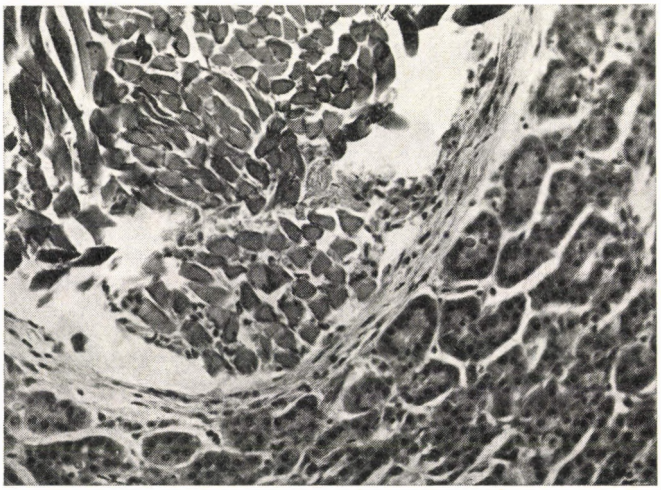

FIG. 3. Less cell-rich capsule-like connective tissue formation of medium thickness around silk on 21st postoperative day (haemalum-eosin staining, ×110)

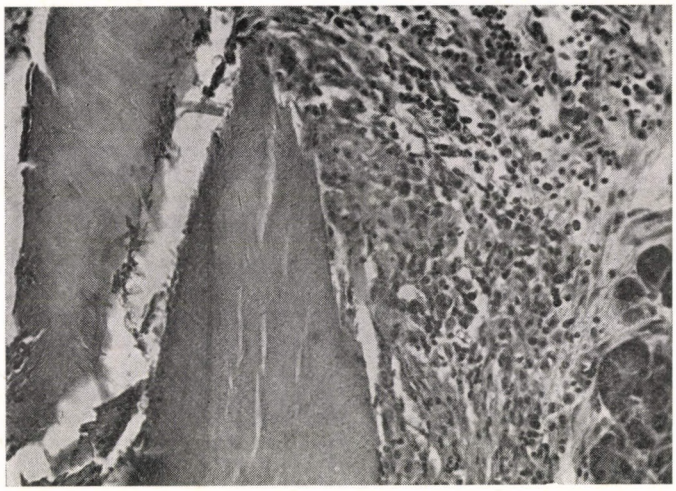

FIG. 4. By the 21st postoperative day catgut has become greatly fragmented but is surrounded by a wide, cell-rich reaction-halo (haemalum-eosin staining, ×110)

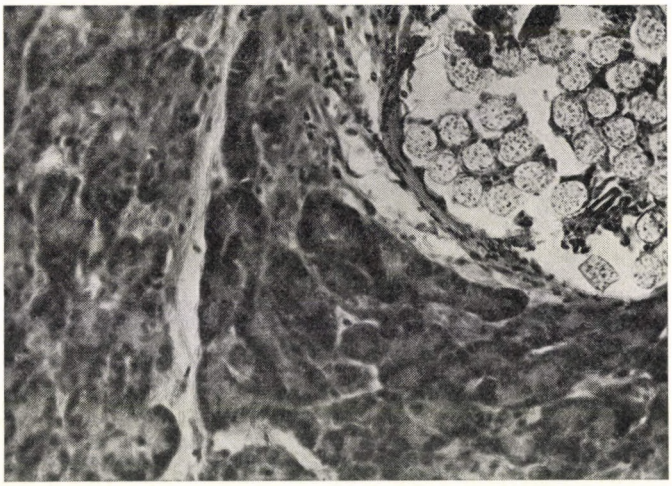

FIG. 5. A very slight reaction-halo appears around the polyester thread on 21st postoperative day (haemalum-eosin staining, ×110)

Discussion

Reaction index of the suture materials

The reaction index for the various materials reflect the histological result and can be plotted in a coordinate system (Fig. 8).

Around the silk, flax and catgut threads an intense inflammatory reaction occurred, consequently, these materials have a low reaction index giving

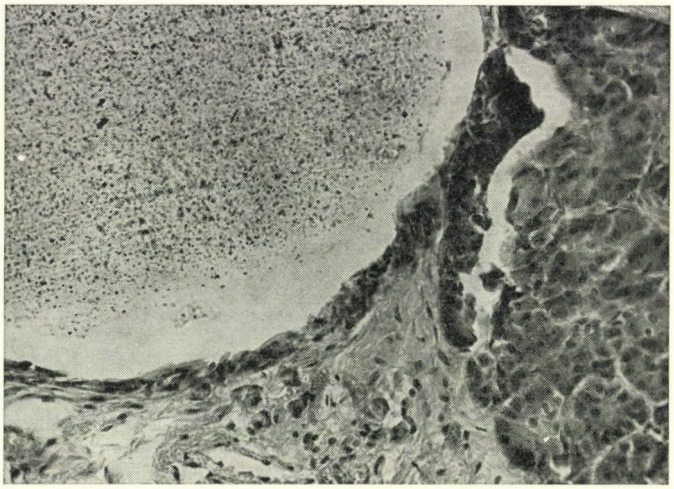

FIG. 6. In the vicinity of the polyethylene suture the tissue reaction is limited to a small area (haemalum-eosin staining, ×110)

a flat curve. These threads do not seem to be suitable for placing sutures in the pancreas. On the other hand, polyglycolic acid and polyester had highly arched curves which means that these suture materials cause the smallest tissue reaction, and so are the most suitable for suturing pancreas wound. However, according to Mizuma's [8] experiments, the tensile strength of polyglycolic acid in contact with the pancreatic juice dropped to one-third of its initial value in 14 days and this period might not be sufficient for the complete healing of the pancreatic wound.

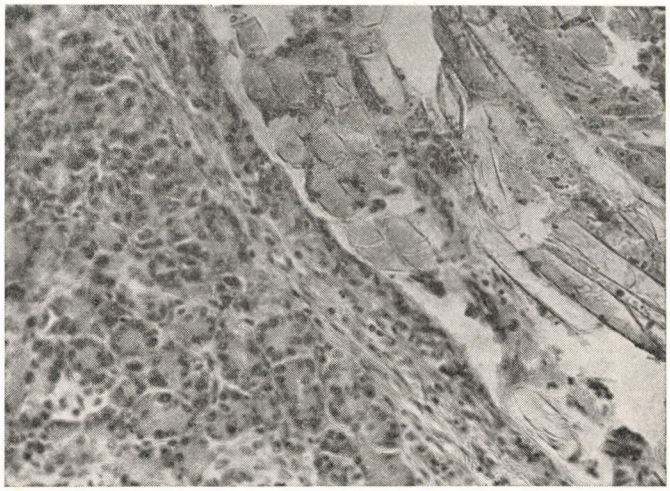

FIG. 7. Around the polyglycolic acid thread a thin capsule-like connective tissue formation poor in cells is visible on the 21st postoperative day (haemalum-eosin staining, ×110)

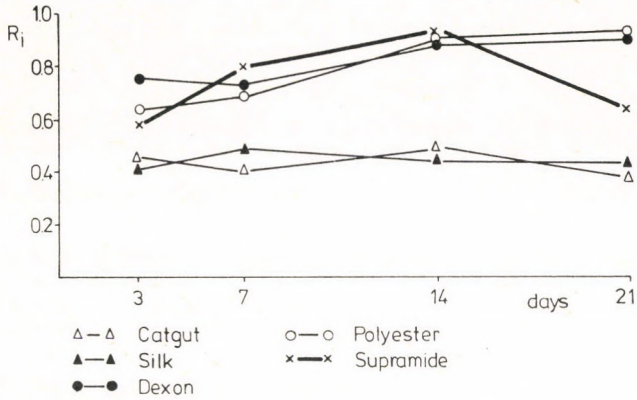

FIG. 8. Comparison of the reaction indices of the suture materials applied

Taking into consideration all experiments, it appears that of the investigated suture materials in the pancreas of the dog, polyglycolic acid and polyester come nearest to the ideal material, and may be recommended to be applied in clinical practice.

References

1. Bornemisza Gy, Szentkereszty B, Furka I, Mikó I: Comparison of suture materials for intestinal anastomosis. Acta Chir Acad Sci Hung 20: 29, 1979
2. Conn J, Oyasu R, Welsh M, Beal JM: Vicryl (polygalactin 910) synthetic absorbable sutures. Am J Surg 128: 19, 1974
3. Furka I, Nagy V, Szilasi M: Különböző varróanyagokkal készített kísérletes hólyagvarratok összehasonlító vizsgálata (Comparative study of experimental bladder sutures prepared with various suture materials). Magy Seb 30: 321, 1977
4. Gyurkó Gy: Sebészi varróanyagok összehasonlító vizsgálata májban (Comparative study of surgical suture materials in the liver). Magy Seb 18: 387, 1965
5. Imre J: Módszerek és lehetőségek a nyelőcsőműtétek biztonságának és hatásfokának javítására (Methods and possibilities of improving the reliability and effectiveness of oesophageal operations). Thesis, Szeged 1975
6. Littmann I, Kiss J, Barda L, Vörös A, Pintér J: Egysoros drótvarrat a tápcsatorna sebészetében (One-row wire suture in the surgery of the alimentary canal). Orv Hetil 118: 2319, 1977
7. Miller JM: Evaluation of a new surgical suture (Prolene). Am J. Surg 33: 666, 1967
8. Mizuma K, Lee PC, Howard MJ: The disintegration of surgical sutures on exposure to pancreatic juice. Ann Surg 186: 718, 1977

Vergleichende Untersuchungen mit in das Pankreas eingelegten Nahtmaterialien

P. SÁPY, IRÉN MIKÓ und I. FURKA

Im Tierexperiment wurden mit in das Pankreas eingelegten traditionellen und neuen, synthetischen Nahtmaterialien vergleichende Untersuchungen vorgenommen. Die Ergebnisse sprachen dafür, daß die kleinsten Gewebereaktionen durch Dexon und

Polyester verursacht wurden; diese Fäden, die sich auch was die Reaktionsindexe anbelangt, für die besten erwiesen, scheinen sich am meisten zur Verfertigung von Pankreasnähten zu eignen.

Сравнительные исследования шовных материалов, выполненные на поджелудочной железе

П. ШАПИ, И. МИКО и И. ФУРКА

В экспериментах на животных авторы выполнили сравнительное изучение традиционных и новых, синтетических шовных материалов, помещенных в поджелудучную железу. Как показывают результаты опытов, самую слабую тканевую реакцию вызывают прежде всего Дексон и полиэстер, они же показывают самые лучшие индексы реакции, почему и являются наиболее подходящими для панкреатических швов.

Dr. Péter SÁPY
Dr. Irén MIKÓ
Dr. István FURKA

First Department of Surgery and Institute of Experimental Surgery, University Medical School, Debrecen

Acta Chirurgica Academiae Scientiarum Hungaricae, Tomus 23 (4), pp. 217–227 (1982)

Diagnosis and Treatment of Adult Polycystic Kidney Disease

Á. Csontai, Gy. Nádas, J. Makó, J. Pánovics and F. Balogh

Department of Urology, Semmelweis University Medical School

(Received June 21, 1981)

The methods applicable to the diagnosis of polycystic kidney disease are reviewed. By assessing the clinical data of 314 patients suffering from adult polycystic kidney disease who had been treated in the 30 years between 1950 and 1979, the importance of conservative therapy and nephrological care is emphasized. The significance of hemodialysis in therapy and the special circumstances of transplantation are discussed. The indication of surgical treatment can be extended in complication-free cases.

In the development of polycystic kidney an important role is attributed to disturbances in the fusion of the nephrogenic secretory tubli with the collecting tubuli developing from the ureteric bud. The prognosis of the disease has been considered rather poor. Due to the progressive process, in most patients the pase of renal failure sooner or later ensues, and the associated septic complications speed up the process considerably. Early diagnosis is today possible with the help of the available up-to-date diagnostic methods, and recent developments in therapy have improved the outlook of the patients.

Material and Method

In our Department 314 patients suffering from polycystic kidney disease were treated in the 30 years from 1950 to the end of 1979. All patients were adults belonging to Potter type 3. There were 152 men and 162 w.omen The family history confirmed in 28 cases (8.9%) the disease in the ascendents. More serious complaints appeared, as a rule, after the age of 30. This is reflected in the patients' age at the time of diagnosis: 82.8% were between the age of 31 and 60 (Fig. 1).

The function of the kidney usually deteriorates slowly, so that the organism can adapt itself to the situation and the first symptoms are not typical. Quite often years pass between the manifestation of early symptoms and the correct diagnosis; in the majority of our cases this period was more than two years (Fig. 2).

The three classical symptoms of the disease are haematuria, hypertension and a palpable kidney. The three symptoms coincided rarely in our material. Quite often a dull, uncertain tense pain in the back was the first symptom,

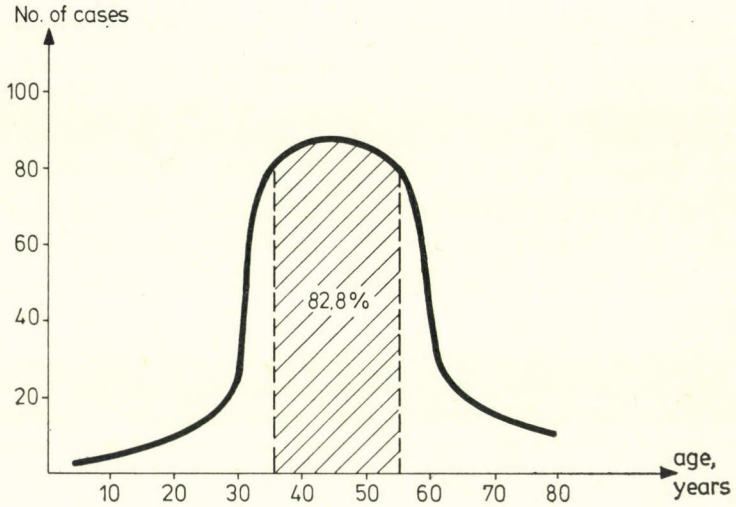

FIG. 1. Age distribution of patients

accompanied by thirst, lack of appetite and a sensation of weakness (Fig. 3). In 61 patients (19.4%) the disease was accompanied by renal calculi; in this case renal colic was the first symptom.

Palpation. In progressive cases a large formation was palpated filling the costovertebral angle on both sides, with a loose abdominal wall and, an uneven surface of the kidney.

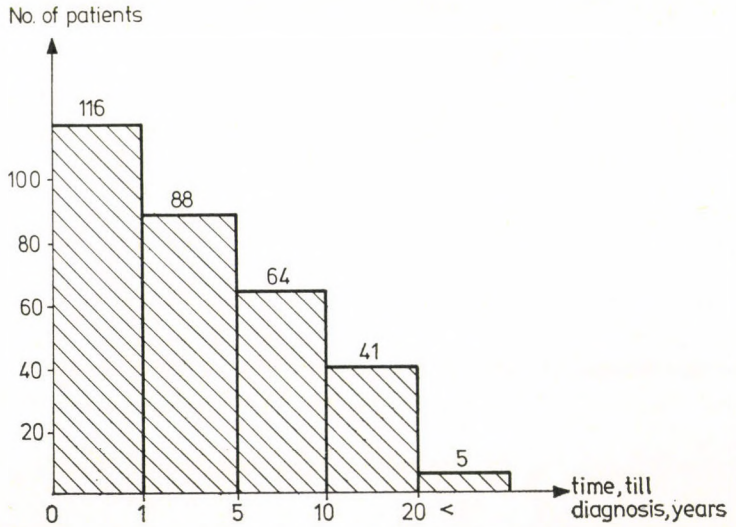

FIG. 2. Time from the appearance of symptoms to correct diagnosis

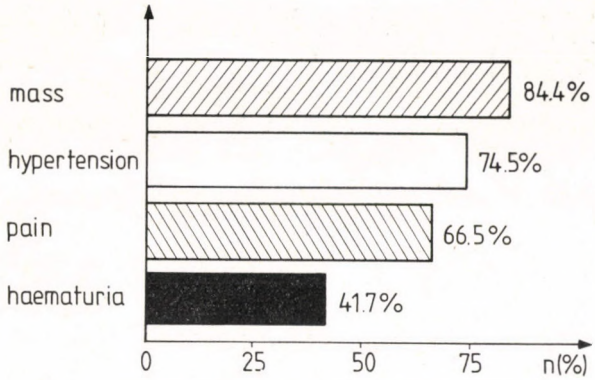

FIG. 3. Frequent symptoms

X-rays are indispensable for the correct diagnosis. In the course of traditional *urography* the first pictures were taken in the 0.5th, 3rd and 5th minute, as early nephrograms have a special value. In the majority of cases tomograms were prepared. *Chamber scintigraphy* is a comparatively new method. Chlomerodrine labelled with ^{197}Hg is bound, for a few hours, to the epithelial cells of the renal tubules and the activity distribution is easy to measure. The polycystic kidneys appeared on the scintigram enlarged in all directions with lobated contours. In the parenchyma, corresponding to the cysts, a number of activity losses more or less of equal size was visible, but cysts smaller than 2.5 cm could not be revealed. *Ultrasonic* examination is a non-invasive method which involves no risk and preparation, and can be performed in outpatients, too. Ultrasonic diagnosis of renal diseases was first suggested in Hungary by Falus and worked out in detail by Szabó et al. [29]. We employed this test in 77 cases. The polycystic kidney was characterized by a restless echogram. Depending upon electronic amplification, at low intensities the structure was not marked, while at higher intensities round, echoless zones corresponding to the cysts appeared (Figs 4*A* and *B*). *In vivo*, the small-cystic and large-cystic forms of the polycystic kidney can be distinguished unambiguously only by means of the ultrasonic test. The importance of this distinction is the significantly worse prognosis of the small-cystic form. *Angiography*, not being an absolutely harmless procedure, was performed only when absolutely necessary. Its most important indication was the suspicion of a tumour in the polycystic kidney. While in the polycystic kidney the main arteries are drawn apart and are characteristic areas without vascular tracings, in the patients with tumour pathological vascular tracings and pools of contrast material are visible in the affected area [1]. The venous phase is often missing.

The majority of patients suffering from polycystic renal degeneration reach the stage of renal failure around the age of 35 to 45 years.

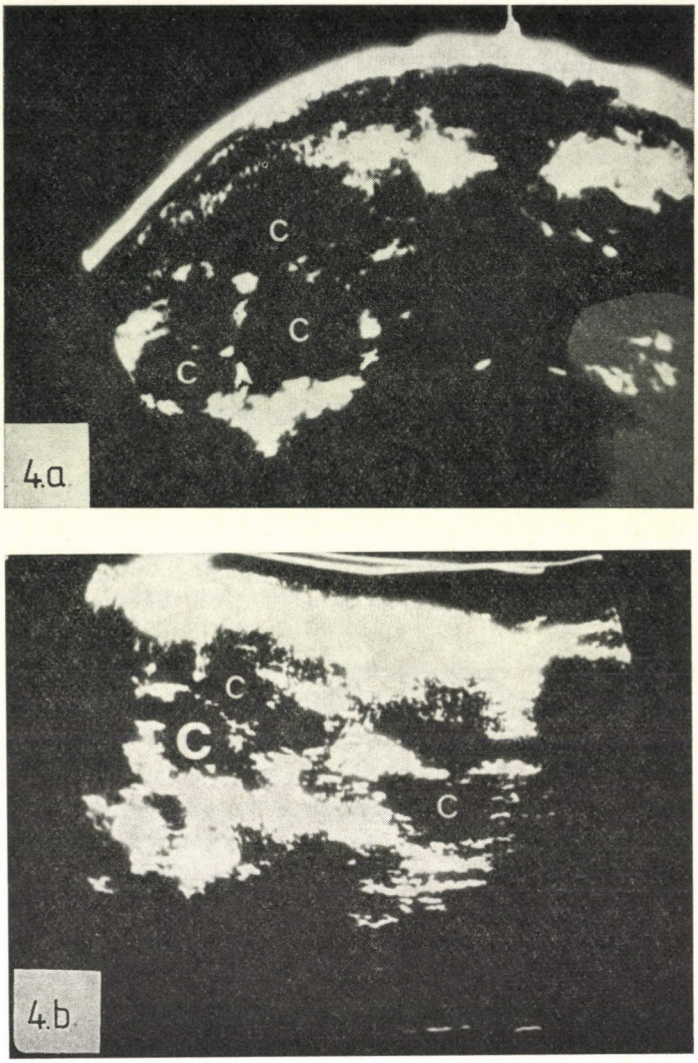

FIG. 4. Ultrasonic picture of polycystic kidney. *A:* cross-section; *B:* longitudinal section (By the courtesy of Dr. V. Szabó)

We used four therapeutic methods, namely

1. nephrologic care
2. haemodialysis
3. transplantation
4. surgical treatment

1. Regular check-ups from the time of diagnosis are necessary. Nephrological care in the stricter sense of the word was started when the first symptoms

of deteriorating renal function had appeared. At the beginning, it was based on the prescription of an appropriate diet. By means of the modified Giordano—Giovanetti diet [23] rich in essential amino acids and containing 25 to 30 g of protein, and by the administration of furosemide ensuring a diuresis of 3 to 4 litres daily, the progression of renal insufficiency could be slowed down considerably [12]. Attention was paid to the possibility of infection. In the case of pyuria or significant bacteriuria, antibiotics are indispensable. Whenever necessary, the drug therapy was continued for months. Even small doses of nephrotoxic drugs were avoided. The life of older patients, once they have become uraemic, must be prolonged by means of conservative therapy. The possibilities and limitations of the latter shall be demonstrated by the case histories of two of our patients.

In the case of A.S., a 59 year-old female patient, polycystic kidney disease had been diagnosed 28 years ago. In 1977 she had been admitted with serious uraemia after an episode of high fever. Her findings at that time were CN 35.34 mmol/l (99 mg/dl), serum creatinine 742.5 μmol/l (8.4 mg). After fluid and urosemide administration the quantity of urine rose to 3.5 to 4 litres daily. The Giordano–Giovanetti diet containing 25 g of protein was prescribed. In three weeks her condition improved considerably and she was discharged almost free of complaints. Since then she is under our nephrological care, and had not experienced pyuria or haematuria. Taking 40 mg furosemide six times daily her urine excretion is around 3 litres. The patient is able to look after her domestic duties and has travelled abroad. The results of the last check-up were CN 27.2 mmol/l (79 mg), serum creatinine 795.6 μmol/l (9.0 mg/dl) urine density 1010, opalescent urine with 1–1 white blood cell and 1–1 erythrocyte in the sediment.

In the case of J.K., a 59 year-old female patient polycystic kidney disease had been diagnosed at 54 years of age. She had had azotaemia and had been in hospital several time. In November 1975 she had been taken over from another hospital because of uraemia. At admission she was oedematous all over the body, very weak and hardly able to move. Because of nausea and vomiting she was unable to eat or drink. Her more important laboratory findings were, CN 66.76 mmol/l (187 mg/dl), serum creatinine 972.4 μmol/l (11 mg%), serum Na 125 mEq/l, serum K 4.0 mEq/l, urine density 1012, sediment: 60–80 WBC, 100–120 erythrocytes per field of vision. The acidosis normalized after the infusion of 600 ml of 4.2% sodium hydrocarbonate solution. Infusions, 1000 mg of *Foruntral* Larix and the Giordano—Giovanetti diet containing 25 g of protein caused an improvement of the findings: CN was 28.9 mmol/l (81 mg/dl), serum creatinine 636.48 μmol/l (7.2 mg/dl), the oedema disappeared. After five weeks the condition had greatly improved, and the patient was discharged. She reported for control monthly. Her urine quantity was 3 to 3.5 litres daily none the less the CN and serum creatinine

values began to increase slowly. The pyuria was treated first with ampicillin and co-trimoxazole which caused a temporary disappearance of leucocyturia and bacteriuria.

In June, 1978, the patient was again admitted with fever and sepsis, CN 35.56 mmol/l (94 mg/dl), serum creatinine 919.36 μmol (10.4 mg/dl). She was given the same diet and fluid therapy as before, supplemented now with aimed antibiotics, but the septic state could no longer be influenced and she died two weeks later.

So far, 24 polycystic patients with reduced renal function have been under our care, out of whom ten were treated by haemodialysis. Six of the patients in the non-dialysed group had died. There are currently eight patients who come regularly for check-up. Among the polycystic patients who, because of their advanced age, were not haemodialysed, considerable azotaemia, with around 50 mmol/l (140 mg/dl) CN values, without uraemic complaints have been quite frequent.

2. In contrast to chronic renal failure of other aetiologies, the serum creatinine of polycystic patients rose despite a two to three litre daily diuresis quite often to 880 μmol/l (10 mg/dl). In such cases haemodialysis should always be considered, and especially patients in the younger age groups should be admitted into the haemodialysis programme. Polycystic patients tolerate haemodialysis well, though their age was higher than that of patients subjected to haemodialysis for some other kidney disease. The majority of the latter patients was dialysed three times weekly, while for polycystic patients dialysis twice weekly was found sufficient for a fairly long period of time. So far, 21 of our patients received regular haemodialytic treatment, and currently eight are being treated in this way. It has to be stressed that with adequate nephrologic care and chronic haemodialysis the survival of polycystic patients can considerably be prolonged.

3. Suppuration of the cysts represents the greatest danger. With a single exception, the cause of death was sepsis and its consequences. If the septic state does not improve, the purulent kidney has to be removed. In certain cases contralateral nephrectomy may also be justified. It is a much discussed problem whether before performing kidney transplantation the nephrectomy should be uni- or bilateral. In Hungary now, kidney transplantation is performed only after bilateral nephrectomy. Because of the few available cadaver kidneys, transplantation is only eventual and its time uncertain. We performed bilateral nephrectomy in six patients out of whom *two* were subjected to transplantation.

4. Up to recent times, in the treatment of patients suffering from polycystic kidney disease the principle of "non-intervention" had been accepted, provided there were no complications (renal calculi, suppuration of the cysts leading to sepsis, intense haemorrhage). Thus, a surgical intervention was done

only when the patient had developed sepsis due to suppuration of the cysts. In such cases, in the course of exploration, the cysts full of pus were opened and their walls resected. Lately, operations aiming at decompression by opening of the central cysts causing the deformity of the pelvic system are being done and it is suggested to open up the peripheral cysts, too. Hence, in these cases no infected or purulent cysts remain. An improvement of the function of the still intact parts of the parenchyma and a relief of the pains, mainly of low back pains, are expected from this type of operation.

Two sisters of the 38 year-old female patient D.K., had suffered from polycystic kidney disease and their father had died of uraemia. The polycystic kidneys of Mrs D.K. had been detected two years after the appearance of her complaints. Urography revealed the deformity of the right pelvis and decompressive surgery was done. Urography carried out in the course of check-up showed the kidney to have decreased in size and a substantial decrease in pelvic stasis (Figs 5*A* and *B*). Since the operation the patient has no complaints.

Discussion

Polycystic degeneration of the kidneys is characterized by cystic dilation of the renal tubules. Beltran [3], Pintér and Csűrös [21] and Szakáll and Zarándy [30] have pointed out that the condition must be sharply distinguished from the unilateral polycystic kidney which is never inherited. When there is a number of cysts in one of the kidneys, the condition is called a multicystic kidney, and when the process affects only part of the kidney we speak of multilocular cystic disease. Balogh [2] has reported on the simultaneous occurrence of polycystic kidney and a giant solitary cyst.

Herxheimer [8] was the first to suppose that the pathogenic factor was a hindrance of the fusion of the tubular apparatus developing from nephrogenic tissue with the canalicular system growing from the direction of the ureteric bud. According to Hildebrand [9], the condition develops when the fusion of the glomeruli and the collecting tubules is disturbed. McKenna and Kampmeier [13] attributed a certain role to the atrophy of embryonic tubules while Hepler [7] considered the obstruction a secondary factor, as in his opinion the cysts would develop as a result of vascular damage. Osathanondh and Potter [15–19] who have studied the problem the most thoroughly, distinguished four types of development of the polycystic kidney. In the case of type 1, polycystic kidney develops in infancy due to hyperplasia of the interstitial portion of the collecting tubules; this condition leads to early death. Polycystic degeneration of other organs, mainly of the liver and lungs also have a high incidence. In type 2, inhibition of ampullary activity leads to bilateral

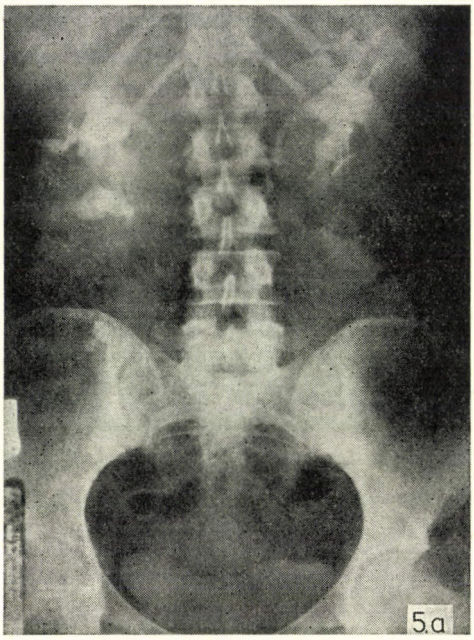

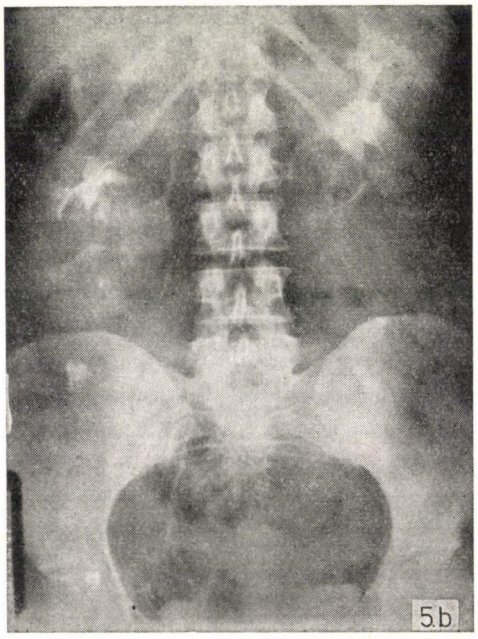

FIG. 5. Urographic picture of polycystic kidney. Compared to the situation before the operation (*A*) decompression greatly reduced the deformity of the pelvic system on the right side (*B*)

polycystic kidney. In clinical practice type 3 is the most often encountered: it is caused by multiple abnormalities of development. This type is familial, of autosomal dominant heredity. Our cases belonged into this group. The fourth form is the consequence of a mild injury of the ampoule caused by urethral obstruction. On the basis of this classification Rutkai and Czeizel [23] stressed the importance of prenatal examination.

Radiological methods play a decisive role in detection of the polycystic kidney. As the process progresses so does the size of the kidneys increase. Lalli and Poirier [11] drew prognostic conclusions by comparing the periodically repeated urographs with the growth of the kidneys. Another diagnostic method is carotid angiography in patients who are suitable for this test. The future way of life of the patient, and his suitability for chronic haemodiaysis or kidney transplantation can be influenced decisively if his cerebral lascular aneurysm is detected in good time, preferably by computer tomography. More recently Pytel et al. [22] have demonstrated a specific dermatographic pattern of polycystic kidneys.

In the majority of cases we apply conservative therapy. Nephrologic care started in good time and carried out with sufficient competence can considerably prolonged the life of the patient. In this way the number of patients who later might require haemodialysis can be reduced. This is an important point as the capacity of haemodialysis stations is rather limited

There is no generally accepted opinion with respect to uni- or bilateral nephrectomy prior to transplantation. Immune suppression after transplantation incurs the risk of infection, so that the remaining polycystic kidney can be the source of sepsis [25]. None the less, many surgeons perform transplantation without previous nephrectomy when there has been no history of haematuria, pyuria or significant bacteriuria [10, 12, 23, 25, 32].

Bilateral nephrectomy is contraindicated when — beside adequate diuresis hypervolaemia is rare which partly in itself and partly through hypertension puts a load on the circulation;

— owing to the erythropoietin produced by the kidneys the patienst require fewer blood transfusions;

— removal of the polycystic kidney(s) would represent a great operational load;

— because of the small number of available cadaver kidneys transplantation is only eventual and its time uncertain.

For these reasons, nephrectomy of polycystic kidney patients with reduced renal function is justified only when they become oliguric, when their hypertension cannot be influenced by drugs and haemodialysis, or when, because of the suppuration of cysts, a septic state develops.

References

1. Babics A: Megtévesztő kóresetek intraoperatív diagnózisa az urológiában (Intraoperative diagnosis of misleading pathologic cases in urology). Akadémiai Kiadó, Budapest 1977
2. Balogh F: Case of a tumoroid polycystic kidney with huge solitary cyst. Acta Urol Belg 4: 163, 1947
3. Beltran JC: Congenital unilateral multicystic kidney in infancy. J Ur 81: 602, 1959
4. Cornell SH: Angiography in polycystic disease of the kidney. J Ur 103: 24, 1970
5. Halpern M, Dalrymple G, Young J: The nephrogram in polycystic disease: An important radiographic scan. J Ur 103: 21, 1970
6. Hatfield PM, Pfister RC: Adult polycystic disease (Potter type 3). Am Med Ass J 222:1527, 1972
7. Hepler AB: Interference with intraparenchymal blood supply in pathogenesis of renal cyst. Surg Gynecol Obstet 53: 688, 1930
8. Herxheimer G: Über Cystenbildung der Niere und abführenden Harnwege. Virchows Arch [Pathol Anat] 185: 52, 1906
9. Hildebrand J: Beitrag zur pathologischen Anatomie der Nierengeschwulste. Arch Klin Chir 48: 343, 1894
10. Kinnaert P, Vereerstraeten P, Toussaint C, Van Geerstruyden J: Polykystose rénale traité par hémodialyse itérative et transplantation rénale. Nouv Presse Med 5: 2299, 1976
11. Lalli AF, Poirier VC: Urographic analysis of the development of polycystic kidney disease. Amer J Roentgenol 119: 705, 1973
12. Makó J, Váry L, Balogh F: Beszűkült vesefunkciójú betegek nephrológiai gondozása (Nephrologic care of patients with limited renal function). Urol Nephrol Szle 3: 153, 1976
13. McKenna CM, Kampmeier OF: Consideration of development of polycystic kidney. Trans Am Assoc Genitourin Surg 26: 377, 1933
14. Mészáros I: A polycystás vese és az intracraniális aneurysma összefüggése (Correlation between polycystic kidney and intracranial aneurysm). Orv Hetil 122: 504, 1981
15. Osathanondh V, Potter EL: Pathogenesis of polycystic kidneys. Historical survey. Arch Pathol Lab Med 77: 459, 1964
16. Osathanondh V, Potter EL: Pathogenesis of polycystic kidneys. Type 1 due to hyperplasia of interstitial portions of collecting tubules. Arch Pathol Lab Med 77: 466, 1964
17. Osathanondh V, Potter EL: Pathogenesis of polycystic kidneys. Type 2 due to inhibition of ampullary activity. Arch Pathol Lab Med 77: 474, 1964
18. Osathanondh V, Potter EL: Pathogenesis of polycystic kidneys. Type 3 due to multiple abnormalities of development. Arch Pathol Lab Med 77: 485, 1964
19. Osathanondh V, Potter EL: Pathogenesis of polycystic kidneys. Type 4 due to uretheral obstruction. Arch Pathol Lab Med 77: 502, 1964b
20. Osathanondh V, Potter EL: Pathogenesis of polycystic kidneys. Survey of results of microdissection. Arch Pathol Lab Med 77: 510, 1964
21. Pintér J, Csűrös E: Adatok az egyoldali sokcystás vese differenciál diagnosztikájához (Data contributing to the differential diagnostics of the unilateral multicystic kidney). Magy Seb 14:119, 1961
22. Pytel JuA, Rozovsky IS, Jankova MF, Nemkova EYA, Trepakov EA: Rezultati kliniko-geneaologicheskikh i dermatoglificheskikh isledovanii i bolnikh politistosom pochek. Sov Med 10:15, 1976
23. Rényi-Vámos F, Rigó J, Csata S, Tóth M: Fehérjében szegény, megfelelő essentiális aminosavtartalmú étrend jelentősége a chronikus uraemia kezelésében (Importance of protein-poor diet with adequate essential amino acid in the treatment of chronic uraemia). Orvosképzés 44: 256, 1969
24. Rutkai K, Czeizel E: A születést követően felismert polycystás vesék kóreredete (Pathogenesis of postnatally detected polycystic kidneys). Orv Hetil 122:195 1981
25. Salvatierra O, Wolfson M, Cochrum K, Amend W, Belzer FO: End-stage polycystic kidney disease: Management by renal transplantation and selective use or preliminary nephrectomy. J Ur 115: 5, 1976
26. Segal AJ, Spataro RF, Barbaric ZL: Adult polycystic kidney disease: A review of 100 cases J Ur 118: 711, 1977

27. Simon HB, Thompson GJ: Congenital renal polycystic disease. A clinical and therapeutic study of 366 cases. J Am Med Assoc 159: 657, 1975
28. Stöber U: Die polyzistische Nierendegeneration. Z Urol Nephrol 68: 809, 1975
29. Szabó V, Sóbel M, Légrádi J, Balogh F: Ultrahangdiagnosztika egyes urológiai megbetegedések kórismézésében (Ultrasonic diagnostics in the diagnosis of some urological diseases). Urol Nephrol Szle 6: 38, 1979
30. Szakáll Sz, Zarándy B: A vese egyoldalú multilocularis cystás betegségéről (Unilateral multilocular cystic disease of the kidney). Urol Nephrol Szle 5: 93, 1978
31. Vela Navarette R, Zuluaga A, Usera G, Robledo AG: Zur Diagnose der polyzystischen Nierenerkrankung. Münch Med Wochenschr 113:1736, 1971
32. Wolfson M, Amend W, Cochrum K, Belzer FO, Salvatierra O: Transplantation in end-stage polycystic kidney disease. Dial Transplant 5 (6th issue): 66, 1976

Moderne Anschauung der Diagnostik und Therapie der polyzystischen Nierenkrankheit der Erwachsenen

(Analyse von 314 klinischen Fällen)

Á. Csontai, Gy. Nádas, J. Makó, J. Pánovics, und F. Balogh

Nach dem Überblick der bei der polyzystischen Nierenkrankheit anwendbaren diagnostischen Methoden, werden anhand der Analyse der klinischen Daten der an der Klinik im Verlauf von 30 Jahren (1950—1979) behandelten 314, an polyzystischer Nierenkrankheit leidenden, erwachsenen Patienten die Fragen der konservativen Behandlung, der nephrologischen Betreuung, der Hämodialyse und der speziellen Verhältnisse der Transplantation erläutert. Anschließend wird auf die Möglichkeiten der Ausbreitung des chirurgischen Eingriffs in komplikationsfreien Fällen hingewiesen.

Современный взгляд на диагностику и терапию поликистозного заболевания почек у взрослых

(Клинический разбор 314 наблюдений)

А. ЧОНТАИ, ДЬ. НАДАШ, Й. МАКО, Й, ПАНОВИЧ и Ф. БАЛОГ

Авторы дают обзор методов, применяемых в диагностике поликистозного заболевания почек. На основе анализа клинических данных, собранных за 30-летний период (1950–1979) у 314 больных с поликистозной болезнью почек, они указывают на важность консервативной терапии и нефрологического патронирования. Обсуждают вопрос о месте гемодиализа в терапии и о специальных условиях трансплантации. Обращают внимание на расширение показаний к хирургическому вмешательству в случаях, не сопровождающихся осложнениями.

Dr. Ágoston Csontai
Dr. György Nádas
Dr. János Makó
Dr. József Pánovics
Dr. Ferenc Balogh

Department of Urology,
Semmelweis University Medical School,
Budapest, Üllői út 78/b,
H-1082

Acta Chirurgica Academiae Scientiarum Hungaricae, Tomus 23 (4), pp. 229–234 (1982)

Urologische Komplikationen bei Beckenfrakturen

E. Korányi,[1] I. Zágh,[2] S. Kottász[1] und E. Kendelényi[2]

Urologische Abteilung[1] und Unfallchirurgische Abteilung[2] des Krankenhauses Újpest, Budapest

(Eingegangen am 18. Januar 1982)

Bei 37 von 258 Patienten mit Beckenfraktur lag auch eine schwere urologische Komplikation vor. Bei der Mehrzahl der polytraumatisierten Patienten besteht die Gefahr einer urologischen Verletzung. Nach Erläuterung der die verschiedenen Frakturtypen begleitenden, charackteristischen urologischen Komplikationen wird darauf hingewiesen, daß im Interesse der Erfassung bzw. Ausschließung einer, akute Versorgung beanspruchenden urologischen Verletzung bzw. der Festlegung der Therapie — Operation oder konservative Behandlung — die dringende Durchführung der urologischen Untersuchung von großer Wichtigkeit ist. Die definitive Versorgung und die bestmöglichsten Heilergebnisse können nur von einem gut kooperierenden, aus Traumatologen, Urologen und Radiologen bestehenden Team erwartet werden.

Statistische und auch klinische Daten zeigen, daß sich die Zahl der Haushalts-, Betriebs-, Verkehrs- und Sportunfälle von Jahr zu Jahr erhöht [1, 3, 5, 6, 7]. Eine ähnliche ansteigende Tendenz weist auch die Zahl der polytraumatisierten Fälle auf. Die urologischen Verletzungen, unter denen die Blasen- und Urethraverletzungen meistens als Folgen von Beckenfrakturen entstehen, werden in den unfallchirurgischen Abteilungen beobachtet bzw. diagnostiziert. Was die Versorgung der Verletzungen anbelangt, verfügen in erster Linie jene urologische Abteilungen über reiche Erfahrungen, die zu auch traumatologische Abteilungen besitzenden Krankenhäusern gehören. In vorliegender Arbeit befassen wir uns mit der Häufigkeit, Diagnostizierung und Therapie der urogenitalen Komplikationen der Beckenfrakturen.

Zwischen 1974 und 1979 wurden auf unsere Unfallchirurgische Abteilung 6872 Verletzte aufgenommen; in 258 dieser Fälle handelte es sich um eine Beckenfraktur, die zu 2/3 der Fälle eine Teilerscheinung der Polytraumatisation und in 1/3 ein Monotrauma war.

Die den Frakturtypen entsprechende Verteilung zeigt folgendes:

Beckenkammfraktur	72 Fälle	28%
einfache Beckenringfraktur	90 Fälle	35%
zweifache Beckenringfraktur	41 Fälle	15%
Pfannenfraktur	55 Fälle	22%

Die Zahl der sich zu den verschiedenen Frakturtypen gesellenden urologischen Komplikationen darf als charakteristisch bezeichnet werden. Blasen-

und Urethraverletzungen bzw. Funktionsstörungen werden am häufigsten durch instabile Ringfrakturen verursacht. Etwas geringer, aber noch immer bedeutend ist die Zahl der urologischen Komplikationen der Azetabulumfrakturen, während durch stabile Ring- oder Kammfrakturen im Bereich der Harnwege nur selten eine Korrektion beanspruchende Veränderung herbeigeführt wird. Da die polytraumatisierten, auch eine Beckenfraktur erlittenen Patienten potentiell auch für urologische Verletzte gelten, wurde in diesen Fällen ausnahmslos eine urologische Untersuchung vorgenommen. Insofern sich anhand der physikalischen Untersuchung sowie der quantitativen und qualitativen Harnuntersuchung der Verdacht einer Verletzung des urogenitalen Traktes erhob, wurden solange weitere diagnostische Mittel herangezogen, bis es schließlich gelang, den Verdacht zu bestätigen oder widerlegen. Nebst der klassischen Füllungsprobe boten uns zur Festlegung der genauen Diagnose bzw. zur Aufstellung des therapeutischen Planes die Ausscheidungsurographie, die Zystographie und nötigenfalls die retrograde Urographie eine Hilfe. Die Durchführung und Auswertung der diagnostischen Routineverfahren sind bei diesen polytraumatisierten, sich manchmal in Schock befindlichen Patienten viel schwieriger als bei nicht verletzten Kranken. Außerdem beansprucht auch die Indizierung der Operation der nachgewiesenen Blasen- oder Urethraverletzung größere Umsicht und ernstere Überlegungen, zumal der urologische Eingriff in die vom Traumatologen aufgestellte Dringlichkeits-Reihenfolge der bei den Polytraumatisierten nötigen sonstigen chirurgischen Operationen eingefügt werden muß.

Schwerere urogenitale Komplikationen kamen bei 37 unserer 258 eine Beckenfraktur erlittenen Patienten (14,3 %) vor. Die frühen und die nach der Frakturheilung aufgetretenen späten funktionellen Störungen, die banalen Harnwegsentzündungen sowie die keine Behandlung beanspruchenden, vorübergehenden Hämaturien, in deren Hintergrund keine Veränderung nachzuweisen war, wurden in unser Material nicht aufgenommen.

Verteilung der urogenitalen Komplikationen:

Blasenverletzung (komplett)	4
Blasenverletzung (inkomplett)	5
Urethraruptur	4
Urethraquetschung	3
Hochgradige Hämaturie	17
Miktionsunfähigkeit verursachendes Hämatom	4

3 der 4 Patienten mit kompletter Blasenverletzung wurden unmittelbar nach der Diagnostizierung operiert: Exzision der gequetschten, zerstörten Abschnitte, Blasenverschluß über dem Katheter (Abb. 1). In einem Fall, in dem wegen des schlechten Allgemeinzustandes keine Operation vorgenommen wurde, erwies sich — ähnlich wie im von Guba und Bálint [4] veröffentlichten

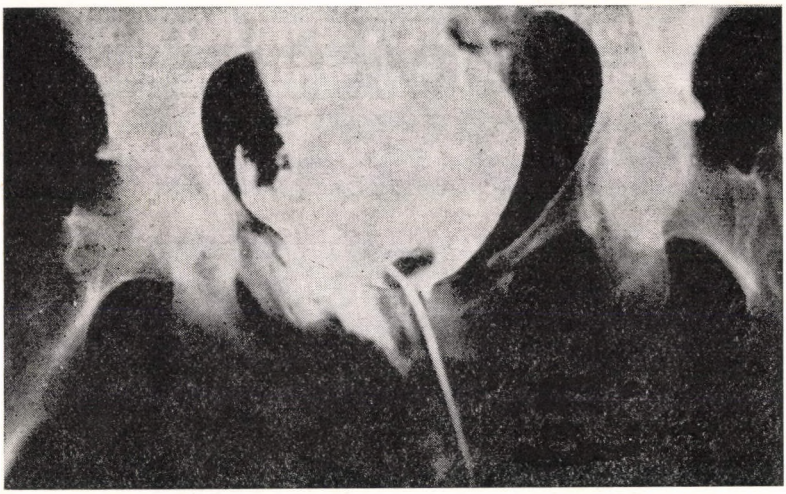

ABB. 1. Zystogramm einer sich zur Beckenfraktur gesellenden Blasenruptur

Fall — die Anwendung eines Dauerkatheters als erfolgreich, die Verletzung heilte. Inkomplette Blasenverletzungen lagen in 5 Fällen vor; in 2 Fällen, in denen der zystoskopische Befund auf eine Ruptur hinwies, konnte nach 1-wöchigem Dauerkatheter Heilung erzielt werden, während die bei den 3 Polytraumatisierten anläßlich der Laparotomie erkannte Blasenverletzung vernäht wurde. In 2 der 4 Fälle mit Urethraruptur lag die Verletzung im Bereich der Pars membranacea, in einem Fall in der Umgebung der Pars prostatica; im 4. Fall wurde die Harnröhre durch das Bruchende vom Blasenfundus abgeschnitten (Abb. 2). In allen vier Fällen kam es zu einer akuten chirurgischen

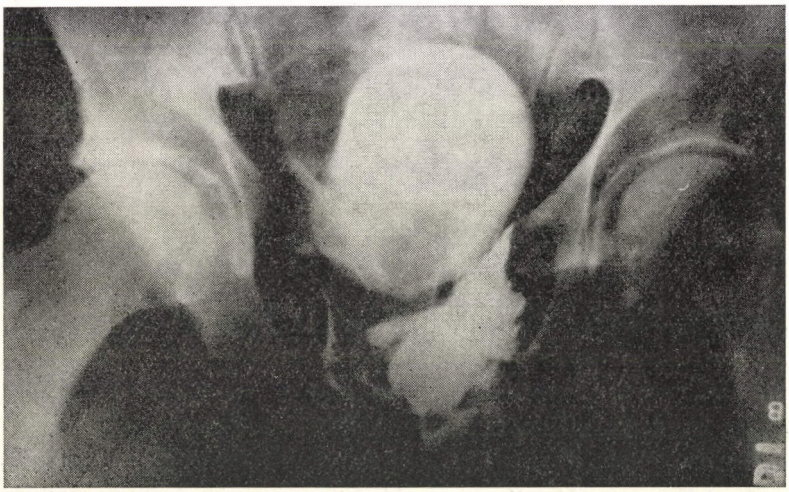

ABB. 2. Retrogrades Urethrogramm einer durch Beckenknochenfraktur bedingten Urethraverletzung

Freilegung und zur Vereinigung der abgerissenen Harnröhrenden mit Situationsnähten über dem Katheter. Im Interesse der sicheren Harnableitung wurde bei den wegen einer Blasen- oder Urethraverletzung operierten Patienten auch eine suprapubische Ableitung angewandt. In den Fällen, in denen es sich um inkomplette Miktionsunfähigkeit bzw. Urethrorrhagie verursachende Harnröhrenverletzungen handelte, konnte mittels konservativer Behandlung aus-

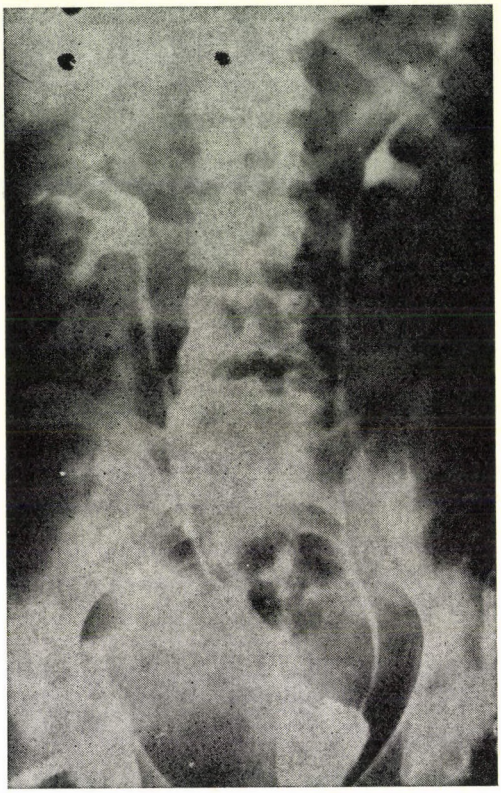

ABB. 3. In Begleitung einer Knochenfraktur entstandenes, Miktionsunfähigkeit vernrsachendes Hämatom im kleinen Becken

nahmslos Heilung erzielt werden. In 17 Fällen gesellte sich zur Beckenfraktur eine massive, oft Gerinnsel enthaltende Blutung, eine chirurgische Freilegung beanspruchende Kontinuitätsunterbrechung ließ sich im Laufe der Untersuchungen jedoch nicht nachweisen. Dank der konservativen Behandlung (Katheter) hörte die Hämaturie bei sämtlichen Patienten auf. Den Knochenbrüchen zufolge entwickelt sich im reich vaskularisierten kelinen Becken häufig ein ausgedehntes, die benachbarten Organe dislozierendes Hämatom (Abb. 3). In 4 Fälle konnte die durch die komprimierende bzw. deformierende Wirkung des Koagulums herbeigeführte totale Miktionsunfähigkeit durch

Einführung eines Katheters und Drainage des Hämatoms gelöst werden. In 10 der 37 Fällen erwies sich wegen einer sich zur Beckenfraktur gesellten urologischen Komplikation eine akute Operation erforderlich: sämtliche Patienten heilten. Durch urologische Komplikationen bedingte Todesfälle kamen nicht vor.

In der Gestaltung der Ergebnisse spielen viele Faktoren eine Rolle. Die grundlegende Bedingung der erfolgreichen Behandlung ist die unverzügliche und tadellose Teamarbeit des Traumatologen, Urologen, Radiologen und Anästhesiologen. Nachdem die Befunde der nötigen und ausreichenden Untersuchungen zur Verfügung stehen, muß die Frage, ob eine Operation oder konservative Behandlung indiziert ist, dringend entschieden werden. Nebst der Harnableitung ist die Anwendung einer, der Harninfiltration vorbeugenden, die Hämatome entleerenden, reichlichen Drainage von großer Bedeutung. Eine nicht minder wichtige Rolle spielen ferner Transfusionen, Infusionen, die Verabreichung von Antibiotika sowie die fortlaufende Beobachtung und die intensive Pflege der Patienten.

Literatur

1. Bauer J, Drahovsky V, Vanicky D, Zelenák P: Urologic complications in pelvic fractures. Hefte Unfallheilkunde 124: 305, 1975
2. Buday P, Ruszinkó B, Nagy E: Medencetörés okozta húgyhólyag sérülések ellátási problémái polytraumatizált betegeknél (Versorgungsprobleme der beckenfrakturbedingten Blaseverletzungen). V. Ungarischer Urologenkongreß, Debrecen 1979
3. Gibson GR: Urological management and complications of fractured pelvis and ruptured urethra. J Ur 11: 353, 1974
4. Guba T, Bálint J: Medencetörés okozta nyílt húgyhólyag sérülés műtét nélküli megoldása (Lösung der Beckenfraktur bedingten freien Blasenverletzungen ohne Operation). Urol Nephrol Szle 3:196, 1976
5. Hubner G, Scholz R: Diagnosis and therapy of bladder and urethral injuries in pelvic fractures. Hefte Unfallkeilkunde 124: 301, 1975
6. Szomor L, Rácz S, Erhardt G: Tapasztalatok a medencetöréssel szövődött hólyag-húgycsősérülések ellátásában öt év anyaga alapján (Erfahrungen bei der Versorgung der mit Beckenfraktur komplizierten Blasen-Urethraverletzungen aufgrund des 5jährigen Materials). V. Ungarischer Urologenkongreß, Debrecen 1979
7. Varga B, Csonka L, Vadász K: Medencetörésekhez társult urológiai szövődméneky ellátása (Versorgung der sich zur Beckenfraktur gesellenden urol ogischen Kom plikationen). V. Ungarischer Urologenkongreß, Debrecen 1979

Urological Complications of Pelvic Fractures

E. Korányi, I. Zágh, S. Kottász and E. Kendelényi

In 37 of the 258 patients with pelvic fractures rather severe urological complications were diagnosed. It seems that the majority of polytraumatized patients can be considered as potential urologic cases. The characteristic urological complications associated with the various types of fractures are described. The importance of urgent urological examination is stressed in order to detect urological injuries requiring acute care and to determine the need for operation or for conservative treatment. Co-operation between the traumatologist, the urologist and the radiologist will ensure the definitive care of the polytraumatized patient and the best chances for recovery.

Урологические осложнения тазовых переломов

Э. КОРАНИ, И. ЗАГ, Ш. КОТТАС и Э. КЕНДЕЛЕНИ

У 37 из 258 больных с переломом таза авторы нашли тяжелые урологические осложнения. Они считают, что большинство больных с множественными травмами могут считаться также потенциально урологически травмированными. Знакомят с урологическими осложнениями, присоединяющимися к разным типам переломов, имеющими характерную картину. Подчеркивают важность срочного урологического исследования для выявления больных с урологическими травмами, которые нуждаются в неотложной помощи, а также для определения в каждом случае необходимости оперативного или консервативного лечения. Хорошее взаимное сотрудничество травматолога, радиолога и уролога обеспечивает соответствующее обслуживание политравматических больных и возможно лучшие результаты лечения.

Dr. Endre KORÁNYI
Dr. Sándor KOTTÁSZ
Urologische Abteilung des Krankenhauses Újpest, Budapest, Nyár u. 99, H-1047

Dr. István ZÁGH
Dr. Ernő KENDELÉNYI
Unfallschirurgische Abteilung des Krankenhauses Újpest, Budapest, Nyár u. 99, H-1047

Acta Chirurgica Academiae Scientiarum Hungaricae, Tomus 23 (4), pp. 235–241 (1982)

Treatment of Acute Suppurative Nephritis

S. Kottász and F. Szijjártó

Department of Urology, Outpatient Surgery, Municipal Hospital of Újpest, Budapest

(Received December 3, 1981)

The diagnostic problems and treatment of acute suppurative nephritis are discussed on the basis of 146 patients. The biological properties of the pathogens isolated from urine and their manifestation with clinical symptoms are discussed. The role of incorrectly prescribed antibiotics in changing the characteristic symptoms and thus making diagnosis difficult is stressed. It appears from the material that in 20% of the operated patients all x-ray and laboratory tests gave negative results, despite the fact that in the course of operation abscesses were detected under the renal capsule. In 60% of the cases x-rays supplied reliable information for the indication of surgical intervention. The history of fever and shaking fits and the progression revealed by careful observation of the patients are considered the most important information needed for deciding for surgery.

Suppurative nephritis is a common condition. Inflammatory involvment of the renal pelvis and parenchyma is usually simultaneous and the two processes cannot sharply be distinguished. In this paper we shall deal with the type of nephritis which involves the renal parenchyma. In our material the types of suppurative nephritis shown in Table I occurred.

The fact that the disease appears in so many forms shows its importance and also the difficulties. This is confirmed by Babics [1] who in his book written on the basis of his fifty-year experience devotes a considerable part to this subject. We shall repeatedly quote this work and refer to Szendrői's earlier findings [4] in order to be able to make definite statements and express our opinion despite our modest experience. To support our statements we have

Table I

Distribution of cases according to type of nephritis

Type	No. of cases
Pyelonephritic abscess	62
Chronic pyelonephritis with exacerbation	55
Renal carbuncle	24
Perinephritic abscess	1
Purulent cyst of the kidney	4

TABLE II

Comparison of data from two departments

	Újpest Hospital	University Department of Urology
No. of cases	146	89
Previous antibiotic therapy	61	75
Septic state	97	59
Uraemic complication	32	26
Death	16	29

processed our material of the six years between 1975 and 1980 comparing the results with the data of the Department of Urology, Semmelweis University Medical School, Budapest, in the five-year period between 1968 and 1972 [1] (Table II).

The differences appearing in this comparison, particularly with respect to mortality, will be dealt with later. Suppurative nephritis can be caused by various types of microbes. In the order of their incidence we found *E. coli* in 51 %, *Proteus* in 26 %, *Klebsiella* in 10 %, *Staphylococcus* in 6 %, *Streptococcus* in 4 %, and *Pseudomonas aeruginosa* in 3 %. These bacteria have different properties which manifest with symptoms, so that from the biological properties of the pathogens a certain information on the changes of the renal parenchyma can be gained before the operation. The differences in the various disorders caused by the different types of pathogen can be detected by the physical examination. *E. coli* which has the highest incidence is a bacterium living in the healthy intestinal flora, but may cause serious and protracted infection of the urinary organs. Two strains of *Proteus*, namely *Proteus mirabilis* (indole-negative) and *Proteus vulgaris* (indole-positive) were detected of which the second has properties leading to an extremely rapid irreperable process in the interstice. *Klebsiella* is a facultative anaerobic bacterium which forms coherent colonies. Owing to this, it causes swelling of the renal parenchyma and, due to the enlarged kidney and the tension of the renal capsule, an intense pain will be experienced on palpation of the kidney. Staphylococci produce a toxin causing severe leucocytosis and rapid necrosis. Staphylococci elicit circumscribed suppuration, thus renal abscesses are, as a rule, caused by *Staphylococcus aureus* strains. Among the Staphylococci the beta-haemolysing strains are of particular importance because of their fibrinolytic effect and biological activity which incur the danger of sepsis *Pseudomonas aeruginosa* strains are responsible for secondary infections in the urinary organs and wounds. They are highly resistant and easily transmitted pathogens (*Pyocyaneus* home infections). A greenish colour of the discharge indicates their presence. As

alcohol and boric acid have a bactericidal effect on them, the infected wound can be treated successfully by means of locally applied boric acid and adequately diluted Lugol's solution. Prevention of hospital infections is a difficult task, for usually the patients themselves are the reservoirs of the pathogens. Soiled bedlinen and towels, infected hands, stored fluids, catheters usually transmit the infections and their spreading should be prevented by strict hygienic measures. Inflammatory bacteria can reach the renal parenchyma and pelvis by ascending, haematogenic or lymphogenic routes or as a result of iatrogenic or traumatic injuries. Infected nephrolithic occlusions and infections ascending from the bladder have the highest incidence and are of great practical importance, just as haematogenic infections which often cause diagnostic difficulties. In our material suppurative nephritis was due to

nephrolithic occlusion and infection	in 51
ascending pyelonephritis	in 56
haematogenic infection	in 20 and
some unclarified cause	in 19

cases. In cases of renal occlusion and ascending infection the history may call attention to the underlying cause. The first complaints the quality of fever, the recurrence of shaking chills, a deterioration of the general condition with lack of appetite, depression, tired facial expression, etc. are of significance. The problem is of particular importance to the general practitioner, since these patients are usually examined first by them or in medical or surgical outpatient clinics but rarely by urologists. Early diagnosis might save the diseased kidney and even the life of the patient, while delay can be fatal not only for the affected kidney but for the patient himself. We therefore consider to perform a comparative analysis of some clinical data and in the interest of conclusions we shall refer to Babics's opinion.

At the time when the complaints appear, in the first phase of acute pyelonephritis, it is usually not the urologist who examines the patient. We must emphasize the diagnostic difficulties and the dangers of injudiciously administered antibiotics [1, 4]. When there is a free passage of urine from the pelvis, pyelonephritis might be cured by sulphonamides or aimed antibiotics. When spontaneous pain and a sensitivity in the kidney region, high fever with repeated shaking chills appear, these are due to an apostematous pyelonephritis, renal carbuncle, suppuration of the renal parenchyma combined with renal occlusion. These conditions cannot be treated without a surgical intervention. At the beginning of the disease the symptoms are not always unambiguous. The fever is not always typical and the shaking chills indicating bacteraemia appear in most cases only later. It is incorrect to prescribe antibiotics before the typical symptoms had appeared, the necessary tests had been performed and the correct diagnosis had been reached. It nevertheless happens

that, in view of the fever, the doctor prescribes some antibiotic before diagnosing the condition and, consequently, the characteristic symptoms of acute pyelonephritis will either be missing or altered. They may alter the duration of the acute phase and blur the symptoms of progression without a change having occurred in the severity of the inflammatory process in the kidney.

The clinical picture is thus blurred and the symptoms are atypical. All this greatly encumbers the diagnostic possibilities. Quite often gastroenterological symptoms and a septic state dominate the case without urological complaints, with unrecognised suppurative nephritis in the background. Patients first treated at home or in some other department pose serious problems to the departments of urology. After the automatic pplication of antibiotics, it is difficult to decide upon the operation which will determine the fate of the patient.

Laboratory findings, too, can be misleading. Depending upon the type of pathogen or upon injudicious treatment, with negative urine tests isolated or clearly circumscribed disintegrating abscesses deep in the parenchyma may occur. Earlier an increase in leucocyte count was considered an important factor in formulating the indication for surgical intervention. The leucocyte count is, as a rule, high in *Klebsiella* or haematogenous *Staphylococcus* infections. In these cases after treatment of the detected lesion the focus of the disease must be found. In half of our patients subjected to operation, the leucocyte count was not high despite a severe parenchymatous suppuration or abscess. In 51 out of the 103 operated patients the leucocyte count was below 10 g/l, though in 21 cases nephrectomy had to be performed. In deciding for surgery changes in the patient's condition, in palpation and sensitivity in the region of the kidney are more important and less misleading aspects. The importance of shaking chills as a truly important factor in making this decision cannot be stressed enough.

X-rays are an indispensable diagnostic tool when nephritis is associated with nephrolithic occlusion. On native pictures beside the shadow of the psoas great attention has to be paid to the countours of the kidney. In cases of passage disorders (calculi or other occlusions, etc.), but also in other cases, urography is indispensable [3]. The view, according to which no intravenous urography should be performed in the case of high fever, is erroneous. Just on the contrary, when pains and sensitivity in the region of the kidney are accompanied by high fever, urography has to be performed as soon as possible, for once ascending pyelonephritis or suppurative nephrosis have been diagnosed, it can no longer be argued whether the patient whose condition has deteriorated during the time lost will or will not be able to bear the load of surgery since by then operation presents his only chance of survival.

Additional x-ray examinations, retrograde pyelography, tomography, etc., do not always give sufficient help in diagnosis. Renal carbuncles of haema-

TABLE III

Therapeutic results

	Cured	Died	Number of cases
Without operation (antibiotic therapy)	43	—	43
Organ conserving operation (decapsulation, nephrostomy)	40	6*	46
Nephrectomy	47	16	57
Total	130	16	146

* Three patients with solitary kidney.

togenic origin or apostematous pyelonephritis often produce entirely negative urograms. In such cases physical examination, continuous observation of the patient, a deterioration of the condition, despite treatment, provide the most important information for indicating the operation. Our therapeutic results are shown in Table III.

As to antibiotic treatment, the drug should be chosen on the basis of the antibiogram, but it is not always possible to wait for the bacteriological result. In 44% of our cases the urine was either sterile or unassessable, for example, impurities were present. In primary urinary infections when only few resistant pathogens are present, treatment is usually introduced by oxytetracycline, chloramphenicol or ampicillin.

In cases of exacerbation of an earlier pyelonephritis or one after an iatrogenic urological intervention, the majority of infections is caused by polyresistant pathogens, and effective treatment can only be expected from entamycin, colimycin or ampicillin [2]. Whenever aimed treatment is possible this, of course, should be preferred. In cases of renal carbuncles, perirenal abscesses, apostematous pyelonephritis and suppuration of the renal parenchyma, there is no sense in experimenting with antibiotics. The correct procedure is the earliest possible exposure of the kidney followed, depending upon the nature and progression of the process and the state of the kidney, by nephrectomy, nephrostomy or decapsulation combined with drainage and aimed antibiotic treatment.

In spite of surgery performed in due time, many of the patients are lost. In this intercurrent diseases, first of all diabetes and cardiorespiratory disturbances of advanced age play important roles.

The role of age in mortality is illustrated by the age distribution of our patients (Table IV).

Mortality could be reduced only by early diagnosis which in fact is not impossible. The operational mortality (11%) of the patients treated for acute

TABLE IV

Age distrtibution of patients

Total number of deaths	Aged below 40	Between 45 and 2652	Above 65
16	—	4	12

pyelonephritis was much higher than the total operational mortality rate (2.4 %) during the same period of time. If, however, we compare our data with those of a similar group of patients treated at the University Department of Urology (32.5 % mortality) ours is only one-third of the latter. What could explain this significant difference? The data of the University Department refer to a seven-year earlier period, but development in diagnostic methods is not a sufficient explanation. The possibilities of antibiotic treatment are, on the other hand, better and are continuously improving. More efficacious drugs against mixed infections and applicable in cases of impaired renal function are now available. We believe that the most important factor is the difference between the current and earlier unsatisfactory antibiotic treatment and hospitalization. In a well-organized and co-operating unit which is in constant touch with the outpatients, these will be referred earlier to the department of urology. In the possession of an early diagnosis we may treat and cure the patients more effectively and what is more important, to lose fewer of them.

Discussion

In order to improve the results of treatment of suppurative nephritis, it is of primary importance immediately to refer these patients to some department of urology. The correct diagnosis should be made the earliest possible, the necessary tests must be performed promptly. Where these tests require two or three days, early diagnosis will be impossible and, because of the loss of time, the operation may have serious consequences. Surgery should be done when with negative laboratory findings (urine, leucocyte count) and a normal urogram there is a marked sensitivity in the region of the kidneys accompanied by high fever and shaking chills. Progression of the condition is a far more important aspect for deciding for surgery than are the various findings. We have exposed the kidney in 20 cases on basis of the history (shaking chills in the patient's home or in some other department) and of increased sensitivity in the renal region when all laboratory and x-ray findings were negative. In 18 of these 20 kidneys there were abscesses below the capsule and in two cases, when the kidney was swollen and tense without an abscess, after decapsulation the patient's condition improved considerably and his temperature normalized.

References

1. Babics A: Megtévesztő kóresetek intraoperatív diagnózisa az urológiában (Intraoperative diagnosis of misleading cases in urology). Akadémiai Kiadó, Budapest 1977
2. Simon C, Stille W, Münnich D: Korszerű antibiotikus kezelés (Up-to-date antibiotic treatment). Medicina Könyvkiadó, Budapest 1974
3. Somogyi Zs, Fogel M: Röntgennel diagnosztizált vesecarbunculusok (X-ray diagnosed renal carbuncles). Orv Hetil 112: 2943, 1971
4. Szendrői Z: Az antibiotikumok haszna és veszélyei az acut gennyes vesegyulladás kezelésében (Usefulness and risks of antibiotics in the treatment of acute suppurative nephritis). Orv Hetil 112: 2880, 1971

Erfahrungen mit der Behandlung der akut eitrigen Nierenentzündung

S. Kottász und F. Szijjártó

Der Arbeit, in der die diagnostischen und therapeutischen Probleme der akut eitrigen Nierenentzündung eine Besprechung finden, liegen 146, aus dem 6jährigen Material der Abteilung stammende Fälle zugrunde. Die biologischen Eigenschaften der aus dem Harn gezüchteten Krankheitserregern und die durch dieselben verursachten, sich auch in klinischen Symptomen manifestierenden verschiedenen Störungen werden erläutert und die Rolle der zweckwidrigen antibiotischen Behandlung hervorgehoben, wodurch die typischen Symptome geändert und demzufolge die Diagnostizierung erschwert werden. In 20% der operierten Fälle fielen sämtliche Röntgen- und Laborbefunde negativ aus, obwohl intraoperativ in der Niere subkapsuläre Abszesse in Erscheinung traten. In 60% der Fälle bot die Röntgenuntersuchung einen Stützpunkt zur Aufstellung der Operationsindikation. Die Entscheidung, ob sich im gegebenen Fall eine chirurgische Lösung für erforderlich erweist, wird unter Berücksichtigung der Anamnese (Fieber, Schüttelfrost) und der sorgfältigen Beobachtung der Zustandsänderungen bzw. der sich darin widerspiegelnden Progression getroffen.

Наш опыт лечения острого гнойного воспаления почек

Ш. Коттас и Ф. Сийяото

Авторы обсуждают проблемы диагностики и лечения острого гнойного воспаления почек, основываясь на результатах обработки 6-летнего материала Урологического отделения Уйпешта, содержащего данные 146 наблюдений. Затрагивают вопрос о биологических свойствах возбудителей болезни, высеваемых из мочи, и о вызываемых ими разных нарушения, которые проявляются и в клинических симптомах. Подчеркивают роль нецелесоедрабной терапии антибиотиками в измении типичных симптомов, что затрудняет диагностику заболевания. Анализ материала показал, что у 20% больных, попавших на операцию, были отрицательные результаты всех рентгеноло гических и лабораторных исследований, несмотря на то, что на операции у них были обнаружены абсцессы под почечной капсулой. Для установления показаний к операции в 60% опорную точку дало рентгенологическое исследование. Главным в решении вопроса об операции авторы считают прогрессирование, установливаемое на основании анамнеза (лихорадка, озноб) и тщательного наблюдения за состоянием больного.

Dr. Sándor Kottász
Dr. Ferenc Szijjártó
Department of Urology, Outpatient Surgery, Municipal Hospital of Újpest, Budapest, Nyár u. 99, H-1047

Acta Chirurgica Academiae Scientiarum Hungaricae, Tomus 23 (4), pp. 243–247 (1982)

Tumours Arising in Skeletal Muscles and Tendons in Adults

L. JÓZSA, A. RÉFFY and A. RENNER

Department of Morphology, National Institute of Traumatology, Budapest

(Received January 14, 1982)

Nineteen cases of tumours arising in the skeletal muscles and 22 cases of tumours arising in tendons seen over 15 years (1967–1981) are surveyed. Malignant tumours occurred most frequently in lower limb muscles and tendons, while beningn tumours in the tendons of the hands.

Tumours arising in skeletal muscle and tendons although not frequent, do occur in a considerable number of cases [2, 3, 4, 6, 7]. Similarly to the skeleton, the skeletal muscle is a large tissue mass from which a variety of tumours may arise.

Materials and Methods

The files of the Department of Morphology of the National Institute of Traumatology for the years 1967–1981 were searched for records of tumours arising in skeletal muscle and tendons. Cases were included based on clinical, surgical and morphological evidence. Metastatic tumours and tumour-like alterations (myositis proliferans, myositis ossificans, osseous metaplasia of muscle and tendon) were excluded.

The surgical specimens were fixed in 6 % neutral formol and embedded in paraffin. The serial sections were stained with H.E., van Gieson, Mallory's trichrome, Gomori's trichrome, phosphotungstic acid haematoxylin (PTAH) and tested by PAS reaction. Tumours of the tendons were also stained with alcian blue-PAS and Romhányi's anisotropic toluidine blue.

Results

Tumours arising in muscle

Nineteen such cases were found. The age of the patients ranged from 16 to 72 years (mean 44 years). There were 10 women and 9 men. The tumours arose at the following sites: 4 on the thigh, 4 on the lower limb, 9 on the trunk and neck, and 2 on the upper limb.

Benign tumours

Of the 6 benign tumours 3 were desmoid tumours, 3 myxochondromas, and 2 angiolipomas (Table I).

TABLE I

Benign tumors of the skeletal muscle

Sex	Age	Muscle	Diagnosis
f	31	m. rectus abd.	desmoid tumour
m	34	m. rectus abd.	myxo-chondroma
m	58	m. pectoralis mai.	angiolipoma
m	28	m. biceps br.	arborescent angiolipoma
f	42	m. rectus abd.	desmoid tumour
m	41	m. obliquus ext. abd.	desmoid tumour

Malignant tumours

Of the 13 tumours in this group (Table II) undifferentiated sarcomas (fusocellular, polymorphocellular etc. types) occurred in seven cases. The degree of differentiation varied, but they were all highly cellular tumours with sparse collagen formation. At necropsy five of the tumours were found to have widespread metastases.

TABLE II

Malignant tumours arising in muscles

Sex	Age yr	Muscle	Diagnosis
f	28	m. soleus	fusocellular sarcoma
f	54	m. interosseus I	fibrosarcoma
m	49	m. quadric. fem.	alveolar soft part sarcoma
f	16	m. quadric. fem.	malignant haemangiopericytoma
m	69	m. quadric. fem.	malignant haemangiopericytoma
m	32	m. peroneus	fusocellular sarcoma
f	68	m. suprascapul.	fibrosarcoma
m	24	m. trapesius	polymorphocellular sarcoma
f	42	m. occipitalis	fusopolymorphocellular sarcoma
m	72	m. iliopsoas	rhabdomyosarcoma
f	64	m. quadric. fem.	polymorphocellular sarcoma
f	62	m. gastrocnem.	malignant haemangioendo-
f	28	m. gastrocnem.	thelioma
		m. popliteus	polymorphocellular sarcoma

Tumours arising in tendons

The age range of the 22 patients was 12 to 71 years. There were 12 women and 10 men. Distribution according to site was as follows: 15 on the tendons of the hand, 1 on the forearm, 6 on the lower limb.

Benign tumours

These included 5 cases of giant-cell xanthofibroma, 6 cases of chondroma, 2 cases of benign synovioma and 1 case each of neurinoma, fibroma, osteoma, haemangioma and lymphangioma (Table III).

Malignant tumours

Of the four malignant tumours there was one case each of fusocellular sarcoma, malignant synovioma, haemangioendothelioma and clear-cell sarcoma (Table IV).

TABLE III

Benign tumours of the tendons

Sex	Age yr	Tendon	Diagnosis
f	18	flex. digit. subl.	xanthofibroma
m	38	flex. digit. prof.	xanthofibroma
n	41	flex. digit. subl.	xanthofibroma
f	38	ext. pollic. long.	xanthofibroma
f	37	ext. digit.	xanthofibroma
m	12	flex. digit. subl.	chondroma
m	21	flex. digit. subl.	chondroma
f	26	flex. digit. subl.	chondroma
f	36	flex. halluc. long.	chondroma
f	41	flex. digit. prof.	chondroma
m	53	tibialis post.	chondroma
f	62	flex. pollic. long.	benign synovioma
f	49	palmaris long.	benign synovioma
m	27	ext. pollic. long.	neurinoma
m	30	flex. digit. subl.	osteoma
m	24	ext. digit	fibroma
f	34	Achilles tendon	cavernous haemangioma
m	53	flex. digit. prof.	lymphangioma

TABLE IV

Malignant tumours of the tendons

Sex	Age yr	Tendon	Diagnosis
m	31	ext. halluc. long.	malignant synovioma
f	71	Achilles tendon	fusocellular sarcoma
f	53	interosseus	clear-cell carcoma
f	49	tibialis post.	haemangioendothelioma

Discussion

This survey has shown that tumours of the skeletal muscles and tendons are indeed rare. Of the 4811 tumours treated at our Institute during the index period of fifteen years, 201 were malignant mesenchymal neoplasms (excluding malignant lymphomas). Of these there were 13 malignant tumours of skeletal muscles (6.4%) and 4 malignant tumours of tendons (2%).

The standard reference books [1, 7] provide little information on the types of tumours occurring in these tissues and on their behaviour. Other sources describe mesenchymal tumours arising in muscles, but do not deal with tumours of the tendons [8, 5].

Our results have shown that malignant tumours of the tendons are extremely rare, while benign tendon tumours occur relatively frequently. Both in muscles and tendons the most frequent sites of malignant tumours are the lower extremities, while the benign neoplasms of the tendons mostly arise on the hands.

References

1. Anderson WAD: Pathology. 6th Ed Mosby, St. Louis 1971
2. Boyes JG, Marroum MC: Epitheloid sarcoma of hand and forearm. Hand 10: 302–305, 1978
3. Enzinger FM: Clear-cell sarcoma of tendons and aponeuroses. An analysis of 21 cases. Cancer 18:1163–1174, 1965
4. Horn RC, Enterline HT: Rhabdomyosarcoma. A clinicopathological study and classification of 39 cases. Cancer 11:181–199, 1958
5. International Histological Classification of Tumours. No 3. Soft Tissue Tumour Classification. World Health Organization, Geneva 1968
6. McClemont JMF: Tumours arising in skeletal muscle in adults. J Pathol 118:113–120, 1976
7. Stout AP, Lattes R: Tumours of the Soft Tissues. Atlas of Tumour Pathology. 2nd Ed. Armed Forces Institute of Pathology, Washington 1967
8. Willis RA: Pathology of tumours. 4th ed. Butterworth, London 1967

Über die aus der Skelettmuskulatur und den Sehnen ausgehende Tumoren bei Erwachsenen

L. Józsa, A. Réffy und A. Renner

In der Arbeit wird über die an der Morphologischen Abteilung des Landesinstituts für Traumatologie im Laufe der vergangenen 15 Jahre (1967–1981) beobachteten, aus der Skelettmuskulatur ausgehenden 19 und aus den Sehnen ausgehenden 22 Tumoren berichtet. Die häufigste Ausgangsstelle der malignen Muskel- und Sehnentumoren ist die untere Extremität und die der benignen Sehnentumoren die Handsehnen.

Опухоли у взрослых, берущие начало в скелетных Мышцах и сухожилиях

Л. ЙОЖА, А. РЕФФИ и А. РЕННЕР

Настоящее сообщение обобщает материал, собранный за 15 лет (1967–1981) в Морфологическом отделении Государственного травматологического института и касающийся опухолей, растущих из скелетных мышц [19] и сухожилий [22]. Исходным местом злокачественных опухолей чаще всего являются скелетные мышцы и сухожилия нижних конечностей, доброкачественных — сухожилия руки.

Dr. László Józsa
Dr. Antal Réffy
Dr. Antal Renner

Department of Morphology, National Institute of Traumatology, Budapest, Baross u. 23.
H-1088

Acta Chirurgica Academiae Scientiarum Hungaricae, Tomus 23 (4), pp. 249–256 (1982)

Blutstillung der transvesikalen Prostatektomie mit einer modifizierten U-förmigen Nadel

V. Szabó, J. Juhász und F. Balogh

Urologische Klinik der Medizinischen Universität Semmelweis, Budapest

(Eingegangen am 27. Januar 1982)

Berichtet wird über die Blutstillung der transvesikalen Prostatektomie unter Anwendung einer modifizierten U-förmigen Nadel. Die in 34 Fällen gewonnenen Erfahrungen führten zur Feststellung, daß das Verfahren vor allem dort vorteilhaft ist, wo die arterielle Blutung nicht aus dem Logerand, sondern aus dem Urethrastumpf oder der Logebasis stammt. Der Blasenverschluß erfolgte mittels Einführung eines Ballonkatheters oder eines epyzystostomischen Draines. Die Methode bietet zwar weitere neue Vorteile, im Zusammenhang mit der Prostatektomie bleiben aber einige Fragen auch weiterhin ungelöst.

Die im letzten Jahrzehnt auf dem Gebiet der Prostatektomie erreichten wesentlichen Fortschritte sind nebst der feineren Operationstechnik vor allem der Ausbreitung der Operationsindikation sowie der sorgfältigen Nachbehandlung zu verdanken [2, 4, 7, 10].

Die die Ergebnisse der Entfernung des Blasenhalsadenoms beeinflussenden Faktoren sind die Operationstechnik, die Blutung und die Infektion [1, 3, 5].

Unter den zahlreichen bekannten Prostatektomiemethoden gehört die transvesikale (Fuller–Freyer) Lösung auch heute noch unter die am häufigsten angewandten Verfahren [6, 7, 12].

Diese Methode bietet nämlich die besten funktionellen Spätergebnisse, wobei aber auch die stets bestehende Gefahr erwähnt werden muß, daß die Blutung des Adenomnests nicht mit voller Sicherheit verhindert werden kann [9, 10, 13, 15].

Heutzutage setzen die Urologen alles daran, die Vorteile der Methode zu bewahren und gleichzeitig eine sichere Blutstillung nebst primärem Blasenverschluß zu erreichen.

Unter den im Interesse der Blutstillung der Prostataloge in den vergangenen Jahrzehnten herangezogenen verschiedenen Modifikationen waren die lokalen und die allgemeinen Blutstillungsverfahren die wichtigsten [8, 14, 15, 16].

Die grundlegende Anforderung der lokalen Maßnahmen ist die Stillung der arteriellen Blutung mit Koagulation, Unternähung oder Unterbindung. Zur Stillung der venösen Blutsickerung eignen sich Tamponade, aufblasbarer Ballonkatheter oder lokal angewandte Hämostatika.

Die intra- und postoperative Blutstillung verursacht, nach wie vor, viele Sorgen; dies veranlaßte eine Vielzahl von Autoren, darunter auch uns eine neue Blutstillungsmethode zu suchen.

Die Versorgung der Logeblutungen knüpft sich an die Namen von Dénis [5]. De la Pena und Alcina [6], Harris [9], Henz [10], Hyrntschak [11] und Szendrői [15].

Material und Methodik

An unserer Klinik wurde bei 34 zwischen 1.3.1980 und 1.10.1981 in epiduraler Anästhesie durchgeführten Prostatektomie eine U-förmige Nadel angewandt; kontrollhalber dienten 34 Patienten, bei denen derselbe Eingriff, aber mit der herkömmlichen Naht stattfand. Der neuen Methode liegt die Blutversorgung des Adenoms zugrunde.

Die Blutversorgung der arteriellen Zweige des Blasenhalsadenoms erfolgt aus der A. vesicalis inferior, der A. haemorrhoidalis media und der A. pudenda interna, während die Venen durch den Plexus vesicalis in die, in die V. hypogastrica mündende Vv. vesicales inferiores bzw. in den Plexus pudendalis münden (Abb. 1).

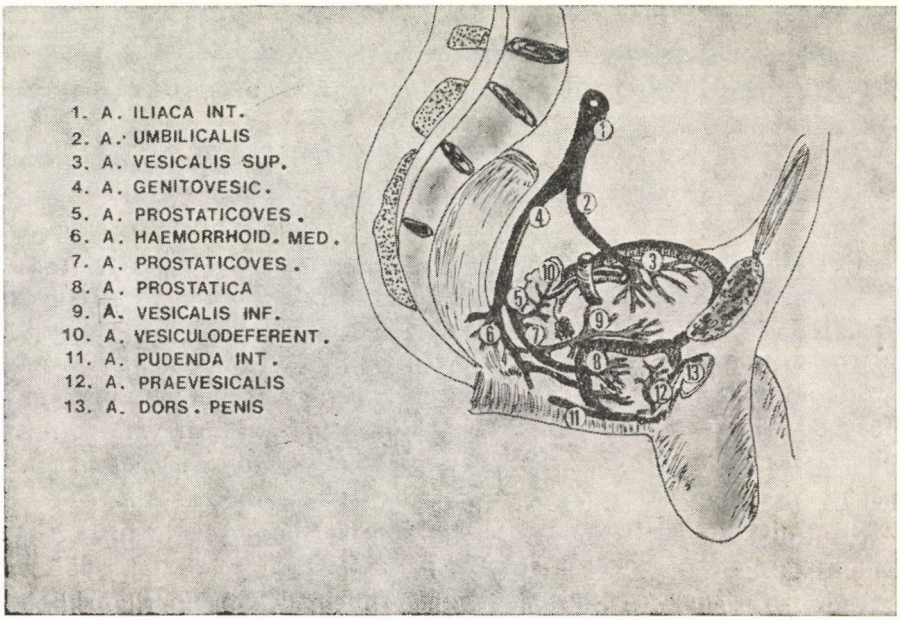

Abb. 1. Blutversorgung der Blase und der Prostata

Unter den auch gegenwärtig gebräuchlichen Methoden der lokalen Blutstillung sind die Logerand-Naht, die beidseitige Naht in der Uhrzeigerrichtung 5h und 9h die Koagulation, der Ballonkatheter sowie die Hencz, Hyrntschak-, De la Pena- und die Milanowszkysche Prostatabettnähte erwähnenswert.

Die aus dem Logefundus und aus dem Urethrastumpf stammenden Blutungen können aber mit den angeführten Verfahren nicht immer behoben werden. Zu diesem Zweck konstruisierten wir ein U-förmig gebogenes Instrument, welches in einer spitzen Nadel endet, in die der sich resorbierende Faden eingefädelt wird (Abb. 2). Dieser modifizierte Haken wird in das Nest des enukleierten Adenoms eingeführt, mit einer energischen Bewegung zurückgezogen und auf diese Weise die Naht in den tiefen Teil der Loge eingelegt — was mit der traditionellen Nadel nicht gelang. Nachdem zwei-drei solche Nähte den Uhrzeigerrichtungen 5h, 7h und 9h entsprechend eingelegt worden sind, läßt die Logeblutung wesentlich nach oder hört sogar vollkommen auf (Abb. 3).

Unter Berücksichtigung der in Tabelle I und II angeführten Gesichtspunkte wurden die Ergebnisse der mit dem von uns konstruierten Blutstillungsinstrument durchgeführten Eingriffe den Daten der Kontrollgruppe, bei der traditionelle Blutstillungsverfahren zur Anwendung kamen, gegenübergestellt (Tabelle I, II).

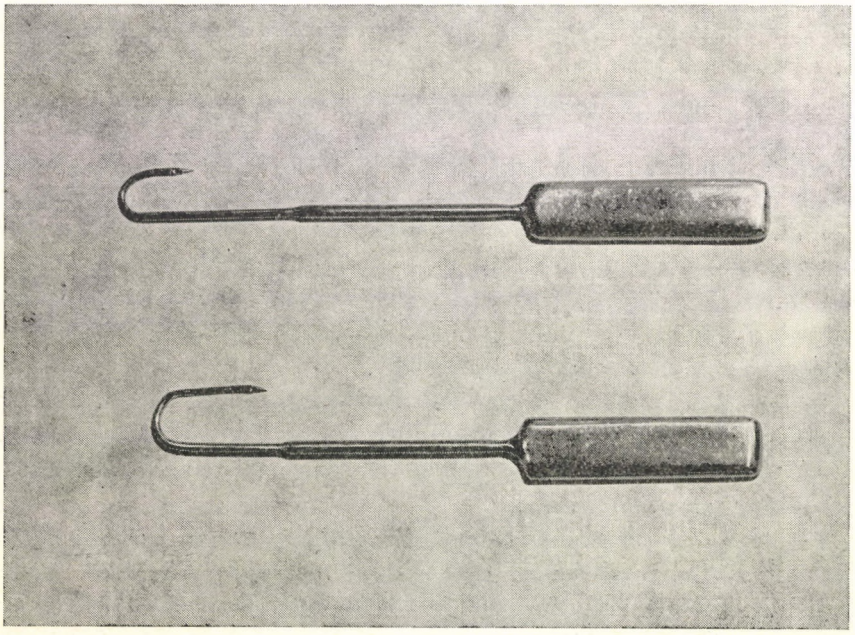

ABB. 2. Modifizierte U-förmige Nadel

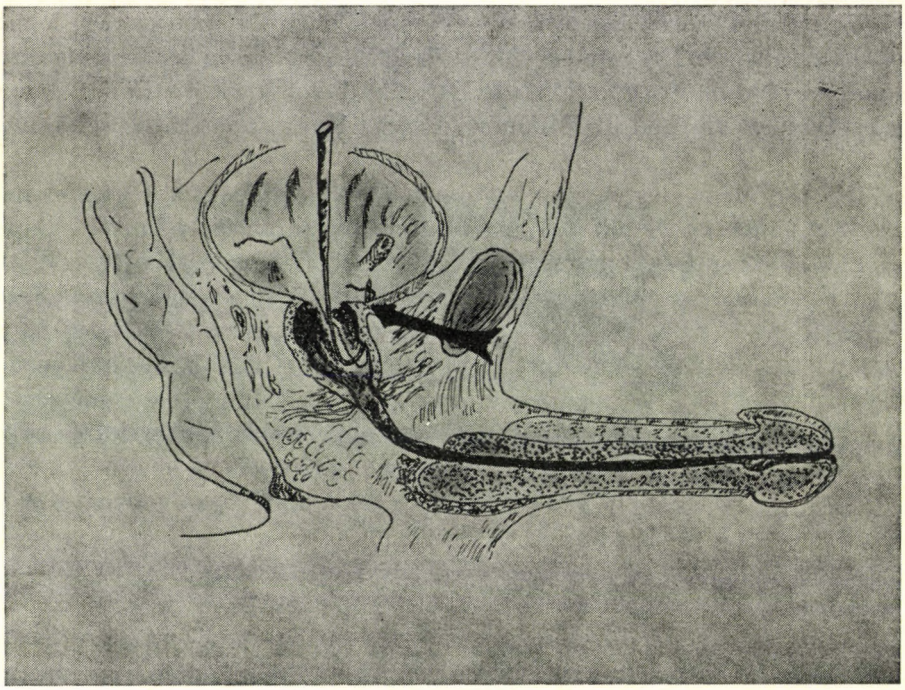

Abb. 3. Mit der U-förmigen Nadel tief in die Loge angelegte Naht. Das Pfeil zeigt auf die Nadelspitze

Ergebnisse

Nebst den intra- und postoperativen Komplikationen — Harnwegsinfektionen, thromboembolische und kardiovaskuläre Veränderungen — wurden auch die eine Transfusion beanspruchenden intra- und postoperativen Blutungen und der Zeitpunkt der postoperativen Katheterentfernung registriert. Durch die frühe Katheterentfernung werden nämlich die postoperative Pyurie, die Zahl der Pflegetage, genauer gesagt die Hospitalisationszeit sowie der Blasenverschluß vorteilhaft beeinflußt.

In der Mehrzahl der in den Tabellen dargestellten Fällen handelte es sich um eine, aus dem Urethrastumpf oder aus der Tiefe der Loge ausgehende Blutung, weshalb betreffs der geeigneten Lösung meistens intraoperativ eine Entscheidung getroffen wurde.

Tabelle III veranschaulicht einige wichtigere Daten unseres Materials: durchschnittliches Lebensalter, Größe des entfernten Adenoms, Blutungshäufigkeit, eventuelle Transfusionen und Zeitpunkt der postoperativen Katheterentfernung (Tabelle III).

TABELLE I

Blutstillung mit modifizierter U-förmiger Nadel

Nr.	Name	Alter (Jahre)	Harn		Gewicht des entfernten Adenoms (g)	Post-operative Blutung	Trans-fusion ml)	Kathe-terent-fernung (Tage)
			Spezif. Gew	Sediment				
1	M.Zs.	74	1018	1– 1 Leuk.	130	—	—	5
2	J.K.	76	1020	8– 10 Leuk.	70	—	—	6
3	L.P.	70	1023	1– 3 Leuk.	65	—	—	6
4	M.T.	55	1018	5– 8 Leuk. 1– 2 Erythr.	60	—	—	7
5	Gy.B.	70	1025	1– 2 Leuk.	50	—	—	5+5
6	J.S.	68	1016	1– 2 Leuk.	60	—	—	8
7	M.T.	65	1019	70– 80 Leuk.	65	—	800	7
8	L.I.	67	1019	60– 70 Leuk.	45	—	—	5
9	B.S.	75	1019	80–100 Leuk.	60	—	—	8
10	P.B.	62	1021	1– 2 Leuk.	40	—	—	10
11	J.G.	73	1027	80– 90 Leuk. 2– 4 Erythr.	80	intraop.	1200	10
12	P.L.	69	1021	20– 25 Leuk.	45	—	—	8
13	V.K.	79	1018	200–250 Leuk. 6– 8 Erythr.	45	postop.	—	10
14	R.T.	68	1020	1– 1 Leuk.	50	—	—	7
15	G.K.	65	1012	10– 15 Leuk.	55	—	—	6
16	Gy.O.	70	1018	30– 40 Leuk. 3– 4 Erythr.	50	intraop.	—	5
17	L.S.	56	1018	10– 15 Leuk.	35	—	—	7
18	J.G.	54	1021	1– 2 Leuk.	50	—	—	8
19	L.H.	73	1025	5– 8 Leuk.	60	—	—	8
20	J.N.	71	1021	1– 2 Leuk.	50	—	—	8
21	A.G.	69	1018	2– 4 Leuk.	55	—	—	5
22	L.T.	79	1025	150–200 Leuk.	50	—	400	8
23	L.B.	80	1015	60– 80 Leuk.	45	—	—	7
24	J.M.	56	1018	1– 2 Leuk.	60	—	—	6
25	K.B.	77	1016	10– 14 Leuk.	40	intraop.	—	9
26	Á.D.	58	1018	5– 6 Erythr.	55	—	—	6
27	Gy.S.	76	1021	1– 3 Leuk.	55	—	—	5
28	J.B.	66	1018	2– 4 Leuk.	60	—	—	6
29	J.D.	66	1019	1– 2 Leuk.	45	—	—	7
30	G.Gy.	83	1021	20– 25 Leuk. 4– 6 Erythr.	55	—	—	8
31	B.K.	69	1018	1– 1 Leuk.	50	intraop.	400	8
32	Gy.T.	72	1019	20– 25 Leuk.	60	intraop.	400	7
33	V.P.	71	1015	60– 80 Leuk.	45 Blasenstein	—	—	8
34	A.Cs.	68	1019	20– 25 Leuk.	55	—	—	8

Besprechung

Dank der Anwendung der neuen, modifizierten Blutstillungsmethode konnten die Besserung der Operationsergebnisse der transvesikalen Prostatektomie, die Verkürzung der Hospitalisationszeit sowie die Abnahme der Zahl der postoperativen Komplikationen erreicht werden.

TABELLE II

Kontrollgruppe

Nr.	Name	Alter (Jahre)	Harn		Gewicht des entfernten Adenoms (g)	Post-operative Blutung	Trans-fusion (ml)	Kathe-terent-fernung (Tage)
			Spezif. Gew.	Sediment				
1	M.Sz.	75	1019	8– 10 Leuk.	80	—	—	7
2	L.Cs.	74	1021	40– 60 Leuk.	21	intraop.	900	8
3	Gy.V.	68	1019	1– 3 Leuk.	65	—	—	8
4	J.T.	66	1019	1– 4 Leuk.	55	—	—	10
5	J.V.	78	1016	10– 15 Leuk.	60	intraop.	800	12
6	J.S.	88	1020	200–250 Leuk.	50	—	—	15
				20– 30 Erythr.				
7	M.U.	68	1018	20– 30 Leuk.				
				3– 4 Erythr.	55	postop.	800	6
8	S.Sz.	68	1021	1– 2 Leuk.	50	—	—	5
9	Gy.N.	75	1025	180–200 Leuk.	45	—	—	6
10	J.F.	72	1025	1– 1 Leuk.	30	—	—	6
11	L.G.	65	1021	2– 4 Leuk.	45	—	—	7
12	J.D.	68	1027	1– 2 Leuk.	60	intraop.	400	8
13	Gy.V.	63	1021	1– 2 Leuk.	45	—	—	6
14	J.F.	71	1023	2– 3 Leuk.	55	postop.	800	8
15	J.Ny.	79	1014	1– 1 Leuk.	45	—	—	6
16	J.Sz.	69	1012	5– 10 Leuk.	40	—	—	8
17	G.J.	51	1019	1– 1 Leuk.	45	intraop.	800	6
18	F.Sz.	73	1018	1– 2 Leuk.	65	—	—	8
19		68	1021	20– 25 Leuk.	40	—	—	12
20	F.M.	69	1025	1– 3 Leuk.	60	intraop.	800	7
21	J.K.	76	1021	1– 1 Leuk.	45	postop.	—	8
22	L.Cs.	73	1018	60– 80 Leuk.	50	—	—	8
				10– 15 Erythr.				
23	A.L.	63	1015	1– 2 Leuk.	40	—	—	7
24	N.A.	67	1018	2– 3 Leuk.	50	—	—	5
25	Z.M.	75	1021	4– 6 Leuk.	55	intraop.	400	4+5
				3– 6 Erythr.				
26	F.M.	62	1010	4– 6 Leuk.	50	intraop.	800	9
				10– 15 Erythr.				
27	F.K.	65	1025	4– 6 Leuk.	40	postop.	400	8
				10– 15 Erythr.				
28	J.N.	83	1018	1– 2 Leuk.	55	—	400	9
29	F.Cs.	73	1021	10– 12 Leuk.	65	intraop.	2000	8
30	L.Sz.	60	1026	1– 2 Leuk.	50	postop.	800	6
31	L.H.	68	1021	1– 1 Leuk.	40	—	—	6
32	V.K.	73	1016	20– 25 Leuk.	45	—	—	5+5
33	R.Cs.	71	1018	5– 6 Leuk.	40	intraop.	—	8
34	B.K.	77	1016	2– 4 Leuk.	45	—	—	9

In der Folge beabsichtigen wir das neue Verfahren nicht mehr serienweise, sondern individuell, von der Blutungsstelle abhängig anzuwenden bzw. in dazu geeigneten Fällen, anhand der Berücksichtigung verschiedener Gesichtspunkte auch weiterhin eine der klassischen Methoden — Ballonkatheter, beidseitige Naht bei 5h und 9h, Hencz- oder sonstige Nähte sowie den, die

TABELLE III

Blutstillung bei Prostatektomie

	Blutstillung	
	mit U-förmiger Nadel	mit anderen Methoden
Insgesamt	34	34
Durchschnittsalter (Jahre)	69	70
Gewicht des entfernten Adenoms (g)	35–130	30–80
Anzahl der präoperativen Dauerkatheter	8	5
intraoperativ	4	9
Blutung	6	14
postoperativ	2	5
Transfusion	5	13
Katheterentfernung (Tage)	4– 8	6–10

besten Ergebnisse zeigenden, einfachen, primären Blasenverschluß über dem Katheter — heranzuziehen.

Unsere nicht allzu vielzahligen Erfahrungen sprechen eindeutig dafür, daß die auf die Entwicklung einer sichereren Blutstillungsmethode der transvesikalen Prostatektomie gerichteten Bestrebungen absolut berechtigt sind, da sich auf diese Weise eine Möglichkeit zur Besserung der Operationsergebnisse bietet.

Literatur

1. Babics A: Megtévesztő kóresetek intraoperatív diagnózisa az urológiában (Intraoperative Diagnose der irreführenden Krankheitsfälle in der Urologie). Akadémiai Kiadó, Budapest 1977
2. Balogh F: Urológia (Urologie). Medicina, Budapest 1978
3. Balogh F, Váry L, Kelemen Zs: Haladás a prostatasebészetben (Forstchritt in der Prostatachirurgie). Magy Seb 23:127, 1970
4. Csata S, Verebélyi A, Balogh Zs: Módosított transvesicalis prostatectomia (Modifizierte transvesikale Prostatektomie). Urol Nephrol Szle 9:11, 1981
5. Dénis R: Prostatectomie sous dépression. J Urol Nephrol 68: 671, 1962
6. De la Pena A, Alcina E: Surgery of the postate. J Urol 86: 88, 1962
7. Freyer PJ: Total exstirpation of the prostate for radical cure enlargement of the organ. Br Med J 1: 249, 1902
8. Fürst F, Corradi Gy, Korányi E: A műtét előtti heveny prostatitisek szerepe a transvesicalis prostatectomiák műtét utáni szövődményeinek kialakulásában (Die Rolle der präoperativen akuten Prostatitiden in der Entstehung der nach den transvesikalen Prostatektomien diagnostizierten postoperativen Komplikationen). Urol Nephrol Szle 2: 51, 1974
9. Harris SH: Suprapubic prostatectomy. Br J Urol 1: 285, 1929
10. Hencz L: Über eine neue Methode der Blutstillung bei transvesicaler Prostatectomie. Acta Chir Acad Sci Hung 3:161, 1962
11. Hryntschak T: Die suprapubische Prostatectomie. W. Mandrich Verlag, Wien 1951
12. Kottász S, Kántor M., Szelepcsényi Z., Keszthelyi L.: Prostatectomiák eredményeinek összehasonlító értékelése osztályunk anyagában. A módosított Dénis-féle módszerrel szerzett tapasztalataink (Vergleichende Bewertung der Ergebnisse der Prostatektomien in unserem Material. E · ah rungen mit der modifizierten Dénis-Methode). Urol Nephrol Szle 6: 200, 1979

13. Magasi P, Végh A: A hólyagnyak adenoma sebészeti megoldásának fejlődése (Entwicklung der chirurgischen Lösung des Blasenhalsadenoms). Urol Nephrol Szle 2:137, 1975
14. Pósta B: Adatok a prostata adenoma műtéti kezeléséhez (Angaben zur operativen Behandlung des Prostataadenoms). Magy Seb 5–6: 357, 1957
15. Szendrői Z: A prostatectomia egyes megoldatlan kérdései (Einige ungelöste Fragen der Prostatektomie). Orv Hetil 110: 2569, 1969
16. Wabrosch G, Guba T: Unsere heutige erfolgreichste Methode bei der Prostatectomie. Urologe 5:134, 1966

Haemostatis in Transvesical Prostatectomy with Modified U-Shaped Needle

V. Szabó, J. Juhász and F. Balogh

In transvesical prostatectomy haemostasis was achieved by the application of a modified U-shaped needle. The method was applied in 34 patients. It is suggested that the method can advantageously be applied when bleeding starts not from the loge-edge, but from the stump of the urethra or from the base of the loge. The bladder was closed by introduction of a balloon catheter and an epicystomic drain. Though the new method ensures additional advantages, it does not solve all the problems arising in connection with prostatectomies.

Остановка кровотечения при трансвезикальной простатэктомии с помощью видоизмененной U-образной иглы

В. САБО, Й. ЮХАС и Г. БАЛОГ

Авторы сообщают о применении модифицированной U-образной иглы для остановки крови при трансвезикальной простатэктомии. Свой новый метод они испробовали на 34 больных. По их мнению, новый метод имеет преимущество в тех случаях, когда артериальное кровотечение происходит не из края *loge*, а из культи мочеточника или из основания *loge*. Пузырь закрывается с помощью помещения баллон-катетера, а также эпицистостомического дренажа. Новый метод обеспечивает новые преимущества, но не разрешает все вопросы, возникающие в связи с простатэктомией.

Dr. Vilmos Szabó
Dr. Ferenc Balogh
Dr. József Juhász
Semmelweis Orvostudományi Egyetem,
Urológiai Klinika
Budapest, Üllői út 78/b, H-1082

Book Reviews

Chirurgische Diagnostik

LEGER–NAGEL

3. überbearbeitete und erweiterte Auflage Springer Verlag Berlin–Heidelberg–New York, 1978. 400 Seiten mit 644 Abbildungen, DM 152,—, US $ 81.—

Die deutsche Auflage der französichen *Sémiologie chirurgicale* wird wahrscheinlich einen noch größeren Anklang auslösen als ihr Vorgänger. Die Einleitung und das Vorwort der typographisch äußerst sorgfältig redigierten, einzigartig didaktischen Arbeit haben Hollender und Kümmerle geschrieben. Nahezu die Hälfte des 400-seitigen Umfangs nehmen außerordentlich gut gelungene Illustrationen in Anspruch: teilweise sind es Photos, teilweise instruktives Abbildungsmaterial und schließlich am Ende des Buches kurzes Literatur- bzw. Sachverzeichnis. Angesichts des ausgezeichneten Bildmaterials stellt man sich unwillkürlich die Frage, wem das Buch von größerem Nutzen sein wird — den Medizinstudenten oder den Fachärzten?

In den einzelnen Kapiteln, die mehr oder weniger den bestimmten Themenkreisen der allgemeinen und speziellen Chirurgie gemäß aufeinander folgen, findet die Behandlung der pathologischen Prozesse — in der Reihenfolge: Beschreibung des Krankheitsbildes, Symptomatologie, Untersuchungsverfahren, Diagnose, Therapie — statt.

Das erste Kapitel befaßt sich mit den häufigsten chirurgischen Infektionen, mit den pyogenen und putriden Infektionen, den kalten und warmen Abszessen, den Eiterungen des Lymphsystems, der Osteomyelitis, den Mykosen, sowie mit den anäroben und spezifischen Infektionen.

Im zweiten Kapitel werden die Probleme der Extremitätentraumatologie erläutert, wonach ein Überblick über die allgemeine Tumorlehre folgt. Ein separates Kapitel befaßt sich mit den Krankheiten des arteriellen und venösen Systems sowie des Lymphsystems. Danach folgt — vielleicht in nicht genügend begründeter Reihenfolge — das den Funktionen und den speziellen Erkrankungen der oberen Extremität, der Hand, der unteren Extremität, sowie des Fußes gewidmete Kapitel.

Das den Titel »Dringende nervenchirurgische Fälle in der allgemeinen Chirurgie« tragende Kapitel bildet soz. einen Übergang zur den Körperregionen entsprechenden Behandlungsweise. In diesem Sinne folgen auf die, die Krankheiten von Kopf und Hals erörternden Kapitel, die die wirbelsäulen- und thoraxchirurgischen, die thoraxtraumatologischen Problemen und die die offenen und bedeckten abdominalen Bauchverletzungen behandelnden Abschnitte.

Dem etwas kurz scheinenden, äußerst wichtigen Kapitel des akuten Abdomens gehen die Besprechung der Zwerchfellkrankheiten und der Bruchlehre voran. Nach der Darlegung der Ileen werden die inneren Blutungen in einem, ihrer Bedeutung gemäß ebenfalls etwas wortkargen Abschnitt erläutert. Im nächsten, die Krankheiten des Nahrungskanals umfassenden Kapitel halten sich die Autoren an die bewährte Reihenfolge, indem zum Abschluß die Krankheiten der Gallenwege, der Leber, des Pankreas und die portale Hypertension eine Besprechung finden.

Das vielleicht am besten gelungene und gleichzeitig auch sehr wichtige Kapitel ist das der Mammachirurgie, in dem alle Vorzüge des Buches aufleuchten: Auf die wichtigsten praktischen Fragen (die eigenhändige Krebsschutzuntersuchung der Frauen darstellende illustrative Abbildungen) wird ebenso eingegangen, wie auf die bei uns leider noch als Neuigkeiten geltenden Techniken (präoperative Aspirationsnadelbiopsie). Das letzte Kapitel bietet ausführliche Kenntnisse in bezug auf die urogenitalen Krankheiten.

Die Quintessenz läßt sich so formulieren, daß die einheimische Kolportage der deutschen, noch eher aber der englischen Auflage dieser ausgezeichneten Arbeit auch unserer Chirurgie von großem Nutzen sein würde.

E. Kisida

Allgemeine und spezielle Operationslehre

Bd VI/2

Herz und herznahe Gefäße

H. G. Borst, W. Klinner und A. Senning (Herausgeber)

Springer Verlag, Berlin–Heidelberg–New York 1978. 802 Seiten mit 797 Abbildungen. DM 310.—, US $ 167.—

Vorliegende Arbeit ist der erste selbstständige Band der von Kirschner gegründeten und später von Zenker, Heberer und Hegemann herausgegebenen traditionsreichen Serie »Allgemeine und spezielle Operationslehre«, welcher ausschließlich der Herzchirurgie gewidmet wurde. Die 30 Verfasser repräsentieren insgesamt 16 herzchirurgische Zentren (13 aus der BRD, 2 österreichische und 1 schweizerisches).

Nach der 3jahrzehntigen Entwicklung der Herzchirurgie kann die überwiegende Mehrzahl der angeborenen oder erworbenen Herzfehler heute bereits chirurgisch korrigiert werden. Der Umstand, daß sich die Operationsprinzipien und -techniken allmählich standardisierten, ermöglichte die Herausgabe einer umfassenden, einheitlich herzchirurgischen Operationslehre. Den Redakteuren muß man es als Verdienst anrechnen, daß das Buch, was Anschauung und Form anbelangt, trotz der vielen Autoren, einheitlich und proportional ist. Im Mittelpunkt der Arbeit steht ausgesprochen der praktische Teil der Operationstechnik, Diagnostik, Pathophysiologie und Indikationen finden nur dann eine Besprechung, wenn sich das im Zusammenhang mit der Auswahl der entsprechenden Operationslösung oder mit intraoperativen Entscheidungen für erforderlich erweist. Die sich am besten bewährten chirurgischen Lösungen und ihre Techniken werden in einer den einzelnen Krankheitsbildern entsprechenden Aufschlüsselung erläutert; in den praktischen Anweisungen widerspiegeln sich die reichen Erfahrungen der Autoren. Zuerst werden die Operationen der angeborenen und erworbenen Vitien, sodann die Koronareingriffe, die thorakalen Aortenaneurysmen, die Pacemakerimplantation sowie die chirurgischen Lösungen der Herzverletzungen und des Perikards beschrieben. Das Gesagte illustrieren rund 800 ausgezeichnete Abbildungen, sowohl die Zeichnungen als auch die Photos sind anschaulich und informativ.

Die allgemeine Operationslehre leitet nach einem historischen Rückblick von Zenker aus der Feder des Freiburger Anatomen Puff ein ziemlich langes, die Fragen der funktionellen anatomischen Entwicklungslehre behandelndes Kapitel ein. Das nächste Kapitel bietet wichtige praktische Kenntnisse in Bezug auf die Technik des extrakorporalen Kreislaufs. Das sich mit den Problemen der postoperativen Behandlung befassende Kapitel ist zwar im Verhältnis zum Gesamtumfang des Buches proportional, in dem Sinne aber, daß es nur die wichtigsten praktischen Standpunkte erfaßt, doch etwas zu kurz. Auf die Besprechung der anästhesiologischen Fragen wird nicht eingegangen.

Besonders wertvoll ist das sehr gut ausgewählte, moderne Literaturverzeichnis am Ende der einzelnen Kapiteln, welches die Orientierung in den Detailfragen erleichtert. Die halbchirurgischen kreislaufunterstützenden Verfahren (Ballonpumpe) werden in dem Buch nicht besprochen, obwohl dies vielleicht lohnhaft gewesen wäre. Ähnlicherweise fehlt auch die Darlegung der Probleme der Herztransplantation und des Kunstherzens, in einer praktischen Operationslehre ist aber das heute noch nicht unbedingt notwendig.

Das Schrifttum der Herzchirurgie verfügte bisher kaum über systematisierte, zusammenfassende Kompendien der Operationslehre; das hiermit besprochene Buch scheint eines der besten dieser Art zu sein.

A. Árvay

K. Bandhauer, J. Frick (eds)

Disturbance in Male Fertility

Springer Verlag, Berlin–Heidelberg–New York 1982. 454 Seiten, 153 Abbildungen Dm 290.—, $ 128.—

Das von Bandhauer und Frick zusammengestellte Buch ist eines der besten andrologischen Fachbücher der letzten Jahre, das den besonderen Wert hat, außer der ausführlichen Besprechung und Wertung allgemeiner andrologischer Kenntnisse auch einen Überblick über die wichtigsten Fragen der gegenwärtigen Andrologie zu gewähren, es ist also eine nützliche Lektüre sowohl für den Anfänger als auch für den Fachmann, der sich mit Andrologie seit langem beschäftigt, oder der eben einen ihrer Zweige speziell betreibt.

Das Buch baut sich aus 17 Kapiteln auf. Die ersten Abschnitte befassen sich mit der Anatomie und Physiologie der männlichen reproduktiven Organe, mit der quantitativen Morphologie des Nebenhodens und der Prostata, mit der Ätiologie der Fertilitätsstörungen, mit den Schritten der klinischen Untersuchung, und berühren die Untersuchungen, die zur täglichen Arbeit eines Andrologen gehören, wie Ejakulatsanalyse, Hodenbiopsie, Röntgen, endokrine Untersuchung.

Ein selbständiges Kapitel behandelt die Nervensystemregelung der Fertilitätsstörungen und die immunologischen Abweichungen. Der therapeutische Schlußteil legt die verschiedenen Arten der konservativen und operativen Behandlung unter Beachtung heutiger Möglichkeiten der Wissenschaft dar, und faßt die korrekte Indikation und die technischen Fragen der artifiziellen Insemination zusammen. Die letzten vier Kapitel beschäftigen sich mit den Grenzgebietsfragen der Andrologie und Sexologie (männliche Kontrazeption, männliche Menopause, Impotenz).

Das Buch ist vorbildlich ausgestattet, hat demonstrative Abbildungen und sein Inhalt ist für jeden Spezialisten interessant, nützlich und notwendig.

Gy. Papp

R. A. Frowein, O. Wilcke, A. Karimi-Nejad, M. Brock and M. Klinger (eds)

Head Injuries. Tumours of the Cerebellar Region. Advances in Neurosurgery 5.

Springer Verlag, Berling–Heidelberg–New York 1978

The book contains the material of the 28th Meeting of the German Neurosurgical Society held in Cologne in September, 1977. The two main subjects were head injuries and cerebellar tumours, supplemented by a number of free papers.

Most of the papers dealt with the prognosis and classification of severe closed head injuries. Braakman suggested, instead of the usual coma-classification, one which takes into account motor and pupil reactions and certain other factors. The significance of continuous registration of intracranial pressure, determination of biochemical changes and of angiographic circulation time was investigated by several authors. Frowein considers the duration of unconsciousness the most decisive factor. Pia attributes a decisive importance to the age of the subject and to the severity of the injury. Brihaye emphasized the importance of several factors in the prognosis of head injuries and the existence of many open questions of which the most important one is the regular clinical examination of the patient. Though the other findings will help assessment, clinical observation is the decisive factor.

Several papers deal with the significance of regular EEG tests and of the analysis of frequency from the aspect of late prognosis. On the basis of frequency analysis, Steudal and Krüger on the 9th day after injury were usually able to set a prognosis corresponding to the late clinical picture.

A few papers deal with the diagnostics and prognosis of traumatic intracerebral haemorrhages. The authors stressed the importance of computerized tomography. If progressive symptoms appear within 4 days following the injury, the results of the operation of intracerebral haemotomas are very poor. Weigel followed 31 cases with computerized tomography (CT) and applied conservative treatment in 27. Twenty-one of the 27 conservatively treated patients survived, while all 4 operated cases died.

Most papers on the diagnosis of cerebellar tumours discuss the role of CT. Grumme et al. found a 96% reliability of CT when some contrast material is used. The detectability of acoustic tumours seemed to the least unambiguous. As to tumours of the posterior scala, Grumme et al. and other authors pointed out that other neuroradiological tests, mainly angiography, cannot be given up. The importance and advantages of ventriculography with absorbable contrast media (Amipaque, Dimer X) are expounded in several papers.

In the case of tumours of the posterior scala tympani, the problem of intracranial pressure stands in the foreground. Intermittent pressure rises (plateau waves) may be an immediate danger to life, thus a pre-operative solution of increased intracranial pressure plays an important role. Brock et al. demonstrate that the various pressure waves behave in a different manner and often appear at night. This induced a number of authors to study the importance of pre-operative ventricle drainage and of shunt-type solutions. New technical solutions have also been proposed.

A separate section is devoted to the medulloblastomas. In contrast to the good results published in the literature, several authors, including Wilcke, Arnold et al., Klug etc., found that with the development of intensive therapy and anaesthesiology, immediate survival has improved in recent years but late progress remained essentially the same, despite attempts with up-to-date chemotherapy. Arnold claims that the best results were observed with old-fashioned local plus spinal irradiation.

Reviewing the catamnesis of 198 patients with cerebellar tumour, Miltz et al. found that 70% of the patients with medulloblastoma died within 1 year and none survived 3 years. The life expectancy of Lindau's tumour is 10 years and of cerebellar astrocytoma 20 years.

Of the free papers, Zülch's report on the principles of the WHO classification of cerebral tumours, some papers on the chemotherapy of cerebral tumours and the work of Knoblich et al. comparing the effects of chmotherapy, hyperventilation and trometamol treatment in clinical and experimental cerebral oedema are of particular interest.

J. JUHÁSZ

P. C. JOANID

Chirurgia Uretrei (Surgery of the Urethra)

Clinica de Chirurgie-Urologie Spitalul Panduri, Editura Medicala, Bucharest 1981.

290 pages, 280 figures, 323 references. US $ 15.—, DM 27.—

This precisely executed, well-edited book with ample references fills a gap in the literature on urologic surgery.

No concise monograph devoted entirely to the surgery of the urethra has so far been published. This book is thus an important contribution, the more so as the problems of up-to-date urethral surgery in cases of congenital diseases, e.g. epispadias, hypospadias, strictures induced by earlier inflammatory processes, e.g. gonorrhoea, and traumatic injuries of the pelvis, neck of the bladder and of the urethra requiring surgical intervention are now receiving increased attention.

The book is divided into 27 chapters with 323 references, and it is a particular merit of their list that it contains articles published not only in English, German and Russian, but also in 12 other languages.

In the introductory part the author stresses the importance of urethral surgery. He points out the dangers involved in neglected cases which by way of retrograde statis can lead to passage disorders, hydroureter, hydronephrosis and urosepsis.

The first two chapters deal with the anatomy and up-to-date physiology of the male and female urethra, as well as with the instruments used in urethral surgery.

The following chapters discuss the indications of surgical intervention, the modes of anaesthesia and the importance of radiological methods.

After discussion of the modes of operative penetration, drainage and splinting, the part on internal urethrotomy reflects an interesting and modern concept of the problems and contains illustrations of the use of instruments.

The importance and applications of urethroscopy in cases of stricture, stones and haemorrhage is the subject of the next chapter. A whole chapter is then devoted to diseases of the meatus of the urethra and to their operations including the special instruments used in these cases.

External urethrotomy, i.e. urethrostomy and urethrectomy are treated in separate chapters. The surgical tricks used in these cases are, in fact, interesting and ingenious.

After discussing the periurethral processes, intubation urethroplasty is described in detail. The figures are good illustrations of the clear, concise text.

Incomplete and complete urethroplasty are the subjects of the next chapters which include the operations for urethral injuries, tumours, diverticulomas and fistulas.

Sphincterectomy performed in the case of sphincter sclerosis and the reconstructive operations recommended for the treatment of incontinence reflect the author's modern concepts of surgical interventions.

Finally, the reader is introduced to the surgical technique of congenital epispadias and hypospadias and, in a separate chapter, to the surgically corrigible diseases of the female urethra.

Summing up, the exacting author possessing a great surgical experience succeeded in enriching the literature on urology with a new indispensable monograph.

A. Verebélyi

CONTENTS

Hübler, J., István, M., Gimes, L. und *Nagy, Z.:* Die Epidermoidzyste des Hodens 205

Sápy, P., Mikó, I. and *Furka, I.:* Comparison of suture materials in the pancreas 209

Csontai, Á., Nádas, Gy., Makó, J., Pánovics, J. and *Balogh, F.:* Diagnosis and treatment of adult polycystic kidney disease 217

Korányi, E., Zágh, I., Kottász, S. und *Kendelényi, E.:* Urologische Komplikationen bei Beckenfrakturen 229

Kottász, S. and *Szijjártó, F.:* Treatment of acute suppurative nephritis 235

Józsa, L., Réffy, A. and *Renner, A.:* Tumours arising in skeletal muscles and in tendons in adults 243

Szabó, V., Juhász, J. und *Balogh, F.:* Blutstillung der transvesikalen Prostatektomie mit einer modifizierten U-förmigen Nadel 249

Book Reviews 257

PRINTED IN HUNGARY
Akadémiai Nyomda, Budapest

ACTA MEDICA

ACADEMIAE SCIENTIARUM HUNGARICAE

REDIGIT

E. STARK

TOMUS XXXIX FASCICULI 1–2

CONTENTS

ENDOCRINOLOGY

Leövey, A., Bakó, Gy., Sztojka, I., Bordán, L., Szabó, T., Kálmán, K., Balázs, Cs.: The pathogenetic connection between Graves' disease and chronic lymphocytic thyroiditis (The role and incidence of thyroid stimulating antibodies)

Tong, A., Farid, N. R., Stenszky, Valeria: Two sisters, one with Graves' disease and the second with thyroiditis and transient hyperthyroidism

Szabolcs, I., Weber, Marianne, Kovács, Zsuzsa, Irsy, G., Góth, M., Halász, T., Szilágyi, G.: The possible reason for serum 3,3'5'-(reverse) triiodothyronine increase in old people

G. Bartha, Klára: Use of compartment models for the study of iodine kinetics

CARDIOLOGY

Littmann, L., Tenczer, J., Fenyvesi, T., Rohla, M., Svenson, R. H.: Concealed re-entry in the human heart

Szatmáry, L., Medvedowsky, J. L., Barnay, C., Pisapia, A., Vincey, J. C., Coste, A., Auberge, J., Medvedowsky, A.: Part of the autonomous nervous system in the development of chaotic post-extrasystolic pictures. Electrophysiological and pharmacological studies of 49 cases

Szatmáry, L., Medvedowsky, J. L., Barnay, C., Medvedowsky, A., Pisapia, A., Delaage, L., Veress, G., Pinot, J. J., Jouve, A., Torresani, J.: Electrophysiological classification of normal and pathological sinus node function

PERIPHERAL CIRCULATION

Soltész, L., Solti, F., Gloviczki, P., Szlávi, L., Entz, L.: Limb circulation in varicosity of various types

GASTROENTEROLOGY

Beró, T., Pongrácz, Gy., Kett, K., Jávor, T.: Weight loss after jejuno-ileal bypass surgery

Beró, T., Pongrácz, Gy., Jávor, T.: Vitamin B_{12} malabsorption after jejuno-ileal bypass surgery

Pálfi, I., Preisich, P.: Long-term results of vagotomy in the light of endoscopy

Miklós, I., Tóth, A., Görög, D., Popik, E.: Orthograde gut irrigation: its general effects

LABORATORY STUDY

El-Waseef, A.: Uroporphyrinogen-I-synthetase activity in red blood cells of lead-exposed workers

---

Papers in English. Published in one volume (4 issues) annually. Subscription rate per volume: $40.00

AKADÉMIAI KIADÓ

Publishing House of the Hungarian Academy of Sciences

Budapest

Distributed by KULTURA, Hungarian Foreign Trading Co., P.O.B. 149, H-1389 Budapest

ACTA PAEDIATRICA

ACADEMIAE SCIENTIARUM HUNGARICAE

EDITOR

P. V. VÉGHELYI

VOLUME 23 NO. 4

CONTENTS

Assessing obesity with body weight and height. *M Amador, C Rodriguez, ME González, J Bacallao*

Diagnosing and misdiagnosing malnutrition. *M Amador, ME González, L Córdova, N Pérez*

Effect of exercise on the lipid parameters in the fasting state and under glucose load. *A Czinner, L Barta, M Tichy*

Ring chromosome 15. *P Kiss, M Osztovics*

Abnormal dermatoglyphics in absence of thumb. *L Borbolla*

Antenatally diagnosed thanatophoric dysplasia. *Z Tóth, J Vachter, G Szeifert, Z Nemes, K Csécsei, O Török, A Harsányi, Z Papp*

Congenital postural deformity association. *I Pazonyi, A Kun, A Czeizel*

HLA antigens in bullous epidermolysis, congenital ichthyosis and ectodermal dysplasia. *A László, G Kaiser, M Simon*

Neonatal oxygen toxicity and its prevention: D-penicillamine offers benefits without harmful side-effects. *G Oroszlán, L Lakatos, L Karmazsin*

The prognosis of severe bronchial asthma in childhood on the basis of late reexaminations. *E Cserháti, G Mezei, J Kelemen, G Póder, A Gegesi*

Papers in English. Published in one volume (4 issues) annually. Subscription rate per volume: $40.00

AKADÉMIAI KIADÓ

Publishing House of the Hungarian Academy of Sciences

Budapest

Distributed by KULTURA, Hungarian Foreign Trading Co., P.O.B. 149, H-1389 Budapest

The *Acta Chirurgica*, a periodical of the Hungarian Academy of Sciences in the field of medical sciences, publish original scientific treatises on surgery and related disciplines (general surgery, surgical aspects of gynecology, urology, oto-rhino-laryngology, orthopaedics, ophthalmology, as well as nerve and brain surgery, pulmonary, oral surgery, heart and blood-vessel surgery) in English, German, French or Russian, with abstracts in languages other than that of the paper.

The *Acta Chirurgica* appear in one volume per year, on some four hundred pages, divided into four fascicles issued quarterly.

Manuscripts should be addressed to

Acta Chirurgica
H-1096 Budapest, Nagyvárad tér 1. István Kórház, Urológia

Orders may be placed with "Kultura" Foreign Trading Company (H-1389 Budapest 62, P.O.B. 149) or its representatives abroad.

Les *Acta Chirurgica*, une revue de l'Académie des Sciences de Hongrie, publient des communications scientifiques originales du domaine de la chirurgie et ses disciplines voisines (chirurgie générale, gynécologie, urologie, oto-rhino-laryngologie, orthopédie, ophthalmologie, ainsi que la neuro-chirurgie, chirurgie du poumon, stomatologie, chirurgie du cœur et des vaisseaux sanguins, etc.). Les langues des communications sont: le français, l'anglais, l'allemand ou le russe, avec des résumés en d'autres langues que celle de la communication.

La revue *Acta Chirurgica* est un périodique publié en un volume par an — 400 pages environ — réparti en quatre livraisons: à paraître chaque trimestre.

On est prié d'envoyer les manuscrits destinés à la rédaction à l'adresse suivante:

Acta Chirurgica
H-1096 Budapest, Nagyvárad tér 1. István Kórház, Urológia

On peut s'abonner à l'Enterprise du Commerce «Kultura» (H-1389 Budapest 62, P.O.B. 149) ou Extérieur chez représentants à l'étranger.

Журнал Академии Наук Венгрии по медицинским наукам *Acta Chirurgica* публикует научные трактаты из области хирургических дисциплин (общая хирургия, гинекология, урология, ото-рино-ларингология, офтальмологиа, ортопедия, также как и нейрохирургия, легочная хирургия, стоматология, сосудистая хирургия, хирургия сердца и т. д.) на русском, английском, немецком или французском языках, с краткими резюме на языках, отличных от языка данной статьи. Авторами трактатов являются выдающиеся венгерские и зарубежные ученые.

Журнал *Acta Chirurgica* выходит по кварталам выпусками, составляющими один том. Приблизительные для публикации рукописи следует направлять по адресу:

Acta Chirurgica
H-1096 Budapest, Nagyvárad tér 1. István Kórház, Urológia

Заказы принимает предприятие по внешней торговле «Kultura» (H-1389 Budapest 62, P.O.B. 149) или его заграничные представительства и уполномоченные.

Periodicals of the Hungarian Academy of Sciences are obtainable at the following addresses:

AUSTRALIA
C.B.D. LIBRARY AND SUBSCRIPTION SERVICE
Box 4886, G.P.O., *Sydney N.S.W. 2001*
COSMOS BOOKSHOP, 145 Ackland Street
St. Kilda (Melbourne), Victoria 3182

AUSTRIA
GLOBUS, Höchstädtplatz 3, *1206 Wien XX*

BELGIUM
OFFICE INTERNATIONAL DE LIBRAIRIE
30 Avenue Marnix, *1050 Bruxelles*
LIBRAIRIE DU MONDE ENTIER
162 rue du Midi, *1000 Bruxelles*

BULGARIA
HEMUS, Bulvar Ruszki 6, *Sofia*

CANADA
PANNONIA BOOKS, P.O. Box 1017
Postal Station "B", *Toronto, Ontario M5T 2T8*

CHINA
CNPICOR, Periodical Department, P.O. Box 50
Peking

CZECHOSLOVAKIA
MAD'ARSKÁ KULTURA, Národní třída 22
115 66 Praha
PNS DOVOZ TISKU, Vinohradská 46, *Praha 2*
PNS DOVOZ TLAČE, *Bratislava 2*

DENMARK
EJNAR MUNKSGAARD, Norregade 6
1165 Copenhagen K

FEDERAL REPUBLIC OF GERMANY
KUNST UND WISSEN ERICH BIEBER
Postfach 46, *7000 Stuttgart 1*

FINLAND
AKATEEMINEN KIRJAKAUPPA, P.O. Box 128
SF-00101 Helsinki 10

FRANCE
DAWSON-FRANCE S. A., B. P. 40, *91121 Palaiseau*
EUROPÉRIODIQUES S. A., 31 Avenue de Versailles, *78170 La Celle St. Cloud*
OFFICE INTERNATIONAL DE DOCUMENTATION ET LIBRAIRIE, 48 rue Gay-Lussac
75240 Paris Cedex 05

GERMAN DEMOCRATIC REPUBLIC
HAUS DER UNGARISCHEN KULTUR
Karl Liebknecht-Straße 9, *DDR-102 Berlin*
DEUTSCHE POST ZEITUNGSVERTRIEBSAMT
Sraße der Pariser Kommüne 3-4, *DDR-104 Berlin*

GREAT BRITAIN
BLACKWELL'S PERIODICALS DIVISION
Hythe Bridge Street, *Oxford OX1 2ET*
BUMPUS, HALDANE AND MAXWELL LTD.
Cowper Works, *Olney, Bucks MK46 4BN*
COLLET'S HOLDINGS LTD., Denington Estate
Wellingborough, Northants NN8 2QT
WM. DAWSON AND SONS LTD., Cannon House
Folkstone, Kent CT19 5EE
H. K. LEWIS AND CO., 136 Gower Street
London WC1E 6BS

GREECE
KOSTARAKIS BROTHERS INTERNATIONAL BOOKSELLERS, 2 Hippokratous Street, *Athens-143*

HOLLAND
MEULENHOFF-BRUNA B.V., Beulingstraat 2,
Amsterdam
MARTINUS NIJHOFF B.V.
Lange Voorhout 9-11, *Den Haag*

SWETS SUBSCRIPTION SERVICE
347b Heereweg, *Lisse*

INDIA
ALLIED PUBLISHING PRIVATE LTD., 13/14
Asaf Ali Road, *New Delhi 110001*
150 B-6 Mount Road, *Madras 600002*
INTERNATIONAL BOOK HOUSE PVT. LTD.
Madame Cama Road, *Bombay 400039*
THE STATE TRADING CORPORATION OF INDIA LTD., Books Import Division, Chandralok
36 Janpath, *New Delhi 110001*

ITALY
INTERSCIENTIA, Via Mazzé 28, *10149 Torino*
LIBRERIA COMMISSIONARIA SANSONI, Via Lamarmora 45, *50121 Firenze*
SANTO VANASIA, Via M. Macchi 58
20124 Milano
D. E. A., Via Lima 28, *00198 Roma*

JAPAN
KINOKUNIYA BOOK-STORE CO. LTD.
17-7 Shinjuku 3 chome, Shinjuku-ku, *Tokyo 160-91*
MARUZEN COMPANY LTD., Book Department,
P.O. Box 5050 Tokyo International, *Tokyo 100-31*
NAUKA LTD. IMPORT DEPARTMENT
2-30-19 Minami Ikebukuro, Toshima-ku, *Tokyo 171*

KOREA
CHULPANMUL, *Phenjan*

NORWAY
TANUM-TIDSKRIFT-SENTRALEN A.S., Karl Johansgatan 41-43, *1000 Oslo*

POLAND
WĘGIERSKI INSTYTUT KULTURY, Marszałkowska 80, *00-517 Warszawa*
CKP I W, ul. Towarowa 28, *00-958 Warszawa*

ROUMANIA
D. E. P., *Bucureşti*
ILEXIM, Calea Grivitei 64-66, *Bucureşti*

SOVIET UNION
SOJUZPECHAT — IMPORT, *Moscow*
and the post offices in each town
MEZHDUNARODNAYA KNIGA, *Moscow G-200*

SPAIN
DIAZ DE SANTOS, Lagasca 95, *Madrid 6*

SWEDEN
ALMQVIST AND WIKSELL, Gamla Brogatan 26
101 20 Stockholm
GUMPERTS UNIVERSITETSBOKHANDEL AB
Box 346, *401 25 Göteborg 1*

SWITZERLAND
KARGER LIBRI AG, Petersgraben 31, *4011 Basel*

USA
EBSCO SUBSCRIPTION SERVICES
P.O. Box 1943, *Birmingham, Alabama 35201*
F. W. FAXON COMPANY, INC.
15 Southwest Park, *Westwood Mass. 02090*
THE MOORE-COTTRELL SUBSCRIPTION AGENCIES, *North Cohocton, N. Y. 14868*
READ-MORE PUBLICATIONS, INC.
140 Cedar Street, *New York, N. Y. 10006*
STECHERT-MACMILLAN, INC.
7250 Westfield Avenue, *Pennsauken N. J. 08110*

YUGOSLAVIA
JUGOSLOVENSKA KNJIGA, Terazije 27, *Beograd*
FORUM, Vojvode Mišića 1, *21000 Novi Sad*

HU ISSN 0001—5431 **Index: 26.008**