Acta Morphologica

Academiae Scientiarum Hungaricae

ADIUVANTIBUS
J. BALÓ, P. ENDES, K. FARKAS, L. HARANGHY,
B. KELLNER, I. KÖRNYEY, I. KROMPECHER,
GY. ROMHÁNYI, E. SOMOGYI, J. SZENTÁGOTHAI

REDIGIT
I. TÖRŐ

TOMUS XIX * FASCICULUS 1

Akadémiai Kiadó Budapest

1971

ACTA MORPHOLOGICA

A MAGYAR TUDOMÁNYOS AKADÉMIA ORVOSTUDOMÁNYI KÖZLEMÉNYEI

SZERKESZTŐSÉG ÉS KIADÓHIVATAL: BUDAPEST V., ALKOTMÁNY U. 21.

Technikai szerkesztő:
Dr. Somogyi Endre

Az Acta Morphologica német, angol, francia és orosz nyelven közöl értekezéseket a kísérletes orvostudomány tárgyköréből.

Az Acta Morphologica változó terjedelmű füzetekben jelenik meg. Több füzet alkot egy kötetet.

A közlésre szánt kéziratok a következő címre küldendők:

Acta Morphologica, Budapest IX., Tűzoltó u. 58.

Ugyanerre a címre küldendő minden szerkesztőségi és kiadóhivatali levelezés.

Megrendelhető a belföld számára az Akadémiai Kiadónál (Budapest V., Alkotmány utca 21. Bankszámla 05-915-111-46), a külföld számára pedig a „Kultúra" Könyv- és Hírlap Külkereskedelmi Vállalatnál (Budapest I., Fő utca 32. Bankszámla: 43-790-057-181) vagy annak külföldi képviseleteinél és bizományosainál.

Die Acta Morphologica veröffentlichen Abhandlungen aus dem Bereiche der experimental-medizinischen Wissenschaften in deutscher, englischer, französischer und russischer Sprache.

Die Acta Morphologica erscheinen in Heften wechselnden Umfanges. Mehrere Hefte bilden einen Band.

Die zur Veröffentlichung bestimmten Manuskripte sind an die folgende Adresse zu senden:

Acta Morphologica, Budapest IX., Tűzoltó u. 58.

An die gleiche Anschrift ist auch jede für die Schriftleitung und den Verlag bestimmte Korrespondenz zu richten. Abonnementspreis pro Band: $ 16,00.

Bestellbar bei dem Buch- und Zeitungs-Außenhandels-Unternehmen »Kultúra« (Budapest I., Fő utca 32. Bankkonto Nr. 43-790-057-181) oder bei seinen Auslandsvertretungen und Kommissionären.

Acta Morphologica

Academiae Scientiarum Hungaricae

Adiuvantibus

I. Baló, P. Endes, K. Farkas, L. Haranghy, B. Kellner, I. Környey, I. Krompecher, Gy. Romhányi, E. Somogyi, J. Szentágothai

Redigit

I. Törő

Tomus XIX

Akadémiai Kiadó, Budapest
1971

ACTA MORPHOLOGICA

TOMUS XIX

INDEX

Gallyas, F.: Silver Staining of Alzheimer's Neurofibrillary Changes by Means of Physical Development 1

Vigh, B.—Vigh-Teichmann, I.—Koritsánszky, S.—Aros, B.: Ultrastructure of the Spinal CSF Contacting Neuronal System in the White Leghorn Chicken 9

Vigh-Teichmann, I.—Vigh, B.—Aros, B.: Light and Electron Microscopic Structure of the Preoptic Recess Organ in the Newt (Triturus cristatus) 25

Ditscherlein, G.—Witte, Ingrid—Kunde, D.: Charakteristische morphologische Befunde im Nierenmark nach Nierenpunktion 43

Gallyas, F.: A Principle for Silver Staining of Tissue Elements by Physical Development 57

Palkovits, M.—Varga, B.—Stark, E.: Effect of ACTH on Repletion of Blood in the Adrenal and Ovarian Tissues of the Dog 73

Pásztor, E.—Hámori, J.: Effect of Local Cooling on Fine Structure of Cerebral and Cerebellar Cortex 81

Lahl, R.: Ein histochemischer Beitrag zum Glykogengehalt im Hirn von chronisch Leberkranken. (Vergleichsuntersuchungen mit einem unausgewählten Obduktionsmaterial) 89

Recensio 103

Péczely, P.: Effect of Metyrapone, Prednisolone and Insulin Treatment on the Domestic Pigeon's Hypothalamus 105

Tóth. S.—Lévai, G.—Szilágyi, T.: Effect of Reptilase on Thrombohaemorrhagie Reactions 123

Csaba, G.—Hodinka, L.: Dynamics of the Cortisone-effect on Mast Cell Formation .. 131

Wenger, T.—Aros, B.: Studies on the Organon vasculosum laminae terminalis III. Vascularization of the Organon vasculosum lamine terminalis in the Rat 141

Kasinathan, S.—Basu, S. L.: Recovery of Spermatogenesis after the Withdrawal of Testosterone Treatment in Rana hexadactyla Lesson 151

Motavkin, P. A.—Dovbish, T. V.: Histochemical Characteristics of Acetylcholinesterase of the Nerves Innervating the Brain Vessels 159

Nagy, Z.—Papp, M.—Bálint, A.: Vascular Injury Associated with Acute Pancreatitis Induced by Oil or Na-Deoxycholate 175

Jellinek, H.: Vascular Changes in Small and Large Arteries in Rapid Hypertension as an Atherosclerosis Provoking Factor 187

Virágh, Sz.—Papp, M.—Rusznyák, I.: The Lymphatics in Oedematous Skin 203

Balázs, M.: Liver Injury Induced by Alpha-Naphthyl-Isothiocyanate 213

Csuka, O.—Sugár, J.: Electron Microscopic Studies on the Specificity of the PA-silver Reaction 233

Basch, A.—Fazekas, I.—Rengei, B.—Mindszenti, L.: Histochemical and Biochemical Examination of Glucuronidase Activity in the Liver and Serum of Severely Burned Rats 241

Neupert, G.: Struktur embryonaler Zellpopulationen in der Leber und primärer Monolayer-Kultur 247

Mándi, B.—Hadházy, Cs.—Mándi, A.—Glant, T.: Effect of Postnatal Thymectomy on Enchondral Ossification 259

Ungváry, G.—Petrovics, E.—Léránth, Cs.—Naszály, S. A.: The Vena portae as an "Independent" Venous Segment: Its Mural Structure and Innervation 269

Törő, I.—Oláh, I.: Electronmicroscopical Changes due to Histamine in the Skin of the Rat 283

Józsa, L.: The Submicroscopic Structure of Connective Tissue in a Case of Hunter's Syndrome 301

Cotutiu, C.—Moraru, I.—Ionescu, V.: Ultrastructural Data in a Case of Dubin—Johnson's Syndrome 313

Recensio 323

Lázár, Gy.: The Projection of the Retinal Quadrants on the Optic Centres in the Frog; a Terminal Degeneration Study 325

Veress, B.—Baintner, K. jr.: Absorption of Colostrum in the Rat and the Cat: A Cooperative Electron Microscopic Study 335

Somogyi, E.—Varga, T.—Sótonyi, P.—Solti, P.—Szabó, Z.—Rényi-Vámos, F.—Földes, I.—Várkonyi, S.: Effect of Immunosuppressive Agents on the Tissue Reaction around the Pacemaker Electrode 349

Somogyi, E. — Varga, T.: Functional and Morphological Changes of the Liver Induced by Electric Shock 363

Papp, M.—Nagy, Z.—Fodor, I.: Ultrastructure of Pancreatic Acinar Parenchyma in Acute Experimental Pancreatitis of the Pigeon 377

Srebro, Z.—Cichocki, T.—Godula, J.: Peroxidase Activity in Glia and Ependymocytes of the Mouse Brain 389

Lapis, K.—Radnót, M.: The Fine Structure of Mast Cells in the Tumours of Protecting Organs of the Eye 397

Kerényi, T.—Romhányi, J.—Poder, G.: Lymphknotenultrastruktur bei Niemann—Pickscher Krankheit 417

Recensiones 433

INDEX AUTORUM

A

Aros, B. vide Vigh, B.—Vigh-Teichmann, I.—Koritsánszky, S.: 9
Aros, B. vide Vigh-Teichmann, I.—Vigh, B.: 25
Aros, B. vide Wenger, T.: 141

B

Baintner, jr. K. vide Veress, B.: 335
Balázs, M.: 213
Basch, A.—Fazekas, I.—Rengei, B.—Mindszenti, L.: 241
Basu, S. L. vide Kasinathan, S.: 151
Bálint, A. vide Nagy, Z.—Papp, M.: 175

C

Cichocki, T. vide Srebro, Z.—Godula, J.: 389
Cotutiu, C.—Moraru, I.—Ionescu, V.: 313

Cs

Csaba, G.—Hodinka, L.: 131
Csuka, O.—Sugár, J.: 233

D

Ditscherlein, G.—Witte, Ingrid—Kunde, D.: 43
Dovbish, T. V. vide Motavkin, P. A.: 159

F

Fazekas, I. vide Basch, A.—Rengei, B.—Mindszenti, L.: 241
Fodor, I. vide Papp, M.—Nagy, Z.: 377
Földes, I. vide Somogyi, E.—Varga, T.—Sótonyi, P.—Solti, P.—Szabó, Z.—Rényi-Vámos, F.—Várkonyi, S.: 349

G

Gallyas, F.: 1, 57
Glant, T. vide Mándi, B.—Hadházy, Cs.—Mándi, A.: 259
Godula, J. vide Srebro, Z.—Cichocki, T.: 389

H

Hadházy, Cs. vide Mándi, B.—Mándi, A.—Glant, T.: 259
Hámori, J. vide Pásztor, E.: 81
Hodinka, L. vide Csaba, G.: 131

I

Ionescu, V. vide Cotutiu, C.—Moraru, I.: 313

J

Jellinek, H.: 187
Józsa, L.: 301

K

Kasinathan, S.—Basu, S. L.: 151
Kerényi, T.—Romhányi, J.—Poder, G.: 417
Koritsánszky, S. vide Vigh, B.—Vigh-Teichmann, I.—Aros, B.: 9
Kunde, D. vide Ditscherlein, G.—Witte, Ingrid: 43

L

Lahl, R.: 89
Lapis, K.—Radnót, M.: 397
Lázár, Gy.: 325
Léránth, Cs. vide Ungváry, G.—Petrovics, E.—Naszály, S. A.: 269
Lévai, G. vide Tóth, S.—Szilágyi, T.: 123

M

Mándi, A. vide Mándi, B.—Hadházy, Cs.—Glant, T.: 259
Mándi, B.—Hadházy, Cs.—Mándi, A.—Glant, T.: 259
Mindszenti, L. vide Basch, A.—Fazekas, I.—Rengei, B.: 241
Moraru, I. vide Cotutiu, C.—Ionescu, V.: 313
Motavkin, P. A.—Dovbish, T. V.: 159

N

Nagy, Z.—Papp, M.—Bálint, A.: 175
Nagy, Z. vide Papp, M.—Fodor, I.: 377
Naszály, S. A. vide Ungváry, G.—Petrovics, E.—Léránth, Cs.: 269
Neupert, G.: 247

O

Oláh, I. vide Törő, I.: 283

P

Palkovits, M.—Varga, B.—Stark, E.: 73
Papp, M. vide Virágh, Sz.—Rusznyák, I.: 203
Papp, M.—Nagy, Z.—Fodor, I.: 377
Papp, M. vide Nagy, Z.—Bálint, A.: 175
Pásztor, E.—Hámori, J.: 81
Petrovics, E. vide Ungváry, G.—Léránth, Cs.—Naszály, S. A.: 269
Péczely, P.: 105
Poder, G. vide Kerényi, T.—Romhányi, J.: 417

R

Radnót, M. vide Lapis, K.: 397
Rengei, B. vide Basch, A.—Fazekas, I.—Mindszenti, L.: 241
Rényi-Vámos, F. vide Somogyi, E.—Varga, T.—Sótonyi, P.—Solti, P.—Szabó, Z.—Földes, I.—Várkonyi, S.: 249
Romhányi, J. vide Kerényi, T.—Poder, G.: 417
Rusznyák, I. vide Virágh, Sz.—Papp, M.: 203

S

Solti, P. vide Somogyi, E.—Varga, T.—Sótonyi, P.—Szabó, Z.—Rényi-Vámos, F.—Földes, I.—Várkonyi, S.: 249
Somogyi, E.—Varga, T.: 363
Somogyi, E.—Varga, T.—Sótonyi, P.—Solti, P.—Szabó, Z.—Rényi-Vámos, F.—Földes, I.—Várkonyi, S.: 249
Sótonyi, P. vide Somogyi, E.—Varga, T.—Solti, P.—Szabó, Z.—Rényi-Vámos, F.—Földes, I.—Várkonyi, S.: 249
Srebro, Z.—Cichocki, T.—Godula, J.: 289
Stark, E. vide Palkovits, M.—Varga, B.: 73
Sugár, J. vide Csuka, O.: 233

Sz

Szabó, Z. vide Somogyi, E.—Varga, T.—Sótonyi, P.—Solti, P.—Rényi-Vámos, F.—Földes, I.—Várkonyi, S.: 249
Szilágyi, T. vide Tóth, S.—Lévai, G.: 123

T

Tóth, S.—Lévai, G.—Szilágyi, T.: 123
Törő, I.—Oláh, I.: 283

U

Ungváry, G.—Petrovics, E.—Léránth, Cs.—Naszály, S. A.: 269

V

Varga, B. vide Palkovits, M.—Stark, E.: 73
Varga, T. vide Somogyi, E.: 363
Varga, T. vide Somogyi, E.—Sótonyi, P.—Solti, P.—Szabó, Z.—Rényi-Vámos, F.—Földes, I.—Várkonyi, S.: 249
Várkonyi, S. vide Somogyi, E.—Varga, T.—Sótonyi, P.—Solti, P.—Szabó, Z.—Rényi-Vámos, F.—Földes, I.: 249
Veress, B.—Baintner, jr. K.: 335
Vigh, B.—Vigh-Teichmann, I.—Koritsánszky, S.—Aros, B.: 9
Vigh, B. vide Vigh-Teichmann, I.—Aros, B.: 25
Vigh-Teichmann, I. vide Vigh, B.—Koritsánszky, S.—Aros, B.: 9
Vigh-Teichmann, I.—Vigh, B.—Aros, B.: 25
Virágh, Sz.—Papp, M.—Rusznyák, I.: 203

W

Wenger, T.—Aros, B.: 141
Witte, Ingrid vide Ditscherlein, G.—Kunde, D.: 43

Acta Morphologica Acad. Sci. Hung. 19 (1), pp. 1–8, 1971

Department of Neurology and Psychiatry
(Head: Prof. St. KÖRNYEY), University Medical School, Pécs

SILVER STAINING OF ALZHEIMER'S NEUROFIBRILLARY CHANGES BY MEANS OF PHYSICAL DEVELOPMENT

F. GALLYAS

(Received July 1, 1970)

A simple and reproducible method for demonstrating Alzheimer's fibrillary changes has been worked out on the basis of a new silver staining principle. It may be applied to 5—200 μ thick sections from both frozen and embedded material fixed in formol even for years. The principle of it is as follows in an alkaline solution AgI_2^- is adsorbed on Alzheimer's changes. The bound AgI_2^- molecules are reduced to colloidal silver grains. Finally, these grains are increased in size up to microscopic dimensions by a special physical developer.

Introduction

Alzheimer's neurofibrillary changes can be demonstrated by BIELSCHOWSKY's (1904) silver impregnation and its modifications (e.g. BRAUNMÜHL, 1927), and by the staining methods for amyloid usual in polarisation (DIVRY and FLORKIN, 1927) and fluorescence microscopy (VASSAR and CULLING, 1959; SCHWARTZ et al., 1964).

By means of a new silver staining principle, based on physical development (GALLYAS, 1971) we have elaborated a simple and reproducible method for demonstrating Alzheimer's neurofibrillary changes. The method by which the tissue elements in the normal brain are not stained, demonstrates, however, certain components of senile plaques and a number of fibrils of unknown origin.

Staining procedure

1. Cut sections 5—200 μ in thickness from frozen or gelatin-, paraffin- or celloidin-embedded material fixed in formol for a period of 1 day to several years. Remove the paraffin or celloidin embedding mass from the sections in the usual manner.
2. Immerse in 5% periodic acid for 30 min.
3. Wash in distilled water for 5 min.
4. Place the section in an alkaline solution of complex silver iodide. — Preparation of the solution: Dissolve 40 g sodium hydroxide then 100 g of potassium iodide in 500 ml of distilled water. Add with a pipette 35 ml of 1% silver nitrate. While pipetting a yellow precipitate forms, which soon disappears if the solution is vigorously stirred. Finally, make it up to 1000 ml with distilled water.

5. Leave sections in physical developer until they become pale gray or brown in colour (about 30 min). The developer is always prepared immediately before use by mixing three stock solutions which, however, can be stored for months at room temperature. The stock solutions are composed as follows.

Solution A: Dissolve 50 g sodium carbonate (anhydrous) in 1000 ml of distilled water.

Solution B: Dissolve 1.90 g of ammonium nitrate, 2.00 g of silver nitrate and 10.0 g of tungsto-silicic acid ($SiO_2 \cdot 12WO_3 \cdot 26H_2O$) all three of analytical grade, in 1000 ml of distilled water in the order given.

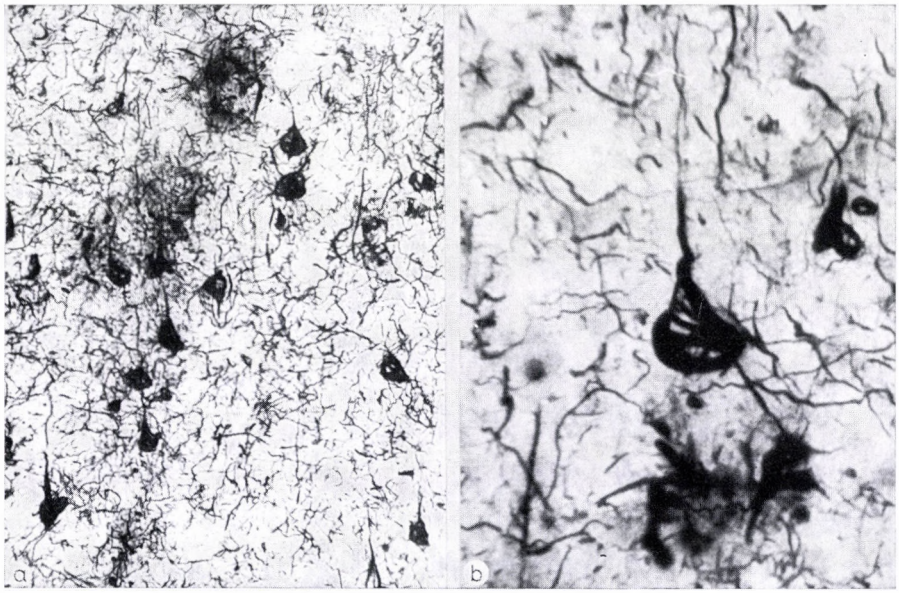

Fig. 1. Alzheimer's neurofibrillary changes in the cerebral cortex in senile dementia. Fine fibres of unknown origin and senile plaques are also demonstrated (a) ×400; (b) ×1100

Solution C: Dissolve 1.90 g of ammonium nitrate, 2.00 g of silver nitrate, 10.0 g of tungsto-silicic acid and 7.3 ml of 35% or 6.1 ml of 40% formol in 1000 ml of distilled water in the order given.

The stock solutions should be mixed according to the following standards depending on the temperature:

Temperature	Solution A ml	Solution B ml	Solution C ml
20 ± 2 °C	10	3	7
25 ± 2 °C	10	5	5
30 ± 2 °C	10	7	3
35 ± 2 °C	10	8	2

To solution A, first solution B then Solution C is added with a pipette in a thin jet. While pipetting, and for some time thereafter, the mixture is vigorously stirred. If the solutions are added too quickly or not in the given order or stirring is not vigorous enough, a white precipitate will form which spoils the developer.

To terminate development, the sections are transferred into a 0.5% solution of acetic acid just when they took on the optimum tint and colour intensity. Until sufficient practice has been gained it is advisable to develop 3—4 sections simultaneously and to remove them

one by one at intervals of two minutes after their beginning to become pale brown in colour. Among these sections there will certainly be one showing optimum development. Growing of the silver particles can be observed under the microscope. For this purpose the sections to be checked are placed in a 0.5% acetic acid solution in order to suspend the development and, after the microscopic examination, placed back, in the developer to continue development if necessary.

6. Wash in 0.5% acetic acid solution for 30 min then in distilled water.
7. Dehydrate in alcohol, clear in clove oil, mount in Canada balsam.

In sections of normal brain only the pale outlines of cell nuclei and capillaries stain even after 40—50 min. of development. In sections from patients with senile dementia, typical Alzheimer's neurofibrillary changes, senile plaques and a number of fine fibrils are demonstrated (Fig. 1). These fibrils are considered pathological because the method does not stain fibrous elements of the normal brain.

Discussion

In a recent paper (GALLYAS) a new principle for silver staining of tissue elements has been described. Tissue sections are immersed in the solution of a certain substance (to be referred to as a "determinant substance") which combines with or is adsorbed on the tissue elements to be demonstrated in a higher degree than on the others. The molecules of this substance, which have been bound on the sections, are replaced with colloidal silver grains by means of chemical reactions. Finally these grains are enlarged to microscopic dimensions by physical development. (The latter term refers to a special kind of photographic process for increasing colloidal silver particles in size so that they can be seen under the microscope.) In contrast to conventional chemical development, in physical development the silver atoms participating in the growth of the silver particles, are provided by the developing solution, the so-called "physical developer" itself, which contains both silver ions and a reducing substance.

Table I

Sequence of chemical reactions in silver staining of Alzheimer's neurofibrillary changes

1.	Alzheimer's changes + AgI_2^-	adsorption	Alzheimer's changes — AgI_2^-
2.	Alzheimer's changes — AgI_2^-	reduction	Alzheimer's changes — $Ag_{(coll.)}$
3.	Alzheimer's changes — $Ag_{(coll.)}$	physical development	Alzheimer's changes — $Ag_{(micr.)}$

In the present method complex AgI_2^- serves as determinant substance. It can be replaced by colloidal silver according to the sequence of reactions shown in Table I. The chemical mechanism of the method consists of 3 stages. In the first stage the complex AgI_2^- molecules are adsorbed on Alzheimer's changes. This reaction can take place over the whole pH range. In the method, however, a strong alkaline solution of AgI_2^- is used in order to suppress the disturbing staining caused by the reducing groups present in the tissue. The potassium iodide in the solution used in this step serves to dissolve the

water insoluble silver iodide in the form of a complex molecule. The remaining stages occur in the physical developer itself. The AgI_2^- is reduced to metallic silver by the formol present in the developer (stage 2). The number of the AgI_2^- molecules bound on Alzheimer's changes is so small that the metallic silver grains which form are of colloidal dimensions. In the final stage the colloidal silver grains are enlarged by physical development up to microscopic dimensions. For suppressing the tissue-produced silver staining which has not been weakened enough by incubating the sections in the strong alkaline medium, treatment with 5% periodic acid is used before stage one.

To control the above chemical mechanism of the method, examinations were carried out on 30 μ sections of the cerebral cortex from a subject with senile dementia. Certain steps of the method given in the description of the staining procedure were omitted or altered and the effects of these changes on final staining were observed.

When incubation in periodic acid was omitted (Fig. 2b), or the pH value of the solution containing AgI_2^- was adjusted to 10 (Fig. 2c) or 7, or 4, Alzheimer's changes were satisfactorily silverized, however, the picture was interfered with by the staining effect of the tissue itself (GALLYAS, 1971). When the sections were treated in an alkaline solution of potassium iodide containing no AgI_2^- (Fig. 2d) or only in 4% sodium hydroxide, Alzheimer's changes failed to take the stain. From the above examinations the conclusion has been drawn that for the silver staining of Alzheimer's changes the AgI_2^- bound by them are responsible.

Two alternatives of how AgI_2^- molecules act as determinant substance can be considered. (i) Certain reducing groups of Alzheimer's changes convert a number of AgI_2^- molecules into colloidal silver grains, which are bound at the site of their formation. (ii) The AgI_2^- molecules are adsorbed on Alzheimer's changes and act as nuclei for the physical development. The first alternative can be left out of consideration because Alzheimer's changes fail to be silverized in acid (pH 4), neutral (pH 7) and alkaline (pH 11 and 14) solutions of $AgBr_2$ (Fig. 2e) or $AgCl_2$ (Fig. 2f). Namely, if Alzheimer's changes would reduce AgI_2^- molecules over the whole pH range, they ought to do the same to $AgBr_2^-$ or $AgCl_2^-$ molecules. The following examinations also contradict the first and confirm the second alternative: Treatment of the sections with either 5% sodium thiosulphate for 30 min (Fig. 2g) or 1% sodium cyanide for 30 min (Fig. 2h) abolished the staining of Alzheimer's changes. It is known that sodium thiosulphate as well as sodium cyanide cannot dissolve metallic silver while they dissolve silver iodide by forming complex compounds. Consequently, they eliminate from the sections the adsorbed AgI_2^- molecules but cannot eliminate the metallic silver particles. On the other hand, staining of Alzheimer's changes was only diminished when, having been incubated in the solution containing AgI_2^- molecules, the sections were treated with 5%

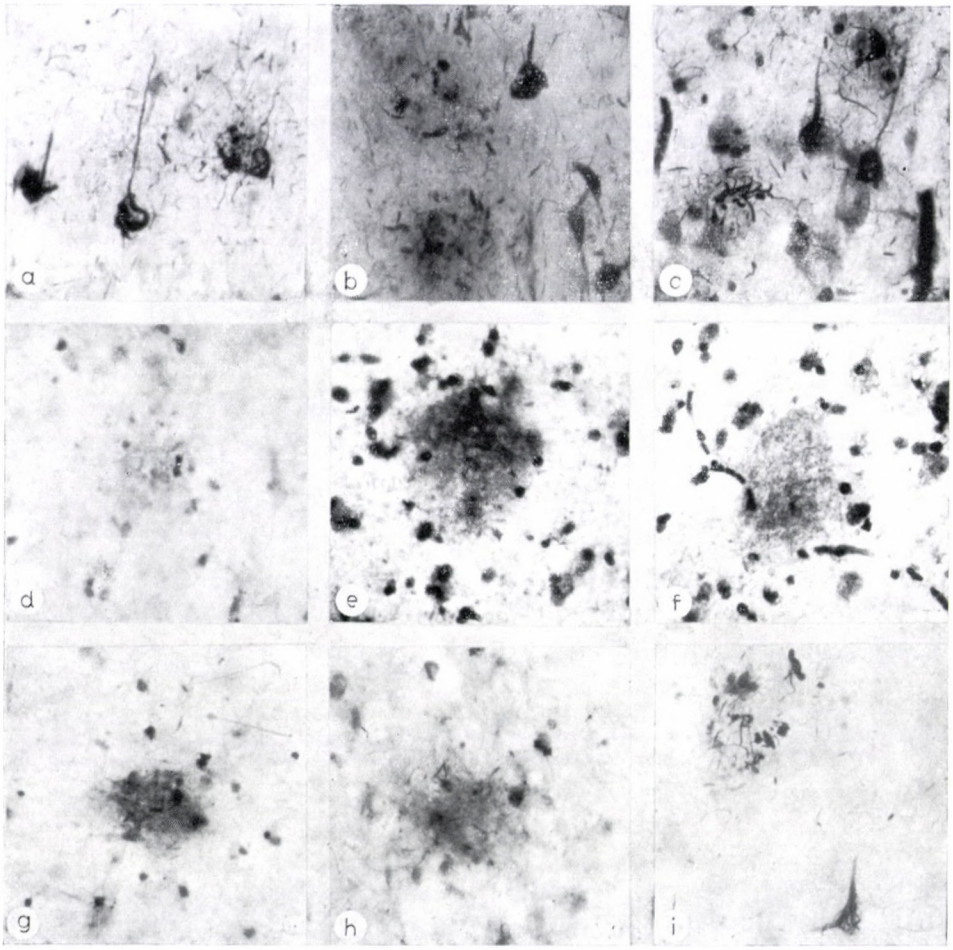

Fig. 2. Experiments on the chemical mechanism of the method. — Cerebral cortex in senile dementia. ×130 — With the exception of item (a), treatment of the sections differed from that given in the description of the staining procedure in the following points; (b) incubation in periodic acid solution was omitted; (c) the solution containing AgI_2^- was adjusted to pH 10; (d) AgI_2^- was replaced by $AgCl_2^-$; (g) development was preceded by 30 minute treatment with 5% sodium thiosulphate; (h) development was preceded by 30 minute treatment with 1% sodium cyanide; (i) before development the sections were immersed in 5% sodium sulphite and then in 5% ammonium hydroxide, for 30 minutes each

sodium sulphite and then with 5% ammonium hydroxide (Fig. 2i). Thus, the two above reagents can dissolve the silver iodide only in a small degree.

The assumption that AgI_2^- molecules can serve as precursor nuclei for physical development has been confirmed by the examinations shown in Table II. They were carried out on 100 μ sections of 25% gelatin fixed in formol. It was determined how long it took for the sections to become deep brown in colour in the physical developer in consequence of the formation of

metallic silver (henceforth this length of time will be referred to as the "time of brown-staining"). The solutions 1, 3 and 8 in Table II are of the same composition as those used in steps 2, 4 and 6 of the method, respectively. Composition of solution 6 is similar to that of the physical developer; the difference is that formol has been left out of solution 6. Solution 7 serves to wash out the excess of solution 6 from the sections.

Table II

Chemical processes of the method

Serial number of examinations / Composition of solutions (time of treatment)	1 5% periodic acid solution (30 min)	2 distilled water (2×5 min)	3 0.05% AgI_2^- and 10% potassium iodide in 4% sodium hydroxide solution (30 min)	4 10% potassium iodide in 4% sodium hydroxide solution (30 min)	5 distilled water (2×5 min)	6 0.1% formol and 0.5% tungsto-silicic acid in 2.5% sodium carbonate solution. (30 min)	7 2.5% sodium carbonate solution (5 min)	8 Physical developer	time needed for sections to become pale yellow in physical developer, min	time needed for sections to become deep brown in physical developer, min
1	−	−	−	−	−	−	−	+	70	78
2	+	+	+	−	+	−	−	+	16	26
3	−	−	+	−	+	−	−	+	16	25
4	+	+	−	+	+	−	−	+	84	93
5	+	+	+	−	+	+	+	+	0	10
6	+	+	−	+	+	+	+	+	81	91

As Table II shows, the untreated gelatin sections remained colourless in the physical developer for 70 min, after which they began to stain yellow, and gradually turned dark brown, through all the tints and intensities of yellow and brown, at 78 min (examination 1). The brown colour of the sections resulted presumably from the enlargement by physical development of the silver nuclei produced by the reducing groups in the gelatin.

The sections treated as detailed in the description of the staining procedure (examination 2) remained colourless in solutions 1 and 3, but in the physical developer they became yellow after 16 min and deep brown in 26 min. The same result was obtained when periodic acid treatment was omitted (examination 3). In contrast, when instead of solution 3 an alkaline potassium iodide solution free from AgI_2^- was used, the time of brown staining was 93 min (examination 4). In examination 4 this time was about 15 min longer than in examination 1, presumably because the formation of gelatin-produced silver nuclei had been suppressed by sodium hydroxide and periodic acid.

A comparison of the first 4 examinations shows that in the physical developer the time of brown-staining for sections containing AgI_2^- molecules serve as precursor nuclei in the physical development.

The sections that had been immersed in a formol-containing solution before physical development (examination 5) became deep brown in a shorter

time than did those which were treated according to the original staining procedure (examination 2). This suggests that it is not the AgI_2^- molecules themselves that act as catalyst in the physical development but the colloidal silver grains which are formed by their reduction. Namely, when the reduction of the AgI_2^- molecules takes place in the physical developer itself (examination 2) the whole time of brown-staining is composed of the part times required for the above reaction and the enlargement of nuclei (the time of development). On the other hand, if the reduction of the AgI_2^- molecules occurs before physical development (examination 5), the time of brown-staining consists only of the time of development. It follows that the speed of reduction of AgI_2^- molecules is low, probably because it takes place in a heterogeneous phase. In examination 6, serving to control examination 5, silver staining was brought about by enlargement of the silver nuclei produced by the reducing groups present in gelatin.

The examinations shown in Table II were carried out also in tissue sections. However, the differences in the time of brown-staining between the individual examinations were considerably smaller than with gelatin sections; in fact, the examination aiming at a verification of the reduction of AgI_2^- molecules in the physical developer was inconclusive.

REFERENCES

1. Bielschowsky, M.: (1904) Die Silberimprägnation der Neurofibrillen. J. Psych. Neurol. **3,** 169—88. — 2. Braunmühl, A.: (1927) Eine einfache Schnellmethode zur Darstellung der senilen Drüsen. Z. Neurol. **122,** 317—22. — 3. Divry, P., Florkin, M.: (1927) Sur les propriétés optiques de l'amyloïde. C. R. Soc. Biol. (Paris) **97,** 1808—10. — 4. Gallyas, F.: (1971) A New Principle for Silver Staining of Tissue Elements by Physical Development. Acta morph. Acad. Sci. hung. **19,** 57. —5. Schwartz, Ph., Kurucz, J., Kurucz, A.: (1964) Morphologische und pathogenetische Untersuchungen über Veränderungen im Greisalter. Zbl. allg. path. Anat. **106,** 320—32. — 6. Vassar, Ph., Culling, C. F. A.: (1959) Fluorescent Stains, with Special Reference to Amyloid and Connective Tissue. Arch. Path. **68,** 487—98.

SILBERFÄRBUNG DER ALZHEIMERSCHEN NEUROFIBRILLENVERÄND ERUNGEN MITTELS PHYSIKALISCHER ENTWICKLUNG

F. GALLYAS

Eine einfache und reproduzierbare Methode für den Nachweis der Alzheimerschen Fibrillenveränderungen wurde aufgrund eines neuen Silberfärbungsprinzips erarbeitet. Sie kann an 5- bis 200 μ dicken Schnitten von gefrorenen oder eingebetteten und in Formol fixierten Objekten sogar nach Jahren angewendet werden. Das Prinzip der neuen Methode besteht darin, daß nach der Adsorption einer alkalischen Lösung von AgI_2^--Molekeln an den Alzheimerschen Veränderungen die gebundenen AgI_2^--Molekeln zu kolloidalen Silbergranula reduziert werden. Schließlich werden diese Granula mit Hilfe eines speziellen physikalischen Entwicklers bis zu mikroskopischen Dimensionen vergrößert.

ОКРАШИВАНИЕ СЕРЕБРОМ АЛЬЦГЕЙМЕРОВСКИХ ИЗМЕНЕНИЙ НЕЙРОФИБРИЛЛ ПУТЕМ ФИЗИКАЛЬНОГО ПРОЯВЛЕНИЯ

Ф. ГАЛЛЯШ

На основе нового принципа для окрашивания серебром был разработан простой и воспроизводимый метод для выявления Альцгеймеровских изменений фибрилл. Новый метод можно применять на 5—200 микроновых срезах замороженных или заключенных и фиксированных формалином объектов даже в течение многих лет. Принцип состоит в том, что щелочный раствор AgI_2^- адсорбируется на Альцгеймеровских изменениях, а затем молекулы AgI_2^- восстанавливаются в зернышки коллоидального серебра. После этого зернышки серебра увеличиваются при помощи специального физикального проявителя до микроскопических размеров.

Dr. Ferenc Gallyas; Ideg- és Elmeklinika, Pécs, Rét ut. 2, Hungary

Acta Morphologica Acad. Sci. Hung. 19 (1), pp. 9–24, 1971

Institute of Histology and Embryology (Head: I. Törő),
Semmelweis University Medical School, Budapest

ULTRASTRUCTURE OF THE SPINAL CSF CONTACTING NEURONAL SYSTEM IN THE WHITE LEGHORN CHICKEN

B. Vigh, I. Vigh-Teichmann, S. Koritsánszky and B. Aros

(Received July 15, 1970)

Around the central canal of the spinal cord of the chicken, there are bipolar nerve cells which send their dendritic process between the ependymal cells into the cerebrospinal fluid (CSF). The processes form characteristic nerve terminals in the lumen of the central canal. The terminal consists of a central body carrying stereocilium-like processes which extend into the CSF in radial direction and sometimes touch Reissner's fibre. These stereocilia, 20—25 μ long and 1.5—2 μ thick, are slightly tapering and contain a bundle of filaments originating from the central body. The central body of the nerve terminal encloses in addition to the above mentioned filaments also microtubules, smooth endoplasmic reticulum and sometimes a multivesicular body. In a funnel-like invagination of the terminal also a cilium of type $9\times2+2$ arises. A basal body and an accessory basal body with thin rootlet fibres are also present. The neck-like part of the CSF contacting terminal is fixed to the adjacent ependymal cells by desmosomes. In the dendrite, there are scattered microtubules, smooth and rough-surfaced endoplasmic reticulum, mitochondria, granulated vesicles and, at the origin of the process, Golgi areas. Axons form synaptic connections with the dendritic process; in the presynaptic area there are mitochondria, synaptic and dense-core vesicles. The perikaryon contains endoplasmic reticulum, mitochondria, Golgi areas and granulated vesicles, 1300 Å in diameter. In the axon terminals forming axo-somatic synapses, dense-core vesicles, 750 Å in diameter, are present beside mitochondria and synaptic vesicles. The distal process of the perikaryon has axon character. At the origin of the process, axons containing dense-core vesicles form synapses on the perikaryon. In the neuropil surrounding the distal processes of the CSF contacting neurons, there are many other nerve fibres forming axo-dendritic synapses. The lining ependymal cells of the central canal are elongated and form several rows in which paler and darker cells can be distinguished. On the basis of the morphological data, the probable receptor function of the spinal CSF contacting neuronal system and its relation to Reissner's fibre is discussed.

Introduction

The term CSF or liquor contacting neuronal system was introduced by us to designate all the CSF contacting nuclei of the central nervous system (Vigh, Teichmann and Aros, 1969). Their neurons are characterized by a dendritic process penetrating into the CSF and forming there a free nerve terminal. Up to now the following CSF contacting nuclei have been described: the neuronal part of the paraventricular organ (nucleus organi paraventricularis; Vigh, 1966, 1967; Vigh, Teichmann and Aros, 1967), the parvocellular part of the preoptic area (preoptic recess organ; Teichmann and Vigh, 1968; Vigh-Teichmann, Röhlich and Vigh 1969). Similar nerve cells can be found in the area of the neurosecretory preoptic nucleus (Vigh-Teich-

MANN and VIGH, 1969, 1970), paraventricular nucleus (VIGH-TEICHMANN, VIGH and AROS, 1970; VIGH-TEICHMANN, VIGH and KORITSÁNSZKY, 1970), lateral tuberal nucleus (VIGH-TEICHMANN, VIGH and KORITSÁNSZKY, 1970; VIGH-TEICHMANN, VIGH and AROS, 1970), infundibular nucleus (VIGH-TEICHMANN, VIGH, KORITSÁNSZKY and AROS, 1970; VIGH-TEICHMANN and VIGH, 1970; VIGH-TEICHMANN, VIGH and AROS, 1971), in the area of the periventricular hypothalamic nucleus (VIGH-TEICHMANN, VIGH and AROS, 1970; VIGH-TEICHMANN, VIGH and KORITSÁNSZKY, 1970) as well as in the grey matter around the central canal of the spinal cord (VIGH-TEICHMANN and VIGH, 1969; VIGH, 1971). All CSF contacting nuclei are localized in the periventricular central grey substance, particularly in the hypothalamic and spinal areas. The latter area has been defined as the spinal CSF contacting neuronal system (VIGH, VIGH-TEICHMANN, KORITSÁNSZKY and AROS, 1970; VIGH-TEICHMANN, VIGH and AROS, 1970; VIGH, 1971).

Neurons localized around the spinal cord and forming terminals in the CSF were revealed earlier by silver impregnation (KOLMER, 1921; AGDUHR, 1922). In previous studies, we demonstrated acetylcholinesterase-positive neurons and their CSF contacting terminals around the central canal (VIGH-TEICHMANN, VIGH and AROS, 1970). Using fluorescence histochemical technique, BAUMGARTEN and WARTENBERG (1970) found monoamine containing CSF contacting neurons at the level of the urophysis. Similar cells were observed by us in the axolotl also in higher segments of the spinal cord (VIGH, VIGH-TEICHMANN, KORITSÁNSZKY and AROS, 1970). The acetylcholinesterase-positive and monoaminergic neurons might represent each a different cell group of the spinal CSF contacting system. Two types of cells were found also by electron microscopy in reptiles, viz. dark, hypendymal cells containing dense-core granules and light, distal neurons containing large granules. The CSF contacting nerve endings differ from similar nerve endings in the hypothalamic area in as much as they carry stereocilium-like processes standing radially in the CSF (VIGH, VIGH-TEICHMANN, KORITSÁNSZKY and AROS, 1970). ARNOLD (1970) described neurons with similar terminals in the spinal cord of the salamander, while it was in the newt where we found the stereociliated nerve terminals and the two types of cells (VIGH, VIGH-TEICHMANN and AROS, 1970). LEONHARDT (1968) demonstrated in the rabbit club-like nerve terminals in the upper portion of the central canal. Thus the spinal CSF contacting neuronal system seems to exist in all classes between fishes and mammals. Up to now, the ultrastructure of the special ciliated terminals of the central canal has been described in amphibians and reptiles. Previous studies in birds revealed the presence of many acetylcholinesterase-positive CSF contacting neurons in the spinal cord (VIGH-TEICHMANN, VIGH and AROS, 1970). As information was lacking on the ultrastructure of the spinal CSF contacting neuronal system in avian species, the present studies in this respect were made in the chicken.

Material and method

Two 10-day-old white leghorn chicken were fixed by aortic perfusion. After rinsing with 6% dextran dissolved in 0.9% NaCl for 20 sec and fixation in 5% glutaraldehyde in 0.1 M phosphate buffer pH 7.2, for 15—20 min, the spinal cord was excised, cut into blocks and fixed in 1% OsO_4 dissolved in 0.1 M phosphate buffer, at 4 °C for 2 hours. After dehydration in ethanol, the specimens were embedded in Araldite. Ultrathin sections were cut with a Reichert OMU-2 ultramicrotome, stained in methanolic uranylacetate and lead citrate and examined with a JEM 6C electron microscope. Semithin sections prepared from the embedded blocks were stained with toluidine blue-azure II.

Results

Ependyma. The ependymal cells arranged in several rows around the central canal possess elongated, chromatin-rich nuclei. There are many microvilli and cilia on the cell surface. The cytoplasm is dark, owing to the highly developed ergastoplasm, particularly to the large amount of polyribosomes. Depending on the degree of the development of their ergastoplasm (Fig. 1A), light and dark ependymal cells can be distinguished. In some cases, large cytoplasmic protrusions can be observed on the ependymal surface (Fig. 1B).

CSF contacting nerve terminals. The central dendritic processes of the neurons localized beneath the ependymal cells form characteristic nerve terminals in the central canal (Fig. 2A). The terminal consists of a central body and 10—15μ long processes resembling stereocilia. These stereocilium-like processes stand radially in the CSF and taper slightly; they are 20—25 μ long, 1.5—2μ thick and are filled out solely by a bundle of filaments (Figs. 2B, C, D), that can be followed into the central body of the nerve terminal (Figs. 3A, B). Sometimes, the free end of the stereocilia touches Reissner's fibre that passes in the lumen of the central canal (Fig. 3C). In the central body of the nerve terminal, there are apart from the bundle of filaments coming from the stereocilia, the endings of microtubules that enter the terminal from the dendrite of the neuron. Sometimes a multivesicular body can be observed (Figs. 3A, D).

The nerve terminal disposes also a kinocilium besides the stereocilia (Fig. 4A). Next to its basal body, there is an accessory basal body, both giving rise to poorly developed thin rootlet fibres extending toward the perikaryon (Fig. 4B). The structure of the cilium resembles that of normal kinocilia (type $9\times2+2$). The cilium characteristically originates from a funnel-like invagination in the central body of the nerve terminal (Figs. 4C, D).

Perikaryon and processes of the CSF contacting neurons. The cells constituting the CSF contacting nerve terminals are bipolar and localized between the basal processes of the ependymal cells. The processes extended by the nerve cells toward the central canal pass straight or in arch-like manner into the CSF. Each process is fixed by desmosomes to the adjacent ependymal cells (Fig. 5A). The process is dendrite-like; it contains scattered microtubules, mitochondria,

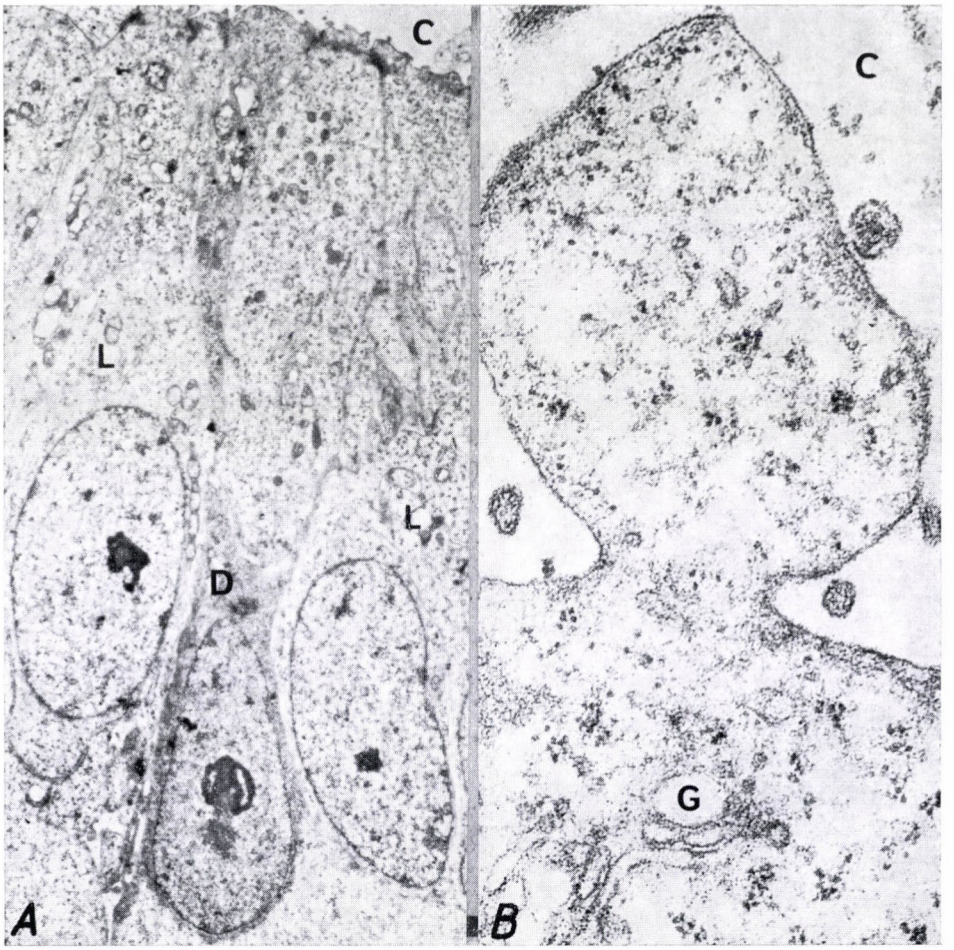

Fig. 1A. Light (L) and dark (D) cells in the ependyma of the central canal of the spinal cord of the chicken. C: central canal. ×6320. *B.* Cytoplasmic process extending from the surface of an ependymal cell. C: central canal; G: Golgi area. ×57 500

smooth and rough-surfaced endoplasmic reticulum, sometimes a multivesicular body and granulated vesicles with a mean diameter of 1300 Å (Figs. 5A, C). At the origin of the dendrite we found Golgi areas. Axons containing dense-core vesicles, 700—800 Å in diameter, form synapses with the dendritic CSF contacting processes (Figs. 5B, C).

Fig. 2A. CSF contacting nerve terminal with stereocilium-like processes (arrows). C: central body of the nerve terminal; DE: desmosomes; Ep: ependymal cells; N: neurotubules. ×50 000. *B.* Longitudinal section of a stereocilium-like process (hollow arrows) extending from the nerve terminal. At arrows cross sections of stereocilia in the surroundings. Ep: ependymal cell;

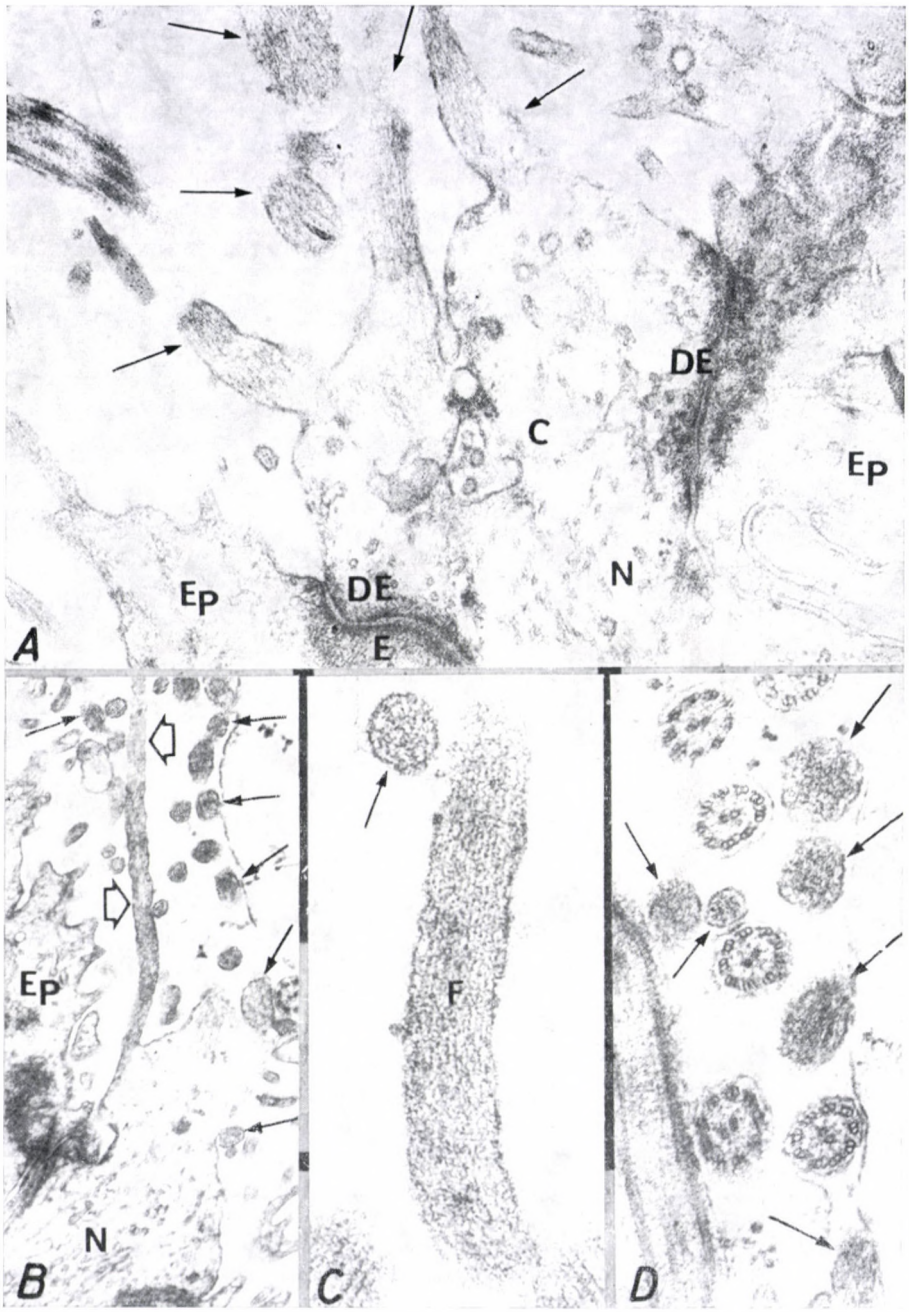

N: neurotubules at the neck-like portion of the nerve terminal. ×23 750. *C.* Longitudinal section of a stereocilium-like process with high power. Note the oriented filaments (F). The arrow points to cross section of a stereocilium. ×90 000. *D.* Cross sections of stereocilium-like processes (arrows) of a CSF contacting nerve terminal under high power, with cross sections of kinocilia. ×57 500

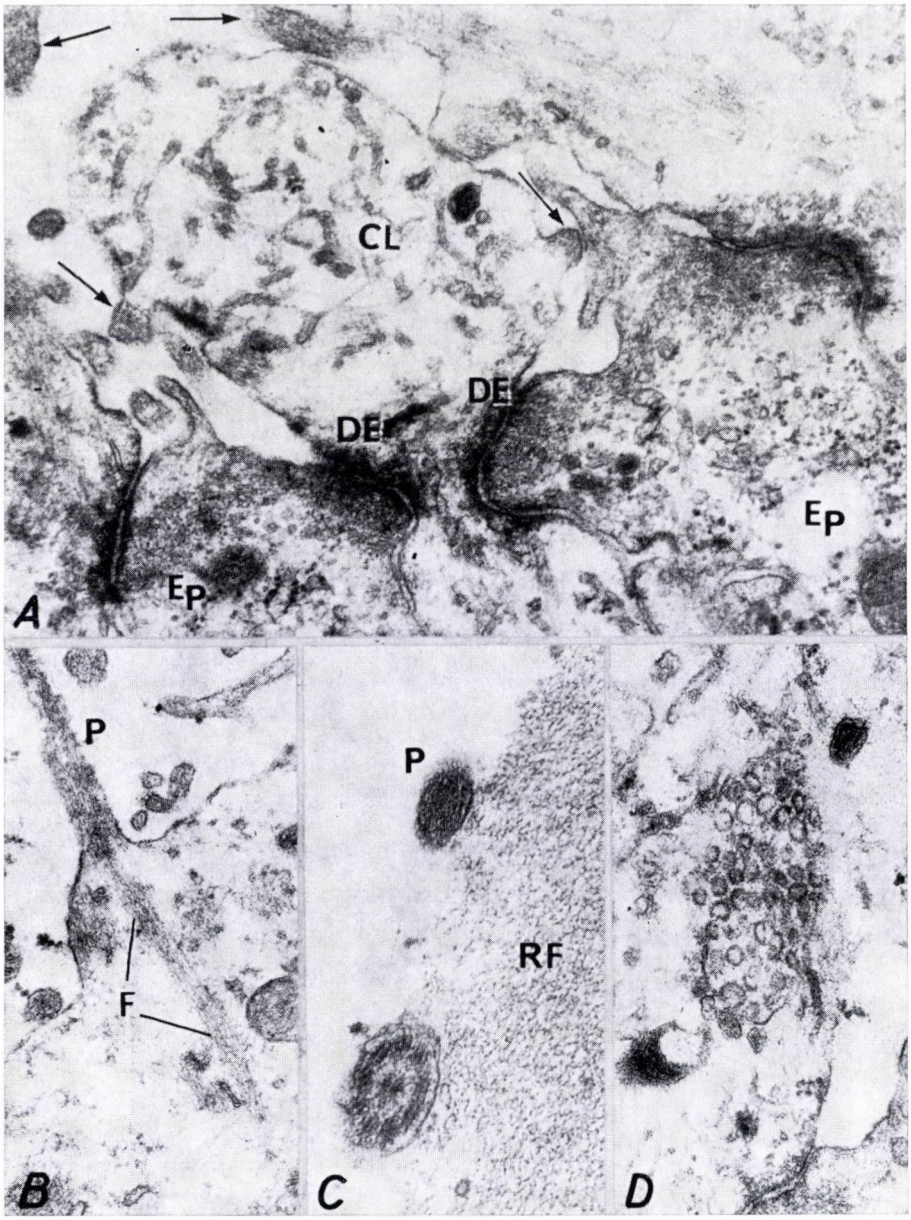

Fig. 3A. Central body (CL) of a spinal CSF contacting nerve terminal from the chicken with ending neurotubules coming from the dendritic process. The arrows point to the site of origin, viz. cross sections of the stereocilium-like processes. DE: desmosome fixing the neck-like part of the nerve terminal to adjacent ependymal cells (Ep). ×45 000. *B.* Bundle of filaments (F) passing from the stereocilium-like process (P) into the central body of the nerve terminal. ×37 500. *C.* Stereocilium-like process (P) of the CSF contacting nerve terminal attaches to Reissner's fibre (RF). Below: cross section of a kinocilium, also adhering to Reissner's fibre. ×62 500. *D.* Multivesicular body in a CSF contacting nerve terminal. ×57 400

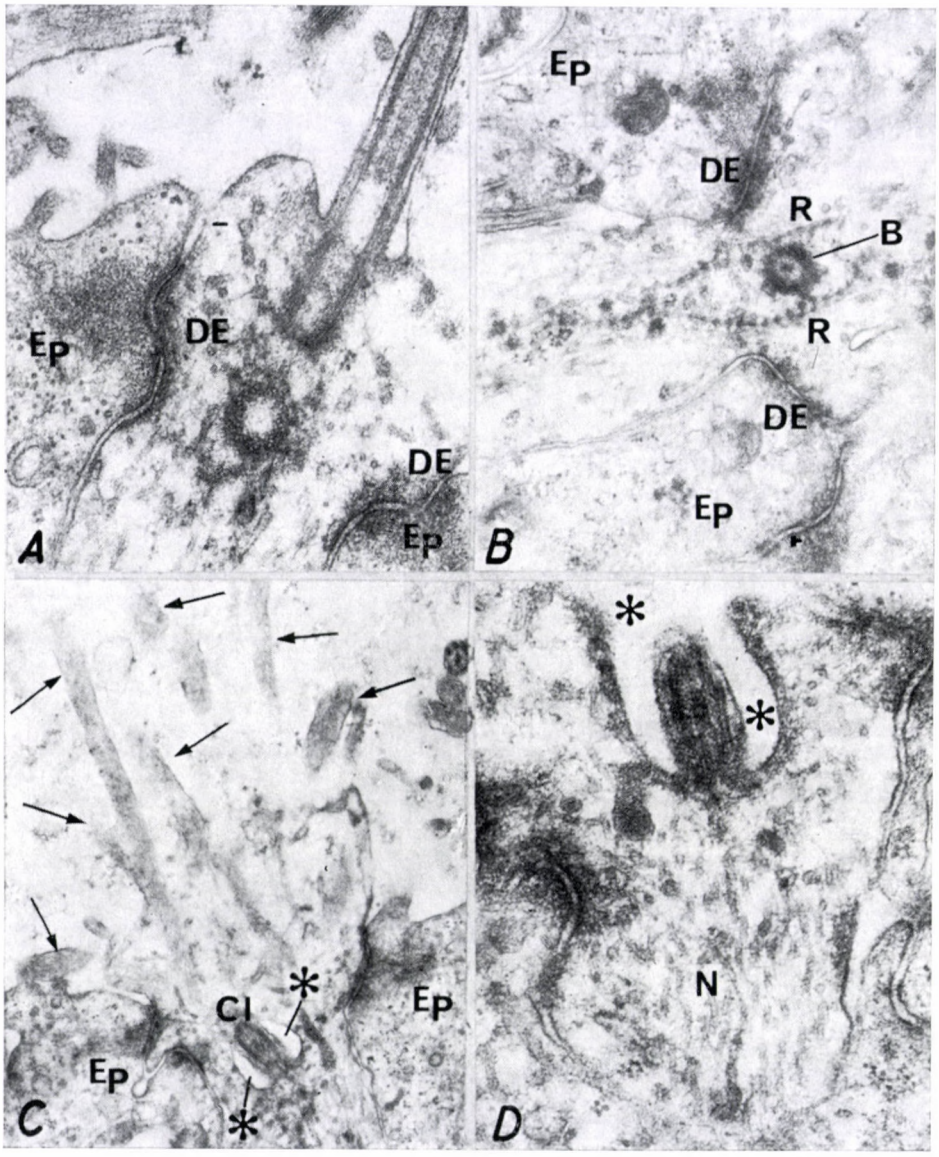

Fig. 4A. Cilium arising from CSF contacting nerve terminal, and basal body. DE: desmosomes linking the neck-like part of the terminal with adjacent ependymal cells (Ep). ×57 400. *B.* Rootlet fibres (R) arising from the basal body of the nerve terminal. B: basal body; DE: desmosome linking the neck of the nerve terminal with the adjacent ependymal cells (Ep). ×37 500. *C.* Funnel-like invagination (asterisks) at the base of the kinocilium (CI) arising from the CSF contacting nerve terminal. The arrows indicate different sections of the stereocilium-like processes extending from the terminal. Ep: ependymal cells. ×17 700. *D.* Funnel-like invaginated part of the terminal (asterisks) around the cilium. ×62 500

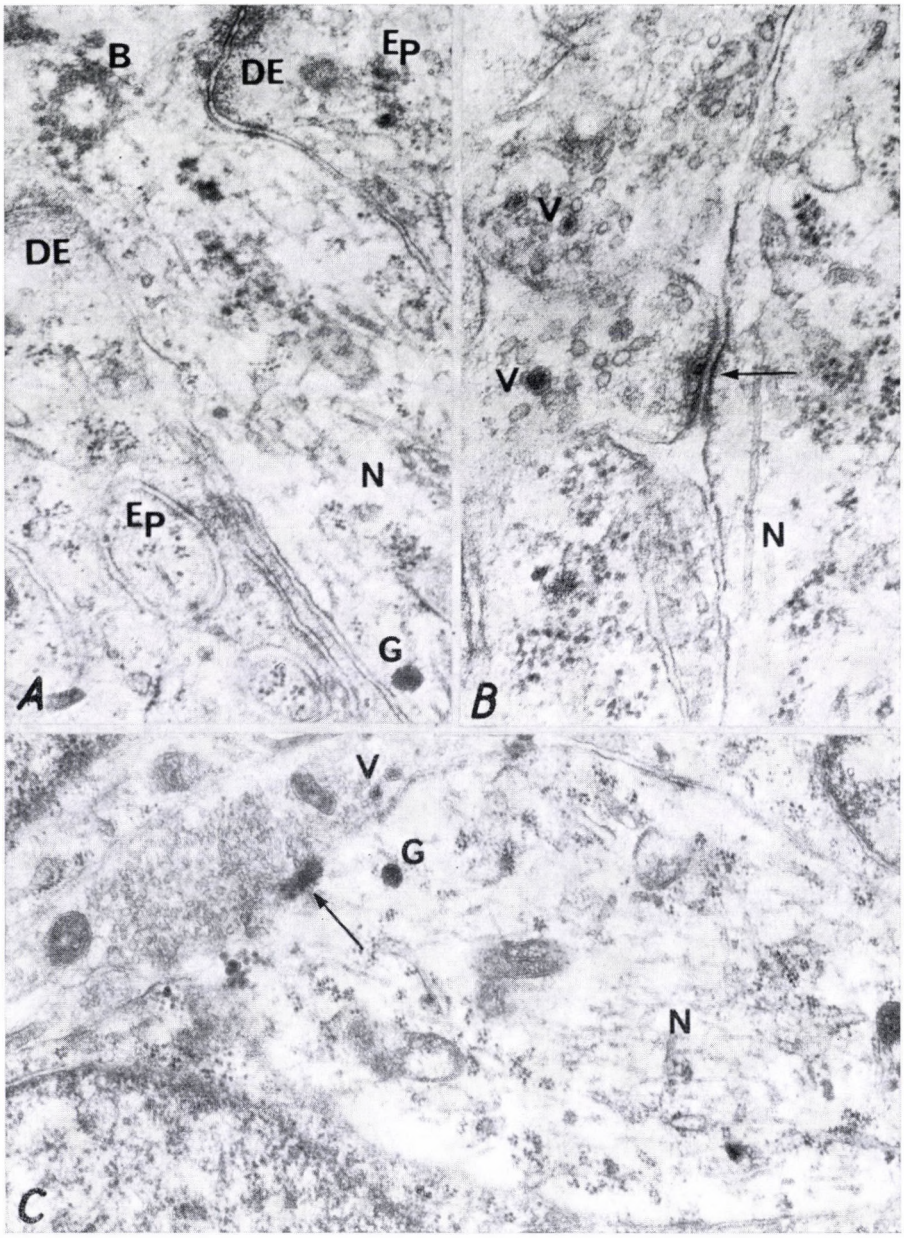

Fig. 5A. Longitudinal section of the central dendritic process of a CSF contacting neuron which forms the terminal. B: basal body within the nerve terminal; DE: desmosome; Ep: ependymal cells; G: granulated vesicle within the dendrite; N: neurotubules. ×37 500. *B.* Synapse (arrow) on the central dendritic process of the CSF contacting neuron. N: neurotubules; V: dense-core vesicle. ×62 500. *C.* Central dendritic process of a CSF contacting neuron with synapse (arrow). G: granulated vesicle (1300 Å); N: neurotubules; V: dense-core vesicles within the axon (average diameter 750 Å). ×28 000

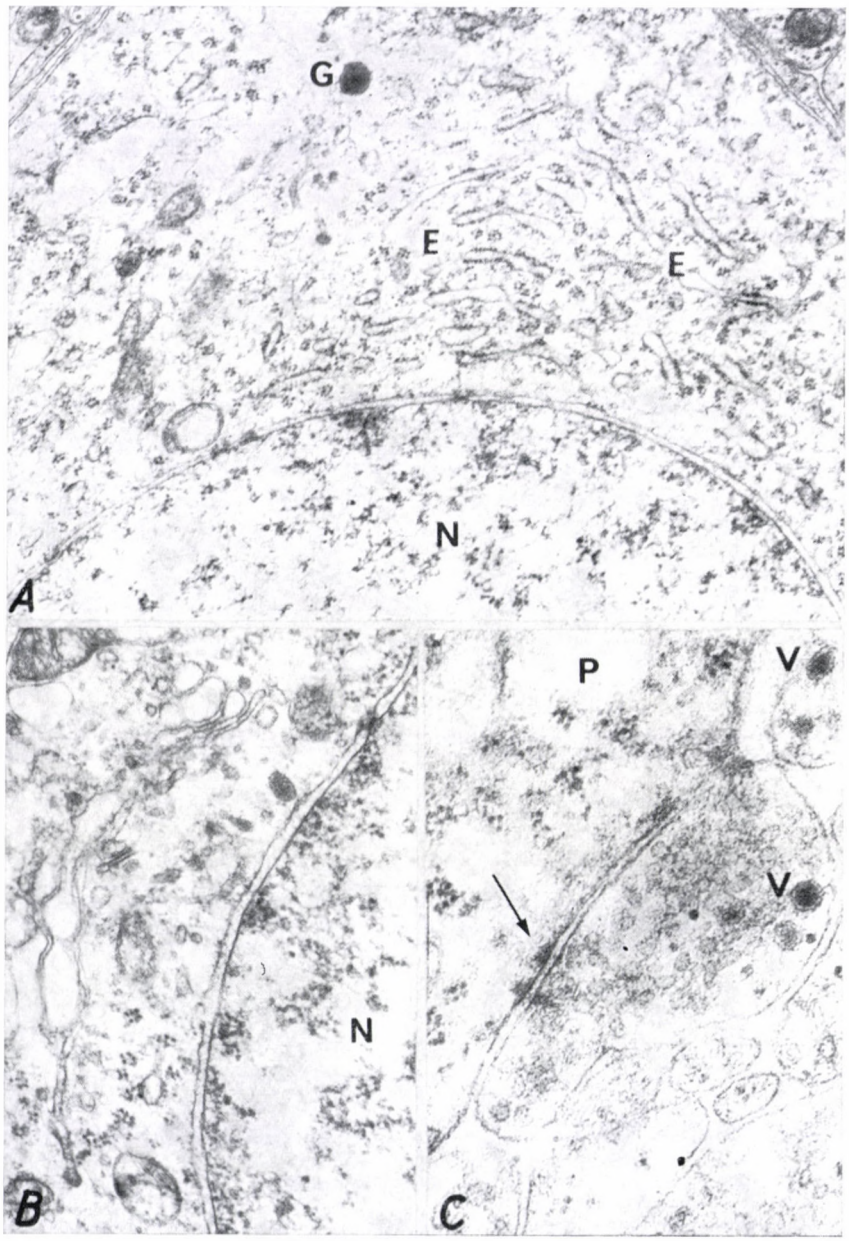

Fig. 6A. Part of the perikaryon of a CSF contacting neuron of the central canal. E: ergastoplasm; G: granulated vesicle; N: nucleus. ×25 250. *B.* Golgi area in the perikaryon of a CSF contacting neuron. N: nucleus. ×37 500. *C.* Synapse (arrow) alongside the perikaryon (P) of a CSF contacting neuron. V: dense-core vesicles. ×62 500

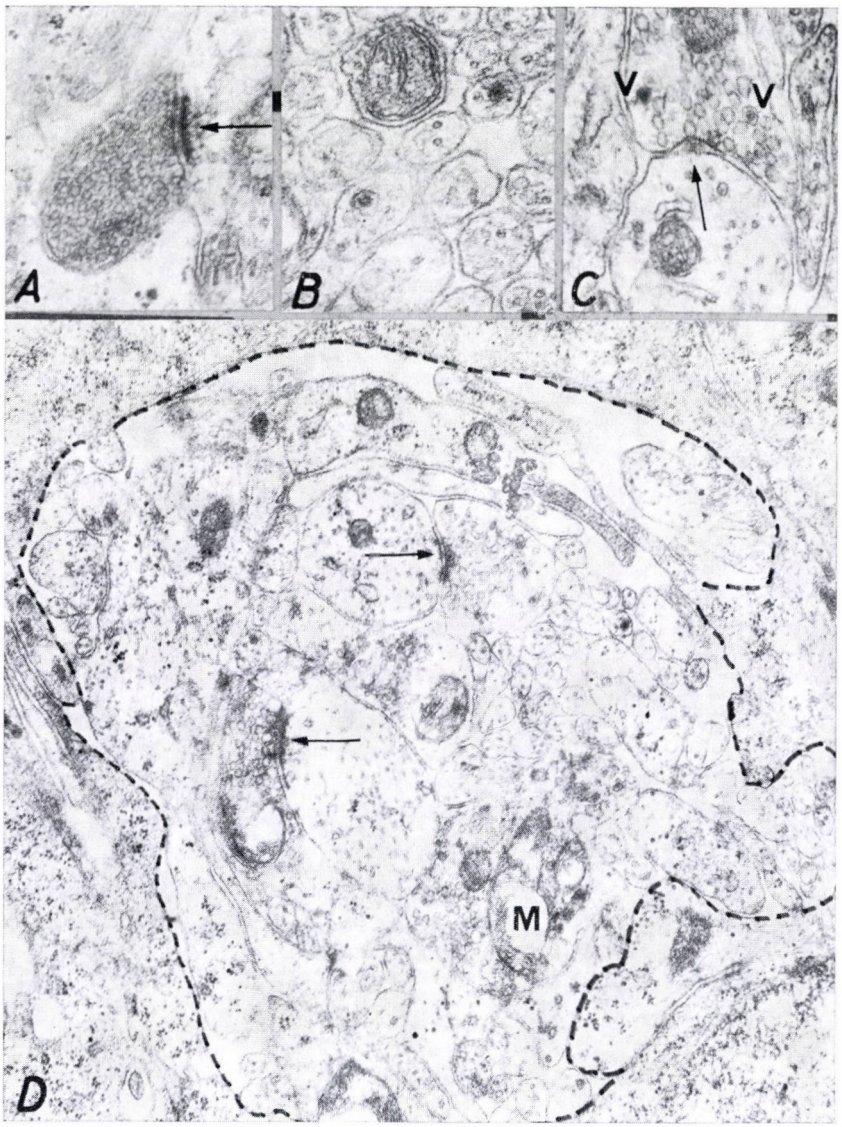

Fig. 7A. Synapse-forming, vesicle-filled axon in the neuropil localized distally to CSF contacting neurons. ×37 500. *B.* Cross sections of small nerve fibres in the neuropil around the central canal. ×57 500. *C.* Axo-dendritic synapse (arrow) in the synaptic zone. V: dense-core vesicles within the axon. ×45 000. *D.* Group of nerve fibres and synapses (arrows) surrounded by glial cells in the area of the neuropil. Margins of the glial cells and fibres are indicated by dotted line. M: mitochondrium. ×27 500

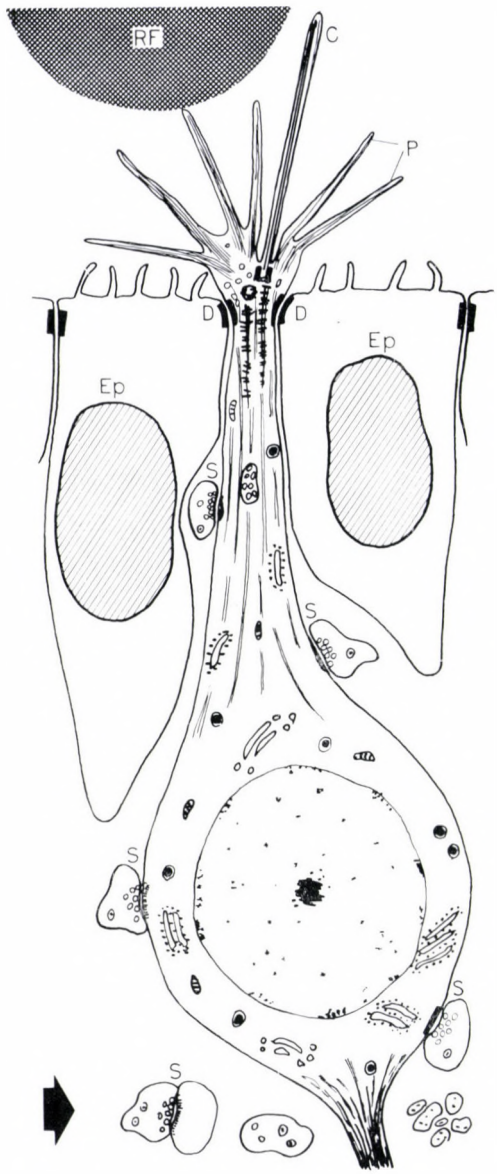

Fig. 8. Schematic drawing of a CSF contacting neuron in the area of the central canal of the spinal cord of the chicken. C: kinocilium of CSF contacting nerve terminal; D: desmosome fixing the neck of the nerve terminal to adjacent ependymal cells (Ep); P: characteristic stereocilium-like processes of CSF contacting nerve terminal; RF: Reissner's fibre in the lumen of the central canal; S: synapses; the arrow indicates the synaptic zone around the distal process of the CSF contacting neuron

The perikaryon of the CSF contacting neurons is less electron dense than that of the ependymal cells and contains a considerable amount of rough-surfaced endoplasmic reticulum (Fig. 6A), but only few free ribosomes as compared to the ependyma. There are also Golgi areas, mitochondria and several granulated vesicles, 1300 Å in diameter (Figs. 6A, B). Synapses (Fig. 6C) formed by axon-like fibres, of the kind described for the dendritic process, are present also on the cell body.

The distal process of the CSF contacting neuron has axon character, it is thinner than the central dendrite and contains many microtubules. At the origin of the distal process, axons containing dense-core vesicles form synapses on the perikaryon. The distal process runs ependymofugally and can be followed over a shorter or longer distance in the fibrous zone situated distally to the neurons. The axons of the CSF contacting nerve cells pass toward the lateral parts of the grey substance of the spinal cord.

Neuropil. Around the CSF contacting neurons, particularly distally to them, cross sections of many nerve fibres are seen. These fibres, varying in diameter, form multiple synapses with each other (Figs. 7A, B, C, D). The synapses contain in addition to synaptic vesicles and mitochondria often also dense-core vesicles (Fig. 7C). The granules measure from 550 to 1000 Å, with a mean diameter of 750 Å. The processes of the ependymal and glial cells surround part of the fibres and synapses into bundles, thus separating them from the rest of the neuropil (Fig. 7D).

Comparing different segments of the spinal cord of the chicken, we did not find any essential difference in the general structure (Fig. 8) of the CSF contacting neuronal areas.

Discussion

The present findings suggest that the spinal CSF contacting nerve terminals of the chicken are structurally analogous with those of amphibians and reptiles (VIGH, VIGH-TEICHMANN, KORITSÁNSZKY and AROS, 1970; VIGH, VIGH-TEICHMANN and AROS, 1970, 1971; ARNOLD, 1970; VIGH, 1971). Similar nerve endings were found by us in the central canal of *Turdus merula* (VIGH, 1970 unpubl.). The nerve terminals are covered by long stereocilium-like processes which stand radially in the CSF (Fig. 8). This kind of nerve terminal is typical only of the spinal CSF contacting system, as terminals in the hypothalamic CSF contacting areas are morphologically different (VIGH, VIGH-TEICHMANN, KORITSÁNSZKY and AROS, 1970). A further characteristic is the presence of a kinocilium on most CSF contacting nerve endings. The structure of the cilium is not atypical like in the hypothalamic terminals ($9 \times 2 + 0$), but resembles that of a normal kinocilium ($9 \times 2 + 2$). These morphological

differences suggest that the spinal and hypothalamic CSF contacting nerve structures differ also functionally.

Contrary to our findings in amphibians and reptiles where two kinds of nerve cells producing granules of about 800—900 Å or 1300 Å in diameter, were present, only one type of neurons with granules 1300 Å in diameter, could be recognized by us in the chicken.

In both chickens and reptiles, a direct contact between the stereocilia of the terminal and Reissner's fibre was found in some cases. It seems likely that the kinocilium of the nerve ending also contacts Reissner's fibre, as cross-sections of cilia are often seen on the latter structure. This morphological contact recalls the hypothesis advanced by AGDUHR in 1922 suggesting Reissner's fibre to play a role in the function of the neurons surrounding the central canal, which the author already considered sensory cells.

From the point of view of the function of the spinal CSF contacting neuronal system, it is interesting to know the fibre connections of its neurons. Investigations into this subject by means of silver impregnation were carried out first by KOLMER (1921) and AGDUHR (1922) who found the neurites to pass either directly or through hypendymal associative cells to the motor neurons and to the external surface of the spinal cord. To explain the function of the fibres running to the motor cells, it may be assumed that the information mediated from the CSF by the sensory cells, acts by facilitating or inhibiting the activity of the motor cells. The role of those nerve fibres which pass to the external surface of the spinal cord presents more of a problem, but recent findings have disclosed an analogy for the function of this type of fibres, too. In the area of the median eminence and of the primitive neurohypophysis in lower vertebrates, the neurosecretory fibres pass to the brain surface or to the vessels supplying it. In certain species the neurites of the urophyseal system, too, pass to the surface of the spinal cord, where they end ventrally or bilaterally (FRIDBERG, 1962). In analogy to the median eminence, viz. the neurohypophysis, these axon terminals may be considered the sites of release of neurohormonal substances (STERBA, LUPPA, SCHUHMACHER, 1965; FRIDBERG and BERN, 1968; etc.). The distal processes of the CSF contacting neurons which run to the surface of the spinal cord, seem to have the same morphological relation with the surface as the above mentioned structures. At the same time, the morphological substrate of the active substances produced by the CSF contacting nerve cells is also present in the form of the various granulated vesicles. Thus it may be suggested that the axon terminals on the outer surface of the spinal cord would act as sites of release of chemically active substances serving for the humoral mediation of informations taken up by the dendritic terminals from the CSF.

In contrast, other authors believe that the CSF contacting terminals of secretory nerve cells, e.g. those of the caudal neurosecretory system, serve to

release active substances into the CSF (FRIDBERG and NISHIOKA, 1966). Nevertheless, the structure of the CSF contacting terminals resembling that of receptors, seems to be more in support of a sensory function. This applies particularly to the spinal CSF contacting terminals, which contain secretory vesicles infrequently or not at all, and their special stereocilium-like processes filled with filaments do not show any morphological evidence of a secretory activity. The fact that the CSF contacting nerve ending is always found on the dendritic process of the neuron also seems to contradict a secretory function, the latter being generally associated with the neurite-like process, the dendritic one serving mostly as a receptor. Thus, on the basis of the morphological data known up to now, we suppose a receptor function of the CSF contacting terminals.

REFERENCES

1. AGHDUHR, E.: (1922) Über ein zentrales Sinnesorgan (?) bei den Vertebraten. Z. Anat. Entwickl.-Gesch. **66,** 223—360. — 2. ARNOLD, W.: (1970) Über eigentümliche neuronale Zellelemente im Ependym des Zentralkanals von Salamandra maculosa. Z. Zellforsch. **105,** 176—187. — 3. BAUMGARTEN, H. G., WARTENBERG, H.: (1970) Adrenergic Neurons in the Lower Spinal Cord of the Pike (Esox lucius) and their Relation to the Neurosecretory System of the Neurophysis spinalis caudalis. 5th Int. Symp. on Neurosecretion, Kiel. — 4. FRIDBERG, G.: (1962) Studies on the Caudal Neurosecretory System in Teleost. Acta zool. (Stockh.) **43,** 1—77. — 5. FRIDBERG, G., BERN, H. A.: (1968) The Urophysis and the Caudal Neurosecretory System of Fishes. Biol. Rev. **43,** 175—199. — 6. FRIDBERG, G., NISHIOKA, R. S.: (1966) Secretion into the Cerebrospinal Fluid by Caudal Neurosecretory Neurons. Science **152,** 90—91. — 7. KOLMER, W.: (1921) Das "Sagittalorgan" der Wirbeltiere. Z. Anat. Entwickl.-Gesch. **60,** 652—717. — 8. LEONHARDT, H.: (1968) Neurosekretorische Strukturen im IV. Ventrikel und Zentralkanal beim Kaninchen. Anat. Anz. Suppl. **121,** 95—102. — 9. STERBA, G., LUPPA, H., SCHUHMACHER, U.: (1965) Untersuchungen zur Funktion des kaudalen neurosekretorischen Systems beim Karpfen. Endokrinologie **48,** 25—39. — 10. TEICHMANN, I., VIGH, B.: (1968) Histochemical Investigation of the Monoamine-containing Neurons of the Paraventricular Organ and the Preoptic Recess of Amphibians (Rana esculenta, Ambystoma mexicanum). Acta biol. Acad. Sci. hung. **19,** 505. — 11. VIGH, B.: (1966) Das Paraventrikularorgan und das periventrikuläre System des Zentralnervensystems (Russ.). VII. Unionskongress der Anatomen, Histologen und Embryologen der SU, Tbilissi 1966. — 12. VIGH, B.: (1967) The Paraventricular Ependymal Organ, a Hypothalamic Receptor? Gen. comp. Endocr. **9** (3), 503. — 13. VIGH, B.: (1971) Das Paraventrikularorgan und das zirkumventrikuläre System. Studia Biologica Hungarica Vol. 10, Akadémiai Kiadó, Budapest. — 14. VIGH, B., TEICHMANN, I., AROS, B.: (1967) The "nucleus organi paraventricularis" as a Neuronal Part of the Paraventricular Ependymal Organ of the Hypothalamus. A Comparative Morphological Study in Various Vertebrates. Acta biol. Acad. Sci. hung. **18,** 271—284. — 15. VIGH, B., VIGH-TEICHMANN, I., AROS, B.: (1970) Ultrastructure of the CSF Contacting Neurons of the Spinal Cord in the Newt, Triturus cristatus. Acta morph. Acad. Sci. hung. (In press.) — 16. VIGH, B., VIGH-TEICHMANN, I., AROS, B.: (1971) Ultrastruktur der spinalen Liquorkontaktneurone beim Krallenfrosch (Xenopus laevis). Z. Zellforsch. **112,** 201—211. — 17. VIGH, B., VIGH-TEICHMANN, I., KORITSÁNSZKY, S., AROS, B.: (1970) Ultrastruktur der Liquorkontaktneurone des Rückenmarkes von Reptilien. Z. Zellforsch. **109,** 180—194. — 18. VIGH-TEICHMANN, I., RÖHLICH, P., VIGH, B.: (1969) Licht- und elektronenmikroskopische Untersuchungen am Recessus praeopticus-Organ von Amphibien. Z. Zellforsch. **98,** 217—232. — 19. VIGH-TEICHMANN, I., VIGH, B.: (1969) The Neurosecretory Preoptic Nucleus as a Member of the Liquor Contacting Neuronal System. Acta morph. Acad. Sci. hung. **17,** 338. — 20. VIGH-TEICHMANN, I., VIGH, B.: (1969) Liquor Contacting Neuronal Areas in the Periventricular Gray Substance of the Central Nervous System. Gen. comp. Endocr. **13,** 537. — 21. VIGH-TEICHMANN, I., VIGH, B.: (1970) Structure and Function of the Liquor Contacting Neurosecretory System. In: Aspects of Neuroendocrinology. (eds) W. BARGMANN and B. SCHARRER. Berlin—Heidelberg—New York, Springer, Pp. 329—337. — 22. VIGH-TEICHMANN, I., VIGH, B., AROS, B.: (1970) Enzymhistochemische

Studien am Nervensystem. IV. Acetylcholinesteraseaktivität im Liquorkontakt-Neuronensystem verschiedener Vertebraten. Histochemie **21,** 322—337. — 23. VIGH-TEICHMANN, I., VIGH, B., AROS, B.: (1971) Liquorkontaktneurone im Nucleus infundibularis des Kükens. Z. Zellforsch. **112,** 188—200. — 24. VIGH-TEICHMANN, I., VIGH, B., KORITSÁNSZKY, S.: (1970) Liquorkontaktneurone im Nucleus paraventricularis. Z. Zellforsch. **103,** 483—501. — 25. VIGH-TEICHMANN, I., VIGH, B., KORITSÁNSZKY, S.: (1970) Liquorkontaktneurone im Nucleus lateralis tuberis von Fischen. Z. Zellforsch. **105,** 325—338. — 26. VIGH-TEICHMANN, I., VIGH, B., KORITSÁNSZKY, S., AROS, B.: (1970) Liquorkontaktneurone im Nucleus infundibularis. Z. Zellforsch. **108,** 17—34.

ELEKTRONENMIKROSKOPISCHE STRUKTUR DES SPINALEN LIQUORKONTAKT-NEURONSYSTEMS IN WEISSEN LEGHORNKÜKEN

B. VIGH, I. VIGH-TEICHMANN, S. KORITSÁNSZKY und B. AROS

An der Basis der Ependymzellen des Zentralkanals finden sich bipolare Nervenzellen, ihr Dendrit verläuft zwischen den Ependymzellen, dringt in das Lumen des Zentralkanals ein und bildet dort eine charakteristische Nervenendigung. Die Endigung besteht aus einem zentralen Körper, von dem zahlreiche, stereociliumartige Fortsätze in verschiedene Richtungen in den Liquor eindringen und in einzelnen Fällen den Reissnerschen Faden erreichen. Die Fortsätze sind 1,5 bis 2 μ breit und 20 bis 25 μ lang, an den Enden werden sie schmäler. Sie enthalten große Massen von Filamenten, die sich in das Innere der Liquorkontaktendigung fortsetzen. In der Endigung sind neben den Filamenten Neurotubuli, endoplasmatisches Retikulum von glatter Oberfläche, selten ein multivesikuläres Körperchen und granulierte Bläschen nachweisbar. In der Endigung befindet sich darüber hinaus ein Basalkörperchen und ein akzessorisches Basalkörperchen. Aus dem Basalkörperchen entspringt ein Flimmerhaar, ferner eine weniger entwickelte Flimmerwurzel. Das Flimmerhärchen tritt aus der Mitte der trichterförmigen Vertiefung der Nervenendigung aus und dringt gleichfalls in den Liquor ein. Seine Struktur zeigt den Aufbau einer normalen Kinozilie ($9 \times 2 + 2$). An der Stelle, wo die Liquorkontakt Nervenendigung in den Dendriten des Neurons übergeht, wird sie an die benachbarten Ependymzellen mit Hilfe von Desmosomen fixiert. Im Dendriten lassen sich zahlreiche diffus verlaufende Neurotubuli, endoplasmatisches Retikulum von grober und glatter Oberfläche, Mitochondrien, granulierte Bläschen und an der Ursprungsstelle des Fortsatzes Golgi-Felder aufzeigen. An beiden Seiten des Fortsatzes liegen Axonüberkreuzungen, die mit dem Dendriten eine synaptische Verbindung herstellen. Im präsynaptischen Gebiet finden sich außer den synaptischen und dense-core-Vesikeln auch Mitochondrien. Das Perikaryon ist hell, seine Elektrondensität ist gering, es enthält in erheblicher Menge endoplasmatisches Retikulum von grober Oberfläche, ferner Mitochondrien, Golgi-Felder und granulierte Bläschen der Größenordnung von 1300 Å. Am Perikaryon finden sich axosomatische Synapsen, und im präsynaptischen Teil sind außer den Mitochondrien und synaptischen Bläschen auch dense-core-Vesikel erkennbar (750 Å). Der distale Fortsatz des Perikaryons ist schmal, in ihm verlaufen Mikrotubuli. An seiner Ursprungsstelle lagern sich synapsenbildende, dense-core-Vesikel enthaltende Axone an das Perikaryon an. Der distale Fortsatz ist von Neuropil umgeben, in dem axo-dendritische Synapsen auftreten. Einzelne Fasern- und Synapsengruppen werden von Gliazellen zu kleineren Einheiten zusammengefaßt. Die den Zentralkanal auskleidenden Ependymzellen sind elongiert, sie bilden mehrere Reihen. Auf Grund der Plasma-Densität lassen sich zwischen ihnen dunkle und helle Zellen unterscheiden. Anhand des morphologischen Bildes werden die einzelnen Hypothesen über die Rolle des spinalen Liquorkontakt-Neuronensystems diskutiert.

ЭЛЕКТРОНОМИКРОСКОПИЧЕСКАЯ СТРУКТУРА НЕЙРОНОВОЙ СИСТЕМЫ, СОЗДАЮЩЕЙ КОНТАКТ СО СПИННОМОЗГОВОЙ ЖИДКОСТЬЮ, У ЦЫПЛЯТ ПОРОДЫ ЛЕГГОРН БЕЛЫЙ

Б. ВИГ, И. ВИГ-ТЕЙХМАНН, Ш. КОРИТШАНСИИ и Б. АРОШ

У основания эпендимальных клеток находятся биполярные нервные клетки, центральный отросток которых проходит среди эпендимальных клеток и входит в просвет центрального канала, образуя там характерное нервное окончание. На ликвоконтактном окончании сидят многочисленные крупные отростки, напоминающие ворсинки, которые в

разных направлениях входят в спинномозговую жидкость, постигая подчас Рейсснеровые волокна. Ширина отростков 1,5—2 микрона, их длина составляет 20—25 микронов, к концамм они суживаются. Они содержат значительную массу филаментов, которые во внутренней части ликвороконтактного окончания продолжаются в виде тяжки: В окончаниях наряду с филаментами выявляемы также нейротрубочки, эндоплазматическая сеточка с гладкой поврехностью, изредка мультивезикулярное тельце и зернистые пузырьки. В окончании расположены кроме того и базальное тельце и добавочное базальное тельце. Из базального тельца исходит ресница, а также мало развитый мерцательный корешок. Ресница выходит из середний воронкообразного углубления нервного окончания и проникает также в спинномозговую жидкость. Ее структура показывает нормальное строение двигательных ресниц ($9\times2+2$). На месте перехода ликвороконтактного окончания в центральный отросток нейрона оно прикреплено к соседним эпендимальным клеткам при помощи десмосом. В центральном отростке расположены многочисленные, диффузно, проходящие нейротрубочки, эндоплазматическая сеточка с грубой и гладкой поверхностями, митохондрии, зернистые пузырьки, а у места выхода отростка видны поля Гольджи. По двум сторонам отростка лежат аксоновые перекращивания, вступающие в синаптическую связь с центральным отростком. В предсинаптической области кроме синаптических и пузырьков dense core обнаруживаются также митохондрии. Перикарион светлый, обладает незначительной электронной гистотой, он содержит значительное количество эндоплазматической сеточки с грубой поверхностью, а ткаже митохондрии, поля Гольджи и зернистые пузырьки порядка величины в 1300 Å. На перикарионе видны аксосоматические синапсы, и в предсинаптической части присутствуют, наряду с митохондриями и синаптическими пузырьками, также пузырьки dense core (750 Å). Дистальный отросток перикариона узкий, в ней проходят тяжки нейротрубочек. У места начала отростка к перикариону прилегают аксоны, содержащие dense core пузырьки и образующие синапсы. Около дистального отростка выявляемы многочисленные перекрещивания отростков, образующие несколько аксонодендритовых синапсов. Между волокнами расположены многочисленные очень тонкие перекрещивания аксонов. Клетки невроглии соединяют отдельные группы волокон и синапсов в небольшие единицы. Эпендимальные клетки, выстилающие центральный канал, удлинены, они образуют несколько рядов, среди них, на основе плотности плазмы, можно обособлять темные и светлые клетки. На основе морфологической картины обсуждаются гипотезы, выдвигаемые относительно роли системы, создающей связь со спинномозговой жидкостью.

Dr. Béla Vigh
Dr. Ingeborg Teichmann
Dr. Sára Koritsánszky
Dr. Béla Aros

Szövettani Intézet,
Budapest IX., Tűzoltó u. 58,
Hungary

Acta Morphologica Acad. Sci. Hung. 19 (1), pp. 25–41, 1971

Institute of Histology and Embryology (Head: I. Törő), Semmelweis University Medical School, Budapest

LIGHT AND ELECTRON MICROSCOPIC STRUCTURE OF THE PREOPTIC RECESS ORGAN IN THE NEWT (TRITURUS CRISTATUS)

I. Vigh-Teichmann, B. Vigh and B. Aros

(Received July 25, 1970)

The preoptic recess organ is situated rostrally to the neurosecretory preoptic nucleus, in the parvocellular preoptic area, on both sides of the preoptic recess of the third ventricle. The organ is composed of cylindrical ependyma and of a characteristic group of neurons. These nerve cells are arranged intraependymally and in several rows beneath the ependymal cells. Part of the neurons are bipolar, sending one process to the preoptic recess and forming there special nerve endings, termed by us CSF contacting terminals. Light-microscopically, the intraependymal and hypendymal cells stain dark, while the distal cells stain light with toluidine blue azure II. Electron microscopy reveals that the CSF contacting terminals of the dark neurons are relatively large, they contain smooth and rough surfaced endoplasmic reticulum, as well as dense-core vesicles 900 Å in diameter. The CSF contacting nerve terminals of the light cells are smaller, they contain several mitochondria and granules 1400 Å in diameter. Every intraventricular nerve ending bears an atypical cilium ($9 \times 2 + 0$ tubules). The ventricular process of the neurons is dendritic, the distal one has neurite character. The perikaryon of the dark intraependymal and hypendymal nerve cells contains well-developed ergastoplasm with free ribosomes, Golgi area, mitochondria and numerous dense-core vesicles 900 Å in size. There are synapses on the perikaryon, the ventricular and distal processes; in their presynaptic area there are synaptic vesicles as well as dense-core vesicles 800 to 900 Å in diameter. The larger light cells forming the distal neuron rows, contain granules 1400 Å in size, and less free ribosomes, otherwise the fine structure of these perikarya is similar to that of the hypendymal dark cells. The neurons are embedded in a neuropil. The fibrous layers situated between the hypendymal and distal neurons, and laterally to the distal cells, are synaptic zones. The two kinds of neurons, of their CSF contacting nerve terminals and of their granules suggest that the preoptic recess organ consists of two functional different components.

Introduction

The preoptic recess organ, as described by us in the frog and the axolotl (Teichmann and Vigh, 1968; Vigh-Teichmann, 1968) corresponds to the parvocellular part of the preoptic area. In the neurons of this territory, monoamines were demonstrated by fluorescence histochemical method (Vigh-Teichmann, Vigh and Aros, 1969). The monoamine-containing cells emit CSF contacting nerve endings between the special, usually multilayered ependymal cells. As the area resembles in structure the paraventricular organ, we have termed it preoptic recess organ and assumed that, like the other CSF contacting

areas, it would act as a receptor, establishing a direct informative connection between the CSF and the central nervous system (VIGH, TEICHMANN and AROS, 1969; VIGH, 1971). Later, acetylcholinesterase-positive CSF contacting nerve cells were demonstrated in this area (VIGH-TEICHMANN, VIGH and AROS, 1970). The enzyme-containing cells are apparently identical with the distal neurons of the preoptic recess organ, while the intraependymal and hypendymal nerve cells show the induced fluorescence characteristic of monoamines.

Electron microscopy revealed that the CSF contacting nerve-endings are characterized by atypical cilia, dense-core vesicles and mitochondria (VIGH-TEICHMANN, RÖHLICH and VIGH, 1969). The preoptic recess organ was demonstrated by light microscopy in the anurans *Rana esculenta*, *Rana arvalis*, *Rana ridibunda*, *Bufo bufo*, *Bombinator igneus and in the urodela Pleurodeles waltlii*, *Ambystoma mexicanum and Triturus vulgaris*. The CSF contacting neurons of the organ, which is well-developed particularly in amphibians, occur in all probability also in fishes and higher vertrebrates. Independently from us, BRAAK (1970), too, described the fluorescence microscopic appearance of the preoptic area in the frog. His findings fully agree with our earlier observations.

As data concerning the ultrastructure of the parvocellular preoptic area of tailed amphibians are lacking, the present paper deals with the fine structure of this territory in *Triturus cristatus*.

Material and method

The animals were perfused through the aorta with 6% dextran in 0.9% NaCl for 20 sec, then fixed in 5% glutaraldehyde in 0.1 M phosphate buffer, pH 7.2, for 15 to 20 min. The brain was removed, the preoptic area excised and fixation continued up to two hours. The material was post-fixed in 1% OsO_4 dissolved in buffer, at 4 °C for 2 hours, dehydrated in ethanol and embedded in Araldite. Ultrathin sections were cut with a Reichert OMU-2 ultramicrotome, contrasted with methanolic uranyl acetate and lead citrate and examined with a JEM 6C electron microscope. Semi-thin sections were stained with toluidine blue-azure II.

Results

Light microscopic structure. The frontal part of the preoptic area, anterior to the preoptic nucleus, contains a group of small neurons, lying closely beneath the ependyma. Most of the nerve cells are arranged in 5 to 7 rows parallel to the ependyma. Only some neurons penetrate in between the ependymal cells. The hypendymal nerve cells are situated closely side-by-side, while the cells of the distal rows are localized more diffusely. The hypendymal neurons are smaller than the distal ones; their size increases from row to row. In contrast to the distal nerve cells, the intraependymal and hypendymal neurons appear dark with toluidine blue-azure II. Dark blue cells occur at sites also

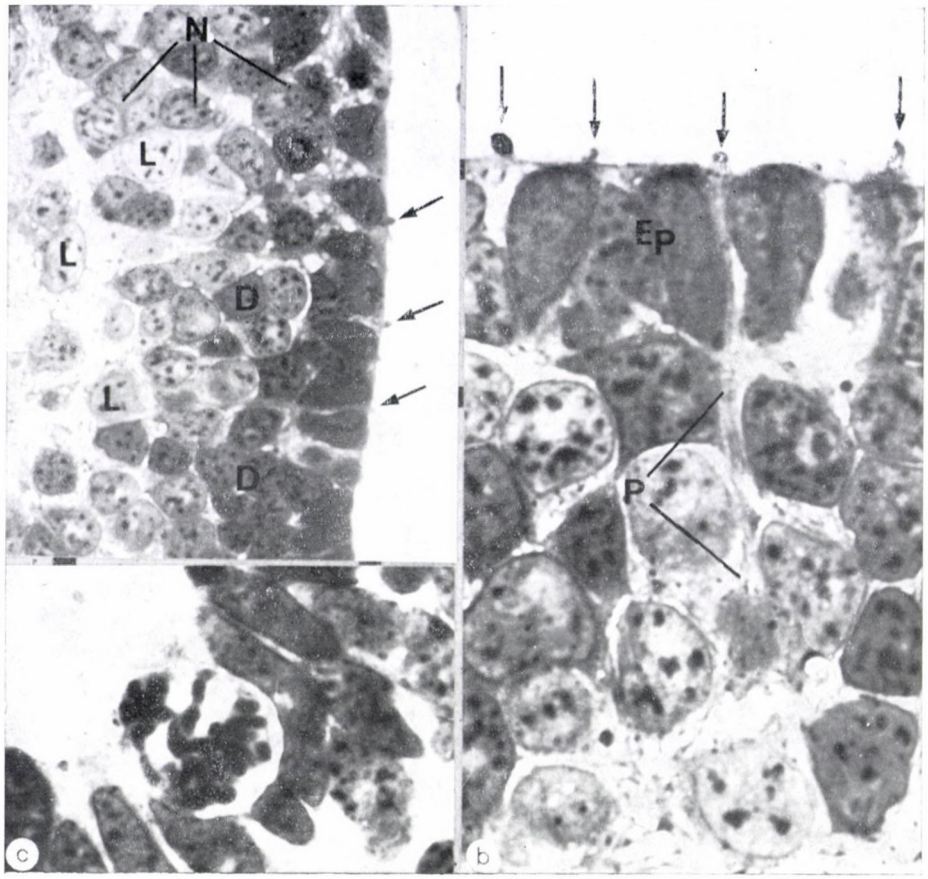

Fig. 1a. Neuron rows (N) and CSF contacting nerve endings (arrows) of the preoptic recess organ. D: dark neurons. L: light neurons. Toluidine blue-azure II. ×450. *b.* High power view of ventricular process (P) of a distal neuron. At arrows CSF contacting nerve terminals in the preoptic recess. Ep: ependyma. Toluidine blue-azure II staining. ×1120. *c.* Mitosis from the lower lateral part of the wall of the preoptic recess. Toluidine blue-azure II staining. ×1120

among the distal rows (Fig. 1a). Part of the nerve cells emitting one branch to the ventricle, are bipolar. Their ventricular process passes through between the ependymal cells and enters the preoptic recess to form there a free club-like terminal (Fig. 1b). The nerve endings occur scattered over the wall of the preoptic recess, dorsally up to the anterior commissure and ventrally also at the floor of the recess. The neurons are embedded in a neuropil which forms a small fibrous zone hypendymally and a broad one distally to the fourth row of neurons. It is remarkable that even in the adult animal there are mitotic cells in the ependyma (Fig. 1c) and between the neurons of the area, first of all in its basal part.

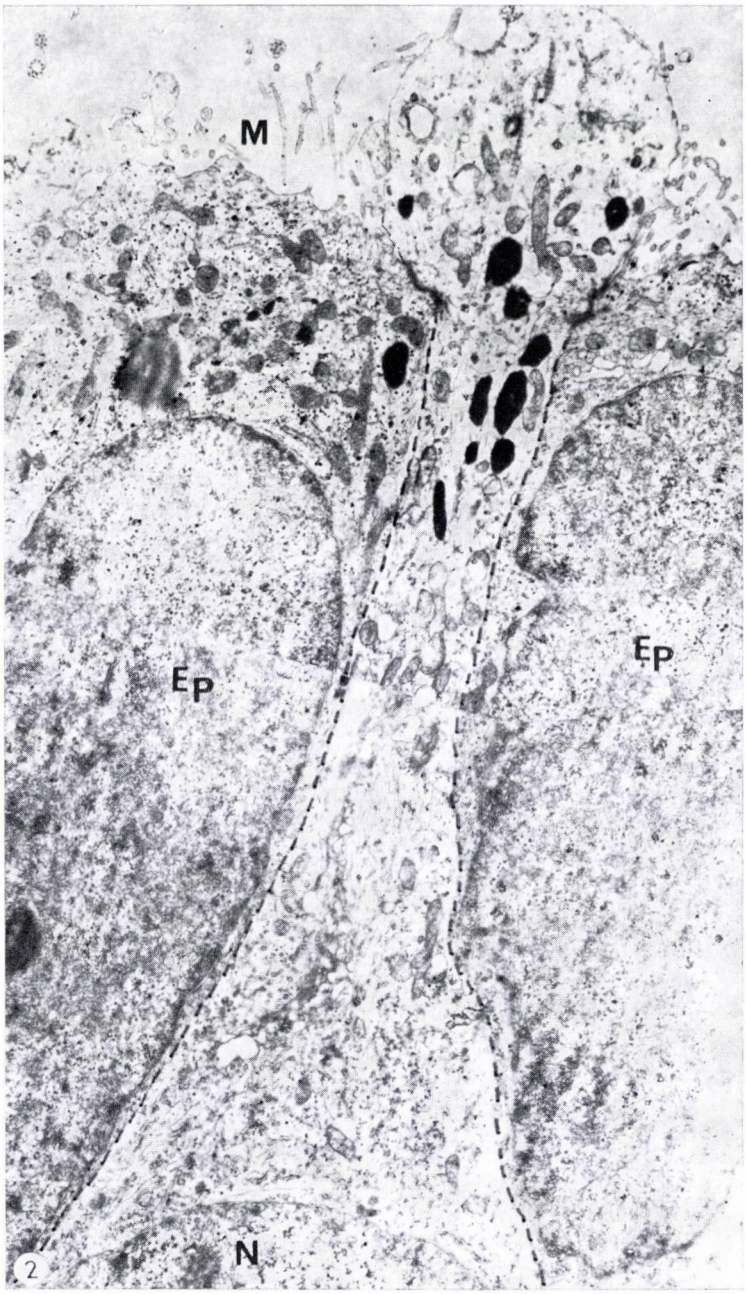

Fig. 2. Part of a hypendymal neuron (dotted line) with ventricular process and club-like CSF contacting nerve ending. Ep: ependymal cells. N: nucleus of neuron. M: ependymal microvilli. Montage, ×7980

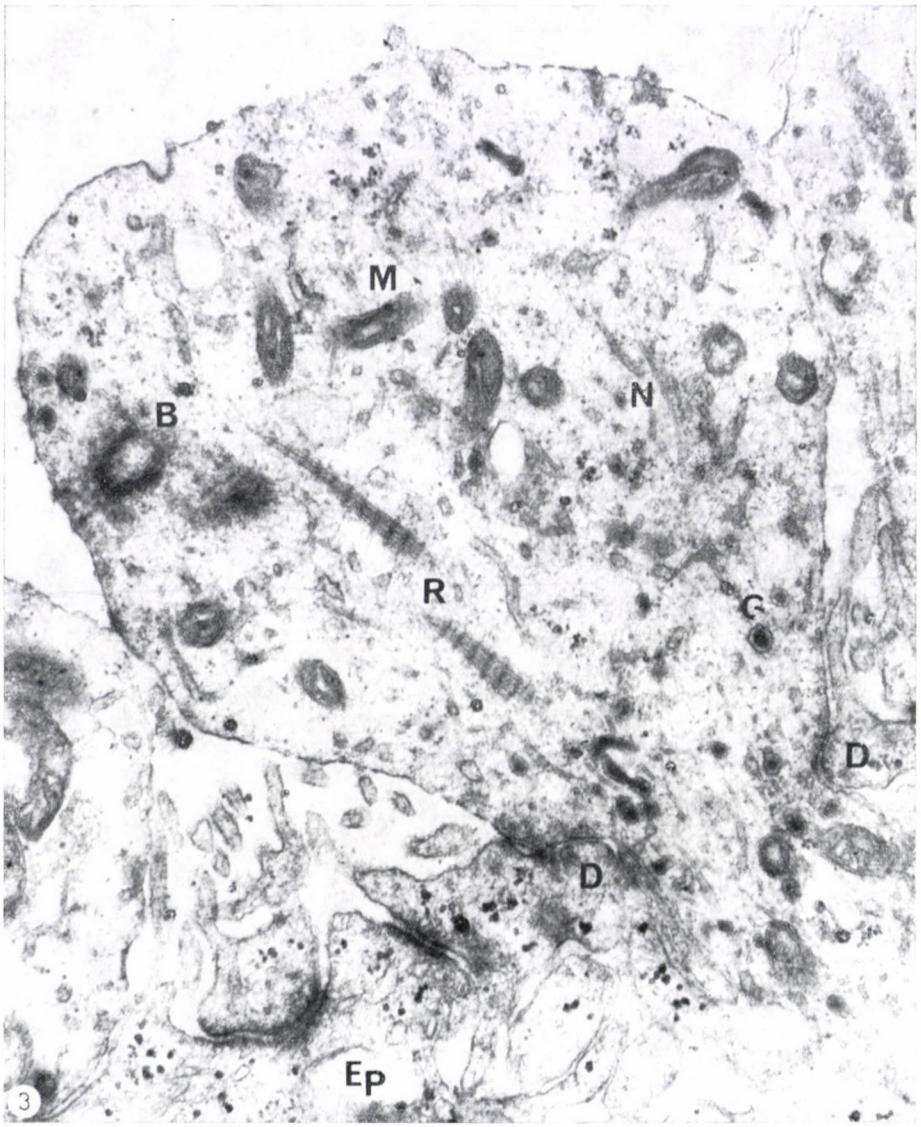

Fig. 3. CSF contacting nerve terminal from preoptic recess organ. B: basal body. D: desmosome. Ep: ependymal cell. G: dense-core vesicles. M: mitochondria. N: neurotubules. R: rootlet fibre. ×37 500

Electron microscopic structure. Ependyma. The ependymal cells are elongated, cylindrical, with elongated nuclei rich in chromatin. The cells contain a well-developed endoplasmic reticulum, free ribosomes and Golgi-areas, as well as many mitochondria and a considerable amount of glycogen

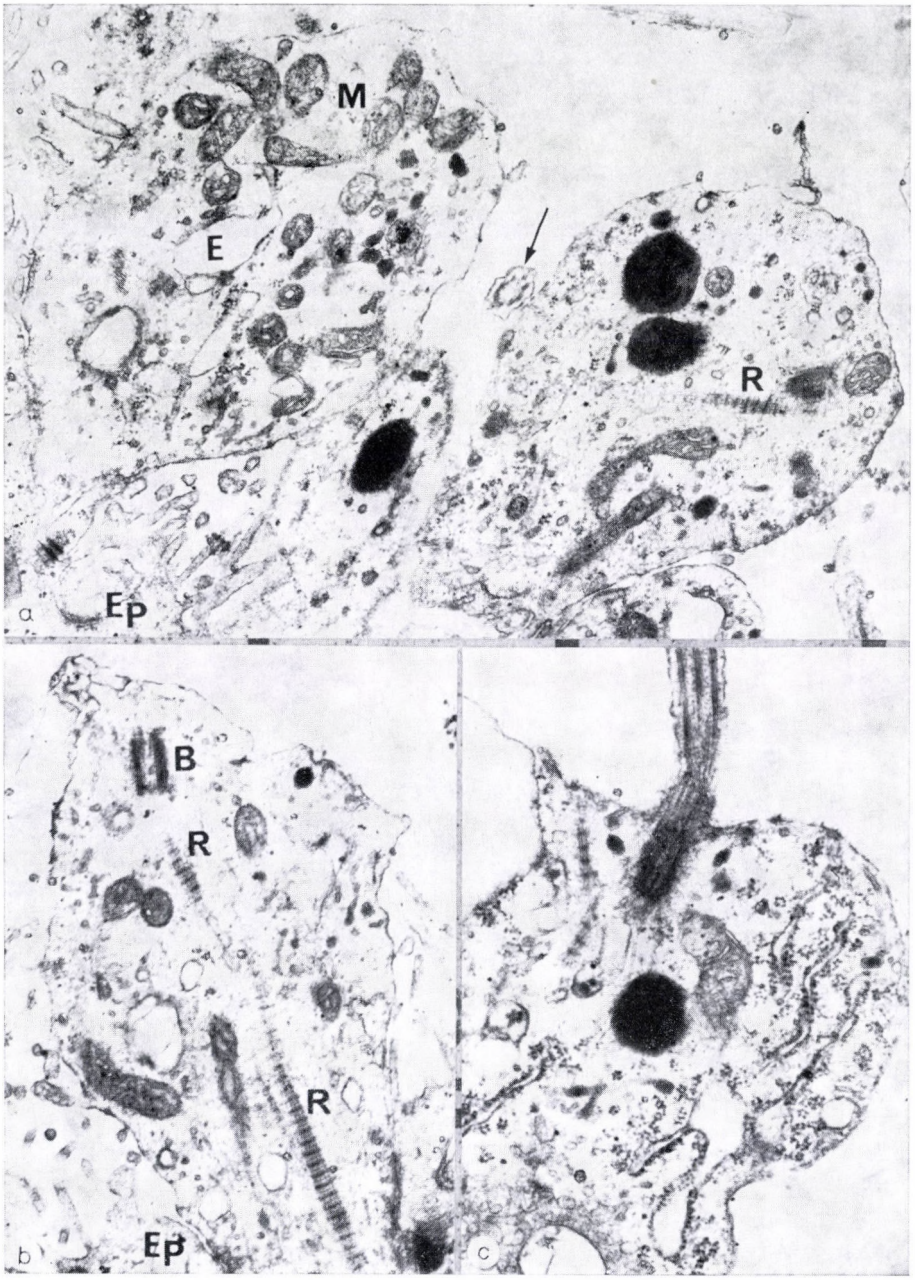

Fig. 4a. Two different, light and dark, intraventricular nerve endings side by side. E: endoplasmic reticulum. Ep: ependyma. M: mitochondria. R: rootlet fibre. Arrow: atypical cilium ($9 \times 2 + 0$). $\times 20\,500$. *b.* Dark CSF contacting nerve terminal with basal body (B) and rootlet fibres (R). Ep: ependymal cell surface. $\times 21\,500$. *c.* Part of a dark CSF contacting terminal containing a large amount of rough-surface endoplasmic reticulum and dense-core vesicles. C: cilium with basal body and slim rootlet fibres. $\times 26\,250$

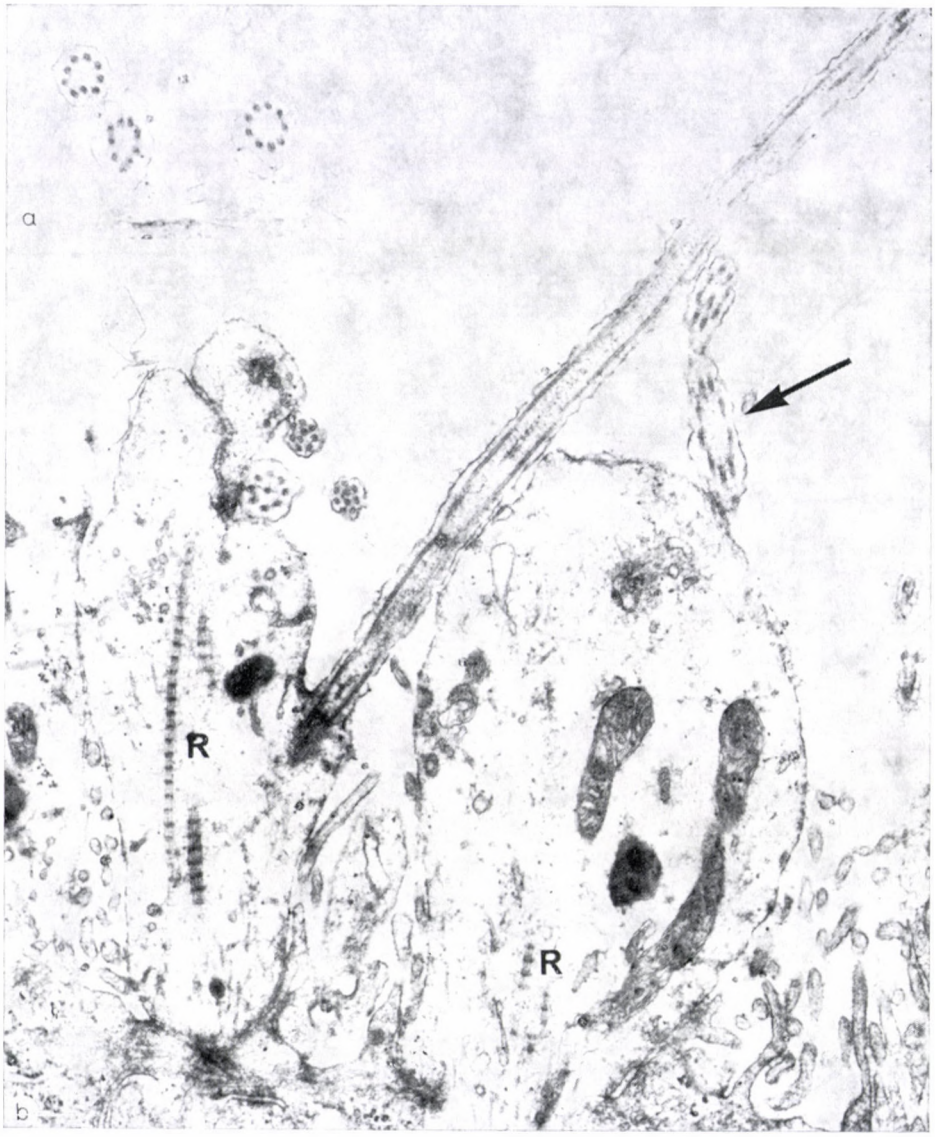

Fig. 5a. Cross-section of atypical cilia (9 × 2 + 0). × 11 200. *b.* Longitudinal section of a cilium arising from a CSF contacting nerve ending. R: rootlet fibre. Arrow: atypical cilium (9 × 2 + 0). × 23 750

granules. There are numerous microcilli on the cell surface, especially around those sites where the nerve terminals enter the CSF.

The CSF contacting nerve endings are formed by the ventricular nerve processes, they protrude into the CSF one by one or in small groups (Figs 3, 4a). The arrangement in groups is particularly marked in the ventral half of the

preoptic recess. In general, the terminals contain endoplasmic reticulum, mitochondria, as well as microtubules coming from the ventricular process into the ending and diverging there radially. In part of the endings there are more, in others less mitochondria. The terminals containing more mitochondria are relatively small, and are characterized by granulated vesicles of 1400 Å in size (Fig. 4a) and by less free ribosomes. Thus, the whole nerve ending appears electronlucent. In other intraventricular terminals, we observed a more electrondense cytoplasm with numerous free ribosomes and also rough-surfaced endoplasmic reticulum. These nerve endings are larger and contain dense-core vesicles 800 to 1000 Å in diameter (Figs 4a, b, c).

In both kinds of nerve endings there is a basal body (Fig. 4b) as well as an accessory basal body; from the basal body a cilium arises (Figs 4c, 5b). This cilium is atypical in structure ($9 \times 2 + 0$ tubules, Fig. 5a). The basal bodies emit well-developed rootlet fibres which may be followed over a long distance into the ventricular process of the CSF contacting neurons (Figs 6a, b). Coated vesicles often in contact with the surface, may be found in the intraventricular nerve terminal as well as in the apical part of the ependymal cells (Figs 6a, c, d).

Ventricular processes of the CSF contacting neurons. The ventricular process is dendritic in character. We found in it losely arranged microtubules, numerous mitochondria, and near the perikaryon rough-surfaced endoplasmic reticulum and Golgi-areas. The rootlet fibres of the cilia originating from the CSF contacting terminal, run in the ventricular process (Figs 7a, b). In some cases, we observed a basal body also in the ventricular dendrite (Fig. 7b). At sites, long mitochondria and dense-core vesicles are visible (Fig. 7b). The ventricular processes run alone or in small bundles toward the ependyma. When several dendrites run side by side, they may form small bundles, but near the ventricular surface, ependymal cell parts are usually inserted between them (Fig. 7a). The ventricular dendrites are fixed by desmosomes to the apical portion of the adjacent ependymal cells (Figs. 2, 3, 4b, 5, 6, 7a). Synapses can be observed on the dendrites near their origin from the perikaryon. The presynaptic area contains synaptic and some dense-core vesicles 900 Å in size. The ventricular processes belonging to the different types of neurons are essentially similar in structure, except that those coming from the hypendymal cells are thicker than those starting from the distal cells.

Perikaryon of the intra- and hypendymal CSF contacting neurons. The cytoplasm of the intraependymal and hypendymal neurons is electrondense, due to the presence of a well-developed smooth and rough-surfaced endoplasmic reticulum as well as free ribosomes. Furthermore, one can find mitochondria, Golgi-areas and microtubules. In the perikaryon there is a large number of dense-core vesicles measuring 900 Å (Fig. 8a). Most of the granules are oval or elongated (Fig. 8c). On the perikarya, axo-somatic synapses are

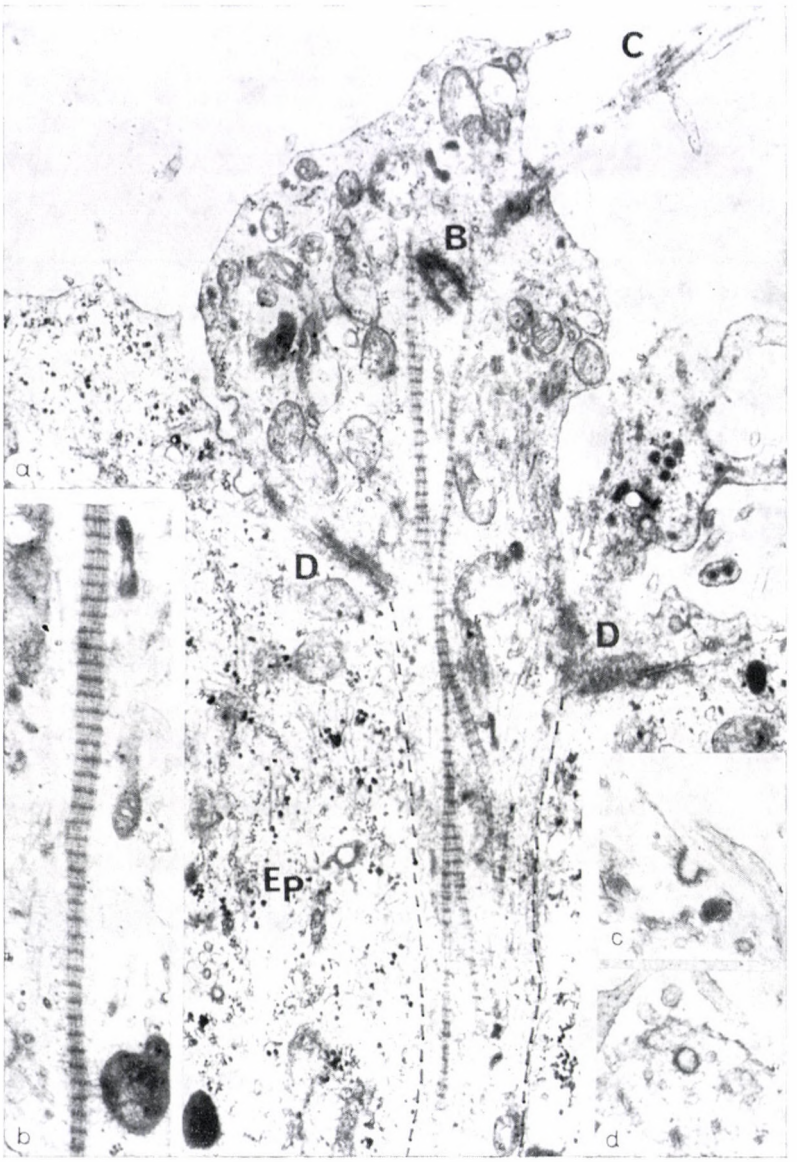

Fig. 6a. Multiple rootlet fibres in CSF contacting nerve ending and ventricular dendrite (dotted). B: basal body. C: cilium. D: desmosome. Ep: ependymal cell. ×22 750. *b.* High power view of rootlet fibre. ×28 000. *c.* Connection of coated vesicle with cell membrane of nerve ending. ×23 000. *d.* Coated vesicle. ×23 000

visible. Their presynaptic cytoplasm contains synaptic and dense-core vesicles 900 Å in size (Fig. 8b).

The *distal process of the intraependymal and hypendymal* CSF contacting neurons is smaller in diameter than the ventricular dendrite. There are microtubules, mitochondria and dense-core vesicles in it and synapses on the initial

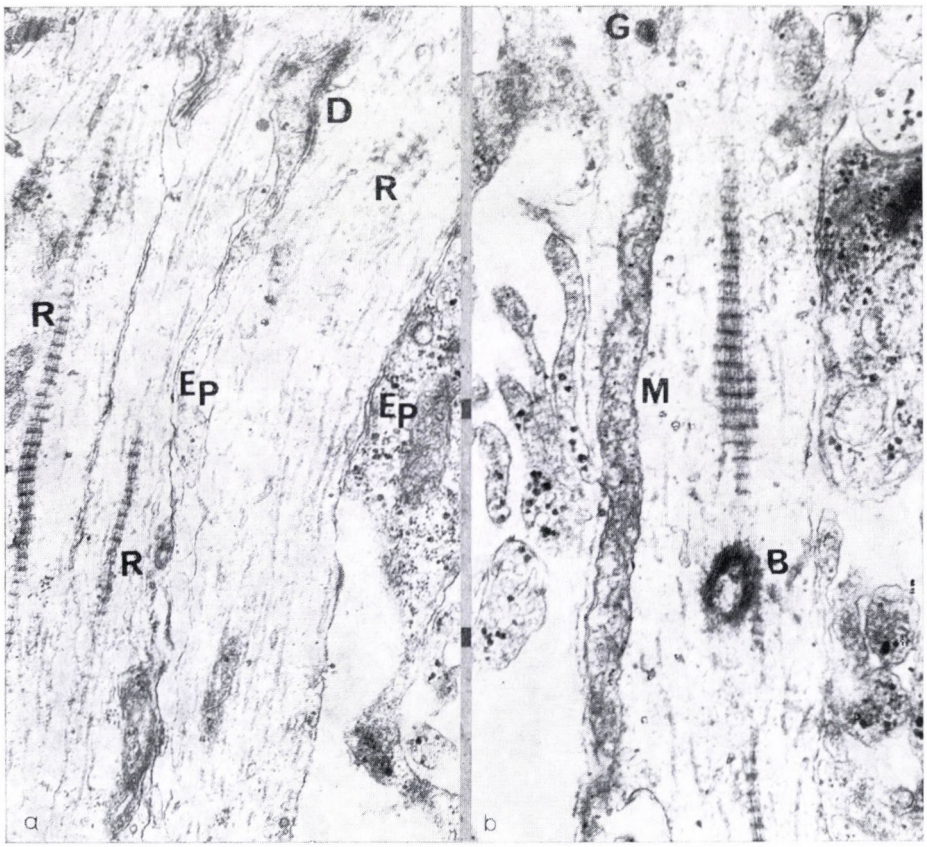

Fig. 7a. Several ventricular dendrites situated side by side near the ventricular surface. D: desmosome. Ep: ependyma. R: rootlet fibres. ×23 750. *b.* Accessory basal body (B) and rootlet fibre in ventricular dendrite. G: dense-core vesicle. M: mitochondrium of unusual length. ×28 000

part of the process. In the presynaptic area there occur synaptic vesicles of about 500 Å and dense-core vesicles of 850 Å.

The distal neurons are larger than those found intraependymally and hypendymally, and contain less endoplasmic reticulum. The perikarya also enclose electrondense granulated vesicles which differ with their diameter of about 1400 Å (Fig. 9a) from that of the dense-core vesicles (900 Å in size)

of the dark intraependymal and hypendymal nerve cells. Otherwise, the structure of the cytoplasm resembles that of the neurons described above. The ventricular dendrite of the distal nerve cells runs toward the ependyma and enters the ventricle. The processes of the cells lying far away from the preoptic recess could not be followed continually into its lumen. The axons of the distal

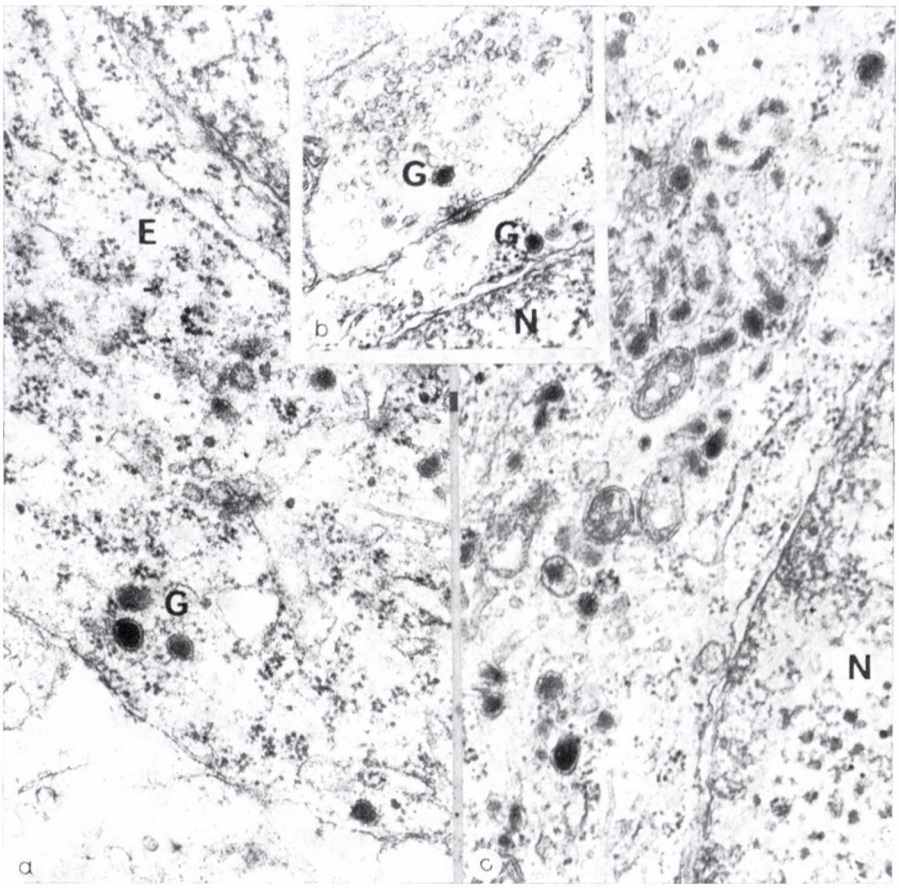

Fig. 8a. Part of the perikaryon of a hypendymal neuron. E: rough-surfaced endoplasmic reticulum. G: dense-core vesicles. ×45 000. *b.* Synapse on the perikaryon of a hypendymal cell. G: dense-core vesicle. N: nucleus. ×37 500. *c.* Perikaryon of an intraependymal neuron with numerous elongated dense-core vesicles. N: nucleus. ×45 000

neurons pass ependymofugally and contain mitochondria and parallel microtubules (Fig. 9b). At the initial part of the axon, synapses can be observed.

Neuropil. The neuropil surrounding the nerve cells, forms a small proximal or hypendymal synaptic zone between the two types of neuron layers as well as a broad distal synaptic zone laterally to the distal neurons. In the two

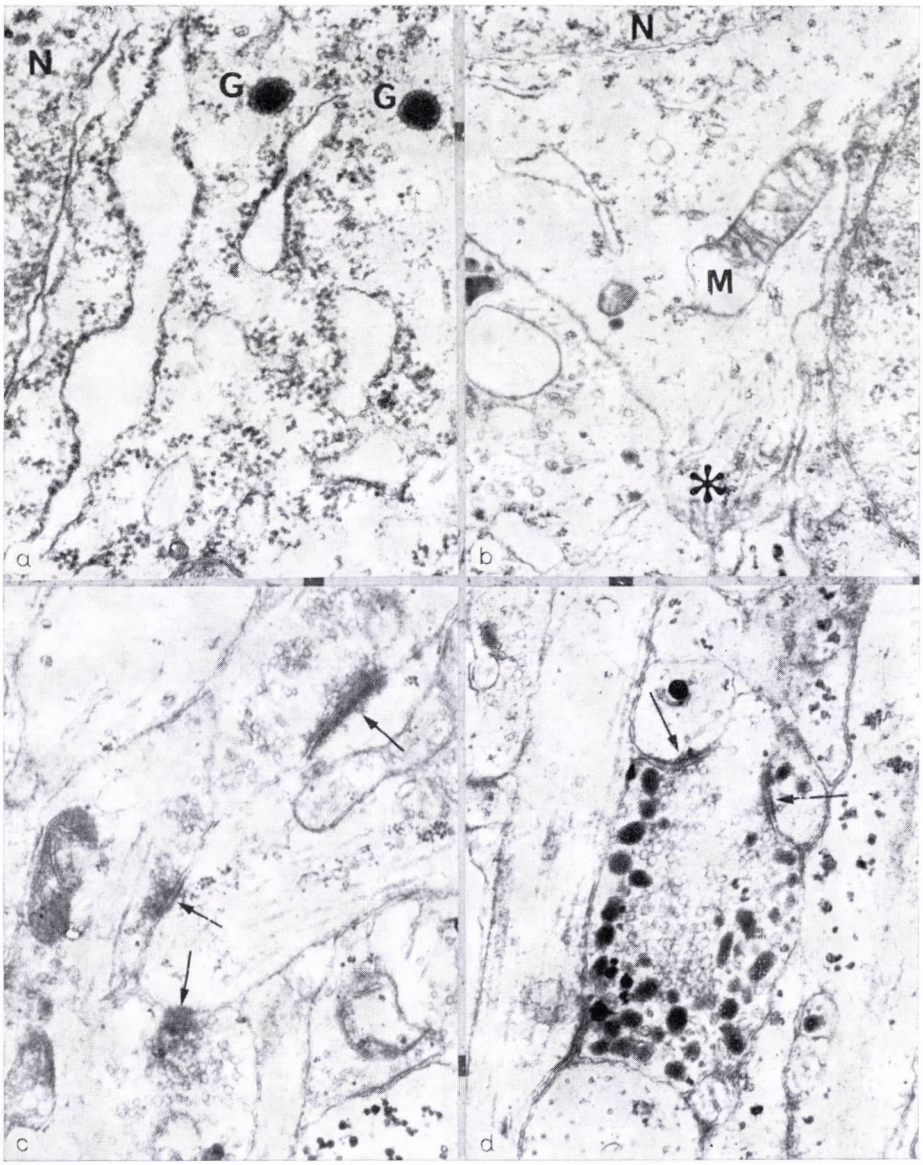

Fig. 9a. Part of the perikaryon of a distal neuron, with rough-surfaced endoplasmic reticulum. G: granulated vesicle. N: nucleus. 45 000×. *b.* Origin of neurite of distal neuron (asterisk). M: mitochondrium. N: nucleus. ×21 500. *c.* Synapses (arrows) in the hypendymal neuropil. × 30 000. *d.* Part of the distal neuropil, at arrows synapses. ×30 000

synaptic zones, axo-dendritic synapses occur first of all. In the presynaptic area, we found synaptic vesicles, mitochondria, sometimes small (600 to 700 Å), sometimes large (900 Å) dense-core vesicles (Fig. 9c, d). The axons containing small dense-core vesicles occur mainly in the distal neuropil.

Discussion

According to the present findings, the pattern found in the preoptic recess organ of tailed amphibians (Fig. 10) is similar to that in the frog (VIGH-TEICHMANN, 1968; VIGH-TEICHMANN, RÖHLICH and VIGH, 1969). The preoptic area is characterized by the small neurons forming CSF contacting nerve endings. The nerve cells occur in several rows intraependymally and hypendymally. The ventricular dendrite of the intraependymal and hypendymal neurons may readily be followed up to the free nerve terminals protruding into the CSF. On the other hand, the ventricular processes of remote neuron rows cannot be tracted in their entire length. It seems likely, however, on grounds of the semithin sections, that the second to fourth cell rows under the ependyma are also in connection with the ventricular lumen. In earlier studies made with acetylcholinesterase reaction in various frog species, we found that also the ventricular processes coming from the distal cell rows and clearly demonstrable by the enzyme reaction, form free club-like endings in the preoptic recess (VIGH-TEICHMANN and VIGH, 1969a, b; VIGH-TEICHMANN, VIGH and AROS, 1970). It is, however, possible that the process of the cells situated farthest away from the ventricle, runs merely to the hypendymal synaptic zone and forms synapses there.

We have observed the cross-sections of the distal, neurite-like processes of the intraependymal and hypendymal neurons in the external fibrous zone where they form synapses. Similar fibres form also axo-somatic synapses, thus there seem to be multiple synaptic connections between the various cell rows. In the synapses there are not only such dense-core vesicles as found in the hypendymal perikaryon, but also smaller ones, 600 to 700 Å in size, mainly in the distal synaptic zone. It is possible that, like in the other CSF contacting areas, here, too, there are monoaminergic axons coming from outside, suggesting the possibility of informative connections with other aminergic nuclei of the brain. We did not succeed in demonstrating any connections between these axons and the CSF contacting nerve terminals themselves, although in reptiles we have found such synaptic contacts in large number in the paraventricular and infundibular nucleus and in fishes in the lateral tuberal nucleus (VIGH-TEICHMANN et al., 1970a, b, c). The absence of intraventricular synapses suggests that the areas mentioned and the CSF contacting nerve endings of the preoptic recess organ differ in function. The absence of synapses may also

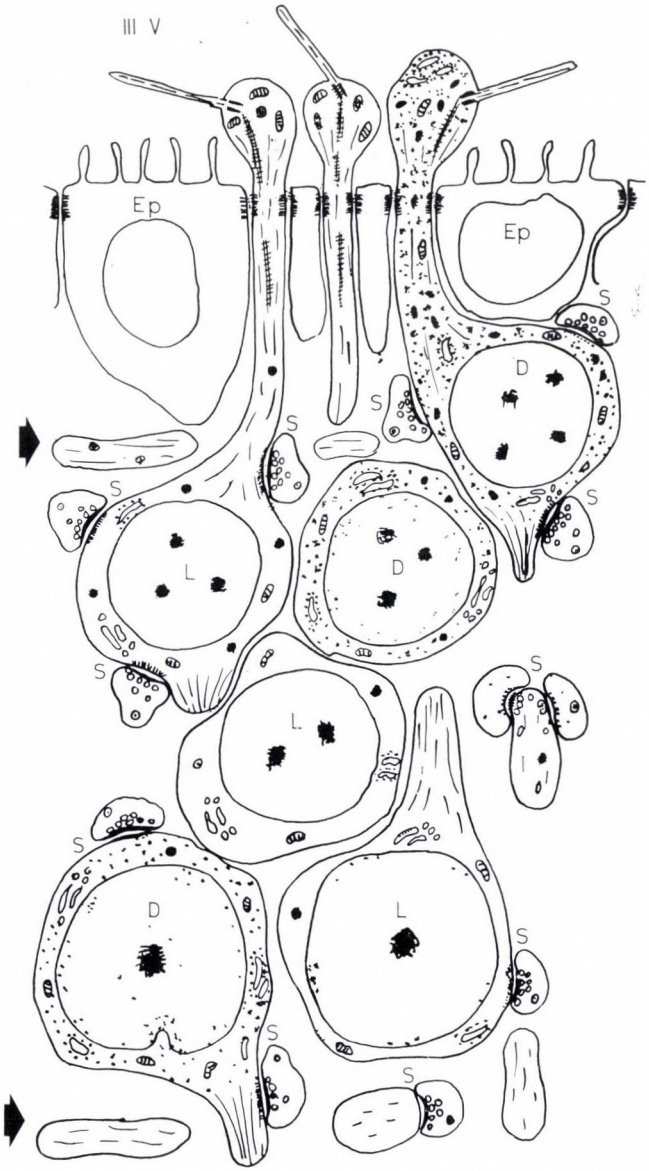

Fig. 10. Scheme of the architecture of the preoptic recess organ. Arrows point at hypendymal and distal synaptic zone. D: dark neurons. Ep: ependymal cell. III V: lumen of preoptic recess of third cerebral ventricle. L: light neurons. S: synapses

be correlated with the lower differentiation of the parvocellular preoptic area in amphibians. It seems noteworthy to mention once more the mitoses found in this territory of adult animals, the mitotic cells indicating the preoptic area to have a high regenerative ability (KIRSCHE, 1967; RICHTER, 1969).

It is interesting that the granulated vesicles in the perikarya are of two sizes; the vesicles in the dark, intraependymal and hypendymal cells measure 900 to 1000 Å in size, while those in the light, distal cells attain as much as 1400 Å. This agrees with our earlier finding that monoamine fluorescence could be localized in the first place to the neurons between and under the ependymal cells. The monoamine content is namely in harmony with the presence of the numerous small-size dense-core vesicles (900 Å), which are regarded as responsible for the appearance of induced fluorescence also in other territories of the brain. The distal neurons which in most aminals give positive acetylcholinesterase reaction, but do not show any induced fluorescence, contain the larger granule type (1400 Å). Granules of similar shape and size in the nerve cells of the classical neurosecretory nuclei are known as containing peptides (s. in KNOWLES, 1967; BARGMANN, 1967; BARGMANN et al., 1967; SCHARRER, 1969) inspiring BARGMANN (1967), BARGMANN et al. (1967) to introduce the term "peptidergic" neurons. On the basis of the similarity, it might be supposed that the large granulated vesicles of the preoptic recess organ represent some kind of peptidergic activity.

Finally, attention should be called to the morphological variability of the CSF contacting nerve endings. These terminals differ not only in the size of their granulated vesicles, but also in the size of the endings themselves, inasmuch as those belonging to the hypendymal cells are larger and contain rough-surfaced endoplasmic reticulum beside the small dense-core vesicles (900 Å). In contrast, the intraventricular nerve terminals of the distal cells are smaller in size and contain numerous mitochondria beside the bigger granules (1400 Å). The two kinds of neurons and their CSF contacting endings might have different functions; perhaps they recept two different properties of the CSF. The present findings do not yet allow to outline a detailed hypothesis concerning the function of the preoptic recess organ, but the morphological evidence obtained, may serve as a basis for further morphophysiological investigations.

LITERATURE

1. BARGMANN, W.: (1967) Conclusions. In: Neurosecretion. IVth International Symposium on Neurosecretion. Ed. F. Stutinsky. Springer, Berlin—Heidelberg—New York, Pp. 241—247. — 2. BARGMANN, W., LINDNER, E., ANDRES, K. H.: (1967) Über Synapsen an endokrinen Epithelzellen und die Definition sekretorischer Neurone. Untersuchungen am Zwischenlappen der Katzenhypophyse. Z. Zellforsch. **77,** 282—298. — 3. BRAAK, H.: (1970) Biogene Amine im Gehirn vom Forsch (*Rana* esculenta). Z. Zellforsch. **106,** 269—308. — 4. KIRSCHE, W.: (1967) Über postembryonale Matrixzonen im Gehirn verschiedener Vertebraten und deren Beziehung zur Hirnbauplanlehre. Z. mikr.-anat. Forsch. **77,** 313—406. — 5. KNOWLES, F.: (1967) Neuronal Properties of Neurosecretory Cells. In: Neurosecretion. IVth International Symposium on Neurosecretion. Ed. F. Stutinsky. Springer, Berlin—Heidelberg—New York, Pp. 8—19. — 6. RICHTER, W.: (1969) Über die Beziehungen zwischen Hirnregeneration und Matrixgewebe bei Amphibien. Anat. Anz. **125,** Suppl., 547—554. — 7. SCHARRER, B.: (1969) Neurohumors and Neurohormones: Definition and Terminology. J. neuro-visc.

Rel. Suppl. **9,** 1—20. — 8. TEICHMANN, I., VIGH, B.: (1968) Histochemical Investigation of the Monoamine-Containing Neurons of the Paraventricular Organ and the Preoptic Recess of Amphibians *(Rana esculenta, Ambystoma mexicanum).* Acta biol. Acad. Sci. hung. **19,** 505. — 9. VIGH, B.: (1971) Das Paraventrikularorgan und das zirkumventrikuläre System. Stud. biol. hung. **10,** Akadémiai Kiadó Budapest. — 10. VIGH, B., TEICHMANN, I., AROS, B.: (1969) Das Paraventrikularorgan und das Liquorkontakt-Neuronensystem. Anat. Anz. Suppl. **125,** 683—688. — 11. VIGH-TEICHMANN, I.: (1968) Hydrencephalocriny of Neurosecretory Material in Amphibia. In: Zirkumventrikuläre Organe und Liquor. Bericht über das Symposium in Schloss Reinhardsbrunn. Ed. G. Sterba. Fischer, Jena 1969, Pp. 269—272. — 12. VIGH-TEICHMANN, I., RÖHLICH, P., VIGH, B.: (1969) Licht- und elektronenmikroskopische Untersuchungen am Recessus praeopticus-Organ von Amphibien. Z. Zellforsch. **98,** 217—232.— 13. VIGH-TEICHMANN, VIGH, B.: (1969a) Liquor Contacting Neuronal Areas in the Periventricular Gray Substance of the Central Nervous System. Gen. comp. Endocr. **13,** 537. — 14. VIGH-TEICHMANN, I., VIGH, B.: (1969b) Structure and Function of the Liquor Contacting Neurosecretory System. In: Aspects of Neuroendocrinology. Ed. W. BARGMANN and B. SCHARRER. Springer. Berlin—Heidelberg—New York 1970, Pp. 329—337. — 15. VIGH-TEICHMANN, I., VIGH, B., AROS, B.: (1969) Fluorescence Histochemical Studies on the Preoptic Recess Organ in Various Vertebrates. Acta biol. Acad. Sci. hung. **20,** 425—438. — 16. VIGH-TEICHMANN, I., VIGH, B., AROS, B.: (1970) Enzymhistochemische Studien am Nervensystem. IV. Acetylcholinesteraseaktivität im Liquorkontakt-Neuronensystem verschiedener Vertebraten. Histochemie **21,** 322—337. — 17. VIGH-TEICHMANN, I., VIGH, B., KORITSÁNSZKY, S.: (1970a) Liquorkontaktneurone im Nucleus paraventricularis. Z. Zellforsch. **103,** 483—501. — 18. VIGH-TEICHMANN, I., VIGH, B., KORITSÁNSZKY, S.: (1970b) Liquorkontaktneurone im Nucleus lateralis tuberis von Fischen. Z. Zellforsch. **105,** 325—338. — 19. VIGH-TEICHMANN, I., VIGH, B., KORITSÁNSZKY, S., AROS, B.: Liquorkontaktneurone im Nucleus infundibularis. Z. Zellforsch. **108,** 17—34.

LICHT- UND ELEKTRONENMIKROSKOPISCHE STRUKTUR DES RECESSUS PRAEOPTICUS-ORGANS BEIM MOLCH (TRITURUS CRISTATUS)

I. VIGH-TEICHMANN, B. VIGH und B. AROS

Das Recessus praeopticus-Organ ist rostral des neurosekretorischen Nucleus praeopticus in der Area praeoptica parvocellularis auf beiden Seiten des Recessus praeopticus lokalisiert. Das Organ besteht aus einem zylindrischen Ependym und einer charakteristischen Gruppe von Neuronen. Diese Nervenzellen sind intraependymal und in mehreren Reihen unter dem Ependym angeordnet. Ein Teil der Neurone ist bipolar; sie senden einen ihrer Fortsätze in den Recessus praeopticus und formen dort spezielle Nervenendigungen, die wir als Liquorkontakt-Nervenendigungen bezeichnen. Lichtmikroskopisch sind die intraependymalen und hypendymalen Neurone mit Toluidinblau Azur II dunkel gefärbt, während die distalen Zellen hell aussehen. Elektronenmikroskopisch stellten wir fest, daß die Liquorkontakt-Nervenendigungen der dunklen Neurone relativ groß sind und glattes und rauhes endoplasmatisches Retikulum, sowie dense-core Vesikel mit einem Durchmesser von 900 Å enthalten. Die Liquorkontakt-Nervenendigungen der hellen Nervenzellen sind kleiner als die vorhergehenden und enthalten mehrere Mitochondrien und Granula vom Durchmesser 1400 Å. Jede intraventrikuläre Nervenendigung trägt ein atypisches Cilium ($9 \times 2 + 0$ Tubuli). Der ventrikuläre Fortsatz der Neurone hat Dendriten-, ihr distaler Fortsatz hat Neuritencharakter. Das Perikaryon der dunklen intraependymalen und hypendymalen Nervenzellen enthält ein gut entwickeltes Ergastoplasma mit freien Ribosomen, Golgi-Apparat, Mitochondrien und zahlreiche dense-core Vesikel (Durchmesser 900 Å). Auf den Perikaryen, den ventrikulären und distalen Fortsätzen kommen Synapsen vor. Ihr praesynaptischer Bereich weist synaptische und dense-core Vesikel (Durchmesser 800—900 Å) auf. Die größeren, hellen Zellen, die die distalen Neuronenreihen bilden, enthalten Granula mit einem Durchmesser von 1400 Å und weniger freie Ribosomen; im übrigen gleicht die Feinstruktur dieser Perikaryen der der hypendymalen, dunklen Zellen. Die Nervenzellen sind in ein Neuropil eingebettet. Die fibrösen Schichten, die zwischen den hypendymalen und distalen Neuronen und lateral der letzteren ausgebildet sind, sind synaptische Zonen. Die zwei Arten von Nervenzellen, ihrer Liquorkontakt-Nervenendigungen und ihrer Granula lassen vermuten, daß das Recessus praeopticus-Organ aus zwei funktionell verschiedenen Komponenten besteht.

СТРУКТУРА ОРГАНА ПРЕДЗРИТЕЛЬНОГО УГЛУБЛЕНИЯ У ТРИТОНА (TRITURUS CRISTATUS) В СВЕТОВОМ И ЭЛЕКТРОННОМ МИКРОСКОПЕ

И. ВИГ-ТЕЙХМАНН, Б. ВИГ и Б. АРОШ

Орган предзрительного углубления расположен соответственно мелкоклеточному предзрительному полю перед нейросекреторным предзрительным ядром, по двум сторонам предзрительного углубления III-го желудочка. Указанный орган состоит из цилиндрической эпендимы и характерной нейроновой группы. Нервные клетки расположены в нескольких рядах между эпендимальными клетками и под ними. Клетки по большей части биполярные, один отросток входит в III-ий желудочек, образуя там специальные нервные окончания, создающие контакт со спинномозговой жидкостью (так наз. ликвороконтактные окончания). Под оптическим микроскопом при окрашивании толуидиновой синькой лазурь II, внутриэпендимальные и гипендимальные клетки окрашиваются в темный цвет, в дистальные клетки остаются светлыми. В электронном микроскопе ликвороконтактные окончания темных нейронов более крупные, и они содержат эндоплазматическую сетчатку гладкой и грубой поверхности, а также зернистые пузырьки величиной в 900 Å. Спинномозговое окончание светлых клеток меньше и содержит множество митохондриев и зернышки величиной в 1400 Å. Из каждого окончания исходит ресница нетипичного построения ($9\times2+0$). Желудочковые отростки нейронов имеют дендритовый, а дистальные отростки нейроновый характер. Перикарион внутриэпендимальных и гипедимальных темных нервных клеток содержит эргастоплазму с многочисленными свободными рибосомами. Кроме того в перикарионе выявляемы аппарат Гольджи, митохондрии и многочисленные пузырьки «dense core» со средней величиной 900 Å. На перикарионе, на желудочковом и дистальном отростке обнаруживаются синапсы, а в предсинаптической области наряду с сынаптическими пузырьками расположены пузырки «dense core» со средней величиной в 800—900 Å. Более крупные, светлые клетки, образующие дистальные ряды нейронов, содержат более крупные зернышки со средней величиной 1400 Å и меньше свободных рибосом. Впрочем их тонкая структура подобна микроструктуре гипендимальных темных клеток. Нейроны вложены в волокнистую зону, образующую под гипендимальными клетками и латерально от дистальных клеток более широкую сынаптическую зону.

Dr. Ingeborg VIGH-TEICHMANN
Dr. Béla VIGH
Dr. Béla AROS
Szövettani Intézet,
Budapest IX., Tűzoltó u. 58.
Hungary

Acta Morphologica Acad. Sci. Hung. 19 (1), pp. 43–56, 1971

Pathologisches Institut der Humboldt-Universität,
das Rudolf-Virchow-Haus der Charité (Direktor: Prof. Dr. L. H. KETTLER), Berlin

CHARAKTERISTISCHE MORPHOLOGISCHE BEFUNDE IM NIERENMARK NACH NIERENPUNKTION

G. DITSCHERLEIN, INGRID WITTE und D. KUNDE

(Eingegangen am 1. August, 1970)

Ausgedehnte Untersuchungen nach Nierenpunktion von Kaninchen, Ratten, Hunden und Menschen haben ergeben, daß immer dann ein charakteristischer Bezirk, der sog. rote Keil (rK) auftritt, wenn der Punktionskanal durch das Nierenmark verläuft. Der rK zieht von der Verletzungsstelle aus papillenwärts und ist scharf begrenzt. Er ist schon nach 90 Minuten in ganzer Ausdehnung vorhanden und bis zum Versuchsende nach einem Jahr nachweisbar, verwandelt aber in diesem Zeitraum allmählich sein makroskopisches und histologisches Bild. Folgende Faktoren werden für die Entstehung des rK verantwortlich gemacht: 1. die besondere Architektur des Nierenmarks, 2. die Unterbrechung aller Kanälchen und Vasa recta eines geschlossenen Bezirks sowie das Ausbleiben ihrer Wiedervereinigung. Daraus resultieren chronische Durchblutungsstörungen und Funktionslosigkeit der Kanälchen. Enzymhistochemisch reagiert anfangs in den schwerer geschädigten Zellen die aPase stark positiv. Die entdifferenzierende Atrophie der Tubuli geht einher mit Aktivitätsverminderung der Oxydoreduktasen. Die ATPase-Aktivität ist in den Wänden der hyperämischen Gefäße herabgesetzt. Für eigenartige periodische Hohlräume in Tubuli sind nach elektronenoptischen Befunden verschiedenen Entstehungsmöglichkeiten anzunehmen.

Nach Nierenpunktion können verschiedene pathologisch-anatomische Befunde beobachtet werden (s. Übersicht, DITSCHERLEIN, 1969a). Zu den häufigsten Punktionsfolgen gehört der sog. rote Keil, den wir bei Ratten, Kaninchen, Hunden und Menschen beobachteten. Er tritt immer dann auf, wenn Nierenmark verletzt wird. Das ist im Tierexperiment häufiger der Fall als beim Menschen.

Material und Methoden

Bei 175 Kaninchen, 90 Ratten und 11 Hunden wurden fast 1000 Nierenpunktionen mit dem Menghini-Besteck vorgenommen (Methoden bei Kaninchen, NAUTSCH u. DITSCHERLEIN, 1969a). Außerdem wurden die Nieren von 27 menschlichen Obduktionsfällen nach vorangegangener Punktion überprüft. Die einzelne Niere wurde nach der Entnahme so eingeschnitten, daß die Schnittfläche senkrecht zur Achse des Punktionskanals lag, wodurch der umschriebene Bezirk am besten getroffen wurde (vgl. Abb. 1, linkes Schema). Die Weiterverarbeitung erfolgte je nach der beachsichtigten Untersuchungsmethode.

Histologische Untersuchung. Fixierung in Formalin, Paraffineinbettung; verschiedene Färbungen bzw. Reaktionen: Hämalaun-Eosin, Hämatoxylin-van Gieson, Lepehne, Feulgen, Berliner Blau, PAS, Tibor Pap.

Enzymhistochemische Untersuchung. An Messertiefkühlschnitten Überprüfung folgender Reaktionen: Alkalische Phosphatase aPase n. (Gomori), Adenosintriphosphatase (ATPase pH 7,2; 7,5; 9,4; s. WACHSTEIN u. MEISEL, 1957, sowie SCHREIBER u. SIMON), Diaphorase I (HESS et al., 1958), Lactatdehydrogenase (HESS et al.), Monoamindehydrogenase (GLENNER et al., 1957), Succinatdehydrogenase (NACHLASS et al., 1957).

Elektronenmikroskopische Untersuchung. Immersionsfixierung in 1%igem gepuffertem OsO_4, Einbettung in Vestopal W, zum Teil Nachkontrastierung nach Reynolds.

Ergebnisse

Makroskopische Befunde

Der rote Keil (rK) ist nur auf Schnittflächen durch das Nierenmark sichtbar. Seine Ausdehnung ist aus den beiden Schemata in Abb. 1 zu entnehmen. Der veränderte Bezirk fällt vor allem durch seine dunkelrote Farbe auf, die er für viele Wochen beibehält. Allmählich nimmt er einen braungrauen Farbton an.

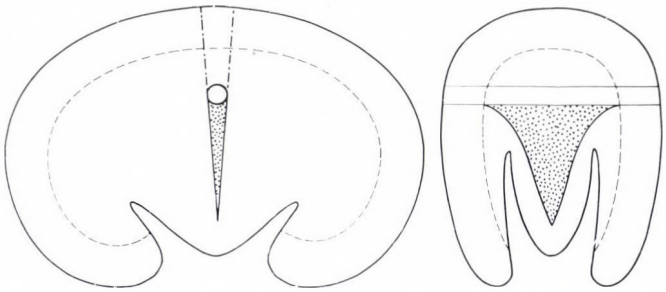

Abb. 1. Ausdehnung des roten Keile (punktierte Flächen) in Schema. Links Längsschnitt durch eine Kaninchenniere, Punktionskanal (rund) im Querschnitt getroffen. Rechts Nierenquerschnitt durch die Längsachse des Punktionskanals (parallele Linien). Gebiet über den Punktionskanal ist nephrohydrotisch. Gestrichelte Linie = Rinden-Mark-Grenze

Histologische Befunde

Bereits nach 5, 10 und 20 Minuten können sich rings um den Punktionskanal (P) in den eröffneten Sammelrohren und Henleschen Schleifen Erythrozyten und Zelltrümmer befinden. Bereits nach 20 Minuten besteht eine Hyperämie. Nach 90 Minuten ist der rK in seiner ganzen Ausdehnung vorhanden: er beginnt am P und hat hier etwa die Breite des ausgestanzten Gewebsdefekts, zieht in Richtung zur Papillenspitze und verjüngt sich auf diesem Wege (Abb. 2). In der Nachbarschaft des P sind vielfach Hämorrhagien nachweisbar. Schon nach 2 1/2 Stunden sind in manchen Kapillaren vermehrt Leukozyten nachzuweisen. — Nach 2 bis 5 Tagen beobachtet man häufig Einzelzellnekrosen, besonders von Epithelien, in der Nachbarschaft des P auch von Bindegewebszellen. In den Kanälchenlichtungen kommen häufig abgestoßene nekrotische Zellen, deren Trümmer und abgeblaßte Erythrozyten vor; oft ist das alles zu Zylindern zusammengeballt. Ferner tritt vermehrt dünnflüssiger, homogener lepehne-positive Kanälcheninhalt auf (Abb. 3).

Regeneratorische Prozesse beginnen nahe dem P; die epitheliale Proliferation geht der Mesenchymalen voraus. Besonders am 2. und 3. Tag findet man in beiden Gewebsanteilen Mitosen (genauer bei WITTE, 1969), am 3. und 4. Tag eisenhaltige Phagozyten. Neben diesen frisch hinzugekommenen

Erscheinungen sind aber auch noch die vorher beschriebenen vorhanden. Je nach Lage des P und Ausdehnung des rK sind degenerative und regeneratorische Vorgänge stark ausgebildet. Bei ursprünglich größerem Gewebsdefekt und Unterbrechung einiger Gefäßbündel überwiegen Nekrosen, die Regeneration setzt zögernd ein. Ein beliebiger rK kann in einem Gewebsabschnitt in Nähe des P einen geschlossenen Nekrosebezirk aufweisen, in einer anderen Gewebsstufe sind kaum noch Einzelnekrosen nachweisbar, die Heilungs-

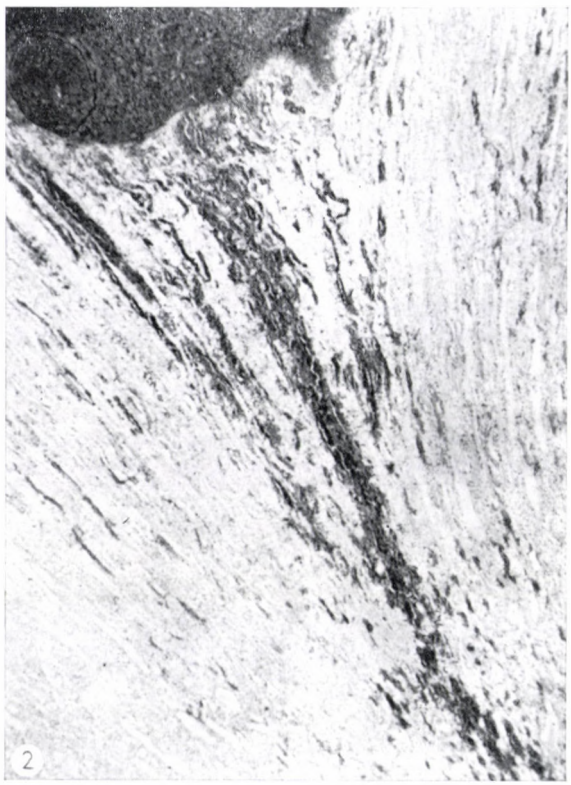

Abb. 2. Übersicht über rK 3 Tage post punctionem (p.p.) Links oben angeschnitten Punktionskanal. Lepehne, 35 ×

vorgänge sind im vollen Gange. Die letzteren treten in der 2. Woche weiter in den Vordergrund. Von jetzt an enthalten die Sammelrohre nur noch vereinzelt und in geringem Maße die oben genannten Bestandteile in ihrer Lichtung. Dagegen sind die Henleschen Schleifen weiterhin von Zylindern ausgefüllt. Diese können ebenso wie die Tubuluszellen feine Eisenpartikel enthalten; am intensivsten kommt aber Siderin in Histozyten vor.

Nach 2—5 Wochen zeigen die Epithelzellen eine zunehmende entdifferenzierende Atrophie. Die Tubuli ohne Lumeninhalt wandeln sich in solide

Zellstränge um. Die Zylinder in den erweiterten Kanälchen sind meist homogen, intensiv eosinophil und PAS-positiv.

Man beobachtet von nun an immer häufiger folgenden Befund: Im Längsschnitt stellen sich Zellstränge dar, die in periodisch wechselnder Reihenfolge 1—2 Zellen und Hohlräume besitzen (Abb. 4). Manche Hohlräume enthalten einen homogenen Inhalt nach Art der oben beschriebenen Zylinder, in anderen

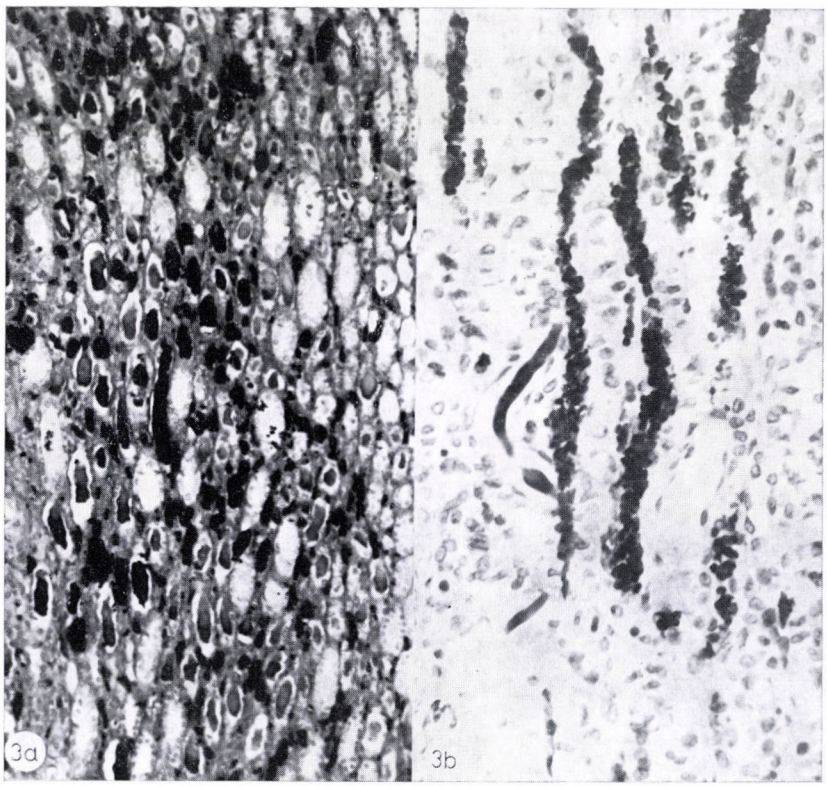

Abb. 3a. Ausschnitt aus rK 9 Tage p. p. Hyperämie und Hämorrhagien. In vielen Kanälchenlichtungen zusammengeballte Erythrozyten (schwarz) oder Hämoglobinzylinder (grau bis schwarz). Sammelrohre (hell) meist frei von Lumeninhalt. Lepehne, 114×

Abb. 3b. Randpartie eines rK 9 Wochen p. p. Noch immer starke Hyperämie und vereinzelte Hämoglobinzylinder in Henleschen Schleifen. Lepehne, 320×

Epithelsträngen sind diese Hohlräume optisch leer (Abb. 4). Im übrigen findet man weiterhin überwiegend stark blutgefüllte Kapillaren, obwohl auch unauffällige Gefäße vorkommen. Die hyperämischen Gefäße liegen nach langen Beobachtungszeiten besonders in der peripheren Zone des rK; der zentrale Teil erscheint dagegen arm an Kapillaren. Zwischen den Vasa recta und den Epithelsträngen befinden sich die in üblicher Weise »strickleiterartig« angeord-

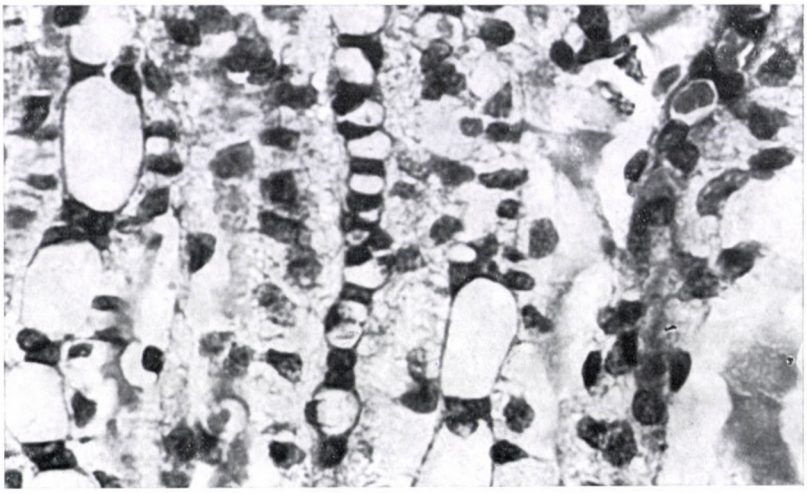

Abb. 4. Ausschnitt aus rK 20 Wochen p. p. Eigenartige periodische Hohlräume der atropischen Tubuli. Meist nur sehr wenig, offenbar eiweißarmes Material in den Hohlräumen, in einem Epithelstrang kräftig angefärbte Massen (Pfeile). Hämalaun-Eosin, 720×

neten Zwischenzellen des Nierenmarks. Der Gehalt an Kollagenfasern ist reicher als in der gesunden Umgebung. Diese Befunde ändern sich nicht mehr prinzipiell bis zum Ende des Beobachtungszeitraums nach einem Jahr.

Enzymhistochemische Befunde

Hydrolysen: Die aPase ist in den ersten Tagen im Kanälcheninhalt, in vielen Epithelzellen, seltener in Interstitiumzellen stark positiv. Nach 5—7 Tagen nehmen diese Befunde schnell ab. Die ATPase der Gefäßwände zeigt innerhalb der ersten Wochen eine allmähliche Aktivitätsverringerung. Nach 6 Wochen reagieren die Gefäße sehr unterschiedlich, d. h. teils normal, teils vermindert.

Oxydoreduktasen: Die überprüften Enzyme verhalten sich gleichsinnig. Bereits vom 1. Tag an ist die Aktivität in den Epithelien der Sammelrohre und Henleschen Schleifen beträchtlich herabgesetzt, besonders nahe dem P (Abb. 5). Zur Spitze des rK hin reagieren die Epithelien normal. Die Interstitiumzellen verhalten sich in den verschiedenen Partien jeweils ähnlich wie die Epithelien. In nekrotische Zonen sprossen nach einigen Tagen kräftig reagierende junge Bindegewebszellen ein. Die Aktivität der atrophischen Tubuli nimmt ständig ab. Die Interstitiumzellen reagieren in gleicher Stärke wie diejenigen der Umgebung.

Elektronenoptischen Befunde

Sie stellen nur eine Ergänzung zu den Spätbefunden dar, insbesondere um die eigenartigen Epithelstränge mit den periodischen Hohlräumen deuten

zu können. Nach einigen Wochen zeigen die Tubuli unterschiedliche Befunde: In manchen Epithelsträngen überwiegen degenerative Veränderungen (Mitochondrienschwellung, Erweiterung des endoplasmatischen Reticulums, völlige hydropische Degeneration) in einzelnen oder allen im Schnitt vorhandenen Zellen (Abb. 6 u. 8). Gelegentlich kommen Zellen mit zahlreichen Zytolysomen vor, manche Zellen haben sich von der Basalmembran und aus dem Zellverband gelöst. Die Lichtungen enthalten abgestoßene Zellen, einzelne oder

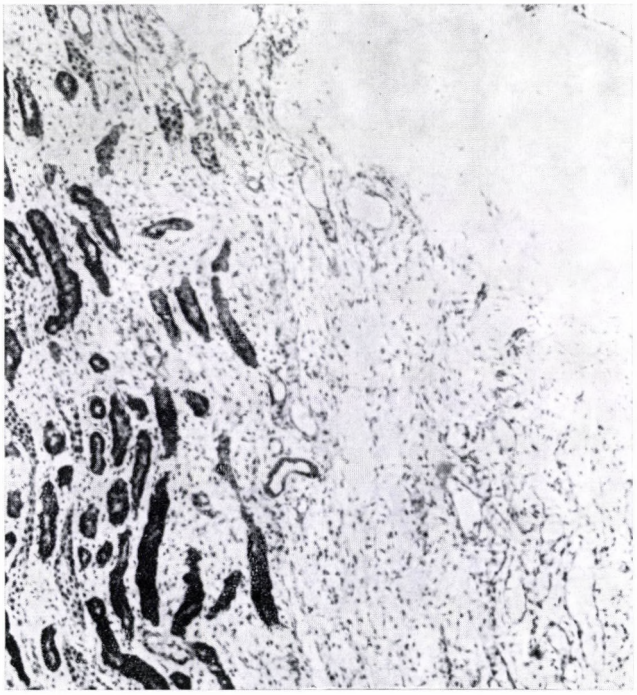

Abb. 5. Ausschnitt aus rK (rechter unterer Quadrant) und Punktionskanal (rechter oberer Quadrant und oberer Bildrand links) 4 Tage p. p. Succinatdehydrogenase-Aktivität in den Kanälchen hochgradig herabgesetzt bzw. nicht mehr eindeutig erkennbar (vgl. mit normaler Enzymaktivität links unten). Kerndarstellung nach Feulgen. 100×

massenhaft degenerierte Zellorganellen oder ganz feingranuläres, mäßig osmiophiles Material beobachteten Räume, die allseitig von Zellen umgeben sind, teils aber auch auf beiden Seiten direkt an die Basalmembran grenzen. Bei denselben Fällen kommen auch Epithelstränge vor, die aus jungen, organellenarmen Zellen bestehen und periodisch wiederkehrende Hohlräume im Längsschnitt besitzen (Abb. 8). Die stets vorhandenen kurzen Mikrovilli und die nahe den Hohlräumen liegenden Schlußleistenkomplexe der umgebenden Epithelzellen lassen erkennen, daß diese Hohlräume dem Tubuluslumen entsprechen, aber offenbar nicht miteinander zusammenhängen (Serienschnitte).

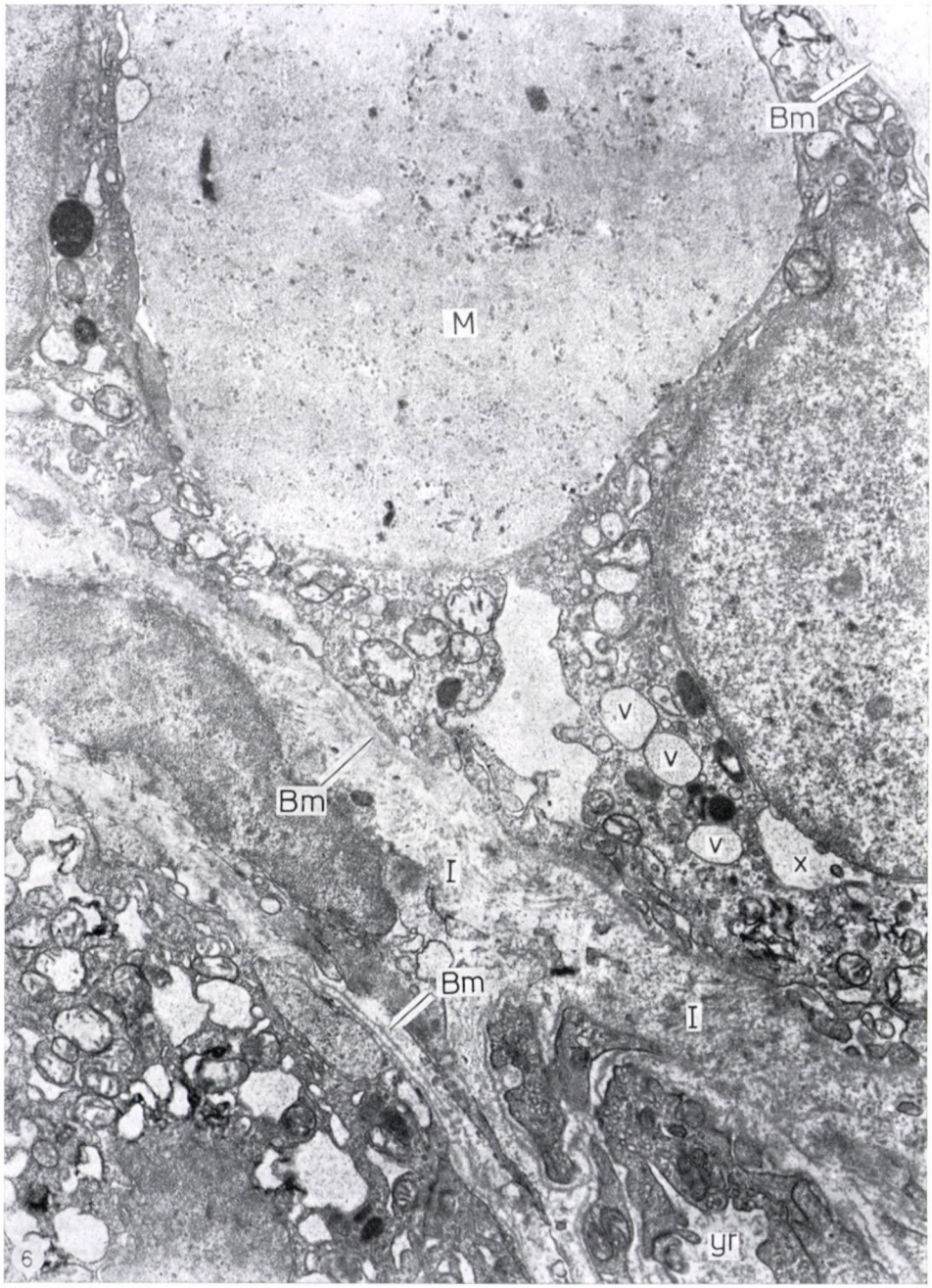

Abb. 6. Ausschnitt aus rK 1/4 Jahr p. p. Teil eines längsgeschnittenen Tubulus mit einem durch dichtes, feingranuläres Material (M) ausgefüllten Hohlraum. Benachbarte Epithelzellen zeigen Mitochondrienschwellung, Erweiterung des endoplasmatischen Reticulum und von Interzellularspalten, Vakuolen (v), lokale Erweiterung des Kernenbranspalts (x); Basalmembran = Bm. Links unten angeschnittener Tubulus mit ähnlichen Zellveränderungen. Interstitium kollagen-faserreich (I). Rechts unten Vas rectum (vr). Orig.-Vergröß. 6000 ×



Abb. 7. Ausschnitt aus rK 5 Wochen p. p. Hydropische Degeneration von Tubuluszellen (hT). Tubuluslumen ausgefüllt mit nekrotischen Zellen und Zellbestandteilen (Z). Orig.-Vergröß. 3000 ×

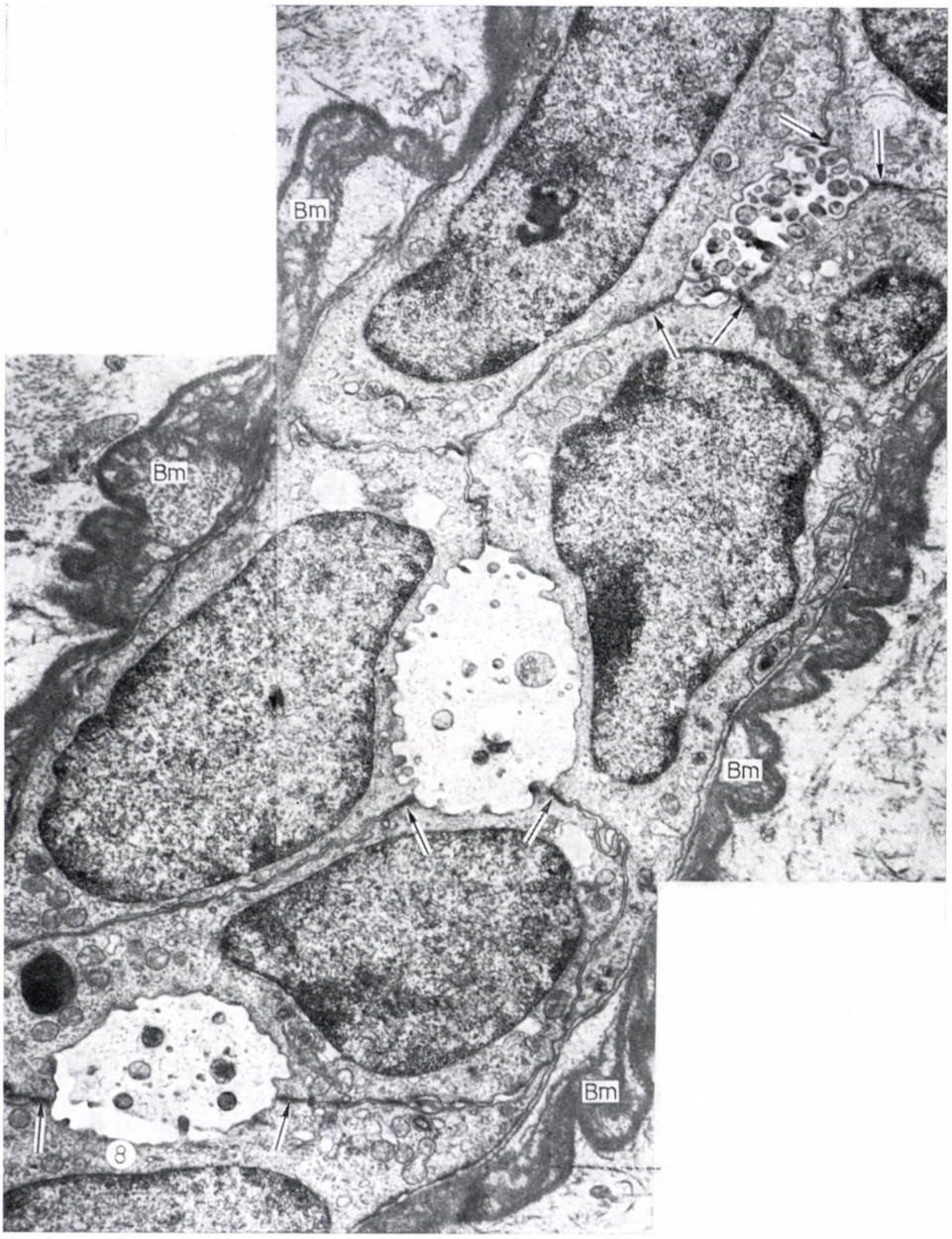

Abb. 8. Ausschnitt aus rK 5 Wochen p. p. (von demselben Fall wie Abb. 7). Längsgeschnittener Tubulus aus wenig differenzierten Zellen ohne Degenerationszeichen. Im axialen Bereich 3 Hohlräume, in deren Nähe Schlußleistenkomplexe ( ) deutlich erkennbar sind. Einzelne kurze Mikrovilli. In den Lumina dünnflüssiges Material. Basalmembran (Bm) mehrschichtig und gefaltet. Fotomontage. Orig.-Vergröß. 6000 ×

Diskussion

Bereits im älteren Schrifttum (BARTH, 1893; RIBBERT und PEIPERS 1894/95; WILDBOLZ, 1906; AWATAGUTI, 1939) wurden nach Messerstichen Nierenspaltung oder Keilexzision z. T. Befunde beschrieben, die denen des roten Keils ähneln; sie wurden aber nur am Rande erwähnt, da bei den schwereren Eingriffen auch massivere Läsionen, besonders Nekrosen, im Vordergrund standen.

Durch Nierenpunktion (oder Lanzenstich) wird in einem umschriebenen Bereich die Kontinuität der Kanälchen und Gefäße unterbrochen, und es entstehen bei Verletzung des Nierenmarks *regelmäßig* zwei verschiedenartige charakteristische Befunde:

1. Zwischen P und Nierenoberfläche entwickelt sich in einem sektorförmigen Bezirk eine Nephrohydrose (DITSCHERLEIN, 1966, 1969c).

2. Auf der Gegenseite, also zur Papillenspitze hin bildet sich der sog. rote Keil aus (Abb. 1). Beide Bezirke sind scharf begrenzt und in ihrer Lage und Ausdehnung geradezu gesetzmäßig von der Lokalisation des P abhängig (DITSCHERLEIN, 1969a). Die Ursache für diese Veränderungen besteht darin, daß im Bereich des Gewebsdefekts trotz starker epithelialer Regeneration und Granulationsgewebsbildung *keine* Wiedervereinigung der proximalen und distalen Kanälchenstümpfe erfolgt, was im wesentlichen auch für die kleinen Gefäße zutrifft (DITSCHERLEIN, 1969b; DITSCHERLEIN und DENA, 1969). Die Blutung aus den zahlreichen eröffneten Gefäßen führt unmittelbar nach dem Eingriff zur schnellen Ausfüllung des durch die Gewebsentnahme entstandenen »Vakuums«; von hier aus gelangen sekundär Blutbestandteile in die eröffneten Kanälchen, wozu sich später nekrotische abgestoßene Epithelzellen und Zellorganellen gesellen. Das weitere Schicksal des Lumeninhalts ist jedoch unterschiedlich und von den vorhandenen oder fehlenden Abflußbedingungen abhängig. Es gibt folgende Möglichkeiten:

a) Die weitaus *meisten Henleschen Schleifen* werden im zu- und abführenden Schenkel unterbrochen; der gesamte entsprechende Schleifenteil wird »stillgelegt«. Nach dem erfolgten Verschluß der beiden Unterbrechungsstellen innerhalb der ersten Tage nach dem Eingriff ist ein Abfluß des Lumeninhalts nicht mehr möglich. Der entsprechende Kanälchenabschnitt verliert seine vorherige Funktion im Rahmen der Harnbereitung; dafür steht er jetzt vor der Aufgabe, das Material im Lumen abzubauen. Daß dies prinzipiell möglich ist, zeigt der positive Eisennachweis (Erythrozytenabbau!) in den Epithelzellen in der Folgezeit.

Andererseits scheint diese Möglichkeit im Bereich des rK beschränkt zu sein, da man sehr lange den Lumeninhalt (größtenteils als Hämoglobinzylinder) beobachten kann.

b) Aus den unterbrochenen *Sammelrohren* kann das Material ohne Behin-

derung abfließen und gelangt in den Harn. Dies dürfte die Ursache für die dem Kliniker wohlbekannte häufige Mikrohämaturie in den ersten Tagen nach Nierenpunktion sein. Es erklärt auch, daß man histologisch in den Sammelrohren nur anfangs reichlich Lumeninhalt (meistens zahlreiche Erythrozyten) nachweisen kann. Die entsprechenden Sammelrohre werden dann funktionslos und daher atrophisch.

c) Am Rand des rK gibt es sicherlich *einzelne Henlesche Schleifen*, die nur im ab- oder zuführenden Teil unterbrochen sind. Je nachdem verhält sich die entsprechende Schleife wie unter a) oder wie unter b).

Die in der Nachbarschaft des P auftretenden Veränderungen sind in der ersten Zeit zum Teil mit *direkt auf die mechanische Läsion* (Stanzeffekt) zurückzuführen; das gilt besonders für Hämorrhagien und Basalmembranrisse der Kanälchen. Hierdurch ist ein Teil der Zellnekrosen erklärbar. Übrigens beziehen wir den in den ersten Tagen in vielen Zellen stark positiven Ausfall der aPase-Reaktion auf nekrobiotische Vorgänge, was in ähnlicher Weise nach Intoxikationen und Durchblutungsstörungen schon mehrfach angegeben wurde (Wilmer, 1944; Hepler et al., 1945; Wachstein, 1947, 1955; Wachstein u. Meisel, 1957; Staemmler, 1956; Sachs u. Dulskas, 1956; Rudolph u. Scholl, 1958).

Im übrigen werden aber die Vorgänge im rK sicherlich ganz wesentlich von den *Durchblutungsstörungen* bestimmt. Da stets eine Reihe benachbarter zuführender Gefäße unterbrochen wird, erwarteten wir eigentlich häufiger anämische Nekrosen. Sie kommen aber nur dann im Zentrum des rK vor, wenn mehrere Gefäßbündel durchtrennt sind. Im übrigen überwiegen Hyperämie und Einzelzellnekrosen des Parenchyms sowie mehr protrahiert verlaufende regressive Veränderungen der verschiedenen Gewebsanteile. Die sofort nach der Punktion vorliegende starke Dilatation und Blutfülle der Kapillaren im gesamten Gebiet des rK dürfte auf Kapillarlähmung infolge des mechanischen Eingriffs zurückzuführen sein, so daß man sie wohl als terminale Hyperämie auffassen kann. Enzymhistochemisch ist in diesem Stadium an den Gefäßen der *gleichmäßige* Reaktionabfall der ATPase auffällig. Die in der Anfangszeit überwiegenden schweren Zellschäden — besonders an den Epithelien — können durch die terminale Hyperämie erklärt werden. Dagegen ist die Hyperämie nach längerer Beobachtungsdauer anders zu deuten. Zunächst ist die Feststellung wichtig, daß den Narbenstrang, der sich aus dem einstigen P gebildet hat, kaum Gefäße durchziehen. Daher erhebt sich die Frage nach dem Zu- und Abfluß zum bzw. vom rK. Unter Berücksichtigung der Studien von Moffat und Fourman (1963), Plakke und Pfeiffer (1964), Rollhäuser et al. (1964), Kriz (1967), Kriz und Lever (1969) über die Architektur des Gefäßbaums von Säugernieren vermuten wir, daß die Auffüllung der Gefäße in der Peripherie des rK von den benachbarten Gefäßbündeln aus über das terminale Stromgebiet erfolgt. Der Blutabfluß geht dann über Anastomosen

der venösen Vasa recta, die nach ROLLHÄUSER et al. (1964) bestehen sollen, vor sich. Schon normalerweise ist das Druckgefälle und damit die Blutstromstärke in diesem längsten terminalen Strombett des Körpers naturgemäß gering (DEETJEN et al., 1964), eine weitere Verlängerung und/oder Blutflußbehinderung muß damit sehr leicht zu peripheren Durchblutungstörungen führen, da die vis a tergo zu gering ist. Der beobachtete Befund ähnelt dem Zustand der Hypostase. Im zentralen Teil des rK bleibt die anfängliche Hyperämie nicht auf die Dauer bestehen, das Gebiet zeigt dann mehr eine chronische ischämische Durchblutungsstörung. Beide Formen der Kreislaufstörungen haben regressive Gewebsveränderungen zur Folge. Daß sich die Gefäße im rK im chronischen Stadium unterschiedlich verhalten, zeigen die ungleichmäßigen Reaktionsausfälle (ATPase) und auch die differenten submikroskopischen Befunde (DITSCHERLEIN und MARX, 1970).

Die Veränderung der *Tubuluszellen* besteht vor allem in einer *entdifferenzierenden Atrophie*, die histologisch und vor allem elektronenoptisch deutlich wird. Enzymhistochemisch zeigt sich das in einer allmählichen Aktivitätsabnahme der Oxydoreduktasen. Die Ursachen für die Atrophie bestehen in dem Verlust der eigentlichen Funktion und in den chronischen Durchblutungsstörungen.

Die eigenartigen *Hohlraumbildungen*, die wahrscheinlich nicht miteinander in Verbindung stehen, sind nicht einheitlich zur beurteilen. Bei einem Teil zeigen die benachbarten Tubuluszellen degenerative Veränderungen und/oder Zytolysomen; meist liegt dann Material in diesen Hohlräumen. Mit Sicherheit werden geschädigte Organellen oder ganze Zellen in diesen Hohlraum hinein abgestoßen. Während in durchgängigen Nephronen üblicherweise das abgestoßenes Material mit dem Harn ausgeschwemmt wird, ist im vorliegenden Fall in der Regel der Abflußweg versperrt, das Material bleibt somit liegen. Daher muß auch an die Möglichkeit gedacht werden, daß es von den benachbarten Epithelzellen aufgenommen wird; dann könnte es sich bei den oben genannten Zytolysomen vielleicht um Phagosomen handeln. Die bisher besprochenen Hohlräume scheinen *aus dem ursprünglichen Tubuluslumen* hervorzugehen. Offenbar gibt es für die lichtoptisch leeren Hohlräume als weitere Entstehungsweise eine *hydropische* Degeneration der Tubuluszellen (vgl. WITTE, 1969), was bei einer Vielfalt von Schädigungsmöglichkeiten beobachtet werden kann (KETTLER, 1952). So läßt sich gelegentlich an einem Schnitt beobachten, wie ein derart veränderter Abschnitt in ein völlig normal aussehendes Sammelrohr papillenwärts vom rK übergeht. Da hier die obigen Erörterungen über die Abflußbehinderungen *nicht* zutreffen, bleibt nur als Erklärung für die Veränderung die chronische Durchblutungsstörung. — Schließlich seien periodische Hohlraumbildungen erwähnt, die in Epithelsträngen aus jungen, *undifferenzierten Zellen vorkommen;* die Hohlräume entsprechen hier ohne Zweifel dem Kanälchenlumen (Mikrovilli, Schluß-

leisten), welches aber nicht axial durchgehend verläuft — vermutlich deshalb, weil hierzu keine funktionelle Notwendigkeit besteht. Diese Hohlräume sind aber stets klein (vgl. Abb. 8).

LITERATUR

1. Awataguti, S.: (1939) Experimentelle Studien über die Wundheilung bei der Nierenspaltung. Mitteil. allg. Path. (Sendai) **10,** 108—127. — 2. Barth, A.: (1893) Über die histologischen Vorgänge bei der Heilung von Nierenwunden und über die Frage des Wiederersatzes von Nierengewebe. Arch. klin. Chir. **45,** 1—54. — 3. Deetjen, P., Brechtelsbauer, H., Kramer, K.: (1964) Hämodynamik des Nierenmarks. III. Farbstoffpassagezeiten in äußerer Markzone und V. renalis. Die Durchblutungsverteilung in der Niere. Pflügers Arch. ges. physiol. **279,** 281—293. — 4. Ditscherlein, G.: (1966) Nephrohydrose als Folge der Nierenpunktion. Experimentelle Untersuchungen an der Niere des gesunden Kaninchens. Frankf. Z. Path. **75,** 306—316. — 5. Ditscherlein, G.: (1968) Morphologische Folgen der Nierenpunktion. Makroskopische, histologische, enzymhistochemische, autoradiographische, elektronen- und fluoreszenzmikroskopische Untersuchungen. Habil.-Schrift Humboldt-Universität Berlin. — 6. Ditscherlein, G.: (1969a) Morphologische Folgen der Nierenpunktion. Tierexperimentelle und humanpathologische Befunde. Springer-Verlag Berlin—Heidelberg—New York. — 7. Ditscherlein, G.: (1969b) Die Wundheilung nach Nierenpunktion. I. Regenerationsprozeß des Epithels. Zbl. allg. Path. **112,** 343—355. — 8. Ditscherlein, G.: (1969c) Spätbefunde der mechanisch bedingten Nephrohydrose. Experimentelle Untersuchungen. Zbl. allg. Path. **112,** 590—599. — 9. Ditscherlein, G., Dena, R.: (1969) Die Wundheilung nach Nierenpunktion. II. Verhalten des Mesenchyms. Zbl. allg. Path. **112,** 377—384. — 10. Ditscherlein, G., Spann, M., Natusch, R.: (1968) Methoden der Nierenpunktion bei der Ratte. Z. ges. exper. Med. **145,** 260—265. — 11. Ditscherlein, G., Marx, I.: (1969) Elektronenmikroskopische Untersuchungen zur Wundheilung nach Nierenpunktion bei Kaninchen. Beitr. path. Anat. **138,** 405—425. — 12. Ditscherlein, G., Marx, I.: (1970) Elektronenmikroskopische Untersuchungen am Nierenmark nach umschriebener mechanischer Verletzung. Z. mikr.-anat. Forsch. (im Druck). — 13. Glenner, G. G., Bortner, H. J., Brown, G. W.: (1957) The Histochemical Demonstration of Monoamine Oxidase Activity by Tetrazolium Salts. J. Histochem. Cytochem. **5,** 591—600. — 14. Gomori, G.: (1946) The Study of Enzymes in Tissue Reactions. Amer. J. clin. Path. **16,** 347—352. — 14a. Hepler, O. E., Gurley, H., Simonds, J. P.: (1945) Experimental Nephropathies. II. Renal Phosphatase After Poisoning with Mercury Bichloride, Uranyl Nitrate and Potassium Dichromate. Arch. Path. **39,** 133—141. — 15. Hepler, O. E., Simonds, J. P., Gurley, H.: (1940) Renal Phosphatase in Experimental Nephropathies. Proc. Soc. exper. Biol. (N. Y.) **44,** 221—223. — 16. Hess, R., Scarpelli, D. G., Pearse, A. G. E.: (1958) The Cytochemical Localization of Oxidative Enzymes. II. Pyridine Nucleotide-linked Dehydrogenases. J. biophys. biochem. Cytol. **4,** 753—760. — 17. Kettler, L.-H.: (1952) Zur Pathogenese hydropischer Zellveränderungen in Leber und Niere. Virchows Arch. path. Anat. **321,** 326—354. — 18. Kriz, W.: (1967) Der architektonische und funktionelle Aufbau der Rattenniere. Z. Zellforsch. **82,** 495—535. — 19. Kriz, W., Lever, A. F.: (1969) Renal Countercurrent Mechanism: Structure and Function. Amer. Heart J. **78,** 101—118. — 20. Moffat, D. B., Fourman, J.: (1963) The Vascular Pattern of the Rat Kidney. J. Anat. (London) **97,** 543—553. — 21. Nachlass, M. M., Tsou, K. C., de Souza, E., Cheng, C. S., Seligman, A. M.: (1957) Cytochemical Demonstration of Succinic Dehydrogenase by the Use of a New p-nitrophenyl Substituted Ditetrazole. J. Histochem. Cytochem. **5,** 420—436. — 22. Natusch, R., Ditscherlein, G.: (1965) Zur Methodik der perkutanen Nierenbiopsie am Kaninchen. Acta biol. med., germ. **15,** 492—499. — 23. Plakke, R. K., Pfeiffer, E. W.: (1964) Blood Vessels of the Mammalian Renal Medulla. Science **146,** 1683—1685. — 23a. Reynolds, E. S.: (1963) The Use of Lead Citrate at High pH as an Electron-opaque Stain in Electron Microscopy. J. Cell Biol. **17,** 208—212. — 24. Ribbert, H., Peipers: (1894/95) Beiträge zur kompensatorischen Hypertrophie und zur Regeneration. Mit einem Abschnitt über die Regeneration der Nieren. Arch. Entwicklungsmech. **1,** 69—90. — 25. Rollhäuser, H., Kriz, W., Heinke, W.: (1964) Das Gefäßsystem der Rattenniere. Z. Zellforsch. **64,** 381—403. — 26. Rudolph, G., Scholl, O.: (1958) Histochemische Untersuchungen zum Fermentgehalt des experimentellen Niereninfarktes. Beitr. path. Anat. **119,** 13—44. — 27. Sachs, H. W., Dulskas, A.: (1956) Die alkalische Phosphatase der Niere bei einigen Vergiftungen. Virchows Arch. path. Anat. **329,** 466—485. — 28. Staemmler, M.: (1956) Die akuten Nephrosen. I. Mitteilung: Die Sublimatnephrose. Virchows Arch. path. Anat. **328,**

1—17. — 29. WACHSTEIN, M.: (1947) Nephrotoxic Action of dl-serine in the Rat. 1. The Localization of the Renal Damage, the Phosphatase Activity and the Influence of Age, Sex, Time and Dose. Arch. Path. **43,** 503—514. — 30. WACHSTEIN, M.: (1955) Histochemical Staining Reactions of the Normally Functioning and Abnormal Kidney. J. Histochem. Cytochem. **3,** 246—270. — 31. WACHSTEIN, M., MEISEL, E.: (1957) A Comparative Study of Enzymatic Staining Reactions in the Rat Kidney with Necrobiosis Induced by Ischemia and Nephrotoxic Agents (mercuhydrin and dl-serine). J. Histochem. Cytochem. **5,** 204—220. — 32. WILDBOLZ, H.: (1906) Über die Folgen der Nierenspaltung. Dtsch. Z. Chir. **81,** 34—62. — 33. WILMER, H. A.: (1944) Renal Phosphatase. The Correlation between the Functional Activity of the Renal Tubule and its Phosphatase Content. Arch. Path. **37,** 227—237. — 34. WITTE, I.: (1969) Über charakteristische pathologisch-anatomische Veränderungen im Nierenmark nach Nierenpunktion. (Experimentelle Untersuchungen an Kaninchen und Ratten.) Inaug.-Dissert. Humboldt-Universität Berlin.

CHARACTERISTIC MORPHOLOGICAL PHENOMENA IN THE MEDULLA OF THE KIDNEY FOLLOWING RENAL PUNCTURE

G. DITSCHERLEIN, I. WITTE and D. KUNDE

Large-scale examinations following renal puncture performed on rabbits, rats, dogs and human subjects have shown the appearance of a characteristic area, the so-called "red wedge", whenever the canal of the puncture passed through the renal medulla. The cuneiform zone extends from the point of injury towards the papillae and is sharply circumscribed. It attains maximal size after 90 min. and remains visible for a whole year during which both its gross and microscopic features undergo gradual change. The following are supposed to be responsible for the development of the "red wedge": (a) the special architecture of the renal medulla; (b) division of all minor vessels and the vasa recta in a closed area without their subsequent reunion, anomalies which lead to chronic disturbances of blood supply and dysfunction of the small channels.

Initial ATP-ase reaction of the severely damaged cells is strongly positive. Dedifferentiating atrophy of the tubules goes hand in hand with a reduction in the activity of oxidoreductases. The walls of the hyperaemic vessels display diminished ATP-ase activity. Electronmicroscopic studies concerning peculiar periodic cavities in the tubules have shown various possibilities in respect of their origin.

ХАРАКТЕРНЫЕ МОРФОЛОГИЧЕСКИЕ ИЗМЕНЕНИЯ ПОСЛЕ ПУНКЦИИ МЕДУЛЛЯРНОГО ВЕЩЕСТВА ПОЧЕК

Г. ДИТШЕРЛЕЙН, И. ВИТТЕ и Д. КУНДЕ

Многочисленные исследования выявили, что у кроликов, крыс, собак и человека после пункции почек появляется характерная область, так наз. красный клин, наблюдаемый только тогда, когда канал прокола проходит через мозговое вещество почки. Красный клин простирается от места поражения в направлении почечных сосочков, и он резко отграничен. Уже по истечении 90 минут красный клин достигает полного размера и до окончания эксперимента его можно выявить даже по истечении года. Однако в течение этого срока наблюдается постепенное изменение его макроскопической и гистологической картины. Ответственным за возникновение красного клина можно считать следующие факторы: 1. архитектуру медуллярного вещества почек, 2. прерывание всех канальцев и прямых сосудов замкнутой области при отсутствии их воссоединения. Из этого следуют хронические расстройства кровотока и прекращение функции канальцев. При фермент-гистологическом изучении вначале АТФаза более тяжело пораженных клеток реагирует положительно. Недифференцирующая атрофия канальцев сопровождается понижением активности оксидоредуктазы. В стенках гиперемических сосудов активность АТФазы понижена. На основе электронноптических результатов для возникновения своеобразных периодических полостей в канальцах можно полагать различные возможности.

Dr. G. DITSCHERLEIN
Dr. Ingrid WITTE
Dr. D. KUNDE

Path. Inst. d. Humboldt-Universität, (Rudolf-Virchow-Haus), Berlin, DDR

Acta Morphologica Acad. Sci. Hung. 19 (1), pp. 57–71, 1971

Department of Neurology and Psychiatry (Head: prof. St. KÖRNYEY)
University Medical School, Pécs

A PRINCIPLE FOR SILVER STAINING OF TISSUE ELEMENTS BY PHYSICAL DEVELOPMENT

F. GALLYAS

(Received 15 August, 1970)

The principle which we propose for silver staining has the following advantages over silver impregnation. (1) Its chemical and physical processes are known and standardizable, which make staining with it easily reproducible; (2) the intensity of staining can be controlled by varying the time of development.

A solution of a certain substance is used which combines with or is adsorbed on the tissue elements to be demonstrated in a much higher degree than on the others. The molecules of this substance, bound on the sections, are replaced by colloidal silver grains with the help of chemical reactions. Finally the silver grains are enlarged to microscopic dimensions by physical development.

On the basis of this staining principle methods have been elaborated for demonstrating fibrous neuroglia, micro- and oligodendroglia, Alzheimer's neurofibrillary changes, myelin, degenerated axons and connective tissue.

Introduction

To eliminate the uncertainty in silver impregnation, LIESEGANG [6] introduced a special kind of reducing bath, the so-called "physical developer". It contains a reducing substance and some silver salt, and thus the silver atoms participating in the growth of the silver grains in photographic emulsions or in tissue sections derive from the developer itself [7].

Silver staining with a physical developer has two advantages over the use of a simple solution of a developing agent with: (1) its chemical and physical processes are known and standardizable so that staining with it is reproducible; (2) the intensity of staining (i.e. the size of the silver particles formed) can be controlled by varying the time of development.

Despite these advantages, physical development has up to now been utilized only, for demonstrating axons and incorporated heavy metals. The methods for staining axons are in fact modifications of the impregnation techniques serving the same purpose, in which, however, enlargement of the silver nuclei produced by the reducing groups of axons is achieved by physical development without [6; 8] or after removal [9—10] of the silver ions from the sections. The principle of the histochemical demonstration of heavy metals (the so-called "sulphide silver" techniques [12—15] is as follows. The material to be stained is fixed in alcohol containing sulphide ions; the latter combine

with the heavy metals forming insoluble metal sulphides which then act as nuclei for physical development.

Intrigued by the advantages of physical development, we have carried out investigations into the possibilities of its general application. As a result, we have devised a principle for silver staining which allows a selective demonstration of fibrous neuroglia, micro- and oligodendroglia, Alzheimer's neurofibrillary changes, myelin, degenerated axons and connective tissue. A detailed description of the individual methods and discussion of their processes will be the subject of separate communications [2—4].

The proposed principle for silver staining

To silverize tissue elements, submicroscopical metallic silver particles are made to deposit on them and subsequently enlarged to microscopic dimensions by means of a physical developer. The silver grains acting as nuclei for the development are produced in the following manner (Table I): Tissue sections are

Table I

General pattern of the proposed staining principle

tissue-element + DS	$\xrightarrow[\text{chemical reaction}]{\text{adsorption or}}$	tissue-element—DS
tissue-element—DS	$\xrightarrow{\text{chemical reaction}}$	.....
.....	$\xrightarrow{\text{chemical reaction}}$	.....
.....	$\xrightarrow{\text{chemical reaction}}$	tissue-element—$Ag_{(coll.)}$
tissue-element—$Ag_{(coll.)}$	$\xrightarrow[\text{development}]{\text{physical}}$	tissue-element—$Ag_{(micr.)}$

DS = determinant substance (the substance determining the distribution of silver in the final picture)

immersed in the solution of a certain substance (which will be referred to as a "determinant substance", i.e. the substance determining the distribution of silver in the final picture) and which combines with or is adsorbed on the tissue element to be silverized in a much higher degree than on the others. The molecules of this substance, bound on the tissue elements, are replaced by metallic silver with the help of chemical reactions. Selective staining can be achieved only if the bound quantity of the "determinant substance" is so small that silver grains of colloidal dimensions are formed as a result of the replacement. The reactions must take place in a heterogenous phase. In this way an insoluble compound is always formed from another insoluble substance. Consequently, the silver nuclei representing the final result of these reactions, as well as the microscopic silver particles resulting from the enlargement of

the nuclei by physical development, are located in the very tissue element by which the determinant substance has been bound.

Two ways of replacing the determinant substance by metallic silver can be taken into consideration: converting it into another compound which (1) precipitates silver ions (Table II. a), or (2) reduces silver ions (Table II. b). For this reason, every inorganic or organic compound which is able to precipitate or reduce silver ions or can be converted into such a compound, as well as molecules, colloids or complexes of silver salts and, finally, colloidal silver can be used as determinant substance. Naturally, the chemical components themselves of the tissue element to be silverized may also serve as determinant substance.

Results and discussion

The physical developer

Preliminary examinations have shown that the physical developer suitable for the proposed silver staining had to fulfil the following conditions:

(1) The time needed for the silver nuclei deposited on the tissue elements to grow to microscopic dimensions (in other words, the time of development) should be about 10 minutes. This permits easy observation of the point when optimum staining has been reached (see below). Besides, uniform staining of sections with a large cut surface can be attained only if the time required for them to unfold is considerably shorter than that of the development.

(2) Silver particles should not be produced within the solution itself during the time of development. Some of the silver particles formed within the solution would precipitate on the surface of the sections and result in undesirable staining.

(3) The rate of formation of "tissue-produced nuclei" should be slow enough to ensure that no considerable number of microscopic silver particles develops as a result of their being increased. In a solution of silver salts the reducing groups present in the tissue elements convert silver ions into silver grains of colloidal dimensions, which are deposited at the site of their formation. (These grains will henceforward be referred to as "tissue-produced nuclei". If the solution containing the silver ions is a physical developer, the tissue-produced nuclei immediately begin to grow. The staining produced by this mechanism (the "tissue-produced silver staining") interferes with or suppresses the silver picture having its origin in the determinant substance bound to the tissue element to be silverized.

(4) The physical developer should not dissolve the silver salts insoluble in water. For replacing the determinant substance by silver nuclei, as outlined in Table IIa, tissue sections are immersed in solutions of a silver salt, a reducing agent and a physical developer in succession. As the latter contains both silver

Table II

Replacement by metallic silver particles of the determinant substance by converting it into another compound able (a) to precipitate silver ions or (b) to reduce silver ions

a

tissue-element + DS	adsorption or chemical reaction →	tissue-element—DS
tissue-element—DS	chemical reaction →	....
.....	chemical reaction →	....
.....	chemical reaction →	tissue-element—PA
tissue-element—PA + Ag^+	chemical reaction →	tissue-element—PA—Ag^+
tissue-element—PA—Ag^+	reduction →	tissue-element—$Ag_{(coll.)}$
tissue-element—$Ag_{(coll.)}$	physical development →	tissue-element—$Ag_{(micr.)}$

b

tissue-element + DS	adsorption or chemical reaction →	tissue-element—DS
tissue-element—DS	chemical reaction →	....
.....	chemical reaction →	....
.....	chemical reaction →	tissue-element—RA
tissue-element—RA + Ag^+	reduction →	tissue-element—$Ag_{(coll.)}$
tissue-element—$Ag_{(coll.)}$	physical development →	tissue-element—$Ag_{(micr.)}$

DS = determinant substance
PA = precipitating agent
RA = reducing agent

salt and reducing agent, the last three steps of the substitution may occur in the physical developer itself, provided it does not dissolve the water-insoluble silver salts. Therefore treating the sections in separate solutions of silver salt and reducing agent as well as washings in distilled water become superfluous.

(5) The pH of the physical developer should not be less than 7. In the course of replacing the determinant substance by silver nuclei, the tissue sections are placed in a solution containing silver ions, in which an insoluble silver salt (Table IIa) or colloidal silver grains (Table IIb) will be formed. As more substances have the ability to reduce silver ions or form insoluble salts with them in neutral and still more in alkaline media than in an acid one, it is expedient to use an alkaline solution of silver ions, or an alkaline physical developer if the possibility mentioned in paragraph 4 is to be taken advantage of.

We propose a physical developer, which is composed as follows.

2.5% of sodium carbonate,
0.100% of silver nitrate,
0.095% of ammonium nitrate,
0.50% of tungsto-silicic acid and
0.013—0.125% of formol (depending on room temperature).

Sodium carbonate ensures an optimum of alkalinity (pH 10.3) for suppressing the disturbing tissue-produced silver staining. The rate of formation of tissue-produced nuclei depends on the pH of the solution containing silver ions. To examine this, tissue sections of human brain, liver, spleen, kidney and muscle were fixed in commercially available formol for three days and then immersed in 0.05% silver nitrate solutions of different pH values. The solutions also contained 0.1% ammonium nitrate to prevent the formation of silver hydroxide or carbonate, 1% sodium borate to be buffered in the mild acid and alkaline pH range and 10% sodium nitrate to keep ionic strength at a constant level. The solutions were adjusted to pH values between 1 and 14 by nitric acid or sodium hydroxide. The sections were removed from the solutions at intervals, washed in 2% sodium sulphite then in distilled water to remove the combined silver ions and finally immersed in TIMM's [13] physical developer (5 parts of 40% gum-arabic, 1 part of 1.2% boric acid, 0.3 parts of 10% silver nitrate and 1.2 parts of 2% hydroquinone solution). This developer is of moderate acidity and, for this reason, tissue-produced silver nuclei are not formed in it. Consequently, if any staining appears it may only originate from an enlargement of the nuclei formed in the 0.05% silver nitrate solutions. The time was recorded during which the sections placed in the silver nitrate solutions had formed enough silver nuclei to lend the sections a deep brown colour after 10 minutes of development (Fig. 1). The sections which had been treated with silver nitrate solutions of a pH less than 4, failed to stain even after 120 minutes incubation. In cerebral grey matter the time of formation of silver nuclei in sufficient amounts decreased gradually below and rapidly above pH 11. As for white matter, the curve characterizing the relationship between pH value and the time of formation of nuclei shows an abrupt drop with a minimum at pH 7—8 then it increases to about pH 10, to decline again above pH 11. On the curve for white matter of a material having been fixed in formol for 6 months there is also a minimum at about pH 7—8, which, however, is less distinct than that mentioned above. White matter fixed in formol for 5 years did not form silver nuclei considerably faster than grey matter along the whole pH range. In the case of the organs examined the correlation under discussion ran a course similar to that of cerebral grey matter. From the above facts it follows that an acid physical developer does not produce nuclei. Despite this fact, in the proposed silver staining the application

of an acid physical developer would be impracticable, because, although not offering the advantage outlined in paragraph 4, it would fail to prevent the formation of tissue-produced nuclei. Viz., in the course of replacement of the determinant substance by silver nuclei the sections have to be placed in an alkaline solution containing silver ions (s. paragraph 5). In determining the

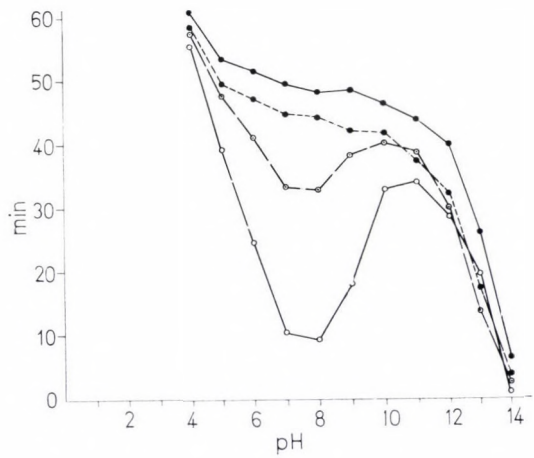

Fig. 1. The time needed for the formation of tissue-produced nuclei as a function of the pH of 0.05% silver nitrate solutions. White matter of human brain fixed in formol for 3 days (○), 6 months (⊙), 5 years (⊕); grey matter of human brain fixed in formol for 3 days (●)

optimum pH value for the physical developer, the above-mentioned peculiar behaviour of cerebral white matter must not be left out of consideration. Because it is at about pH 10.5 that the rate of formation of tissue-produced nuclei is the lowest in the alkaline pH range, the pH of our physical developer is adjusted to 10.3 by sodium carbonate.

The other factor on which the rate of formation of tissue-produced nuclei depends is *the concentration of silver ions*. To examine this dependence, sections of human brain fixed in formol for three days, cut 20 μ thick were immersed in silver nitrate solutions of various concentrations. The solutions contained 5% sodium carbonate, to be buffered at pH 10.3, and also ammonium nitrate, in an amount equivalent to the silver ions, to prevent the formation of insoluble silver carbonate. The sections were removed from the solutions at intervals, washed first in 2% sodium sulphite then in distilled water and finally placed in TIMM's physical developer. The length of time was recorded in which the sections placed in the silver nitrate solutions had formed enough silver nuclei to lend the sections a deep brown colour after 10 minutes of development.

Fig. 2 shows that the time of formation of tissue-produced nuclei increases with the decrease in silver ion concentration. It seems to be expedient to choose the silver nitrate concentration of the developer as low as possible, the limit being set by the requirement that the developer should contain reducible silver in sufficient amounts to enlarge the nuclei having their origin in the

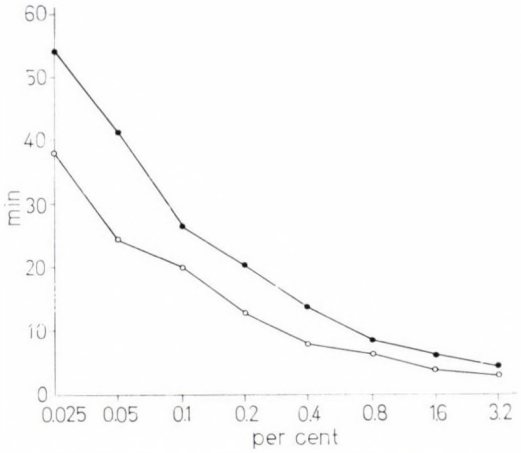

Fig. 2. The time needed for the formation of tissue-produced nuclei as a function of the concentration of silver nitrate solutions at pH 10.3. ○ white, ● grey matter of human brain fixed in formol for 3 days

determinant substance deposited in the sections. The silver nitrate concentration of our physical developer is 0.1%. Thus 1 ml of it can ensure the growth of as many silver nuclei as are deposited in 2 sq.cm of a section.

In view of the presence of carbonate and hydroxide ions in the physical developer, the silver ions in it have to be masked by a complexing agent. For this purpose *ammonium nitrate* is used in an amount just sufficient for keeping the silver nitrate content in solution, as an excess of complexing agent is undesirable (s. paragraph 4).

The speed of reduction of silver ions in a physical developer can be slowed down by adding to it a protective colloid or an excess of complexing agent [7]. Since the latter is to be avoided the protective action of various substances of high molecular weight was tested. Of these, *tungsto-silicic acid* proved to be the most suitable. To assess the dependence of the protective activity on the tungsto-silicic acid concentration, physical developers containing various amounts of this acid were tested at different temperatures. The length of time between the preparation of the solutions and their beginning to become turbid from metallic silver particle formation was recorded. Fig. 3 shows that this time increased with the rise in tungsto-silicic acid concentration. If this exceeds 0.5%, an unidentified compound will precipitate some minutes after prepara-

tion of the developer which, thereby, becomes useless. In a physical developer containing 0.5% tungsto-silicic acid no metallic silver particles are formed, or can be detected with the naked eye within 1—2 hours, depending on the temperature. In contrast, in the developer the sections are kept for a period of 10—30 minutes, which includes the time necessary for the last two reactions of replacement of the determinant substance by silver nuclei and the time of development.

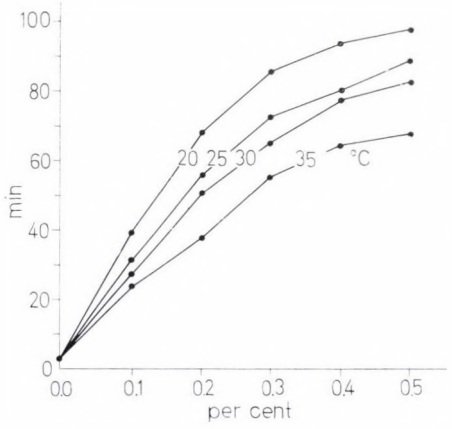

Fig. 3. The time needed for colloid silver particles to be produced in the physical developer as a function of its tungsto-silicic acid concentration at various temperatures

In our physical developer the reducing agent is *formol*, which has proved suitable in silver impregnation, too. To determine its optimum concentration, 20 μ thick tissue sections fixed in formol for three days were immersed in an 0.1% silver nitrate solution at pH 7.3 for 5 minutes, washed in 2% sodium sulphite solution then in distilled water and finally placed in our physical developer of various formol concentrations and temperatures. It was determined how long it took for the solutions to render the sections deep brown in colour by enlarging the nuclei produced in the 0.1% silver nitrate solution. As can be seen in Fig. 4, the time of development is a function of the formol concentration and temperature. In order to obtain a physical developer which develops in about ten minutes time, its formol concentration is to be adjusted depending on the solution's temperature (which is usually the same as the room temperature).

The physical developer is always prepared immediately before use by mixing three stock solutions. These, however, can be kept at room temperature for months. The stock solutions are composed as follows.

Solution A. Dissolve 50 g of sodium carbonate (analytic grade) (Na_2CO_3, anhydrous) in 1000 ml of distilled water.

Solution B. Dissolve 1.90 g of ammonium nitrate (analytic grade) (NH_4NO_3), 2.00 g of silver nitrate ($AgNO_3$) (analytic grade) and 10.00 g of tungsto-silicic acid (analytic grade) ($SiO_2 \cdot 12WO_3 \cdot 26H_2O$) in 1000 ml of distilled water in the order given.

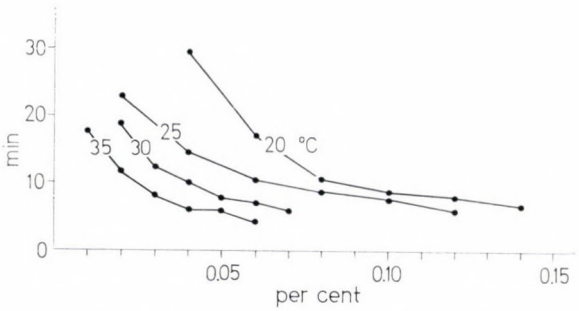

Fig. 4. The time of development as a function of formol concentration of the physical developer at various temperatures

Solution C. Dissolve 1.90 g of ammonium nitrate, 2.00 g of silver nitrate, 10.00 g of tungsto-silicic acid and 7.3 ml of 35%, or 6.1 ml of 40% formol in 1000 ml of distilled water, in the order given.

The stock solutions should be mixed according to the standards given in Table III.

Table III

Stock solutions for the physical developer at various room temperatures and the concentrations of formol in the mixture

Temperature °C	Sol. A ml	Sol. B ml	Sol. C ml	Formol-concentration, per cent
15 ± 2	10	0	10	0.125
20 ± 2	10	3	7	0.086
25 ± 2	10	5	5	0.063
30 ± 2	10	7	3	0.040
35 ± 2	10	8	2	0.025
40 ± 2	10	9	1	0.013

First solution B then solution C is added to solution A with a pipette in a thin jet. While pipetting, and for some time thereafter, the mixture is vigorously stirred. If the order of mixing is inverted, or the solutions are added too quickly, or stirring is not vigorous enough, a white precipitate will form which spoils the developer.

Having been placed in the physical developer, the tissue sections carrying the silver nuclei will little by little become black in colour, passing through the tints of yellow and brown. The colour of the sections showing optimum

staining under the microscope varies with the tissue elements to be silverized. To terminate development, the sections are transferred into a 0.5% solution of acetic acid or some other weak acid. Optimum staining of the sections can be checked on the basis of their colour. Until sufficient practice has been acquired it is advisable to develop 3—4 sections simultaneously and to remove them one by one at intervals of two minutes after their beginning to become pale brown in colour. Among these sections there will be one showing optimum development. Growing of the silver particles can be observed under the microscope. For this purpose the sections to be checked are placed in 0.5% acetic acid solution in order to arrest temporary development and, after the microscopic examination, placed back in the developer for continuing development if necessary.

Decreasing the rate of formation of tissue-produced silver nuclei by pretreatment

The formation of tissue-produced nuclei in our physical developer is not to be neglected if the last reactions which replace the determinant substance by colloidal silver grains, viz., those that occur in the physical developer, take longer than the formation of tissue-produced silver nuclei. To prevent the disturbing tissue-produced silver staining, we have attempted to decrease the rate of formation of tissue-produced nuclei by pretreating the sections. Two kinds of such pretreatment could be considered, (i) to decrease the number of reducing groups in the tissue elements; (ii) to decrease the capacity of the tissue elements for binding colloidal silver.

For decreasing the number of reducing groups the following alternative presents itself: (a) blocking or (b) eliminating them. By blocking the aldehyde, keto, hydroxyl, sulphydryl and amino groups and the unsaturated bonds [1] the time that the formation of tissue-produced nuclei takes could not be prolonged for each tissue element. Of the procedures tested the blocking of hydroxyl and amino groups by acetylation proved to be the most successful. It suppresses the formation of tissue-produced nuclei in all tissue elements except myelin and erythrocytes. The abolition of reducing groups by oxidation resulted in a considerable decrease in the rate of formation of tissue-produced nuclei in all the tissue elements concerned. Three strong oxidizing agents were tested, potassium permanganate, sodium-bismutate and periodic acid. They showed similar effects. Of the three agents we chose periodic acid because it did not render the sections fragile and its excess could be removed from the sections by washing in water [5]. To determine its optimum concentration and the optimum duration of treatment of the sections in it, frozen sections 20μ thick of human brain having been fixed in formol for some days were immersed in periodic acid solutions of various concentrations and tempera-

tures. The sections were removed from the solutions at intervals of 5 minutes, washed with distilled water and placed in the physical developer. It was determined how long it took for the sections to become deep brown in colour (Fig. 5). This period (i.e. the time needed for the tissue-produced silver staining to develop) consists of two components. One is the time required by the forma-

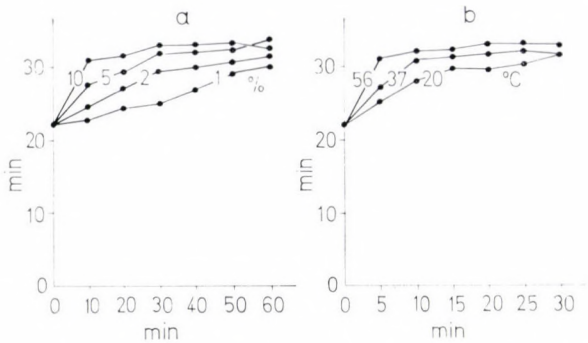

Fig. 5. The time needed for tissue-produced silver staining to develop in the physical developer as a function of the time of a previous incubation of the sections in periodic acid. *a* 1, 2, 5 and 10% periodic acid, 20 °C; *b* 5% periodic acid, 20, 37, 56 °C

tion of the tissue-produced nuclei; it can be varied by changing the length of pretreatment. The other component is the time of development; it is constant in a physical developer of given concentration and temperature, i.e. independent of the pretreatment. Consequently, from a prolongation of the time needed for the tissue-produced silver staining to develop it can be inferred that the rate of formation of the tissue-produced nuclei has decreased. Fig. 5 shows that pretreatment with periodic acid can prolong this time only up to a certain limit which can be reached in less time by using a periodic acid solution of higher concentration and temperature. We incubate the sections in 5% periodic acid solution at room temperature for 30 minutes if necessary. This results in a prolongation by about 40% of the time needed for the tissue-produced silver staining to develop.

It is well-known that periodic acid can form reducing groups while it eliminates others. Thus, it converts 1,2-glycol groups into aldehydes. It appears that the aldehyde groups form silver nuclei more slowly at the pH of the physical developer than do the reducing groups that have been abolished by the periodic acid. However, on increasing the pH the reducing strength of the aldehyde groups increases, and beyond pH 12 a pretreatment with periodic acid shortens the time necessary for the development of the tissue-produced silver staining in certain tissue elements containing 1,2-glycol groups [4].

The capacity of tissue elements to bind colloidal silver depends on the distribution of their positively and negatively charged chemical groups, which

is not uniform. There are sites with relatively more positive charges and vice versa. In the course of their formation, tissue-produced silver grains obtain negative charges by absorbing anions and are deposited on the positively charged sites of the sections [11]. Bearing the above fact in mind, two ways can be thought of to decrease the capacity of tissue elements to bind colloidal

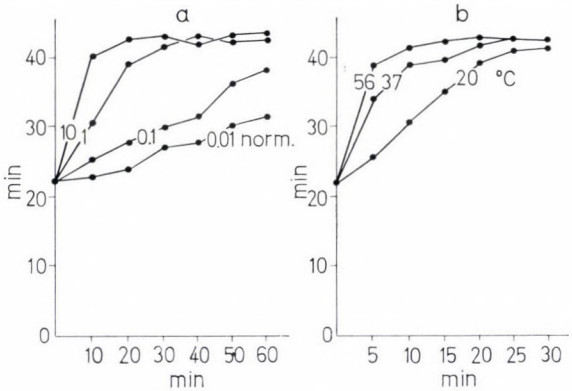

Fig. 6. The time needed for tissue-produced silver staining to develop in the physical developer as a function of the time of a previous incubation of the sections in sodium hydroxide. *a* 0.01*n*, 0.1*n*, 1*n* and 10*n* sodium hydroxide, 20 °C; *b* 1*n* sodium hydroxide, 20, 37 and 56 °C

silver, (i) blocking their positively charged sites with the help of negatively charged compounds; (ii) modifying the distribution of charges on the sections. For blocking the positively charged sites we have not been able to find any substance which would have prolonged the time needed for tissue-produced silver staining to develop in each tissue element. However, the tissue-produced silver staining of certain elements can be suppressed in this way (for instance, that of erythrocytes at pH 13 by sodium dodecyl-sulphate [4]).

For the modification of the distribution of charges on the sections the only possibility that presents itself is an alteration of the shape of the macromolecules. Such an alteration can be expected to result only under a strong effect, since the shape of the macromolecules is determined by the fixation. A slight prolongation of the time needed for tissue-produced silver staining to develop was obtained on incubating the sections in strong acids, hot water and lipid-solvents, and a substantial one by pretreatment with strong alkali. Sodium, potassium and lithium hydroxide proved to have the same effect. To determine the optimum concentration of the alkali and the optimum duration of treatment of the sections in it, frozen sections of human brain fixed in formol for some days and cut 20 μ thick were immersed in sodium hydroxide solutions of various concentrations and temperatures. Thereafter the sections were removed from the solutions at intervals of 5 min, washed with distilled water and placed in the physical developer. It was

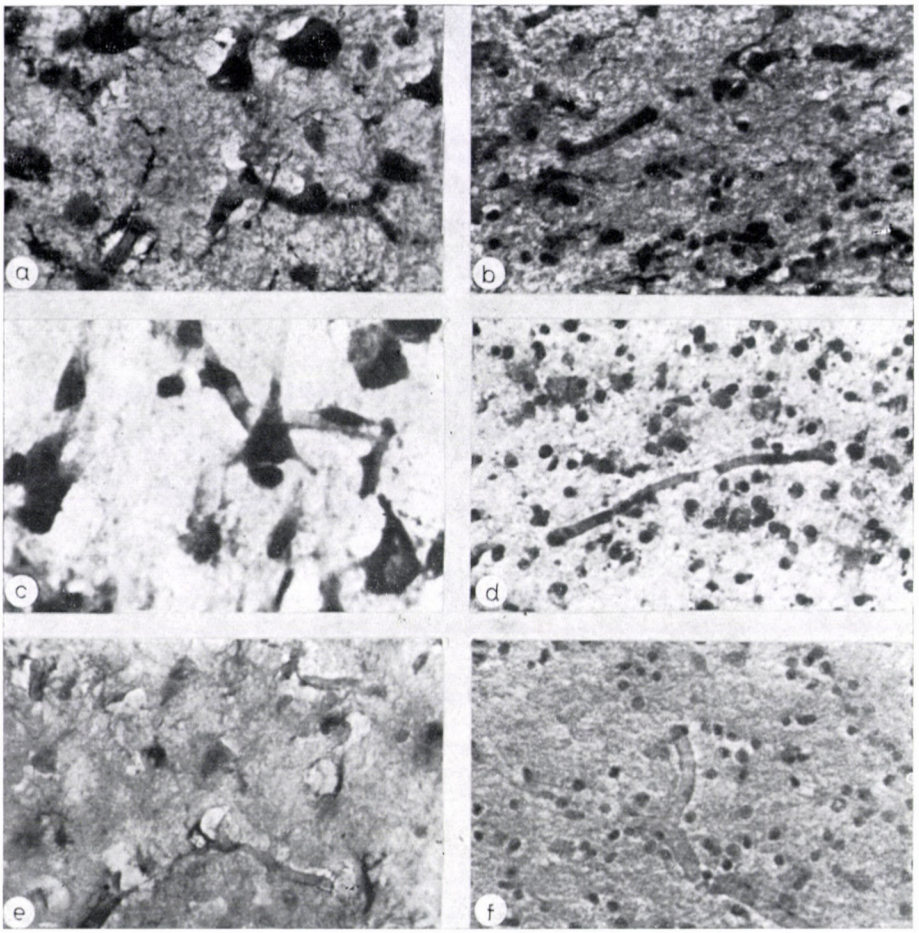

Fig, 7. Micrograms of tissue-produced silver staining in grey (a, c and e) and white (b, d and f) matter of human brain fixed in formol; *a* and *b*, unpretreated section after 22 minutes physical development; *c* and *d*, section pretreated with 5% periodic acid solution for 30 min, after 29 minutes of physical development; *e* and *f*, section pretreated with 4% sodium hydroxide for 30 minutes, after 42 minutes of physical development. ×400

recorded how long it took until the sections had become a deep brown in colour. Fig. 6 shows that sodium hydroxide pretreatment prolonged this period of time only up to a certain limit. A prolongation was achieved more easily by using a sodium hydroxide solution of higher concentration and temperature. We incubate the sections in a 4% solution of sodium hydroxide of room temperature, if necessary for 30 minutes; this results in a prolongation by about 90% of the time required for the tissue-produced silver staining to develop. The result of alkali treatment could not be influenced by subsequent incubation in acid solutions, indicating that the modification by alkali of the

distribution of charges in the tissue elements is irreversible. If the sections are treated in periodic acid and alkali in succession, the effects are additive.

On developing the tissue-produced nuclei in an unpretreated section of human brain fixed in formol, pathological micro- and oligodendroglia, nerve cells, erythrocytes, blood vessels and nuclei of endothelial and glia cells become visible (Fig. 7a, b). The rates of suppressing the tissue-produced silver staining by the two above-mentioned pretreatments are not the same for the various tissue elements enumerated above. That is why micro- and oligodendroglia fail to stain in sections pretreated with periodic acid, and why the background is considerably lighter compared with that of the unpretreated sections (Fig. 7c and d). Incubation of the sections in alkali before development suppresses the staining of all tissue elements, except that of fragments of pathological micro- and oligodendroglia, to the level of the background (Fig. 7e and f). In sections treated in both periodic acid and sodium hydroxide only pale spots of cell nuclei can be observed. Consequently, to prevent disturbing tissue-produced silver staining it is preferable to incubate the sections in alkali. A pretreatment with periodic acid is advisable only if that with alkali is to be avoided or if the latter alone has not proved effective. The introduction of alkaline treatment into the individual methods based on the proposed silver staining principle does not increase the number of steps. Namely, one of the reactions to replace the determinant substance by colloidal silver can generally take place in alkaline medium as well.

REFERENCES

1. Barka, T., Anderson, P. J.: Histochemistry: Theory, Practice and Bibliography. Harper and Row, New York. 1963. — 2. Gallyas, F.: (1970) Silver Staining of Fibrous Neuroglia by Means of Physical Development. Acta neuropath. (Berl.) **16,** 39 — 3. Gallyas, F. (1970): Silver Staining of Micro- and Oligodendroglia by Means of Physical Development. Acta neuropath. (Berl.) **16,** 35 — 4. Gallyas, F. (1970): Silver Staining of Collagen- and Reticulum Fibres and Cerebral Capillaries by Means of Physical Development. J. Microscopy. **91**, 1 — 5. Lhotka, J. F.: (1953) Effects of Oxidation on Neurofibrillar Argyrophylia. Stain. Techn. **28,** 101. — 6. Liesegang, R. E.: (1911) Die Kolloidchemie der histologischen Silberfärbung. Kolloid Beih. **3,** 1. — 7. Mees, C. E. K.: The Theory of the Photographic Process. McMillan, New York 1962. — 8. Pearson, A. A., O'Neill, S. L.: (1946) A Silver Gelatin Method for Staining Nerve Fibres. Anat. Rec. **95,** 297. — 9. Peters, A.: (1955) A General Purpose Method of Silver Staining. Quart. J. micr. Sci. **96,** 323. — 10. Samuel, E. P.: (1953) The Mechanism of Silver Staining. J. Anat. (Lond.) **87,** 278. — 11. Silver, M. L.: (1942) Colloida Factors Controlling Silver Staining. Anat. Rec. **82,** 507. — 12. Stegner, H. E., Fischer, W.: (1957) Das Sulfidsilberverfahren zum topochemischen Schwermetallnachweis. Virchows Arch. path. Anat. **330,** 608. — 13. Timm, F.: Zellmikrochemie der Schwermetallgifte. Habil.-Schrift, Leipzig (1932). — 14. Timm, F.: (1933) Neues zum Giftnachweis im Gewebe. Dtsch. Z. gerichtl. Med. **20,** 582. — 15. Voigt, G. E., Bog, R., Wolf, J.: (1954) Untersuchungen zum histotopochemischen Nickel- und Kobaltnachweis. Zbl. allg. Path. path. Anat. **92,** 1.

EIN NEUES PRINZIP FÜR DIE SILBERFÄRBUNG VON GEWEBEELEMENTEN DURCH PHYSIKALISCHE ENTWICKLUNG

F. GALLYAS

Das vorgeschlagene Prinzip für Silberfärbung bietet gegenüber der Silberimprägnierung folgende Vorteile: 1. Die chemischen und physikalischen Prozesse sind bekannt und können standardisiert werden, wodurch die Färbung leicht reproduzierbar wird; 2. die Färbungsintensität läßt sich durch das Variieren der Entwicklungszeit kontrollieren.

Man verwendet die Lösung einer bestimmten Substanz, die an die darzustellenden Gewebeelemente in bedeutend höherem Maße als an andere Gewebeelemente gebunden oder an ihnen adsorbiert wird. Die Molekeln dieser Substanz, die an den Schnitten gebunden sind, werden mit Hilfe chemischer Reaktionen durch kolloidale Silbergranula ersetzt. Schließlich werden die Silbergranula mittels physikalischer Entwicklung bis zu mikroskopischen Dimensionen vergrößert.

Aufgrund dieses Färbungsprinzips wurden Verfahren für die Darstellung von fibrösem Neuroglia, Mikro- und Oligodendroglia, Alzheimersche Veränderungen der Neurofibrillen, Myelin, degenerierten Axonen und Bindegewebe entwickelt.

ПРИНЦИП ОКРАШИВАНИЯ СЕРЕБРОМ ТКАНЕВЫХ ЭЛЕМЕНТОВ ПУТЕМ ФИЗИКАЛЬНОГО ПРОЯВЛЕНИЯ

Ф. ГАЛЛЬЯШ

Предлагаемый принцип для окрашивания серебром имеет следующие преимущества перед импрегнацией серебром: 1. Химические и физические процессы метода известны и их можно стандартизировать, вследствие чего окрашивание становится легко воспроизводимым. 2. Интенсивность окрашивания можно проверять путем варьирования времени проявления.

Применяется раствор определенного вещества, которое в гораздо большей мере чем с другими элементами связывается с выявляемыми тканевыми элементами или адсорбируется на последних. При помощи химических реакций молекулы этого вещества, связанные со срезами, замещают зернышками коллоидного серебра. Затем зернышки серебра увеличивают при помощи физического проявителя до микроскопических размеров.

На основе этого принципа окрашивания были разработаны методы для выявления фиброзной нейроглии, микро- и олигодендроглии, Альцгеймеровских изменений нейрофибрилл, миэлина, перерожденных аксонов и соединительной ткани.

Dr. Ferenc GALLYAS Ideg- és Elmeklinika, Pécs, Rét u. 2.

Acta Morphologica Acad. Sci. Hung. 19 (1), pp. 73–80, 1971

Institute of Experimental Medicine, Hungarian Academy of Sciences, Budapest, Hungary

EFFECT OF ACTH ON REPLETION OF BLOOD IN THE ADRENAL AND OVARIAN TISSUES OF THE DOG

M. Palkovits, B. Varga and E. Stark

(Received October 16, 1970)

As measured by internal calorimetry, acute as well as chronic ACTH increases adrenal and ovarian blood flow in the dog. In animals killed at peak flow, the volume of blood in the glands is increased. This increase extends to all the glandular tissue elements. As the morphological changes induced by acute or chronic ACTH were corresponding to those observed earlier by physiological methods, it seems evident that the hormone-induced increases in blood flow and blood volume are concurrent processes.

ACTH has been shown to increase both adrenal [6] and ovarian [7] blood flow. With the hormone administered intravenously, the rise in flow is related to the dose and attains its maximum the first 2 minutes. Synthetic ACTH increases ovarian blood flow in the adrenalectomized animal, showing that this effect of the hormone is an extra-adrenal effect [7]. These flow data were obtained in dogs and cats [7] and in hamsters and rats [12] by the measurements based on thermal conductance or by the ^{86}Rb method [5]. As measured with heated thermocouples, the increase in blood flow induced by a single intravenous injection of ACTH took 20 to 40 minutes to return to its pre-ACTH value, depending on the dose applied; and each subsequent injection given when the effect of the preceding one had worn off, induced a new rise in blood flow [7, 8, 9].

The present work was undertaken to study whether a single dose of ACTH or its repeated injection would give rise to morphological changes corresponding to those obtained earlier by physiological methods.

Materials and methods

Twelve dogs of various age and body weight were anaesthetized with chloralose and urethane and adrenal and ovarian blood flow was measured by thermocouples [7] inserted into the glands on the left side of the body. In one experimental series, flows were registered for the first 5—6 hours, then each dog was given a single intravenous injection of 10 μg/kg b.wt. of $ACTH^{1-24}$ (Synacthen Ciba). When in the first two minutes the flows had attained their maximum, the animals were sacrificed by saturated potassium chloride. The control animals were treated in the same manner, except that they received physiological saline instead of ACTH. In another series of experiments, each animal was given through an intravenous cannula, daily for 5 days a total of 10 μg/kg b.wt. of $ACTH^{1-24}$ divided into several doses. On the 6th day, these dogs were subjected to the same procedure as that in the first experimental series.

Immediately after killing, the adrenals and ovaries were fixed in 6% formalin, embedded in paraffin, and sections 10 μ thick were cut at the largest sectional surface. To determine the volume of blood in the tissues, a modified Azan method (haematoxylin-aniline blue-erythrosin-orange G) was employed by which the ground tissue is stained blue and erythrocytes, purple.

Results

As in previous experiments [6—9, 11, 12], acute as well as chronic ACTH produced a rise in both adrenal and ovarian blood flow (Fig. 1). In the adrenal, the increase varied from 40 to 55%, exceeding it sporadically. In the

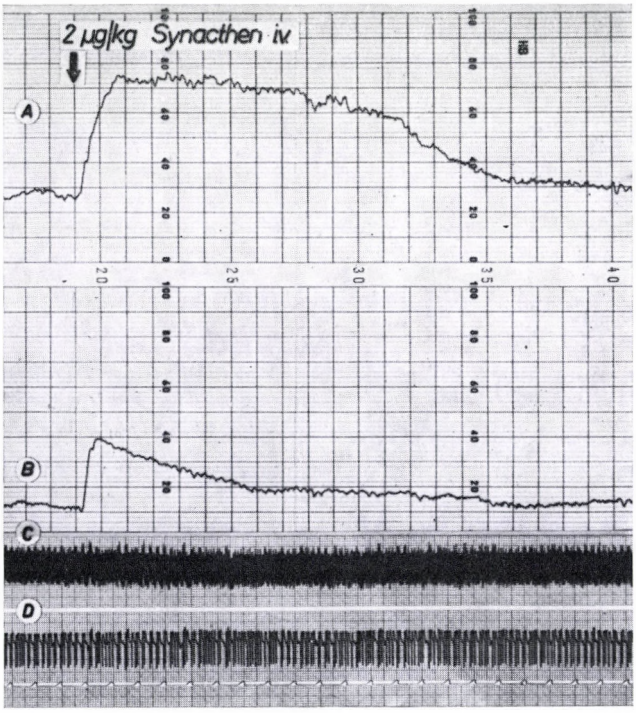

Fig. 1. Effect of ACTH on ovarian and adrenal blood flow. A: ovary; B: adrenal; C: arteria blood pressure; D: respiration. Time scale: 1 min.

ovary, it rose to even higher levels. Animals subjected to chronic ACTH treatment responded with much greater sensitivity to the dose administered on the 6th day. Inspection directly at removal showed the two organs to be swollen and hyperaemic both after acute and chronic exposure.

The histological study revealed in the adrenal that a single injection of ACTH increased the number of erythrocytes in both medulla and cortex (Fig. 2b). In the control animals, insertion of the thermocouple produced, apart from the local injury (Fig. 2d), no change either in morphology or in

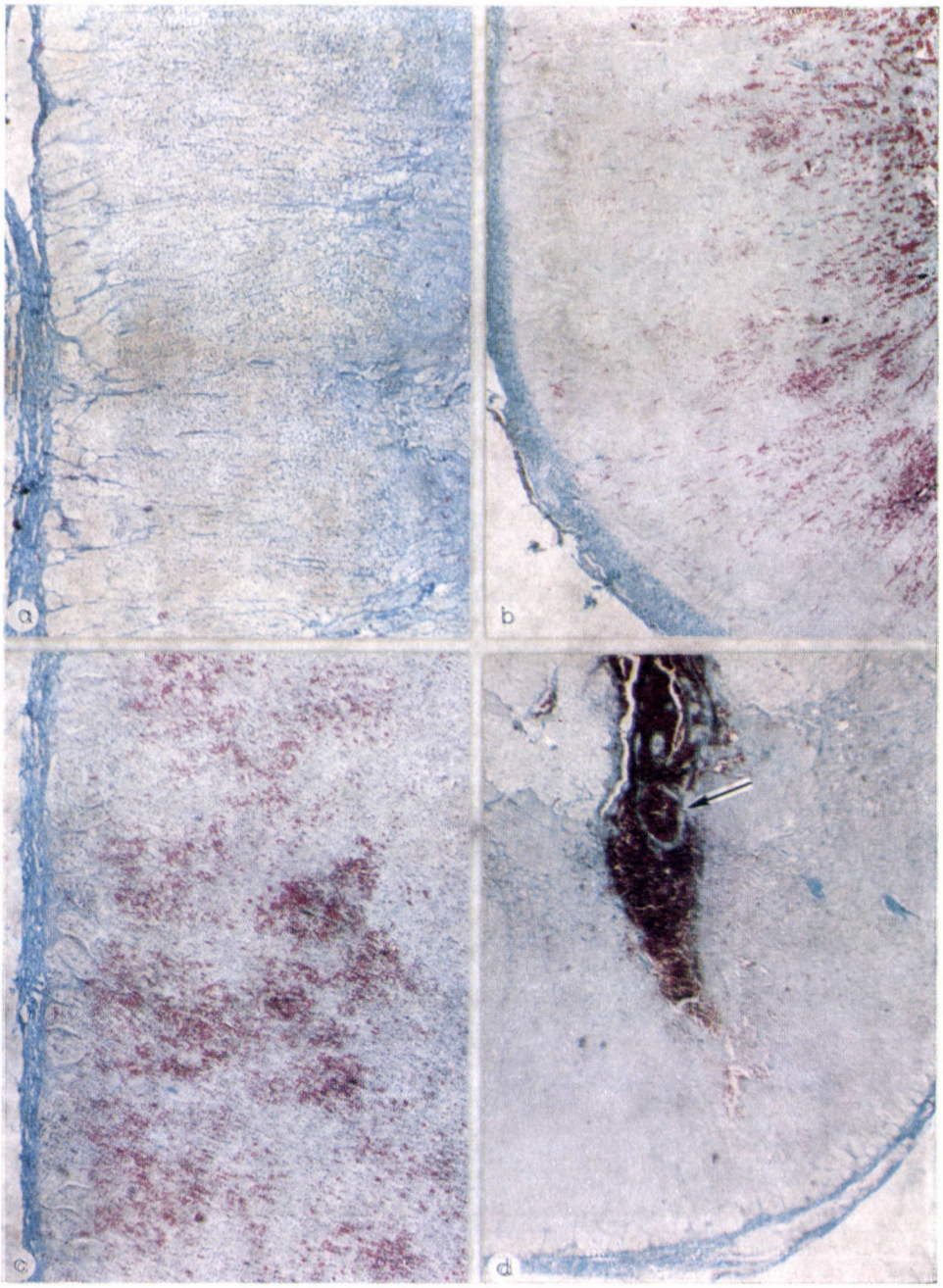

Fig. 2. Dog adrenal; modified Azan staining (×40). a) control, b) after a single injection of 10 μg/kg b.w. of ACTH, c) after an injection of 10 μg/kg b.w. of ACTH given to animal pretreated with ACTH for 5 days, d) control adrenal, showing stab wound caused by thermocouple

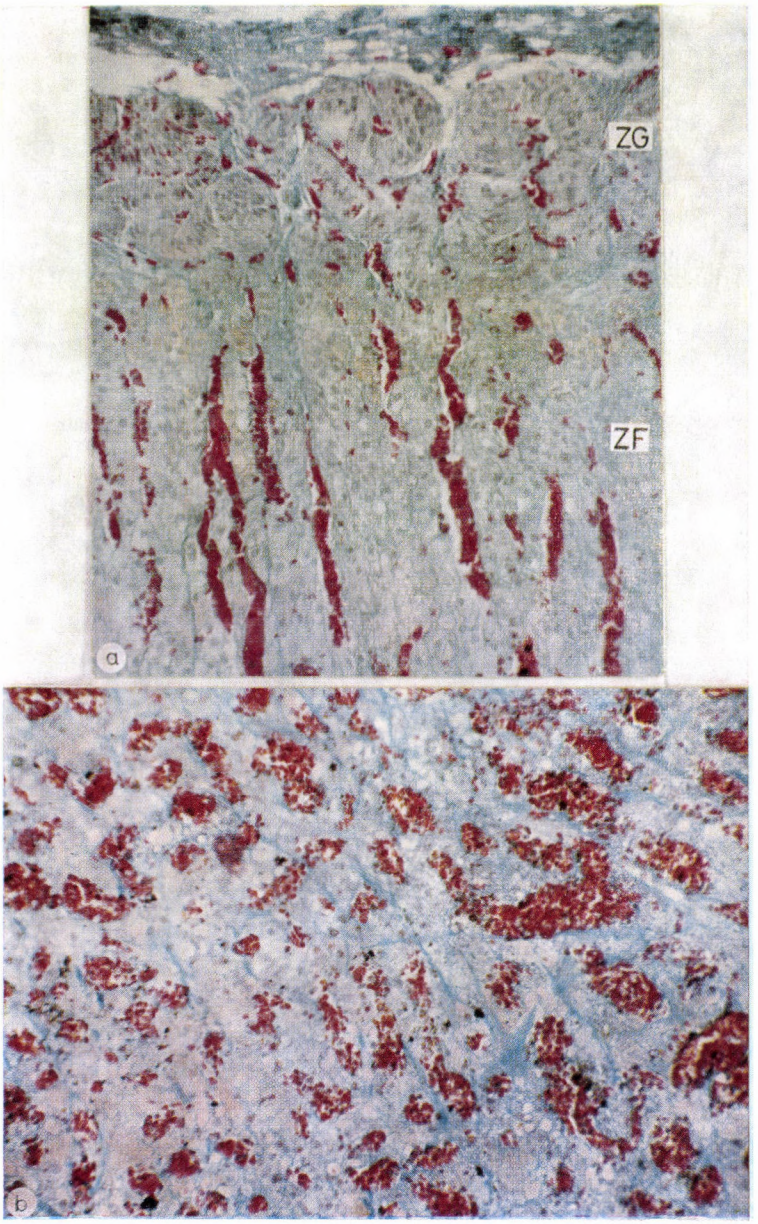

Fig. 3. Dog adrenal; modified Azan staining (×200) after an injection of 10 μg/kg b.w. of ACTH given to animal pretreated with ACTH for 5 days. a) zona glomerulosa (ZG) and zona fasciculata (ZF); b) zona reticularis

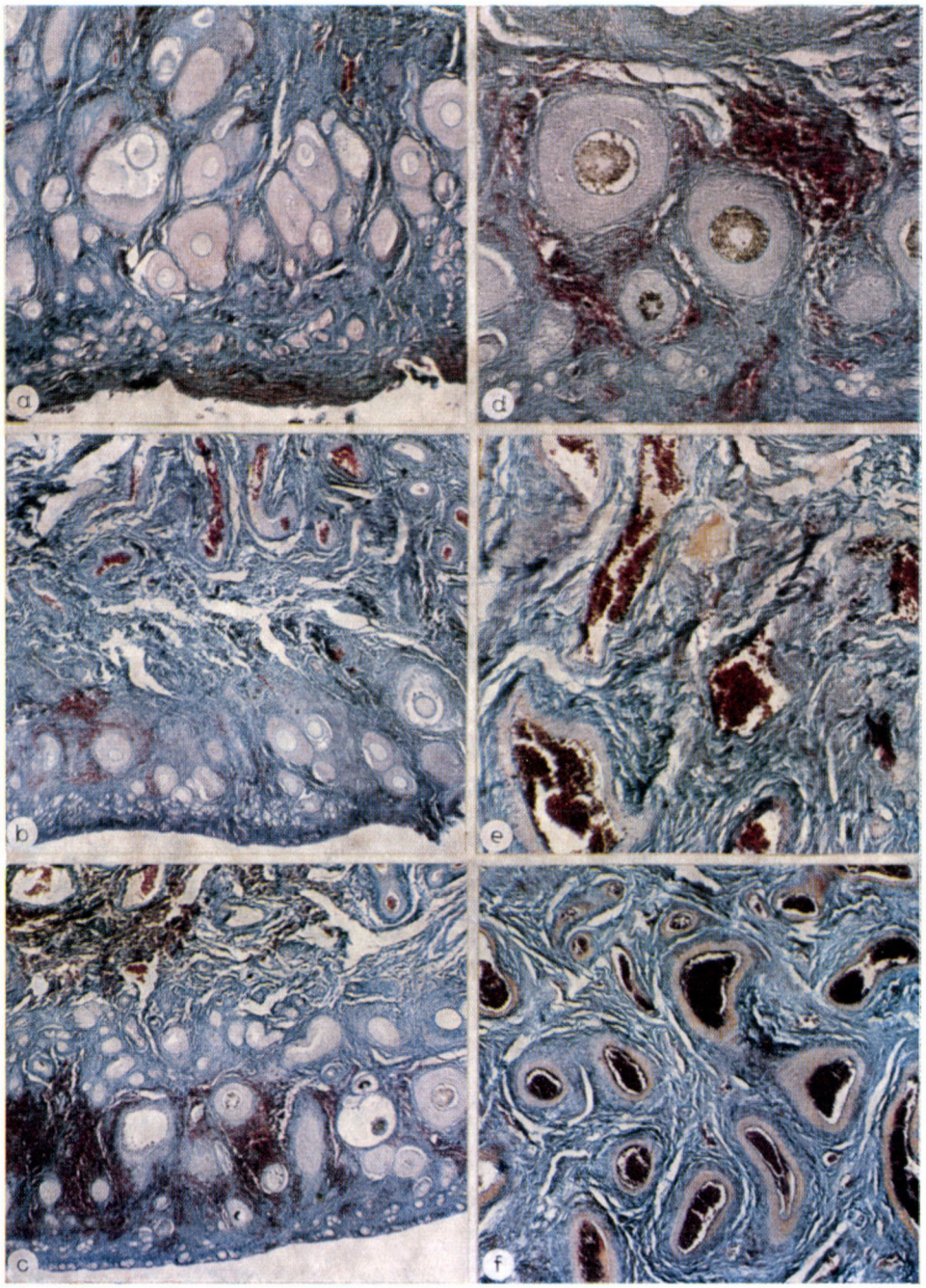

Fig. 4. Dog ovary; modified Azan staining. a) control (×32); b) after a single injection of 10 μg/kg b.w. of ACTH (×32); c) after an injection of 10 μg/kg b.w. of ACTH given to animal pretreated with ACTH for 5 days; d) extravascular erythrocytes among follicles (×80); e) stroma of ovary (×80); f) hilum of ovary (×80)

blood flow (Fig. 2a). In the zona glomerulosa the capillaries contained moderate amount of blood (Fig. 3a). In the zona fasciculata the sinusoids were dilated and replete with erythrocytes, and erythrocytes could be seen among the cells (Fig. 3a). Most conspicuous for repletion of blood was the zona reticularis, particularly near the boundary between the cortex and the medulla (Fig. 3b). Prolonged exposure to ACTH produced an even greater volume of blood in the adrenal gland (Fig. 2c).

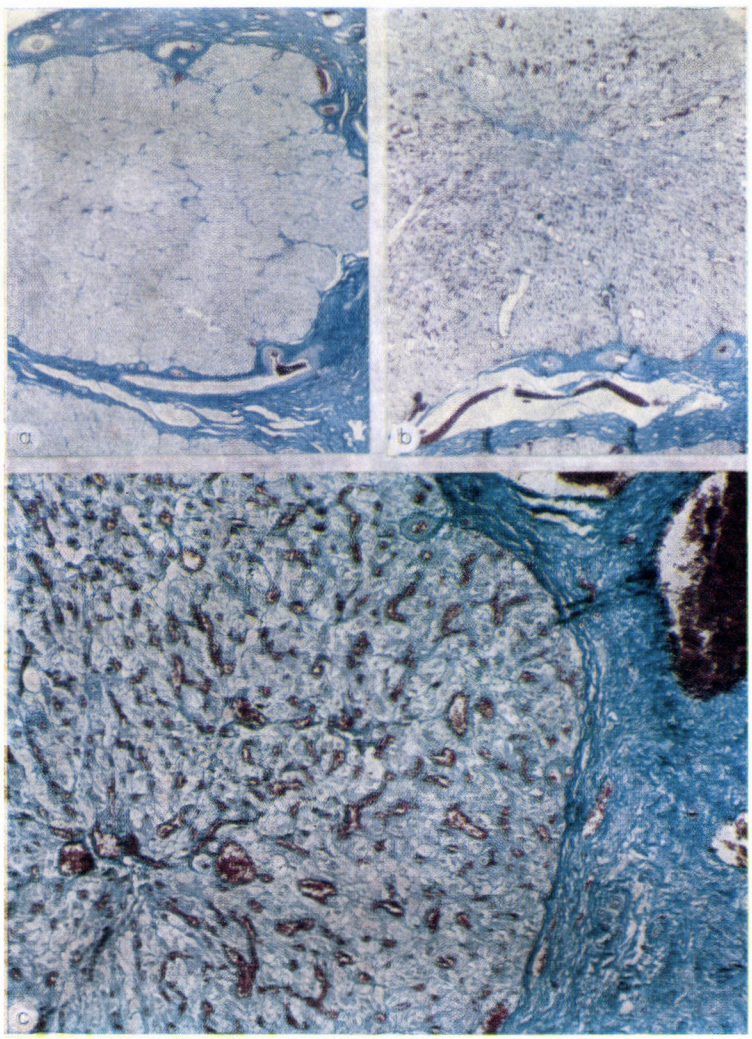

Fig. 5. Dog ovary; corpus luteum; modified Azan staining. a) control (×15); b) after a single injection of 10 μg/kg b.w. of ACTH (×15); c) after an injection of 10 μg/kg b.w. of ACTH given to animal pretreated with ACTH for 5 days

The histological picture of the ovary showed that a single injection of ACTH produced marked repletion when ovarian blood flow had attained its maximum. This repletion involved all the structural elements of the gland. Many erythrocytes were evident around the follicles, mostly within vessels (Fig. 4b), others in the stroma (Fig. 4e). Prolonged exposure to ACTH provoked a still greater increase in blood volume (Fig. 4c) with a great number of erythrocytes outside the vessels (Fig. 4d). The vessels in the hilum of the ovary were dilated and replete with erythrocytes both after acute and after chronic ACTH (Fig. 4f). The hyperaemia following ACTH treatment affected the corpora lutea (Fig. 5).

Discussion

Increased adrenal blood flow due to ACTH has been observed by many authors using various methods in various animal species [1, 3—8, 10, 12]. In earlier work [7, 8] we demonstrated by a method based on thermal conductance measurement that intravenous ACTH increases ovarian blood flow within the first two minutes after its administration. The present work yielded morphological evidence of a marked excess of blood in both organs at that time. Each subsequent injection of ACTH given after the effect of the preceding one had worn off, i.e. in 20—40 minutes, depending on the dose applied, again produced a rise in flow.

Our investigations offered no information as to whether the increase in blood volume caused in the tissues by the first ACTH injection still prevailed, at least in part, when the subsequent injection was being administered. If it did, then the rise in flow produced by the subsequent injection(s) obviously passed off in the presence of an increased repletion of blood in the tissues. In earlier reports [4, 6] it has been shown that the effects of ACTH in increasing adrenal blood flow and corticosteroid secretion are not directly related phenomena. From this it appears to follow that the blood flow-raising effect of ACTH is a "trophic" effect, independent of the corticosteroidogenic effect.

Kovács et al. [2] found that under the effect of chronic ACTH the increase in the adrenal fraction of cardiac output was less than that in adrenal weight; they concluded that the adrenal blood supply per unit weight was reduced. It is not known whether in our chronically treated animals the increase in blood flow was proportionate to the increase in adrenal weight, but we would emphasize that at no time during the 5-day treatment we were able to detect a lesion in any part of the cortex. Had the blood supply been impaired, we should have noticed lesions arising in the course of treatment. It needs to be mentioned that the dose of ACTH applied by us for pretreatment and as the last injection, was an order of magnitude less than that employed by Kovács et al. [2].

Both acute and chronic treatment with either naturally occurring or synthetized ACTH increases ovarian blood flow [8, 11]. In the present work, the histological picture of the ovary — like that of the adrenal — revealed an increased repletion of blood in the tissues and a high degree of venous filling. These morphological changes observed after acute and chronic ACTH treatment have corroborated those revealed earlier by the use of physiological methods. Further studies are required to elucidate the physiological significance of this effect of ACTH.

REFERENCES

1. Holzbauer, M., Vogth, M.: (1957) J. Physiol. (Lond.) **138,** 449. — 2. Kovács, K., Csernay, L., Szijj, I.: (1968) Kísérl. Orvostud. **20,** 422. — 3. Monos, E., Koltay, E., Kovách, A. B. G.: (1967) Acta physiol. Acad. Sci. hung. **31,** 149. — 4. Nichols, J., Richardson, A. W.: (1960) Proc. Soc. exp. Biol. (N. Y.) **104,** 539. — 5. Sapirstein, L. A., Goldman, H.: (1959) Amer. J. Physiol. **196,** 159. — 6. Stark, E., Varga, B., Ács, Zs., Papp, M.: (1965) Pflügers Arch. ges. Physiol. **285,** 296. — 7. Stark, E., Varga, B., Ács, Zs.: (1967) J. Endocr. **37,** 245. — 8. Stark, E., Varga, B.: (1968) Acta med. Acad. Sci. hung. **25,** 367. — 9. Stark, E., Varga, B., Medzihradszky, K., Bajusz, S., Hajtman, B.: (1970) Acta physiol. **38,** 193. — 10. Urquhart, J.: (1965) Amer. J. Physiol. **209,** 1162. — 11. Varga, B., Ács, Zs., Papp, M., Stark, E.: (1967) Endocr. exp. **1,** 173. — 12. Varga, B., Stark, E., Csáki, L., Marton, J.: (1969) Gen. comp. Endocr. **13,** 468. — 13. Wright, R. D.: (1963) Endocrinology, **72,** 418.

ACTH-EFFEKT AUF DIE HYPERÄMIE DER NEBENNIEREN- UND OVARGEWEBE BEIM HUND

M. PALKOVITS, B. VARGA und E. STARK

Durch innere Kalorimetrie wurde aufgezeigt, daß sowohl akute als auch chronische ACTH-Gaben einen Anstieg des Blutzustroms in die Nebennieren und die Ovarien des Hundes bewirken. Bei den im Maximum der Blutzufuhr getöteten Tieren war in den untersuchten Drüsen auch das Blutvolumen erhöht. Der Anstieg erfaßt sämtliche Elemente des Drüsengewebes. Da die durch akute oder chronische ACTH-Gaben herbeigeführten morphologischen Veränderungen den früher mit Hilfe von physiologischen Verfahren beobachteten Befunden entsprachen, scheint es evident zu sein, daß die hormonbedingten Durchblutungs- und Blutvolumensteigerungen gleichgerichtete Prozesse darstellen.

ДЕЙСТВИЕ ВВЕДЕНИЯ АКТГ НА НАСЫЩЕНИЕ КРОВЬЮ ТКАНИ НАДПОЧЕЧНИКОВ И ЯИЧНИКОВ У СОБАК

М. ПАЛКОВИЧ. Б. ВАРГА и Э. ШТАРК

На основе внутренней калориметрии, как острое так и хроническое введение АКТГ повышают кровоток в надпочечниках и яичниках собаки. У животных, убитых в момент максимального кровотока, в указанных железах нашли повышенный объем крови. Это повышение охватывает все тканевые элементы желез. Морфологические изменения, вызванные острым или хроническим введением АКТГ, соответствуют изменениям, наблюдавшимся раньше физиологическими методами исследования. Следовательно кажется очевидным, что вызванные гормоном повышения перфузии и повышения объема крови являются параллельными процессами.

Dr. Miklós Palkovits
Dr. Bertalan Varga
Dr. Ervin Stark

KOKI, Budapest VIII.,
Szigony u. 43, Hungary

Acta Morphologica Acad. Sci. Hung. 19 (1), pp. 81–87, 1971

Institute of Neurosurgery, and Department of Anatomy,
Semmelweis University Medical School, Budapest

EFFECT OF LOCAL COOLING ON THE FINE STRUCTURE OF THE CEREBRAL AND CEREBELLAR CORTEX

E. PÁSZTOR and J. HÁMORI

(Received December 15, 1970)

Local cooling to 8—10 °C of the cerebral and cerebellar cortex results in an apparent increase in number of microtubuli in the preterminal axons and causes a selective increase of density of the synaptic terminals. The changes are completely reversible and normal conditions are restored on rewarming the cortex to 37 °C. An attempt has been made to correlate these morphological alterations with the simultaneous development of electric silence in the cooled cortex.

Introduction

Short local cooling of the cerebral cortex below 20 °C cortical temperature results in a complete lack of cortical electric activity both in man [5] and in animals [4, 6]. Light microscopic investigations of cooled cortical regions [1, 2, 3] failed to reveal any correlative morphological alterations, indicating that corresponding structural changes, if any, ought to be looked for at the electronmicroscopic (EM) level. This paper reports some ultrastructural alterations observed in the axonal processes and synapses of the cooled cerebral and cerebellar cortex in the cat.

Material and methods

In six cats under pentobarbital anaesthesia the parietal cortex was exposed and the right hemisphere was cooled by sprinkling with 4 °C mammalian Ringer solution. The temperature of the cortex, measured by surface and intracortical thermistors, fell in 2—10 minutes to 8—16 °C on the surface, and to 14—24 °C in the deeper layers. At this stage — during the complete absence of any electric activity, small pieces were excised from the cortex and immediately fixed in glutaraldehyde of pH 7.4, at 20 °C temperature. The blocks were kept in the aldehyde solution for two hours, rinsed briefly in buffer solution, postosmicated for another 30 minutes, dehydrated in ethanol, and embedded in Durcupan. Control material was obtained from the exposed — non-cooled — left parietal cortex.

In a second experimental series the cortex of the right cerebellar hemisphere was cooled and than processed as described above while the left cerebellar cortex was used as control.

After identification of the cortical layers in toluidine blue stained semi-thick sections, ultrathin sections were made by an LKB ultrotome of the superficial layers of the cerebral cortex and of all three layers of the cerebellar cortex. The sections were stained with uranyl acetate and lead citrate and examined with a Tesla BS 413 A type electron microscope.

Densitometric measurements of the electronmicrograph negatives were made by aid of a Zeiss densitometer.

Results

Local cooling to 8—10 °C of the cerebral and cerebellar cortex did not bring about significant changes in tissue structure; the only alteration that could be observed even under small EM power was an apparent increase in the number of microtubuli in the preterminal axons (Figs 1—4), whereas plasma structure, perikaryon density and the thicker dendrites were practically unchanged.

Similarly, no conspicuous gross change occurred in the structure of the predominantly axodendritic synapses (Figs 3—4). However, densitometric analysis of 580 synaptic contacts in the photographic plates revealed a signif-

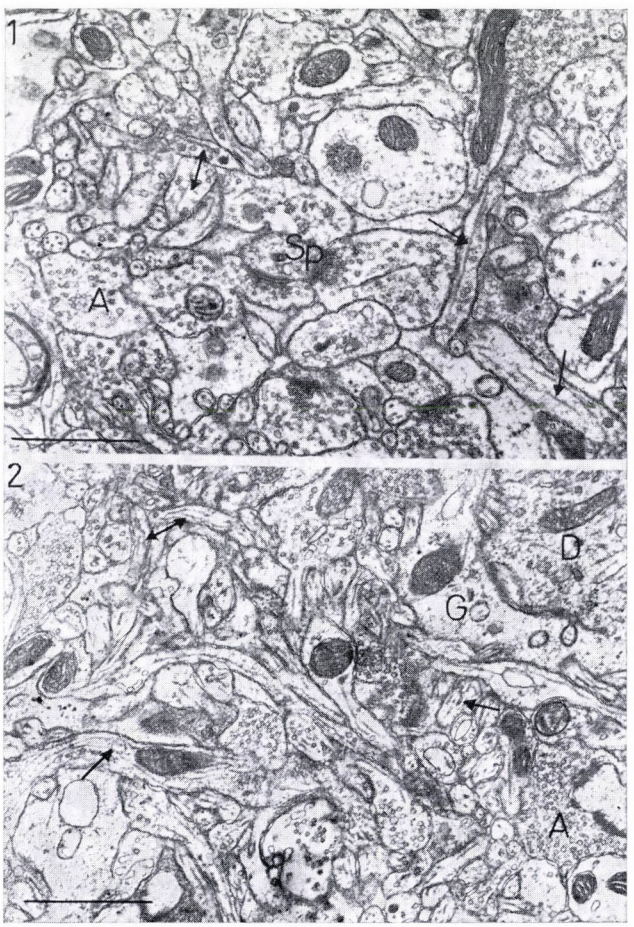

Fig. 1. Control parietal cortex of cat, lamina I. *A* = axon terminal with synaptic vesicles; *Sp* = dendritic spine in synaptic contact with the axon terminals. Arrows point to microtubules in preterminal axons. Scale, 1 micron

Fig. 2. Cooled (10 °C) parietal cortex, lamina I. *D* = dendrite, *G* = glial process, *A* = axon terminal. Apparent hypertrophy of microtubules (arrows) in thin preterminal axons

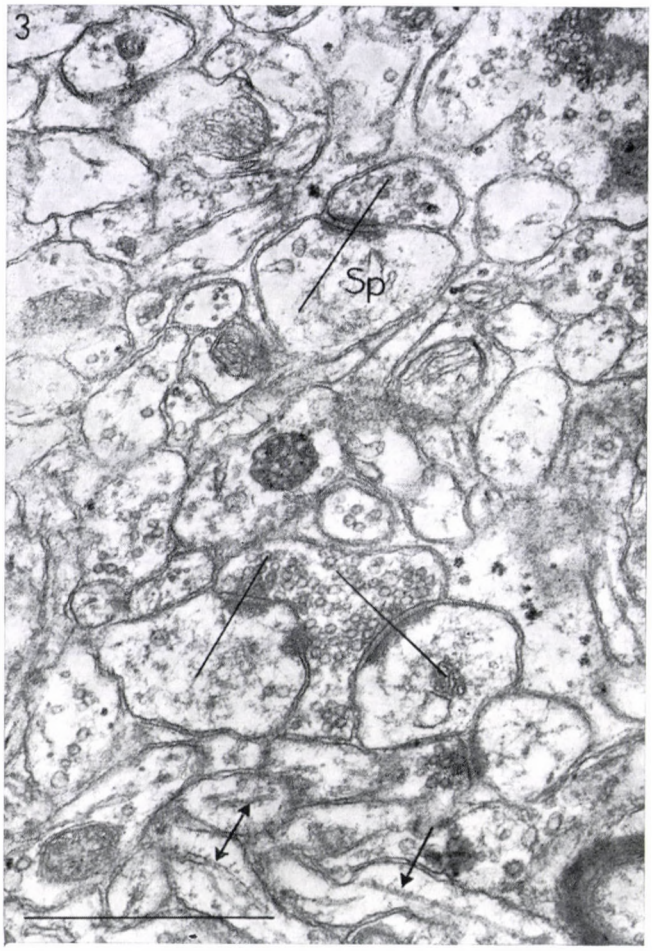

Fig. 3. Higher magnification of control cortex, lamina I. Density measurements of synaptic participants (axon terminal and dendritic spine — *Sp* —) were made along the black lines (see Table I). Arrows point to microtubules in preterminal axons

Table I

Density values of dendritic spines and axon terminals of cat parietal cortex, lamina I

	Axon terminal	Dendrite (spine)	Axon density in % of Dendritic spine density
I/1 Control	5.84 ± 0.21	6.85 ± 0.25	85.2
I/2 Cooled	6.46 ± 0.27	6.70 ± 0.19	96.4
II/1 Control	6.23 ± 0.18	7.52 ± 0.32	82.8
II/2 Cooled	6.93 ± 0.23	7.32 ± 0.29	94.6

I/1 = Exp. No. 1, Control cortex, mean value of densitometric measurement of 150 synapses
I/2 = Exp. No. 1, Cooled (13 °C, 5′). 200 synapses
II/1 = Exp. No. 2, Control cortex, 97 synapses
II/2 = Exp. No. 2, Cooled (14 °C, 10′) 133 synapses
Cooling caused a significant density increase in the axon terminals

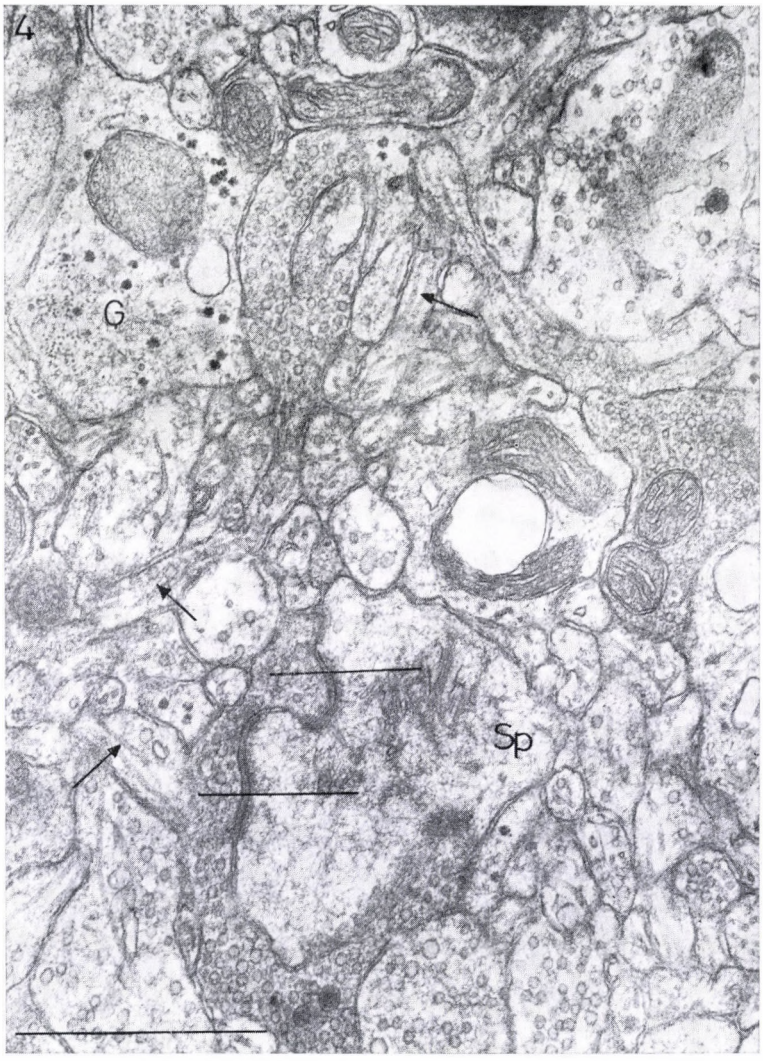

Fig. 4. Higher magnification of cooled (10 °C) cortex, lamina I. *Sp* = dendritic spine surrounded by an axon terminal which appears to be somewhat denser than those in the control (Fig. 3), due probably to finely dispersed osmiophilic intervesicular material. Black line across the synapses corresponds to densitometric measurement lines. Arrow points to proliferating microtubuli in the preterminal axons

icant increase in the density of axon terminals (Table 1). This increase in axon density was probably due to the accumulation of fine dispersed osmiophilic material between the synaptic vesicles (Fig. 4). In extreme cases, as e.g. with the mossy terminals in the cerebellar glomeruli, the accumulation of the osmiophilic material after cooling gave a dense appearance to the whole axon terminal (Fig. 5).

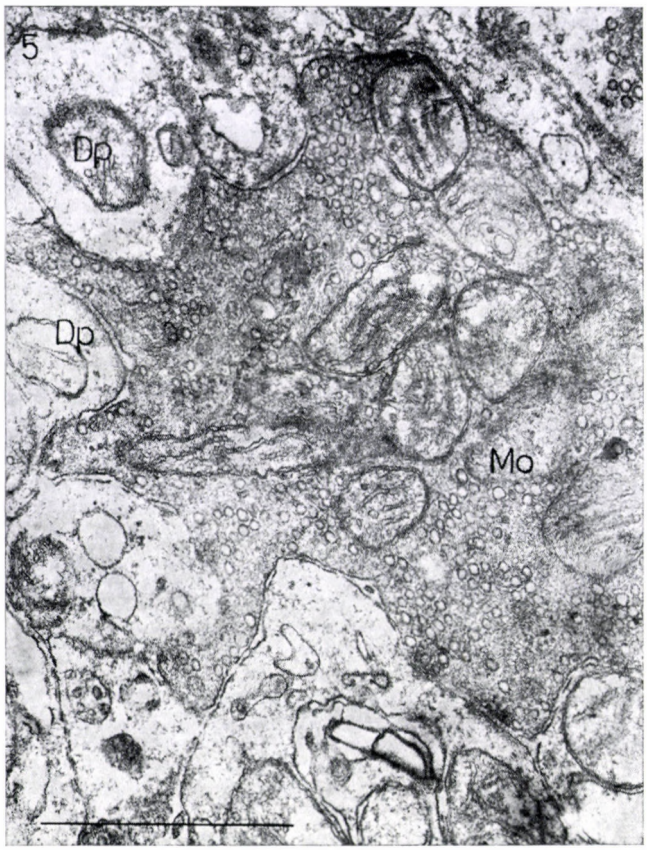

Fig. 5. Part of cerebellar glomerulus from cooled (12 °C) cerebellar cortex, showing fine granular osmiophilic intervesicular material, and providing a dense appearance of the whole mossy terminal *(Mo)*. *Dp* = dendritic processes of the granular cells

Both structural changes caused by cooling, i.e. the microtubular hypertrophy and the density increase of the axon terminal disappeared and normal conditions were fully restored on rewarming of the cortex to 37 °C.

Discussion

Local cooling of the cortex to 8—10 °C caused (a) an apparent increase in the number of microtubuli in the preterminal axons and (b) an increase in density of the presynaptic axon terminals. No other structural changes could be detected in the cortex even by the electron microscope, which explains the failure of light microscopic studies to find morphological alterations of cortical structures by cooling.

Ad (a). It is known from the investigations of TILNAY and PORTER [9] that the microtubuli in the axopodium of Heliosoa are depolymerised and consequently broken to short pieces by cooling the animal to 4 °C. Similar phenomena might explain the apparent numerical increase of microtubuli in the cerebral cortex, although on the basis of our pictures, owing to a lack of serial sections, the assumption could not be substantiated. The original hypothesis of SCHMITT [7] on the role of microbutuli in the fast particle (vesicle) transport in the axon has recently gained a convincing EM support by SMITH et al. [8]. The supposition is therefore at hand that the abolition of synaptic transmission might be due at least partly to a breakdown in the fast transport of vesicles in consequence of a structural disturbance of the microtubular system.

Ad (b). The increase in density of the intervesicular matrix of the synaptic axon terminals is obscure and calls for further electron histochemical investigation.

The minute structural alterations induced by cooling turned out to be completely reversible. This is reassuring from the point of view of local cooling of the cortex, used as a treatment in certain forms of epileptic states not influenced by drugs.

REFERENCES

1. COSTAL, M., OWENS, G., WOLDRING, S.: (1963) Experimental Production of Cerebral Hypothermia by Ventricular Perfusion Techniques. J. Neurosurg. **20,** 112—117. — 2. DONDEY, M., ALBE-FESSARD, D., LE BEAU, J.: (1962) Premières applications neurophysiologiques d'une méthode permettant le blocage électif et réversible de structures centrales par réfrigération localisée. Electroencéph. clin. Neurophysiol. **14,** 758—763. — 3. MIYAZAKI, Y., ERVIN, F. R., SIEGFRIED, J., RICHARDSON, E. P., MARK, V. H.: (1963) Localized Cooling in the Central Nervous System. Arch. Neurol. **9,** 80—87. — 4. PÁSZTOR, E., KUKORELLI, T.: (1967) Effect on Cortical Evoked Potentials of Local Cooling of the Cerebral Surface. Acta physiol. Acad. Sci. hung. **31,** 41—50. — 5. PÁSZTOR, E., TOMKA, I.: (1970) Changes of Electrocorticographic Activity in Response to Direct Brain Surface Cooling in Epileptic Patients. Acta physiol. Acad. Sci. hung. **36,** 277—292. — 6. PÁSZTOR, E., TOMKA, I., DEÁK, GY.: (1965) The Effect of Local Cerebral Hypothermia on the Electrocorticogram and on Experimental Epileptic Activity. J. Neurosurg. **23,** 49—53. — 7. SCHMITT, F. O.: (1968) Neuronal Fibrous Proteins. N. R. P. Bull. Vol. VI/2, 119—124. — 8. SMITH, D. F., JÄRLFORS, O., BERÁNEK, R.: (1970) The Organisation of Synaptic Axoplasm in the Lamprey (Petromyzon marinus) Central Nervous System. J. Cell Biol. **46,** 199—219. — 9. TILNAY, L. G., PORTER, K. R.: (1967) Studies on the Microtubules in Heliozoa: II. The Effect of Low Temperature on these Structures in the Formation and Maintenance of Axopodia. J. Cell Biol. **34,** 327—343.

E. PÁSZTOR, J. HÁMORI:

DIE WIRKUNG DER LOKALEN ABKÜHLUNG AUF DIE FEINSTRUKTUR DER GROSSHIRN- UND KLEINHIRNRINDE

Eine lokale Abkühlung der Großhirn- und Kleinhirnrinde bis zu einer Temperatur von 8—10° C führt zu einer scheinbaren Vermehrung der Zahl der Mikrotubuli in den praeterminalen Axonen und zu einer selektiven Verstärkung der Densität der synaptischen Endungen. Die Veränderungen sind vollständig reversibel und die normalen Verhältnisse werden bei der Erwärmung der Rinde auf 37° C wiederhergestellt. Es wurde der Versuch unternommen einen Zusammenhang zwischen diesen morphologischen Veränderungen und der gleichzeitigen Entwicklung einer elektrischen Ruhe in der gekühlten Rinde festzustellen.

Э. ПАСТОР, Й. ХАМОРИ:

ДЕЙСТВИЕ МЕСТНОГО ОХЛАЖДЕНИЯ НА ТОНКУЮ СТРУКТУРУ КОРЫ ГОЛОВНОГО МОЗГА И МОЗЖЕЧКА

Местное охлаждение коры головного мозга и мозжечка до температуры в 8—10° С приводит к кажущомуся увеличению числа микроканальцев в претерминальных аксонах и вызывает избирательное увеличение густоты синаптических окончаний. Изменения полностью обратимные и нормальные условия восстанавливаются цри нагревании коры до 37° С. Была произведена попытка установить взаимосвязь этих морфологических изменений с одновременным развитием электрической тишины в охлажденной коре.

Dr. Emil PÁSZTOR: Országos Idegsebészeti Tud. Int.,
Budapest XIV., Amerikai út 57, Hungary
Dr. József HÁMORI: Anatómiai Intézet,
Budapest IX., Tűzoltó u. 58, Hungary

Acta Morphologica Acad. Sci. Hung. 19 (1), pp. 89—101, 1971

Klinik und Poliklinik für Psychiatrie und Neurologie der Martin-Luther-Universität
(Direktor: Prof. Dr. med. habil. H. RENNERT), Halle

EIN HISTOCHEMISCHER BEITRAG ZUM GLYKOGENGEHALT IM HIRN VON CHRONISCH LEBERKRANKEN

VERGLEICHSUNTERSUCHUNGEN MIT EINEM UNAUSGEWÄHLTEN OBDUKTIONSMATERIAL

R. LAHL

(Eingekommen am 2. Juni 1970)

Neben Allgemeinbetrachtungen über den Glykogengehalt des Gehirns unter normalen und pathologischen Bedingungen wird über das Vorkommen von Polysacchariden bei Lebererkrankungen berichtet. 25 Hirne von Verstorbenen mit Leberzirrhose bzw. -fibrose wurden hinsichtlich ihres histochemischen Glykogengehaltes mit 25 Kontrollhirnen aus dem laufenden Obduktionsgut des Pathologischen Instituts der Martin-Luther-Universität Halle verglichen. An histochemischen Methoden verwendeten wir die Best'sche Karmin-, PAS- und BTS- (SHIMIZU u. KUMAMOTO) Methode sowie die Diastase bzw. Salivaprobe. Während sich PAS-positive Substanzen in den meisten Fällen besonders in Ganglienzellen, der Leptomeninx, in der Gefäßwand und perivasal, im Neuropil und perizellulär nachweisen ließen, konnten nur in den Hirnschnitten der Leberzirrhotiker z. T. Polysaccharid- bzw. Glykogengranula verifiziert werden. In 8 Fällen waren diese Granula in proliferierten, nackten Makrogliakernen, in 12 perinukleär (um Gliakerne), in 7 adventitiell bzw. perivasal und in 8 im Neuropil nachweisbar. Die Befunde erwiesen sich als signifikant. Eine Relation zwischen Leber- und Hirnglykogen hingegen bestand nicht. Für das Auftreten der Polysaccharidgranula dürfte neben zum großen Teil ungeklärten metabolischen Störungen eine Beeinträchtigung der Glukoseverwertung verantwortlich zu machen sein. Möglichkeiten des intrazerebralen Nährstofftransportes werden diskutiert. Die Diskrepanz zwischen histochemisch nachweisbarem Glykogen und der Aktivität glykogensynthetisierender Enzyme bereits unter Normalbedingungen deutet auf zusätzliche bisher unbekannte Faktoren der zentralen Polysaccharidregulation hin.

Einleitung

Im Säugehirn kann unter Normalbedingungen histochemisch Glykogen nur spärlich nachgewiesen werden (ADAMS, 1965; FRIEDE, 1956). Diese Befunde weisen auf eine nur geringe Glykogenreserve des Gehirns hin. In neueren, vorwiegend biochemischen Untersuchungen (GOTTSTEIN u. HELD, 1968) konnte Glykogen auch quantitativ erfaßt werden. Nach Messungen von VILLAR-PALASI u. LARNER (1960) ist der Glykogengehalt im Hirngewebe von Ratten mit 1,96 mg/g Feuchtgewebe sogar höher als im Herzmuskel. Entgegen früheren Meinungen, die Hirnzellen seien ausschließlich auf Glukose als Energiequelle angewiesen, ist die Verwertung vor allem von Aminosäuren und Lipoproteiden als Nährstoffe in Notsituationen und unter extremen Bedingungen

des Hirnstoffwechsels durch exakte Untersuchungen hinreichend gesichert (KNAUFF u. Mitarb., 1964; GOTTSTEIN u. HELD, 1968; HÖPKER, 1968). Unter besonderen und pathologischen Zuständen sowie Einflüssen enthält das ZNS histochemisch und elektronenoptisch vermehrt Glykogen. So teilte OKSCHE eine eindrucksvolle Glykogenbildung in Gliazellen bei Winterstarre, im Winterschlaf, nach einem mehrtägigen experimentell erzeugten pharmakologischen Schlafzustand mit Megaphen sowie in den Astrozyten an Tumorrandgebieten mit. Auch TIRASPOLSKAYA u. TOROPOVA wiesen Glykogen in Hirntumoren nach. SHIMIZU u. KUBO (1957) konnten tierexperimentell am Meerschweinchen durch Elektroschocks eine Glykogenerhöhung erzielen. SHIMIZU u. HAMURO (1958) berichten über eine konzentrische Glykogenablagerung in der Umgebung frischer Hirnwunden bei Ratten. Nach FRIEDE (1962) lassen sich gewisse Beziehungen zwischen histochemischen Glykogenbefunden und Hirnwellenfrequenz im EEG von menschlichem Biopsiematerial nachweisen; eine EEG-Frequenzverlangsamung soll mit Glykogenanreicherung, eine Frequenzbeschleunigung mit Glykogenschwund einhergehen. ARSENI u. Mitarb. (1967) fanden in blastomatösen Astrozyten sowie im bindegewebigen Stroma Glykoproteide und Mukopolysaccharide. Bei experimentellen Aufbrauchsituationen im Hirn kommt es nach MEIER-RUGE (1968) durch eine Störung in der Überträgerfunktion der Astrozyten für Stoffwechselmetaboliten zu einer Steigerung des Eigenstoffwechsels und zu einer Akkumulation von Glykogen. Elektronenoptisch wurde der Nachweis einer vermehrten Glykogenablagerung im ZNS unter anderem in den reaktiven Astrozyten der Hirnschwellungszone von Glioblastomen (KAZUMI u. Mitarb., 1967), in chronischen Ödemen (OKSCHE, 1961; DAVID u. Mitarb., 1967), nach Strahleneinwirkung und Thorotrastinjektionen (FISCHER u. BLINZINGER, 1968; LAMPERT u. Mitarb., 1966; SELLE u. Mitarb., 1968), in den Astrozyten bei Hirninfarkten unterschiedlichen Alters sowie im Kleinhirn von Kaninchen mit hereditärer Ataxie (O'LEARY u. Mitarb.) mitgeteilt.

Bei den Folgezuständen schwerer Lebererkrankungen, insonderheit bei dem Coma hepaticum, liegt neben den Störungen des Eiweiß- und Elektrolytstoffwechsels auch eine erhebliche Beeinträchtigung des Kohlenhydratstoffwechsels vor; diese führt zu einem reduzierten zellulären oxydativen Metabolismus im Gehirn. Da selbst bei schweren Hepatopathien eine Hypoglykämie äußerst selten (ERBSLÖH u. Mitarb., 1958; ZIEVE, 1966 u. a.), bzw. gar nicht auftritt (BENHAMOU u. Mitarb 1960), muß angenommen werden, daß die dem Hirn an sich in normaler Menge angebotene Glukose nicht verwertet werden kann. Für die gestörte Glykolyse und Schädigung im Trikarbonsäurezyklus dürften auch der erhöhte Brenztraubensäurespiegel im Blut (FAZEKAS u. Mitarb., 1967) sowie das vermehrte Vorkommen ihrer Metaboliten wie Acetoin und 2,3-Butylen-Glykol (MÜTING u. Mitarb., 1966; GIOANNINI u. Mitarb. u. a., 1969) sprechen. Ob das intra-und perinukleäre Auftreten von Glykogengranula

bzw. Polysacchariden (GAUPP JR., 1939; INOSE, 1961; INOSE u. Mitarb., 1960; MOSSAKOWSKI, 1966; KITANI u. Mitarb., 1962; LAHL, 1967) im Hirn von an schweren Lebererkrankungen Verstorbenen als Ersatz- bzw. Hilfsmechanismus oder Reaktion eines gestörten Glukoseabbaus zu deuten ist, kann bis jetzt nur vermutet werden. Die Beurteilung von Untersuchungsbefunden, die an glykogensynthetisierenden Enzymen im Hirn erhoben wurden, ist äußerst schwierig (FRIEDE, 1962). Histochemische Mitteilungen über das Enzymverhalten des Hirns bei Lebererkrankungen sind weder beim Tier noch beim Menschen bisher bekannt. In unseren Ausführungen soll zu folgenden Problemen Stellung genommen werden:

1. Häufigkeit und Lokalisation von Glykogen- bzw. Polysaccharidablagerungen im Hirn von chronisch Leberkranken, sowie ein Vergleich mit einem unausgewählten Kontrollmaterial.

2. Deutung der Topik der Glykogenablagerungen.

3. Relation zwischen nachgewiesenem Glykogen im eigenen Untersuchungsmaterial und der aus der Literatur bekannten Aktivität glykogensynthetisierender Enzyme im Gehirn.

Eigene Untersuchungen*

Material und Methode

Untersuchungsmaterial. Aus dem laufenden Sektionsgut der dem Institut für Pathologie der Medizinischen Akademie Magdeburg angeschlossenen Prosektur des Bezirkskrankenhauses Magdeburg-Altstadt sowie des Pathologischen Institutes der Martin-Luther-Universität Halle wurden 25 Hirne von Verstorbenen mit Leberzirrhose histologisch und histochemisch auf ihren Glykogengehalt untersucht; es handelt sich um 12 Männer und 13 Frauen. Das Alter der Verstorbenen lag zwischen 50 bis 79 Jahren.

Kontrollmaterial. Dazu dienten 25 Hirne aus dem laufenden Sektionsgut des Pathologischen Institutes der Martin-Luther-Universität Halle; es handelt sich um 12 männliche und 13 weibliche Hirne, das Alter der Verstorbenen lag zwischen 1 Jahr und 86 Jahren.

Methode. In jedem Falle wurden Leber, Frontalkortex, Neostriatum und Pallidum untersucht. Fixierung des Materials (1 Stunde bis 2 Tage post mortem) in einem 4% Neutralformol, zur histochemischen Verarbeitung Äthanol-Formol bzw. Äthanol-Formol-Eisessiggemisch.

Färbung. Zum Nachweis vor allem der proliferierten, hellen Makrogliakerne HE, van Gieson, Nissl, Trichromfärbung nach Goldner, Azanfärbung, Kresylviolett.

Histochemische Methoden. Best'sches Karmin, PAS, PAS mit Hämatoxylin bzw. Lichtgrün als Kerngegenfärbung, BTS (nach Shimizu u. Kumamoto), Diastase bzw. Speichelprobe, Jodprobe (histochemische Methodik siehe KISZELY u. PÓSALAKY, 1964). Schnittgröße cca 3×4 cm, Schichtdicke 8 bis 12/μ. Von jedem Schnitt wurden zur Beurteilung der quantitativen Veränderungen 50 Gesichtsfelder bei einer 200-fachen Vergrößerung untersucht.

Statistische Auswertung erfolgte nach dem Prinzip des Vergleiches zweier Häufigkeiten mit der Formel.

* Für die Überlassung des Sektionsmaterials und der Obduktionsbefunde sei den Herren Prof. Dr. med. habil. D. ESSBACH (Direktor des Institutes für Pathologie der Medizinischen Akademie Magdeburg) und Prof. Dr. med. habil. C. COUTELLE (Direktor des Pathologischen Institutes der Martin-Luther-Universität Halle) herzlichst gedankt.

Untersuchungsergebnisse

Hirnbefunde bei Leberzirrhose bzw. -fibrose

Bei der histologischen Untersuchung zeigten sich neben Altersveränderungen vor allem die Folgen der Kreislaufschädigung durch Hypoxydose und Anämie sowie der Intoxikation einschließlich Ikterus und Coma hepaticum. Es fanden sich ausgedehnte Ganglienzelldegenerationen und Zytolysen, gefäßabhängiger und unabhängiger Status spongiosus, kleine Erweichungen. In 21



Abb. 1. Schematische Darstellung der Glykogeneinschlußkörperchen in proliferierten Astrogliakernen im Hirn von Leberzirrhotikern

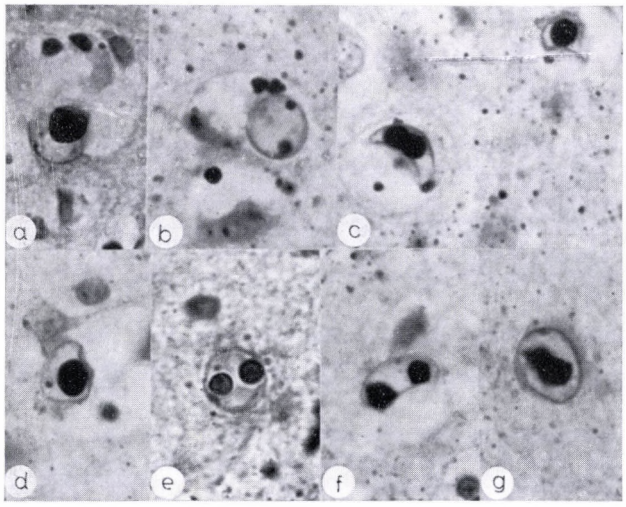

Abb. 2a—g. Glykogeneinschlußkörperchen in proliferierten »nackten« Astrogliakernen im Frontalkortex, Neostriatum und Pallidum von Leberzirrhotikern. Methode: PAS, BEST'sches Karmin (positive Diastaseprobe). Vergr.: ca. 700-fach

Fällen konnten proliferierte atypische astrozytäre Makrogliakerne nachgewiesen werden, davon in 5 Fällen vom Stadium I, in 9 vom Stadium II, in 7 vom Stadium III (Einteilung siehe LAHL, 1967). Bei den histochemischen Untersuchungen stellte sich Glykogen 8mal deutlich und 4mal spärlich in den hellen, nackten Makrogliakernen dar (Abb. 1. und 2.), dabei maximal felderförmig

in einem Drittel bis zur Hälfte der Kerne. In den äußeren Rindenschichten und in den Windungstälern konnte die Einlagerung gehäuft angetroffen werden. Kerngröße und Glykogeneinschlüsse standen nicht in unmittelbaren Zusammenhang. In einem Teil der polysaccharidhaltigen Kerne ließ sich eine deutliche Auflockerung der Kernmembran erkennen. Perinukleär (um die nackten Gliakerne) waren 12mal karmin- und PAS positive Granula (Abb. 3.), adventitiell bzw. perivasal 7mal und im Neuropil 8mal Glykogen- (Abb. 4),

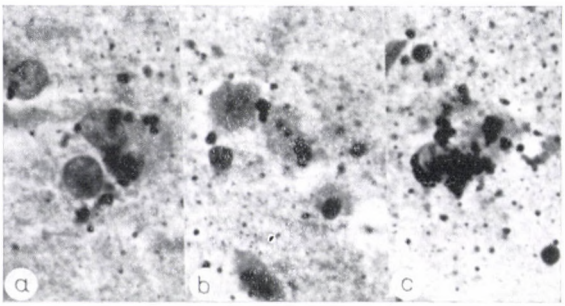

Abb. 3a—c. PAS und karminpositive Granula perinukleär und im Neuropil von Frontalkortex Neostriatum und Pallidum chronisch Leberkranker. Verg.: ca. 700-fach

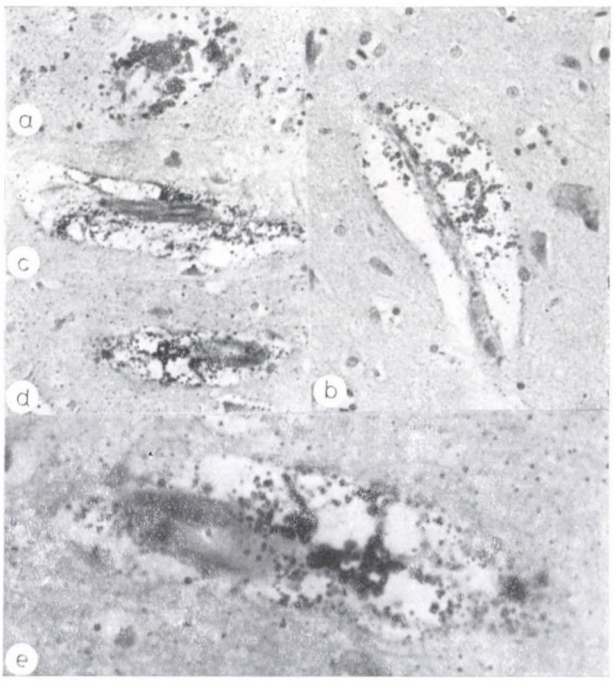

Abb. 4a—e. Adventitielle und perivasale schollige Polysaccharidablagerungen im Kortex und Neostriatum von Leberzirrhotikern. Methode: PAS, BTS (Shimizu u. Kumamoto), Best'sche Karmin (positive Diastaseprobe). Verg.: *a—d* ca. 300-fach, *e* ca. 700-fach

bzw. Polysaccharidgranula nachweisbar. Glykogen konnte histochemisch in der weißen Substanz und in Ganglienzellen nicht beobachtet werden. In fast allen Fällen stellten sich besondern perinukleär (um die nackten Gliakerne) sowie perizellulär und im Neuropil PAS positive Granula dar, die jedoch keine Diastase bzw. Salivaprobe ergaben. PAS-positive Substanzen wurden auch in Ganglienzellen, der Gefäßwand, intravasal und in der Leptomeninx angetroffen.

Leberbefunde des Untersuchungsmaterials

Bei der makroskopischen und histologischen Untersuchung der Lebern handelte es sich in 16 Fällen um eine Zirrhose vom postnekrotischen und in 7 vom portalen Typ. In 2 Fällen lag eine Thorotrastfibrose der Leber bei gleichzeitig bestehendem Gallenblasen- bzw. Gallengangskarzinom mit Tumorstenose der Gallengänge und daraus resultierendem Coma hepaticum vor. Bei einem Fall von postnekrotischer Zirrhose bestand ein multilokuläres hepatozelluläres

Tabelle 1

Nachweis und Häufigkeit von karmin- u. PAS-positiven Substanzen (Polysaccharide, pos. Diastaseprobe) im Kortex, Neostriatum und Pallidum von 25 chron. Leberkranken

Zirrhoseform	Anzahl der untersuchten Fälle	Aktivität u. Progredienz d. Zirrhose bzw. Fibrose	Zeichen der portalen Hypertension[1]	Zeichen der Leberinsuffizienz[2]	Lebererkrankung u. Folgen als Todesursache	Leberglia	Polysaccharidnachweis			
							Intranukleär (Gliakerne)	Perinukleär (um Gliakerne)	Adventiell u. perivasal	Neuropil
Postnekrotisch	16	15	14	14	14	14	7	10	5	7
Portal	7	5	7	2	4	5	1	1	1	--
Thorotrastfibrose	2	2	1	2	2	2	—	1	1	1
Insgesamt	25	22	22	18	20	21	8	12	7	8

[1] Vor allem Milzvergrößerung und Ösophagusvarizen
[2] Vor allem Ikterus, Aszites, Präkoma o. Koma

Karzinom. In 22 Fällen war die Zirrhose bzw. Fibrose aktiv, 22mal ließen sich die Zeichen der portalen Hypertension, 18mal die Zeichen der Leberinsuffizienz nachweisen. In 20 Fällen war die Lebererkrankung und deren Folgezustände das zum Tode führende Leiden. Bei der Untersuchung konnte eine Relation zwischen Glykogengehalt der Leber und des Hirnes sowie zwischen dem der Lochkerne in beiden Organen nicht nachgewiesen werden.

Hirnbefunde der Kontrollfälle

Histologisch fanden wir vor allem Alters- und Kreislaufveränderungen wie Ganglienzelldegenerationen bis zur Zytolyse, außerdem Pigment- und Kalkablagerungen, Drüsen, Gefäßsklerose und -hyalinose mit Status spongiosus, Malazien und Mikrohämorrhagien. In zwei Fällen lag eine zerebrale Metastasierung bei Bronchial- bzw. Mammakarzinom, in einem Fall eine vasale und perivasale lymphozelluläre Infiltration bei chronischer Lymphadenose vor. Vergrößerte, nackte, helle Makrogliakerne konnten in keinem der Kontroll-

Tabelle 2

Nachweis und Häufigkeit von PAS-positiven Substanzen (neg. Diastaseprobe) im Kortex, Neostriatum und Pallidum von 25 Kontrollfällen aus einem unausgewählten Obduktionsmaterial

Art der Erkrankung	Anzahl der untersuchten Fälle	intranukleär (von Gliazellen)	PAS-positive Substanzen					
			perizellulär (von Gliazellen)		adventitiell und perivasal		Neuropil	
			gering (+)	deutlich +	gering (+)	deutlich +	gering (+)	deutlich +
Herz- und Kreislaufprozesse	9	—	2	7	5	—	4	—
Karzinom und Folgezustände	6	—	—	4	4	—	3	—
Entzündung und Folgezustände	6	—	1	4	2	—	4	—
Chron. Lymphadenose	1	—	—	1	1	—	1	—
Steinleiden mit Folgezustand	1	—	—	1	1	—	1	—
Mißbildung	1	—	—	—	—	—	—	—
Pankreasnekrose	1	—	—	1	—	—	1	—
Insgesamt	25	—	3	18	13	—	14	—

fälle nachgewiesen werden. Glykogen wurde mit den oben angeführten histochemischen Methoden nicht dargestellt. PAS-positive Substanzen in Form kleiner Granula fanden sich in 18 Fällen perizellulär (um Gliazellen), spärlich adventitiell und perivasal (13 Fälle) sowie im Neuropil (14 Fälle). Geringe Ablagerungen bzw. Einlagerungen histochemisch PHS-positiv reagierender Substanzen beobachten wir in Ganglionzellen, gelegentlich in Gliazellen, intravasal, in der Leptomeninx und in Drüsen.

Leberbefunde des Kontrollmaterials

Die histologische Untersuchung der Leberschnitte ergab Zellverfettung, Zellatrophie mit Lipofuszinose, Aktivierung der Sinusendothelien und Blutstauung; in 2 Fällen bestanden Lebermetastasen, davon in einem mit schwerem Leberparenchymikterus, je 1 × war ein Leberzelladenom, eine chronische Lymphadenose und entzündliche Portalfeldinfiltration bei Septikopyämie nachweisbar.

Diskussion

An den Anfang der Besprechung und Deutung unserer Befunde stellen wir einige allgemeine Betrachtungen über die glykogensynthetisierenden Enzyme des Gehirns:

Biochemische Untersuchungsergebnisse stimmen hinsichtlich des Glykogennachweises mit den histochemischen, auch unter Normalbedingungen, nur teilweise überein.

Die Glykogensynthese findet sowohl in der weißen als auch grauen Substanz statt. Die Enzymbestimmungen orientieren sich vor allem auf den Nachweis der Phosphorylaseaktivität (PhA). In der weißen Substanz ist die Glykogensynthese diffus und in Axonen mit dicken Faserzügen herdförmig vorhanden. Sotelo u. Wegmann berichten über eine bemerkenswerte Aktivität in den Fußplatten von Astrozyten. Die Angaben über den Phosphorylasegehalt der grauen Substanz sind unterschiedlich. Dabei kann histochemisch jeweils nur die aktive Form nachgewiesen werden. Eine Zunahme der PhA tritt vor allem bei mechanischer Alteration des Gewebes auf. Untersuchungen über Bestimmungen anderer glykogensynthetisierender Enzyme im Hirn, so der Glykogensynthetase und Branching-Enzyme sind selten. Entgegen der Annahmen der Biochemiker zeigt die Phosphorylase in histochemischen Gewebsschnitten mit geringer behandlungsbedingt-mechanischer Schädigung eine strenge zytologische Lokalisation. Eine Aktivierung und Inaktivierung des Enzyms scheint in Nervenzellen Ausmaß der Glykogenablagerung nur teilweise überein. Oftmals konnte eine bemerkenswerte Phosphorylaseaktivität an Stellen mit nur wenig Glykogen nachgewiesen werden, so z. B. in der weißen Substanz des Großhirns, in der Granularschicht des Kleinhirns und im perivaskulären Hirngewebe. Diese Tatsache deutet darauf hin, daß noch andere, bisher nicht bekannte Faktoren das Ausmaß der Glykogenablagerung im Hirngewebe bestimmen müssen (Friede, 1966).

Eine ätiologische Klärung der im Hirn von Verstorbenen mit Lebererkrankungen nachweisbaren Glykogen-Ein und -Ablagerungen liegt bisher nicht vor. Entweder wird die Ursache überhaupt offengelassen (Gaupp jr., 1939; Inose, 1961; Inose u. Mitarb., 1960; Mossakowski, 1966; Kitani u.

Mitarb., 1962) oder eine Glukoseverwertungsstörung (LAHL) diskutiert. Da eine Übereinstimmung zwischen der bisher bekannten Topik und Aktivität glykogensynthetisierender Enzyme und der nachgewiesenen Polysaccharideinbzw. -ablagerungen nicht vorliegt, muß sowohl die Möglichkeit eines Stofftransportes als auch die Existenz bisher unbekannter Faktoren einer Glykogensynthese (FRIEDE, 1966) in Betracht gezogen werden. Eine ursächliche Klärung wird auch dadurch erschwert, daß grundlegende pathoneurophysiologische und biochemische Probleme bei Lebererkrankungen und deren schwerster Folge, dem Coma hepaticum, ungeklärt sind. Insonderheit müßte überprüft werden, ob unter Extrembedingungen, z.B. im Präkoma oder Coma hepaticum mit Hirnödem ein Transport auch so großer Moleküle wie das Glykogen, z.B. in Gefäßnähe möglich ist. Bei nicht hepatogenen Erkrankungen sind im Hirn intranukleäre Glykogengranula in Gliakernen u. E. bisher nicht bekannt. Eine intranukleäre Glykogensynthese in den fast ausschließlich degenerierten Kernen mit Kernödem, weitgehendem Schwund der Kernbestandteile sowie schwer gestörter Kern-Plasmarelation ist unwahrscheinlich. Die Einschleusung kleiner Glykogengranula durch eine geschädigte Kernmembran könnte vermutet werden. Ein großer Teil, auch der nicht glykogenhaltigen Astrogliakerne, wird von Polysaccharidgranula meist halbmondförmig und exzentrisch umgeben. Bei den vorliegenden Untersuchungen war ein positiver Kernbefund stets mit einer perinukleären Ablagerung vergesellschaftet. Perinukleäre Glykogengranula hingegen mit »leerem« Kern wurden häufig beobachtet. Dabei dürfte die Glykogeneinlagerung erst nach der Kernvakuolisation bzw. -hydratisation erfolgt sein. Ob die nukleären Granula allerdings aus dem bei funktioneller Überbeanspruchung möglicherweise glykogenhaltigen Zytoplasma des untergehenden bzw. untergegangenen Zelleibes stammen oder aber extrazellulär durch die Membran des bereits nackten Kernes transportiert wurden, muß offenbleiben. Glykogengranula im Zytoplasma von intakten oder teilgeschädigten Astrogliazellen konnten von uns nicht beobachtet werden. Wir glauben, daß es sich bei den Einlagerungen in den Astrogliakernen entsprechend den von SELLYEI u. WALTON (1969) in der Leber erhobenen Befunden um echtes oder Infiltrationsglykogen handelt. Ein fördernder Einfluß auf die Entstehung des Kernglykogens als Folge des gestörten Zellstoffwechsels und Ionengleichgewichtes zwischen Zytoplasma und Kern durch eine Hyperglykämie, wie das für die Leber von ZIMMERMANN u. Mitarb. anhand der überprüften klinischen Befunde nicht bestätigt werden. Die Klärung einer verstärkten Glykogensynthese infolge eines Glukosestau durch enzymatische Fehlleistungen muß biochemischen Untersuchungen vorbehalten bleiben. Eine verstärkte Glykogenaktivierung unter toxischen Einflüssen ist möglich; wir denken hierbei besonders an die Bildung von Lyoglykogen auf Kosten des Desmoglykogens. Die teilweise erhebliche Ablagerung von schollig-granulärem Glykogen in der Adventitia und perivasal stimmt mit der in der Literatur

angegebenen Phosphorylaseaktivität teilweise überein. Es muß jedoch auch hier in Erwägung gezogen werden, ob es sich bei dieser Lokalisation nicht um die Zwischenstufe eines Transportmechanismus (ähnlich dem bei der freien perivasalen Fettansammlung) handelt; eine zelluläre Fixierung konnte dabei für das Glykogen nicht beobachtet werden. Der Transport von Polysacchariden aus dem Blut und seine perivasale Ablagerung im Gehirn bei gestörter Bluthirnschranke ist bisher nicht bekannt; diese Möglichkeit muß als unwahrscheinlich angesehen werden. Bei den zellulären Granula (um Gliakerne und -zellen) handelt es sich nur um einen Lipoproteide (ihr histochemisches Verhalten siehe WOLMAN, 1961, zit. nach ADAMS, 1965). Diese vielfach auch als Pigmentgranula beschriebenen Substanzen sind teilweise Stoffwechselprodukte und Reste untergegangener gliöser Zellstrukturen. Der bei schwer Leberkranken gestörte Zellstoffwechsel der Ganglienzellen für Glukose könnte eine Glukoseanhäufung in den entsprechenden Neuronen und eine verstärkte Glykogensynthese zur Folge haben. SHIMIZU u. HAMURO (1958) vermuten, daß die Anhäufung von Glykogen als Reaktion auf anaerobe Stoffwechselbedingungen zurückzuführen ist. Sie weisen auf die herabgesetzte Aktivität der Succinodehydrogenase und die erhöhte Aktivität der glykogensynthetisierenden Phosphorylase an den Rändern von Hirnläsionen hin.

Auch durch neuere Untersuchungen ist die Regulation der Glukoseversorgung der Ganglienzellen noch nicht hinreichend geklärt, wenngleich die Mehrzahl der Autoren eine primär gliös gesteuerte (also zelluläre) für wahrscheinlich hält. Ein erhöhtes Glukoseangebot des Hirnes, wie wir es ja auch beim Diabetiker finden, reicht für die vermehrte Glykogenbildung allein nicht aus PALAY (zit. nach OKSCHE, 1961) hält einen extrazellulären Glukosestrom in den 200—300 Å weiten Spalträumen für unwahrscheinlich und eine intrazelluläre Regulation für wahrscheinlicher. BRAMBRING (1965) mißt den im Großhirnmark zwischen den Markfasern elektronenoptisch nachgewiesenen leeren Feldern eine Bedeutung für den Stoffaustausch bei. Nach MEIER-RUGE (1968) führt eine experimentelle Aufbrauchsituation im Hirn zu einer Stoffwechselhemmung in den Ganglienzellen mit einer kompensatorischen Aktivierung der versorgenden Astroglia; dabei wird durch eine Störung in der Überträgerfunktion des Astrozyten für Stoffwechselmetaboliten sein Eigenstoffwechsel aktiviert; es kommt zur Glykogenakkumulation und vermehrten Hydratisation. Ein ähnlicher Zusammenhang wird auch zwischen Astroglia und Kapillaren vermutet. CASTAN (1968) fand eine besondere Zwischenstellung der Astrozyten bei toxischen und metabolischen Hirnschädigungen; sie stehen sowohl mit den Kapillaren als auch Nervenzellen in Verbindung. Ihre Reaktion wird für primär gehalten, der Verlust von Nervenzellen hingegen auf eine sekundäre Reaktion und Dysfunktion der Astroglia zurückgeführt. Auch TSCHIRGI, 1958; OKSCHE, 1961 u. a. messen der Glia eine primäre Bedeutung bei der Glukoseversorgung der Ganglienzellen bei. GEIGER u. Mitarb. (1954)

hingegen glauben, daß die Glukoseaufnahme durch das Hirn von verschiedenen hämatogenen Aktivatoren, die im strömenden Blut unter Normalbedingungen vorkommen, reguliert wird und somit ein aktiver Prozeß ist. WOLFE u. NICHOLLS (1967) jedoch konnten durch elektronenmikroskopische autoradiographische Untersuchungen nachweisen, daß ein von Gliazellen befreites Neuron zur normalen Glukoseaufnahme fähig war. Daraus wurde gefolgert, daß zumindest ein Teil der im Hirn zu transportierenden Substanzen ohne Mitwirkung der Gliazellen direkt aus den intrazellulären Räumen von den Neuronen aufgenommen werden könnte. So ließ sich auch von HELD u. Mitarb. (1968) durch Glukose-Insulininfusionen die Glukoseaufnahme des menschlichen Hirns verbessern, jedoch gelang es ihnen tierexperimentell an Ratten nicht, durch Injektionen von Glukose und Insulin den Glykogengehalt des Gehirns zu erhöhen; Blutzuckerwerte von 41—1146 mg % hatten dabei keinen Einfluß. Erst in der tiefen Hypoglykämie wurde eine signifikante Abnahme des Hirnglykogens beobachtet.

Bei der Klärung der in dieser Arbeit absichtlich angeführten vielen ungelösten Probleme dürfte sich eine Komplexforschung von Biochemikern, Histochemikern, Neurophysiologen und Neuropathologen als besonders fruchtbar erweisen.

LITERATUR

1. ADAMS, C. W. M. (edit): (1965) Neurohistochemistry. Elsevier, Amsterdam—London—New York. — 2. ARSENI, C., CARP, N., MESTES, E., ADEL, M.: (1967) Histochemistry of Mucopolysaccharides in Brain Tumors. Acta neuropath. (Berl.) **7,** 275. — 3. BENHAMOU, J.-P., LENNE, C., CLOCHE, R., FAUVERT, R.: (1960) L'encéphalopathie des cirrhoses. Sem. Hôp. Paris **36,** 1707. — 4. BRAMBRING, P.: (1965) Elektronenmikroskopische Untersuchungen über die Weite des Extrazellularraumes in Großhirnmark. Acta neuropath. (Berl.) **4,** 317. — 5. CASTAN, P.: (1968) Les fonctions métaboliques de l'astroglia cérébrale, élément fondamental de la barrière hémato-encéphalique. Applications aux encéphalopathies métaboliques, toxiques et gliospongieuses subaiguës. J. neurol. **6,** 53 — 6. DAVID, E., MARX, I., DAVID, H.: (1967) Zur Feinstruktur des experimentell erzeugten subakuten und chronischen Hirnödem. Acta neuropath. **9,** 217. — 7. ERBSLÖH, F., BERNSMEIER, A., HILLESHEIM, H. R.: (1958) Der Glucoseverbrauch des Gehirns und seine Abhängigkeit von der Leber. Arch. Psychiatr. Nervenkr. **196,** 611. — 8. FAZEKAS, J. F., BESSMAN, A. W.: (1953) Coma mechanism. Amer. J. Med. **15,** 804. — 9. FAZEKAS, J. F., TICKTIN, H. E., EHRMANTRAUT, W. R., ALMAN, R. W.: (1956) Cerebral Metabolism in Hepatic Insufficiency. Amer. J. Med. **21,** 843. — 10. FAZEKAS, J. F., TICKTIN, H. E., SHEA, J. G.: (1957) Effect of L-glutamic Acid on Metabolism of Patients with Hepatic Encephalopathy. Amer. J. Med. sci. **234,** 145. — 11. FAZEKAS, J. F., TICKTIN, H. E., EHRMANTRAUT, W. R.: (1957) Effects of L-arginine on Hepatic Encephalopathy. Amer. J. Med. Sci. **234,** 462. — 12. FISCHER, J., BLINZINGER, K.: (1968) Vorkommen von Glykogen in geschwollenen Dendriten bei experimenteller Kobaltnekrose des Rattengehirns. Virchows Arch. **1,** 201. — 13. FRIEDE, R. L.: (1956) Über Beziehungen zwischen histochemischen Glykogenbefunden und der Hirnwellenfrequenz im EEG an einem Material von menschlichen Biopsien. Arch. f. Psychiatr. u. Z. Neur. **194,** 213. — 14. FRIEDE, R. L.: (1962) The Cytochemistry of Normal and Reactive Astrocytes. J. Neuropath. Exp. Neurol. **21,** 471. — 15. FRIEDE, R. L.: (1966) Topographic Brain Chemistry. Academic Press, New York—London. — 16. GAUPP, JR. R.: (1938) Zur Frage hepatoencephaler Krankheitsbilder. Arch. f. Psychiatr. **107,** 422. — 17. GAUPP, JR. R.: (1939) Fortschritte der Histopathologie des ZNS. Fortschr. Neur. **11,** 180. — 18. GEIGER, A., MAGNES, J., TAYLOR, R. M., VERALLI, M.: (1954) Effect of Blood Constituents on Uptake of Glucose and on Metabolic Rate of the Brain in Perfusion Experiments. Amer. J. Physiol. **177,** 138. — 19. GIOANNINI, P., SCALISE, G., PIPPI, L., BOGGIANO, C. A.: (1969)

Osservazioni sul comportamento di alcuni metaboliti dell'acido piruvico nel sangue. Minerva med. **60,** 524. — 20. GOTTSTEIN, U., HELD, K. (1968) Einfluß von Insulin auf den zerebralen Glukosestoffwechsel des Menschen. In Verhandlungen der Deutschen Gesellschaft f. exp. Medizin, Heft 15, Insulin-Kohlenhydratstoffwechsel und nervale Regulation. S. 25. — 21. HELD, K., WALPURGER, G., GOTTSTEIN, U.: (1968) Der cerebrale Glykogengehalt unter dem Einfluß von Glucose- und Insulin-Injektionen. Klin. Wschr. **46,** 15. — 22. HÖPKER, W.: (1968) Glukosestoffwechsel des Gehirns bei Hypoglykämie. In: Verhandlungen der Deutschen Gesellschaft f. exp. Medizin, Heft 15, Insulin-Kohlenhydratstoffwechsel und nervale Regulation, S. 34. — 23. INOSE, T.: (1961) Neuropathologie der hepatocerebralen Erkrankungen nebst einigen histochemischen Bemerkungen. IV. Intern. Kongreß für Neuropathologie 4.—8. Sept. 1961. in München. Vol. 1. Histochemie und Biochemie. Georg Thieme Verlag, Stuttgart. — 24. INOSE, T., ICHIKAWA, Y., NOMURA, H.: (1960) Eine histochemische Studie bei den hepatocerebralen Degenerationen und bei Lebererkrankungen (Glykogenbefund). Arch. Psychiat. Nervenkr. **200,** 509. — 25. KAZUMI et al., zit. nach DAVID H. in »Elektronenmikroskopische Organpathologie«. Volk und Gesundheit, Berlin 1967. S. 317. — 26. KISZELY, G., PÓSALAKY, Z.: (1964) Mikrotechnische und histochemische Untersuchungsmethoden. Akadémiai Kiadó, Budapest. — 27. KITANI, T. et al.: (1962) Autopsy Findings in a Case of a Special Type of Hepatocerebral Disease with Sustained Hyperammoniaemia (Japanese). Psychiatr. Neurol. Jap. **64,** 655. — 28. KNAUFF, H. G., GOTTSTEIN, U., MILLER, B.: (1964) Untersuchungen über den Austausch von freier Aminosäuren und Harnstoff zwischen Blut und Zentralnervensystem. Klin. Wschr. **42,** 27. — 29. LAHL, R.: (1967) Zur Häufigkeit astrozytärer Gliaveränderungen (»Leberglia«) bei hepatogenen Erkrankungen, insbesondere Leberzirrhosen, und ihre Abhängigkeit vom Funktionszustand des Organs. Zbl. allg. Path. **110,** 518. — 30. LAHL, R.: (1969) Ein Beitrag zur neurologischen Symptomatik hepatozerebraler Krankheitsbilder. Firtsch. Neurol. u. Psych. **37,** 77. — 31. LAMPERT, P. W., FOX, J., EARLE, K.: (1966) Electron Microscopic Observations on Cerebral Edema Induced by Laser Radiation. J. Neuropath. exper. Neurol. **25,** 152. — 32. MEIER-RUGE, W.: (1968) Das Verhalten von Ganglienzelle und Astroglia bei experimentell erzeugter Aufbrauchsituation. 52. Tagung der Deutschen Gesellschaft für Pathologie in Verbindung mit der 17. Tagung der Arbeitsgemeinschaft für Veterinärpathologie vom 1.—6. April 1968. in Würzburg. In Zbl. allg. Path. **111,** 570. — 33. MOSSAKOWSKI, H. J.: (1966) Patomorfologia i histochemia spontanicznych i doswiadczalnych encefalopatii pochodzenia watrobowego. Neuropat. pol. **4,** 231. — 34. MÜTING, D., REIKOWSKI, H., ESCHRICH, W., BUHL, H., JUTZLER, G. A.: (1966) Zur Pathogenese und Klinik des Coma hepaticum. Dtsch. med. Wschr. **33,** 1449. — 35. OKSCHE, A.: (1961) Der histochemisch nachweisbare Glykogenaufbau und -Abbau in den Astrozyten und Ependymzellen als Beispiel einer funktionsabhängigen Stoffwechselaktivität der Neuroglia. Ztschr. Zellforsch. **54,** 307. — 36. O'LEARY, J. L., HARRIS, A. B., FOX, R. R., SMITH, J. M.: (1968) Ultrastructural Lesions in Rabbit Hereditary Ataxia. Arch. Neurol. **13,** 238. — 37. PALAY, S. L.: (1958) An Electron Microscopical Study of Neuroglia. S. 24. In W. F. Windle, Biology of Neuroglia. Springfield, Illi. Ch. C. Thomas. — 38. PALAY, S. L.: (1958) Diskussionsbemerkung S. 65. In W. F. Windle, Biology of Neuroglia. Springfield, Illi. Ch. C. Thomas. — 39. SELLE, G., LIERSE, W., FRANKE, H.: (1968) Topochemischer Nachweis von Glykogen und Mukopolysacchariden im Gehirn des Meerschweinchens nach Telekobaltbestrahlung. Strahlentherapie, **136,** 712. — 40. SELLYEI, M., WALTON, E.: (1969) Über Vorkommen und Erscheinungsformen des Kernglykogens in Leberzellen. Zbl. allg. Path. **112,** 1. — 41. SHIMIZU, N., KUMAMOTO, T.: (1952) Histochemical Studies on the Glycogen of the Mammalian Brain. Anat. Rec. **114,** 479. — 42. SHIMIZU, N., KUBO, Z.: (1957) Histochemical Studies on Brain Glycogen of the Guinea Pig and its Alteration Following Electric Shock. J. Neuropath. Exp. Neurol. **16,** 40. — 43. SHIMIZU, N., HAMURO, Y.: (1958) Deposition of Glycogen and Changes in Some Enzymes in Brain Wounds. Nature (Lond.) **171,** 781. — 44. TIRASPOLSKAYA, N. M., TOROPOVA, M. N.: (1963) On the Glycogen Content in the Tumours of the CNS. Arch. Pat. (Mosk.) **25,** 3, 34. — 45. TSCHIRGI, R. D.: (1958) The Blood-brain Barrier. S. 130. In: W. F. Windle: Biology of Neuroglia. Springfield, Illi. Ch. C. Thomas. — 46. VILLAR-PALASI, C., LARNER, J.: (1960) Levels of Activity of the Enzymes of the Glycogen Cycle in Rat Tissues. Arch. Biochem. **86,** 270. — 47. VILLAR-PALASI, C., LARNER, J.: (1960) Insulin Mediated Effect on the Activity of UDPG Glycogen Translucosylase of Muscle. Biochem. et Biophys. Acta **39,** 171. — 48. WOLFE, D. E., NICHOLLS, J. G.: (1967) Uptake of Radioactive Glucose and its Conversion to Glycogen by Neurons and Glial Cells in the Leech Central Nervous System. Neurophysiol. (Springfield, III.) **30,** 1593. — 49. ZIEVE, L.: (1966) Pathogenesis of Hepatic Coma. Arch. of Int. Medicine, **118,** 211.

ON THE HISTOCHEMISTRY OF GLYCOGEN CONTENT IN THE BRAIN OF CHRONIC HEPATOPATHIC PATIENTS

R. LAHL

General information regarding the amount of glycogen contained in the brain under physiological and pathological conditions is followed by discussions dealing with the presence of polysaccharides in hepatopathic patients. The brain of 25 subjects died with cirrhosis and fibrosis of the liver was examined histochemically for glycogen and compared with 25 control brains taken at random from the autopsy material of the Institute of Pathology of the Martin Luther University at Halle. Best's carmine, PAS and BTS (SHIMIZU and KUMAMOTO) as also digestion with diastase and saliva were employed for histochemical analysis. PAS-positive substances were mostly found in the ganglion cells, in the leptomeninx, in the vessel wall and perivascularly, in the neuropil and around the cells, while granules of polysaccharides and glycogen were demonstrable only in the brain of hepatocirrhotic subjects. Such granules were observed in proliferative naked macroglial nuclei in 8 cases; around neuroglial nuclei in 12 cases; in the adventitia or perivascularly in 7 cases; in the neuropil in 8 cases. These findings proved to be significant. No correlation between cerebral and hepatic glycogen was observed. The presence of polysaccharide granules may be due to mostly unelucidated metabolic disturbances as well as the faulty utilization of glucose.

Problems in respect of the intracerebral transport of foodstuffs are discussed. Discrepancy between the histochemically demonstrable amount of glycogen and the activity of enzymes which are known to synthesize it under physiological conditions, points to the existence of undetected factors of central polysaccharide regulation.

ГИСТОХИМИЧЕСКИЕ ДАННЫЕ ОТНОСИТЕЛЬНО СОДЕРЖАНИЯ ГЛИКОГЕНА В ГОЛОВНОМ МОЗГУ БОЛЬНЫХ С ХРОНИЧЕСКИМ ЗАБОЛЕВАНИЕМ ПЕЧЕНИ. СОПОСТАВЛЕНИЕ С НЕПОДОБРАННЫМ СЕКЦИОННЫМ МАТЕРИАЛОМ

Р. ЛАЛ

Наряду с общими примечаниями к содержанию гликогена в головном мозгу в норме и в патологических условиях автор приводит данные о встречаемости полисахаридов при заболеваниях печени. 25 головных мозгов умерших от цирроза или фиброза печени были сопоставлены в отношении их гистохимического содержания гликогена с 25 контрольными мозгами из материала вскрытия Института патологии при Университете им. Мартина Лютер города Галле. Применялись следующие гистохимические методы исследования: Метод БЕСТ-а с кармином, реакции ПАСК и БТС (по Шимизу и Кумамото), а также пробы с диастазой и слюнотечением. ПАСК-положительные вещества в большинстве случаев были обнаружены преимущественно в ганглиозных клетках, в мягкой мозговой оболочке, в сосудистой стенке и перивазально, в невропиле и околоклеточно, тогда как зернышки полисахаридов или гликогена удалось выявить только в срезах головного мозга больных циррозом печени. В 8 случаях эти зернышки были найдены в пролиферированных, голых ядрах макроглии, в 12 случаях перинуклеарно (около ядер невроглии), в 7 случаях в адвентиции или перивазально и в 8 случаях в невропиле. Результаты оказались достоверными. Однако между содержанием гликогена в печени и его концентрацией в головном мозгу не удалось выявить зависимости. Ответственными за появление полисахаридных зернышек следует считать, кроме по большей части еще невыясненных метаболических расстройств, понижение использования глюкозы. Обсуждаются возможности внутримозгового транспорта питательных веществ. Расхождение между гистохимически выявляемым гликогеном и активностью гликогенсинтезирующих энзимов, наблюдаемое уже в условиях нормы, указывает не добавочные, до сих пор неизвестные факторы центральной регуляции полисахаридов.

Dr. R. LAHL Klinik u. Poliklinik f. Psychiatrie und Neurologie, Martin-Luther-Universität Halle—Wittenberg, DDR

RECENSIO

Biology of Amphibian Tumors

Special Supplement, Recent Results in Cancer Research. Ed. Merle Nizell. Springer Verlag, Berlin—Heidelberg—New York 1969. — 484 pages.

The volume contains the material of a symposium held at Tulane University, New Orleans, in 1968. The conference convened in order to facilitate the exchange of ideas between investigators concerned with the different problems regarding amphibian tumours, to review the present state of knowledge about this subject and, finally, to present the recent results in a book for researchers working in other fields of tumour-biology. These objects have not only been fully realized but the symposium went even beyond its original assignment by having ensured the presence of investigators concerned with the tumours of birds and higher vertebrates. These specialists were given opportunity of exchanging views with the experts of amphibian tumours.

The volume contains 11 chapters in which all biological aspects of amphibian tumours are thoroughly discussed. Chapters exclusively dealing with tumours are preceded by papers on the biology of amphibians, the cultivation of their cells, the immunity and tolerance in this class of vertebrates. Although numerous spontaneous tumours of the different amphibians are discussed in the book (lymphoma, lymphosarcoma, plasmacytoma, melanoma), the widest space is devoted to the renal adenocarcinoma of the leopard frog (Rana pipiens), the well known tumour of Lucké. This is only natural because this is the most widely examined amphibian tumour. Its viral origin has long been conjectured, and recent investigations have yielded important results concerning its aetiology. In 1956, FAWCETT observed in the cells of certain Lucké tumours viruses which showed resemblance to the herpes virus. That the tumour is subject to seasonal variations was observed long ago, and microscopic examinations confirmed this phenomenon. Nuclear inclusions were found only in tumours arising in winter or in those of hibernating animals, while the tumours of frogs captured in summer and kept at laboratory temperature contained no nuclear inclusions. At the same time, electron-microscopic inspection revealed viruses only in the tumours of winter and hibernating animals. If tumorous summer frogs were kept for some time at low temperatures, viruses of the herpes-type became demonstrable in their tumour cells, a phenomenon proving that the complete genom of the virus must be present in some masked or latent form in the summer variety of the Lucké tumour. The significance of this observation will be appreciated if we remember that the recovery of viruses from tumours induced in rodents by DNA viruses (i.e. from neoplasms of undoubtedly viral origin) means a thorny problem. It is, moreover, suggested by many authors that human tumours may also harbour viral genoms in a masked form notwithstanding the fact that so far it has been impossible to isolate viruses from human neoplasma of supposedly viral origin.

Since it is obvious from the foregoing that there is a correlation between the temperature and the viruses of cells, frogs with Lucké's tumour are — owing to their poikilothermic nature — particularly suitable for the study of gene repression and derepression. It is worthy of note that, after having incubated at a low temperature virus-free cell cultures prepared from Shope's papilloma, it was possible to induce the appearance of infective viruses.

The chapter on the immunological methods for the study of virus antigens associated with tumours presents a concise clear review of recent results obtained in respect of tumour virology and immunology. The chapter deals also with some important experiments which have shown that the detection of specific antigens determined by the persisting virus genom in virus-free tumours may allow to ascertain the viral aetiology of a given tumour by immunological methods.

The last chapter of the volume is likewise instructive. It describes the present state of knowledge of the role the herpes viruses are suspected to play in the aetiology of various tumours (e.g., Burkitt's lymphoma, human cervical carcinoma, the Marek disease of birds, and the Lucké tumour of frogs).

The book is exemplarily executed, and its text is accompanied by rich illustrations, instructive tables, diagrams and (at the end of each paper) abundant bibliographical data.

The work will undoubtedly promote cancerological research work in general and stimulate also investigations in respect of human tumours. Biologists, medical research workers and clinicians interested in the intriguing problems of tumour biology will derive benefit from this interesting book.

K. Lapis

INDEX

Morphologia Normalis et Experimentalis

Gallyas, F.: Silver Staining of Alzheimer's Neurofibrillary Changes by Means of Physical Development 1

Vigh, B.—Vigh-Teichmann, I.—Koritsánszky, S.—Aros, B.: Ultrastructure of the Spinal CSF Contacting Neuronal System in the White Leghorn Chicken 9

Vigh-Teichmann, I.—Vigh, B.—Aros, B.: Light and Electron Microscopic Structure of the Preoptic Recess Organ in the Newt (Triturus cristatus) 25

Ditscherlein, G.—Witte, Ingrid—Kunde, D.: Charakteristische morphologische Befunde im Nierenmark nach Nierenpunktion 43

Gallyas, F.: A Principle for Silver Staining of Tissue Elements by Physical Development 57

Palkovits, M.—Varga, B.—Stark, E.: Effect of ACTH on Repletion of Blood in the Adrenal and Ovarian Tissues of the Dog 73

Pásztor, E.—Hámori, J.: Effect of Local Cooling on Fine Structure of Cerebral and Cerebellar Cortex 81

Pathologia

Lahl, R.: Ein histochemischer Beitrag zum Glykogengehalt im Hirn von chronisch Leberkranken. (Vergleichsuntersuchungen mit einem unausgewählten Obduktionsmaterial) 89

Recensio 103

Printed in Hungary

A kiadásért felel az Akadémiai Kiadó igazgatója — Műszaki szerkesztő: Várhelyi Tamás

A kézirat nyomdába érkezett: 1971. III. 30. — Terjedelem: 9,5 (A/5) ív, 48 ábra, (4 színes)

71.71521 Akadémiai Nyomda, Budapest — Felelős vezető: Bernát György

The Acta Morphologica publish papers on experimental medical subjects in English, French, German and Russian.

The Acta Morphologica appear in parts of varying size, making up volumes.

Manuscripts should be addressed to:

Acta Morphologica, Budapest IX., Tűzoltó u. 58.

Correspondence with the editors and publishers should be sent to the same address.

The rate of subscription is $ 16.00 per volume.

Orders may be placed with "Kultúra" Foreign Trade Company for Books and Newspapers (Budapest I., Fő utca 32. Account No. 43-790-057-181) or with representatives abroad.

Les Acta Morphologica paraissent en français, allemand, anglais et russe et publient des travaux du domaine des sciences médicales expérimentales.

Les Acta Morphologica sont publiés sous forme de fascicules qui seront réunis en volumes.

On est prié d'envoyer les manuscrits destinés à la rédaction à l'adresse suivante:

Acta Morphologica, Budapest IX., Tűzoltó u. 58.

Toute correspondance doit être envoyée à cette même adresse.

Le prix de l'abonnement est de $ 16.00 par volume.

On peut s'abonner à l'Entreprise du Commerce Extérieur de Livres et Journaux «Kultúra» (Budapest I., Fő utca 32. Compte-courant № 43-790-057-181) ou à l'étranger chez tous les représentants ou dépositaires.

«Acta Morphologica» публикуют трактаты из области экспериментальных медицинских наук на русском, немецком, английском и французском языках.

«Acta Morphologica» выходят отдельными выпусками разного объема. Несколько выпусков составляют один том.

Предназначенные для публикации авторские рукописи следует направлять по адресу:

Acta Morphologica, Budapest IX., Tűzoltó u. 58.

По этому же адресу направлять всякую корреспонденцию для редакции и администрации. Подписная цена — $ 16.00 за том.

Заказы принимает предприятие по внешней торговле книг и газет «Kultúra» (Budapest I., Fő utca 32. Текущий счет № 43-790-057-181) или его заграничные представительства и уполномоченные.

Reviews of the Hungarian Academy of Sciences are obtainable at the following addresses:

ALBANIA
Drejtorija Qändrone e Pärhapjes dhe Propagandimit tä Libri
Kruga Konferenca e Päzes
Tirana

AUSTRALIA
A. Keesing
Box 4886, GPO
Sydney

AUSTRIA
GLOBUS
Höchstädtplatz 3
A-1200 Wien XX

BELGIUM
Office International de Librairie
30, Avenue Marnix
Bruxelles 5
Du Monde Entier
162, rue du vidi 5, Place St. Jean
100. Bruxelles

BULGARIA
HEMUS
11 pl Slaveikov
Sofia

CANADA
Pannonia Books
2, Spadina Road
Toronto 4, Ont.

CHINA
Waiwen Shudian
Peking
P. O. B. 88

CZECHOSLOVAKIA
Artia
Ve Smečkách 30
Praha 2
Poštovní Novinová Služba
Dovoz tisku
Vinohradská 46
Praha 2
Mad'arská Kultura
Václavské nám. 2
Praha I
SLOVART A. G.
Gorkého
Bratislava

DENMARK
Ejnar Munksgaard
Nörregade 6
Copenhagen

FINLAND
Akateeminen Kirjakauppa
Keskuskatu 2
Helsinki

FRANCE
Office International de Documentation et Librairie
48, rue Gay-Lussac
Paris 5e

GERMAN DEMOCRATIC REPUBLIC
Deutscher Buch-Export und Impor
Leninstraße 16
Leipzig 701
Zeitungsvertriebsamt
Fruchtstraße 3—4
1004 Berlin

GERMAN FEDERAL REPUBLIC
Kunst und Wissen
Erich Bieber
Postfach 46
7 Stuttgart S.

GREAT BRITAIN
Blackwell's Periodicals
Oxenford House
Magdalen Street
Oxford
Collet's Subscription Impor Department
Dennington Estate
Wellingsborough. Northants.
Robert Maxwell and Co. Ltd.
4—5 Fitzroy Square
London W. I

HOLLAND
Swetz & Zeitlinger
Keizersgracht 471—487
Amsterdam C.
Martinus Nijhof
Lange Voorhout 9
The Hague

NDIA
Hind Book House
66 Babar Road
New Delhi I

ITALY
Santo Vanasia
Via M. Macchi 71
Milano
Libreria Commissionaria Sansoni
Via La Marmora 45
Firenze
Techna
Via Cesi 16.
40135 Bologna

JAPAN
Kinokuniya Book-Store Co. Ltd.
826 Tsunohazu 1-chome
Shinjuku-ku
Tokyo
Maruzen and Co. Ltd.
P. O. Box 605
Tokyo-Central

KOREA
Chulpanmu
Phenjan

NORWAY
Tanum-Cammermeyer
Karl Johansgt 41—43
Oslo I

POLAND
RUCH
ul. Wronia 23
Warszawa

ROUMANIA
Cartimex
Str. Aristide Briand 14—18
Bucureşti

SOVIET UNION
Mezhdunarodnaya Kniga
Moscow G—200

SWEDEN
Almquist & Wiksell
Gamla Brogatan 26
S—101 20 Stockholm

USA
F. W. Faxon Co. Inc.
15 Southwest Park
Westwood Mass. 02090
Stechert Hafner Inc.
31. East 10th Street
New York, N. Y. 10003

VIETNAM
Xunhasaba
19, Tran Quoc Toan
Hanoi

YUGOSLAVIA
Forum
Vojvode Mišića broj 1
Novi Sad
Jugoslovenska Knjiga
Terazije 27
Beograd

15. IX. 1971

Index: 26.025

Acta Morphologica

Academiae Scientiarum Hungaricae

ADIUVANTIBUS

J. BALÓ, P. ENDES, K. FARKAS, L. HARANGHY,
B. KELLNER, I. KÖRNYEY, I. KROMPECHER,
GY. ROMHÁNYI. E. SOMOGYI, J. SZENTÁGOTHAI

REDIGIT

I. TÖRŐ

TOMUS XIX * FASCICULUS 2

Akadémiai Kiadó Budapest

1971

ACTA MORPHOLOGICA

A MAGYAR TUDOMÁNYOS AKADÉMIA ORVOSTUDOMÁNYI KÖZLEMÉNYEI

SZERKESZTŐSÉG ÉS KIADÓHIVATAL: BUDAPEST V., ALKOTMÁNY U. 21.

Technikai szerkesztő:
Dr. Somogyi Endre

Az Acta Morphologica német, angol, francia és orosz nyelven közöl értekezéseket a kísérletes orvostudomány tárgyköréből.

Az Acta Morphologica változó terjedelmű füzetekben jelenik meg. Több füzet alkot egy kötetet.

A közlésre szánt kéziratok a következő címre küldendők:

Acta Morphologica, Budapest IX., Tűzoltó u. 58.

Ugyanerre a címre küldendő minden szerkesztőségi és kiadóhivatali levelezés.

Megrendelhető a belföld számára az Akadémiai Kiadónál (Budapest V., Alkotmány utca 21. Bankszámla 05-915-111-46), a külföld számára pedig a „Kultúra" Könyv- és Hírlap Külkereskedelmi Vállalatnál (Budapest I., Fő utca 32. Bankszámla: 43-790-057-181) vagy annak külföldi képviseleteinél és bizományosainál.

Die Acta Morphologica veröffentlichen Abhandlungen aus dem Bereiche der experimental-medizinischen Wissenschaften in deutscher, englischer, französischer und russischer Sprache.

Die Acta Morphologica erscheinen in Heften wechselnden Umfanges. Mehrere Hefte bilden einen Band.

Die zur Veröffentlichung bestimmten Manuskripte sind an die folgende Adresse zu senden:

Acta Morphologica, Budapest IX., Tűzoltó u. 58.

An die gleiche Anschrift ist auch jede für die Schriftleitung und den Verlag bestimmte Korrespondenz zu richten. Abonnementspreis pro Band: $ 16,00.

Bestellbar bei dem Buch- und Zeitungs-Außenhandels-Unternehmen »Kultúra« (Budapest I., Fő utca 32. Bankkonto Nr. 43-790-057-181) oder bei seinen Auslandsvertretungen und Kommissionären.

Acta Morphologica Acad. Sci. Hung. 19 (2), pp. 105—122, 1971

Institute of General Zoology (Director: J. Kovács), Eötvös Loránd University, Budapest

EFFECT OF METYRAPONE, PREDNISOLONE AND INSULIN TREATMENT ON THE DOMESTIC PIGEON'S HYPOTHALAMUS

P. Péczely

(Received January 29, 1970)

The hypothalamus of pigeons was investigated with histological and karyometric methods, after treatment with 10 mg of metyrapone daily for 4 and 14 days, 15 mg of prednisolone three times daily for 4 days, 5 mg of prednisolone daily for 12 days as well as with a single 40 I.U. dose of insulin administered intravenously. In the last case the animals were killed 8 hours subsequent to the injection. Metyrapone treatment for 4 days increased nuclear volume in the preoptic, medial and lateral divisions of the supraoptic nucleus and in the arcuate nucleus; it stimulated the function of the aldehyde-fuchsin positive neurosecretory cells and induced a depletion of secretion in the anterior median eminence. Fourteen-day metyrapone treatment caused a strong increase in nuclear volume in the preoptic and lateral cell groups of the supraoptic nucleus as well as in the paraventricular and arcuate nuclei; it brought about a significant transportation of secretion in the aldehyde-fuchsin positive cells and an accumulation of large amounts of aldehyde-fuchsin positive secretion in the anterior median eminence.

Prednisolone treatment for 4 days caused a definite decrease of nuclear volume in the preoptic division of the supraoptic nucleus and in the paraventricular and arcuate nuclei, further an accumulation of secretion in the neurosecretory cells and, to a limited extent, also in the anterior median eminence. Twelve-day treatment induced a significant decrease of nuclear volume in the preoptic and lateral divisions of the supraoptic nucleus, the paraventricular and arcuate nuclei as well as in the n. tuberis, with an accumulation of secretion in the neurosecretory cells and the stratum palisadicum of the anterior median eminence.

Under the influence of insulin, a significant increase in nuclear volume was observed in all the investigated cell groups except in the entopeduncular nucleus. The activity of the neurosecretory cells increased, the anterior part of the anterior median eminence was totally emptied whereas in the anterior part of the posterior median eminence aldehyde-fuchsin positive secretion appeared. The amount of secretion in the neural part was not altered by the applied agents. The results indicate that the aldehyde-fuchsin positive neurosecretory system of the anterior hypothalamus and the median eminence is in close functional correlation with corticotropic activity. At the same time, also the arcuate nucleus may play an important role in the regulation of ACTH secretion.

Introduction

The hypothalamic neurosecretory systems are responsible partly for the balance of water metabolism and osmoregulation and partly for the regulation of adenohypophyseal function. The hypothalamo-neurohypophyseal system (ADH) in mammals is well-known and there are a number of histological and physiological data concerning its function in birds (Farner and Oksche, 1962; Munsick 1964; Munsick et al. 1960; Oota and Kobayashi, 1962; Kobayashi et al. 1961). According to these observations arginine-

vasotocin and oxytocin are bound to the neurosecretion formed in the aldehyde-fuchsin positive cell groups of the anterior hypothalamus and from there they react the posterior pituitary through the supraoptic-paraventriculo-hypophyseal tract.

At the same time in birds the histology of the hypothalamus shows two important differences as compared to that of mammals, (1) a large number of Gomori positive (aldehyde-fuchsin positive) cells in groups or dispersed in the anterior and medial hypothalamus, and (2) the anterior median eminence contains numerous aldehyde-fuchsin positive fibres terminating in the perivascular connective tissue (FARNER and OKSCHE, 1962; UEMURA and KOBAYSHI, 1963; and MATSUI, 1966).

It has been shown by ASSENMACHER (1958) that the aldehyde-fuchsin positive secretion in the anterior median eminence disappears after a lesion of the rostral hypothalamus, in other words, the secretion is produced by the neurosecretory cells localized in the latter structure. At the same time, the aldehyde-fuchsin positive fibres of the anterior median eminence do not originate in the supraoptic-paraventriculo-hypophyseal tract. Thus two Gomori positive tracts of different localization might exist; one of them would terminate in the anterior median eminence and the other in the pars nervosa (MATSUI, 1966; OKSCHE et al. 1964).

The secretion of the anterior median eminence and that of the pars nervosa differ from each other both histochemically (OKSCHE et al. 1959; FARNER and OKSCHE, 1962; BERN et al. 1966; PÉCZELY, 1966a; 1966b; OKSCHE et al. 1964) and electronmicroscopically (KOBAYASHI et al. 1961; OEHMKE et al. 1969; PÉCZELY and CALAS, 1970).

The neurosecretion content of the pars nervosa is sensitive to osmotic stimuli which do not affect that of the anterior median eminence (FARNER and OKSCHE, 1962; OKSCHE et al., 1963; 1964; PÉCZELY, 1966b). On the other hand in photosensitive birds the daily changes in light, adenohypophysectomy or ACTH treatment were found significantly to affect the secretion content of the anterior median eminence, in contrast to that of the pars nervosa (OKSCHE et al., 1969; FARNER and OKSCHE, 1962; UEMURA and KOBAYASHI, 1963; OKSCHEet al., 1964; KOBAYASHI et al., 1966; PÉCZELY, 1966b).

Thus, the Gomori positive axons terminating in the outer zone of the anterior median eminence and in the pars nervosa differ from each other both morphologically and functionally. Accordingly, in birds, besides the Gomori positive hypothalamo-hypophyseal (ADH) system, there exists another Gomori positive system the neurosecretory cells of which are also localized in the anterior hypothalamus, most of its axons terminate in the anterior median eminence and some in the posterior median eminence.

The Gomori positive neurosecretory system of the median eminence was shown to regulate the gonadotropic, thyreotropic and corticotropic func-

tions of the pituitary in birds (FARNER and OKSCHE, 1962; MATSUI, 1966; ASSENMACHER, 1968; ASSENMACHER and TIXIER-VIDAL, 1965; KANEMATSU and MIKAMI, 1969; LEGAIT, 1969; EGGE and CHIASSON, 1963; KAWASHIMA et al., 1964; PÉCZELY, 1969a; 1969b; PÉCZELY and ZBORAY, 1967), and also in amphibia (RODRIGUEZ et al., 1967; RODRIGUEZ, 1969; COMPHER, 1969; GOOS and OORDT, 1969).

It has been shown that in mammals the releasing factors regulating the functions of the adenohypophysis, are produced by the parvocellular groups of the mediobasal pituitary, the so-called hypophyseotropic area (SZENTÁGOTHAI et al., 1962; HALÁSZ et al., 1962; PORTER, 1969). The role of this area in the regulation of pituitary function in birds has also been proved. Thus according to WILSON (1967), GRABER et al. (1967), RALPH and FRAPS (1959, 1960) and STETSON (1969), the lesion of the infundibular nucleus (arcuate nucleus) abolishes the photoperiodical testicular reaction and causes an atrophy of the gonads and the crest. FRANKEL et al. (1967) reported on a significant decrease in adrenal function after the lesion of the ventral tuberal area.

All these results show that, in contrast to the situation in mammals, in amphibia and birds there exists a Gomori positive neurosecretory system connected with the median eminence and regulating the function of the adenohypophysis. This system is not identical with the classical ADH system. On the other hand, the role of the tubero-infundibular area in the control of the adenohypophysis is unquestionable both in birds and in mammals.

Thus, it seemed interesting to study by qualitative and quantitative histological methods, how the aldehyde-fuchsin positive cell groups of the anterior hypothalamus, the tubero-infundibular area and the median eminence react to the agents mentioned above.

Material and methods

Adult domestic pigeons of both sexes were used. They were kept at 23°C temperature, and illuminated for 11 hours daily. Eight pigeons served as control; 7 were treated intramuscularly with 5 mg of metyrapone in oil daily for 4 days and further 7 birds for 14 days. Seven pigeons were treated orally with 15 mg of prednisolone daily for 4 days, while further 7 pigeons received 5 mg of prednisolone daily for 12 days. Six birds were treated with a single intravenous injection of 40 I.U. insulin and killed 8 hours later.

The animals were killed by decapitation. The brain was fixed in Heidenhain's Susa fixative. After double embedding according to Péterfi, sections 5 μ thick were cut and stained with paraldehyde-fuchsin combined with haematoxylin.

In each case 200 cell nuclei of each hypothalamic cell group were measured on a projected picture of 2,500 fold magnification. The logarithm of the nuclear volumes was calculated on the basis of the Fischer-Inke nomogram, using the formula $\pi/6$ LB^2. The arithmetical mean of the logarithms of each cell group as well as their scattering were computed. The changes in nuclear volume were evaluated by Student's t test. The differences were considered significant if $p = 0.001$ and $t \geq 3.29$. Taking into consideration the error of the methods used, only those statistically significant cases were evaluated biologically where $|m_1 - m_2| > 0.05$.

Results

The cell groups of the hypothalamus will be termed according to the nomenclature used by ARAI (1963), FARNER and OKSCHE (1962), PÉCZELY (1966a; 1966b), KARTEN and HODOS (1967), VAN TIENHOVEN and JUHÁSZ (1962).

1. Aldehyde-fuchsin positive cell groups of the anterior and medial hypothalamus

The preoptic, lateral and medial divisions of the supraoptic, paraventricular and entopeduncular nuclei can be differentiated; their topography has been described by PÉCZELY (1966a; 1966b).

a) *Metyrapone treatment for 4 days.* An increase of the secretory activity was observed in all three divisions of the supraoptic nucleus. The granular secretion content of the perikaryon decreased, a finely granular secretion appeared in the axons and nuclear volume increased significantly. The highest degree of functional activation was shown by the preoptic and lateral divisions.

In the cells of the paraventricular nucleus, the amount of secretion was slightly increased and so was nuclear volume. The situation was the same in the cells of the entopeduncular nucleus.

b) *Metyrapone treatment for 14 days.* The cells of the supraoptic nucleus showed hypertrophy; the amount of Nissl-granules increased. Nuclear volume was significantly increased as compared to the controls, but less than under the effect of 4-day treatment.

The cells of the paraventricular nucleus showed a slight hypertrophy whereas their secretion content decreased. Numerous cells were shrunk, filled with secretion, some of them were pycnotic. Nuclear volume was significantly increased.

The cells of the entopeduncular nucleus showed no essential change, nuclear volume was slightly increased.

c) *Prednisolone treatment for 4 days.* A roughly granulated secretion in the cells of the supraoptic nucleus. There was a definite decrease of nuclear volume in the preoptic division, whereas in the others an insignificant increase occurred.

The cells of the paraventricular nucleus showed a considerable decrease in nuclear volume, while those of the entopeduncular nucleus a slight decrease.

d) *Prednisolone treatment for 12 days.* Granulated aldehyde-fuchsin positive secretion appeared in considerable amount in all cell groups.

Nuclear volumes decreased significantly in the preoptic and lateral division of the supraoptic nucleus, and increased in their medial division.

The cells of the paraventricular nucleus showed a considerable decrease in nuclear volume.

No essential cytological changes were found in the cells of the entopeduncular nucleus, but nuclear volume was slightly increased.

e) *Insulin treatment.* A considerable hypertrophy was found in the neurosecretory cells of all the three divisions of the supraoptic nucleus. The cells were characterized by a swelling of the perykaryon, finely granulated secre-

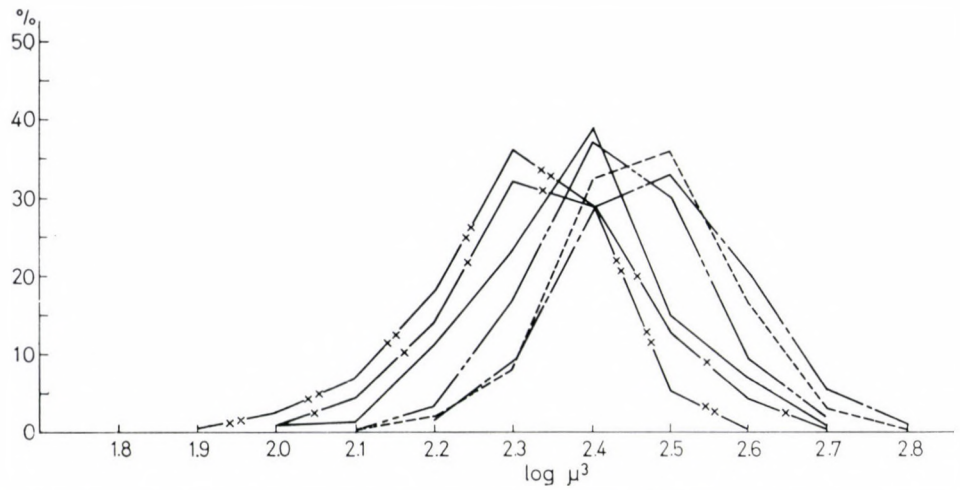

Fig. 1. Distribution of nuclear volume in the preoptic division of the supraoptic nucleus ——— : control; — · — : metyrapone treatment for 4 days; — -- — : metyrapone treatment for 14 days; — × — : prednisolone treatment for 4 days; — × × — : prednisolone treatment for 12 days; - - - - : insulin treatment. The significance of the lines is the same on all karyometric curves of Figs 1—7

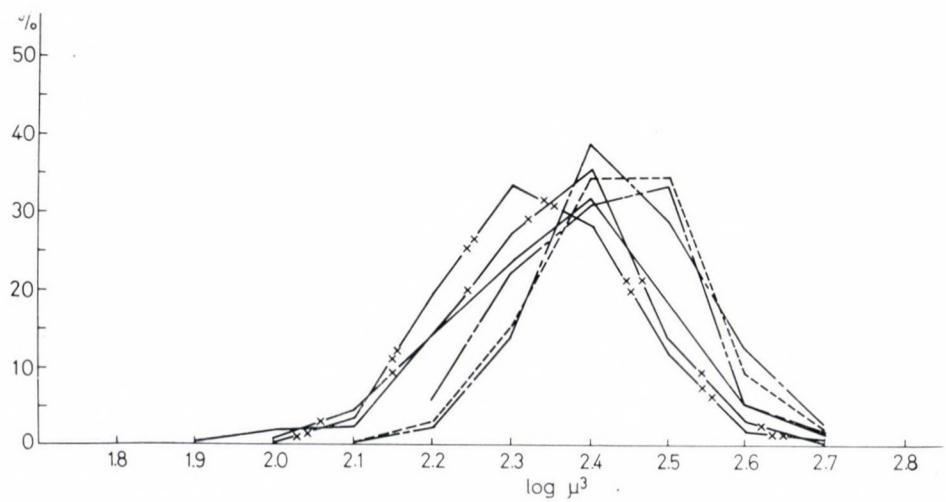

Fig. 2. Lateral division of supraoptic nucleus

tion, well developed peripheral Nissl-granulation and vacuolization of the cytoplasm. Nuclear volume increased very significantly.

The cells of the paraventricular nucleus were less hypertrophic but the increase in nuclear volume was significant.

Neither cytological nor karyometric changes occurred in the entopeduncular nucleus (Figs 1—5).

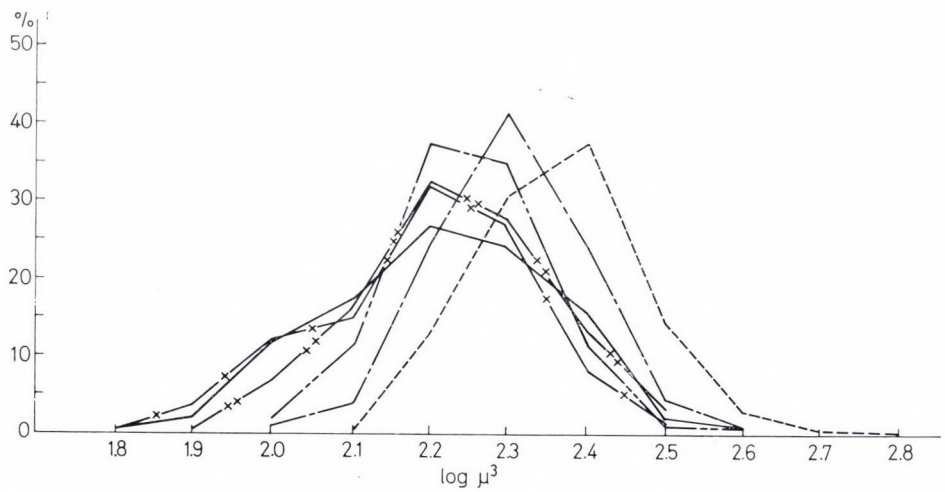

Fig. 3. Medial division of supraoptic nucleus

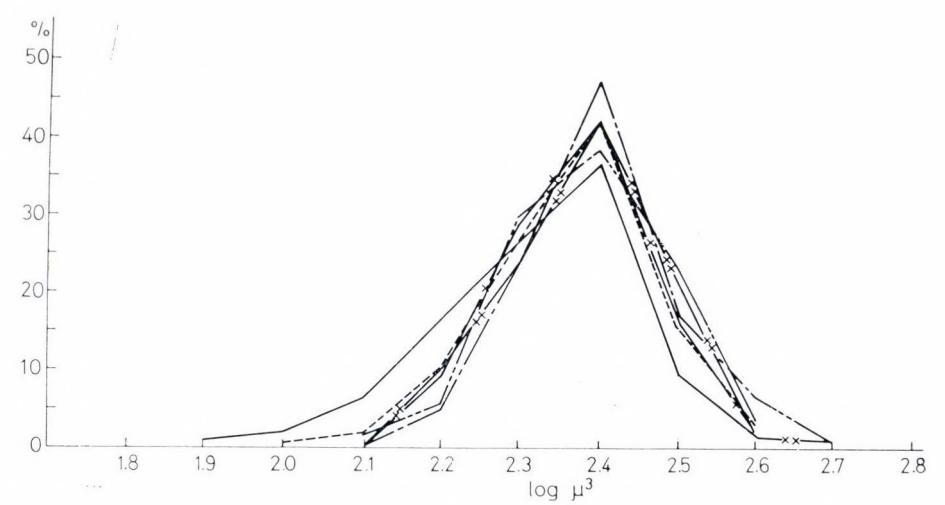

Fig. 4. Entopedurcular nucleus

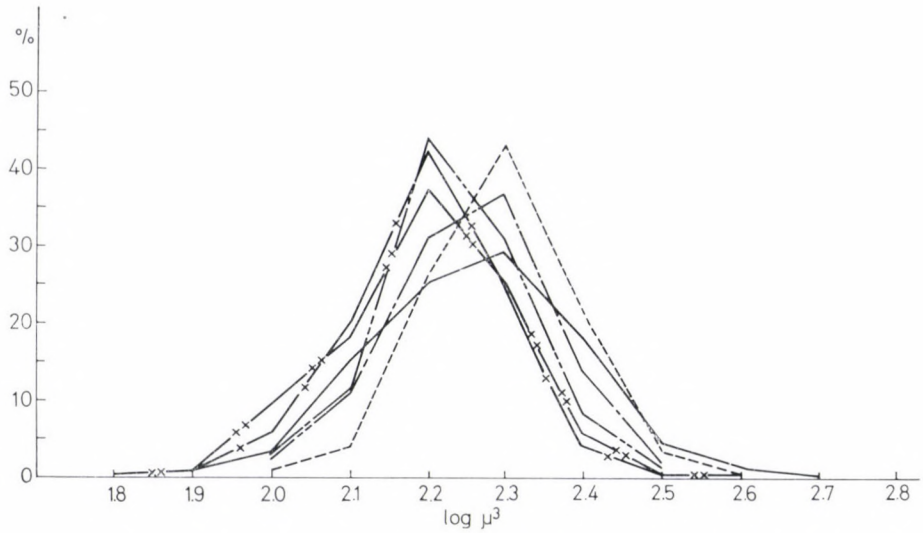

Fig. 5. Paraventricular nucleus

2. *Parvocellular nuclei of the tubero-infundibular region*

Two continuous cell groups were found. The arcuate nucleus was of ventromedial localization, it contained cells with small nuclei and surrounded the end of the infundibular recess widening on the ventral side. Some of its cells penetrated into the internal zone of the median eminence. In the perikaryon of these cells there was no aldehyde-fuchsin positive secretion. Some of the cells of the arcuate nucleus contained a number of basophilic granules indicating an increased development of the endoplasmic reticulum.

The nuclei of the periventricular cells of the arcuate nucleus were smaller (the maximum was 2.0) than those of the cells localized more laterally, where the maximum was 2.1. Since the cells of these groups reacted uniformly to the treatments, the values for the two cell populations were considered together.

The n. tuberis was of more dorsolateral localization than the arcuate nucleus; its cells were larger and lighter, localized more diffusely and characterized by an increased nuclear volume.

a) *Metyrapone treatment for 4 and 14 days.* A strongly significant increase in nuclear volume occurred in both cell groups of the arcuate nucleus.

b) *Prednisolone treatment for 4 days.* A considerable decrease in nuclear volume occurred in the arcuate nucleus, whereas an increase in the n. tuberis.

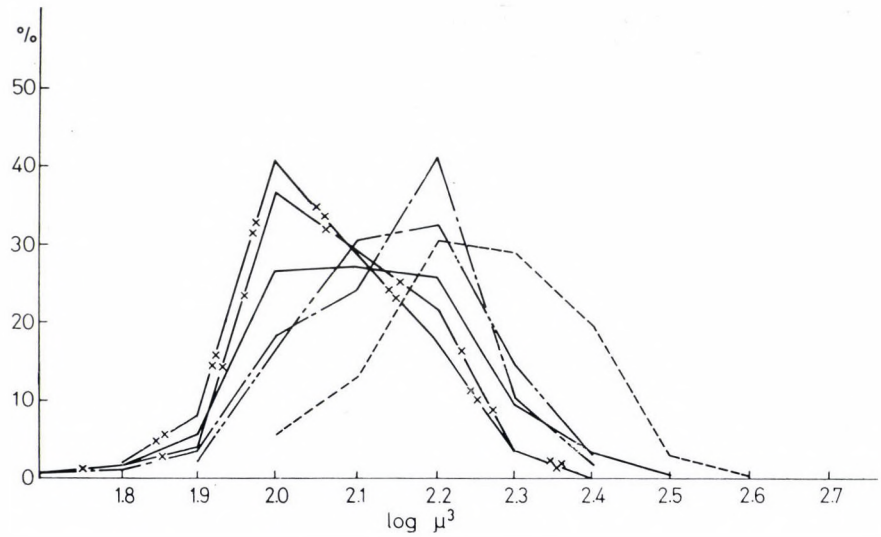

Fig. 6. Arcuate nucleus

c) *Prednisolone treatment for 12 days.* A strongly significant decrease of the nuclear volume was recorded in both groups of cells.

d) *Insulin treatment.* Nuclear volume increased strongly significantly n both the n. arcuatus and the n. tuberis (Figs 6—8).

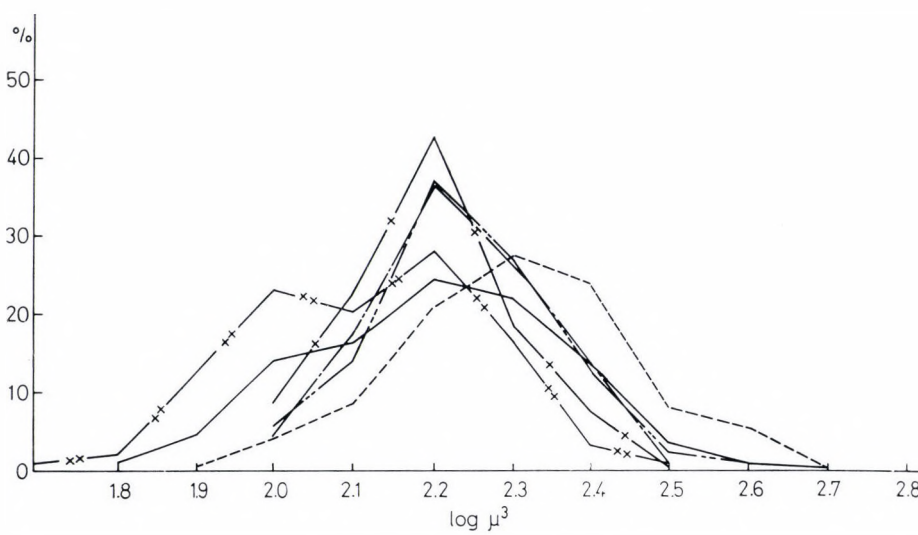

Fig. 7. Tuberal nucleus

	n. supraopticus			n. ento-peduncularis	n. para-ventricularis	n. arcuatus	n. tuberis
	praeoptical	lateral	medial				
Metyrapone 14 days	+ 5.6*	+ 8.3*	+ 6.5	+ 6.9	+12.4*	+ 4.5*	+ 7.7
Metyrapone 4 days	+24.5*	+13.7*	+20.5*	+ 8.3*	+ *2.4*	+12.0*	+ 7.8
Prednisolone 12 days	−15.2*	− 5.9*	+ 6.5	+ 6.2	−11.2*	−12.2*	−10.7*
Prednisolone 4 days	− 6.5*	+ *1.9*	+ *2.1*	+4.3	−14.3*	− 9.1*	+ 6.0
Insulin	+18.8*	+13.7*	+29.9*	+3.8	+ 8.3*	+26.5*	+18.3*

Fig. 8. Table of t values ($p = 0.001$). — : not significant; + : significant and* $| m_1 - m_2 | > > 0.05$

3. *Median eminence*

In the domestic pigeon this structure is divided into well defined anterior and posterior parts. In control birds, the supraoptic-paraventriculo-hyophyseal tract running in the internal zone of the anterior median eminence, contains Herring bodies. The reticular stratum of the external zone contains more roughly granulated aldehyde-fuchsin positive secretion than the fine granulated one in the palisadic stratum (Fig. 9).

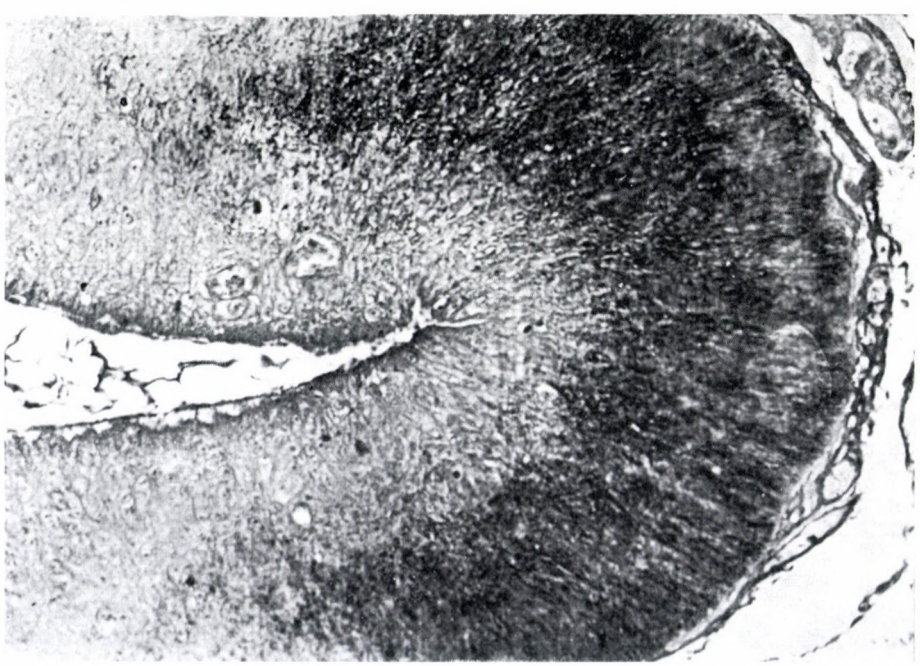

Fig. 9. Control, anterior median eminence, Susa, paraldehyde-fuchsin-haematoxylin, ×210

a) *Metyrapone treatment for 4 days.* The amount of the secretion was reduced in the external zone, except in one pigeon. The secretion content of the reticular and palisadic stratum was considerably decreased. Some places of the beta zone were more rich in secretion (Fig. 10).

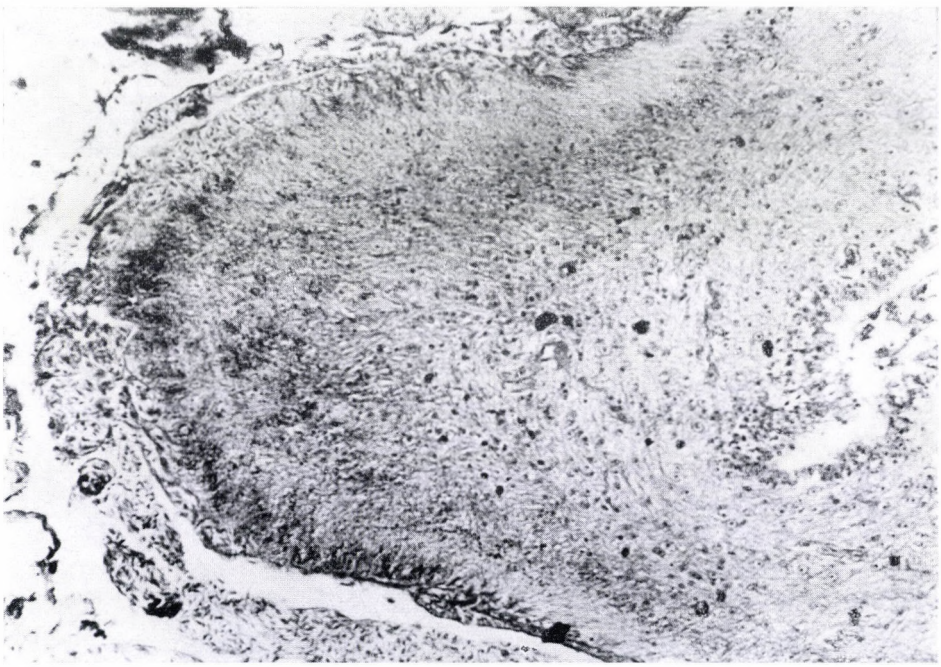

Fig. 10. Metyrapone treatment for 4 days, anterior median eminence, Susa, paraldehyde-fuchsin-haematoxylin, ×210

b) *Metyrapone treatment for 14 days.* The amount of the secretion increased considerably in the external zone. At the same time areas containing less or almost no secretion were observed in the external beta zone, especially in the lateral parts of the median eminence. A lack of secretion, as in the animals treated for 4 days, occurred in the external zone in two pigeons. A number of large Herring bodies were seen in the tract (Fig. 11).

c) *Prednisolone treatment for 4 days.* The secretion content of the reticular stratum decreased. Large neurosecretory grains appeared in the palisadic stratum. The tract contained only a few Herring bodies (Fig. 12).

d) *Prednisolone treatment for 12 days.* The reticular stratum is almost devoid of secretion, the palisadic stratum contained roughly granulated secretion. A small number of little Herring bodies coud be observed in the fibrose stratum (Fig. 13).

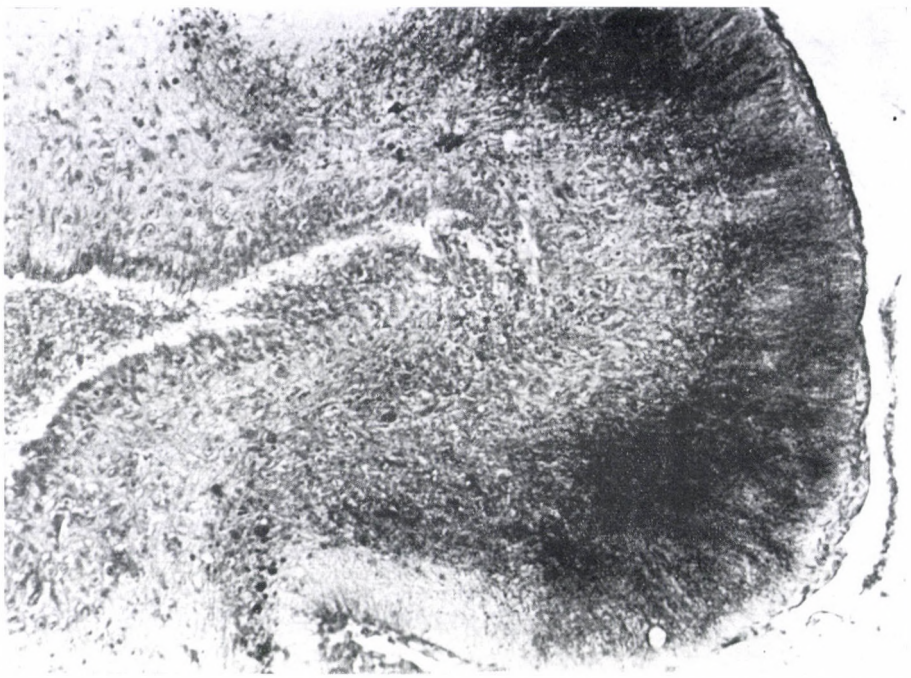

Fig. 11. Metyrapone treatment for 14 days, anterior median eminence, Susa, paraldehyde-fuchsin-haematoxylin, ×210

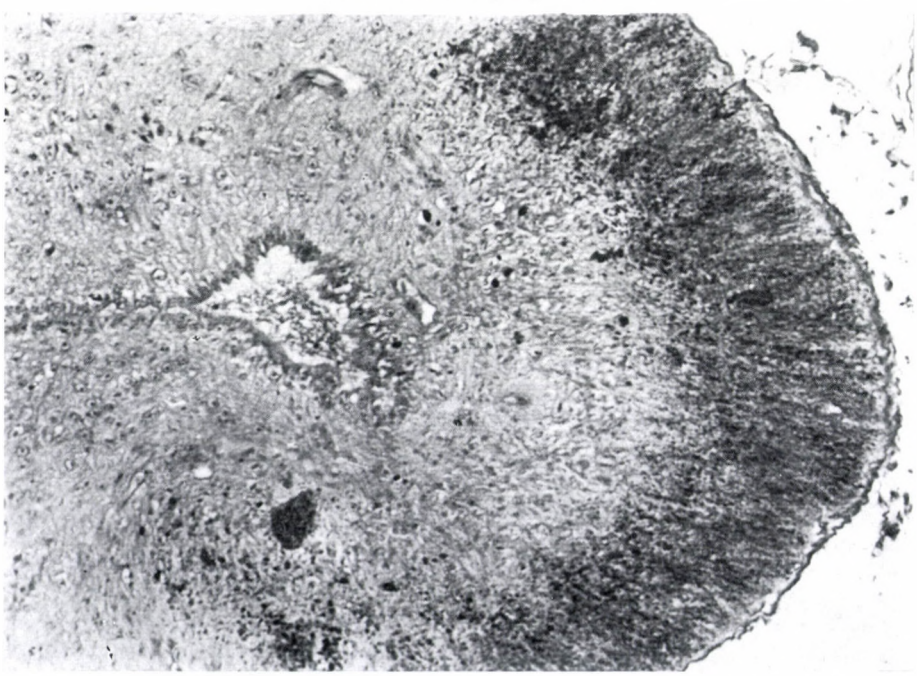

Fig. 12. Prednisolone treatment for 4 days, anterior median eminence, Susa, paraldehyde-fuchsin-haematoxylin, × 210

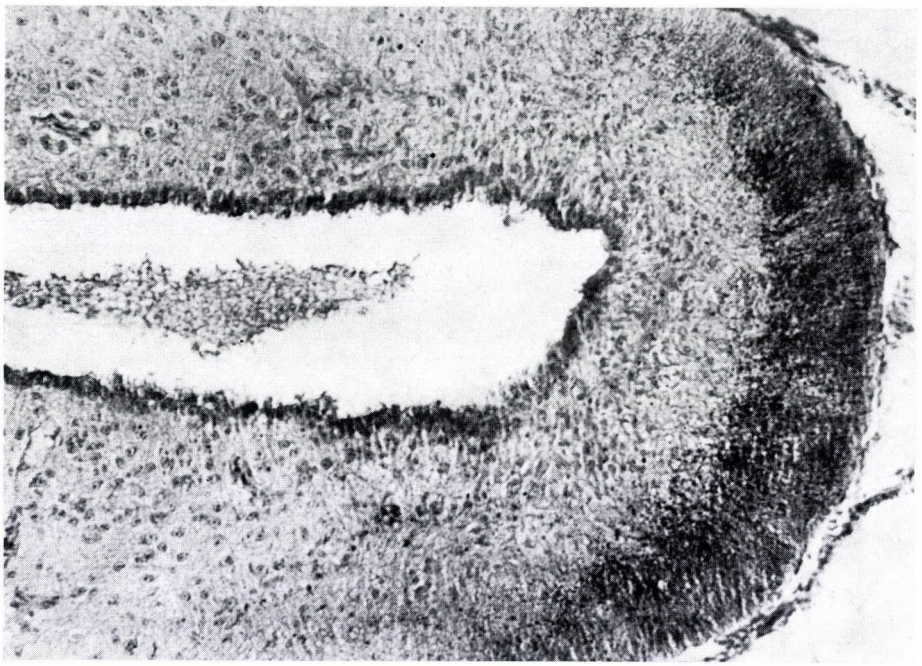

Fig. 13. Prednisolone treatment for 12 days, anterior median eminence, Susa, paraldehyde-fuchsin-haematoxylin, × 210

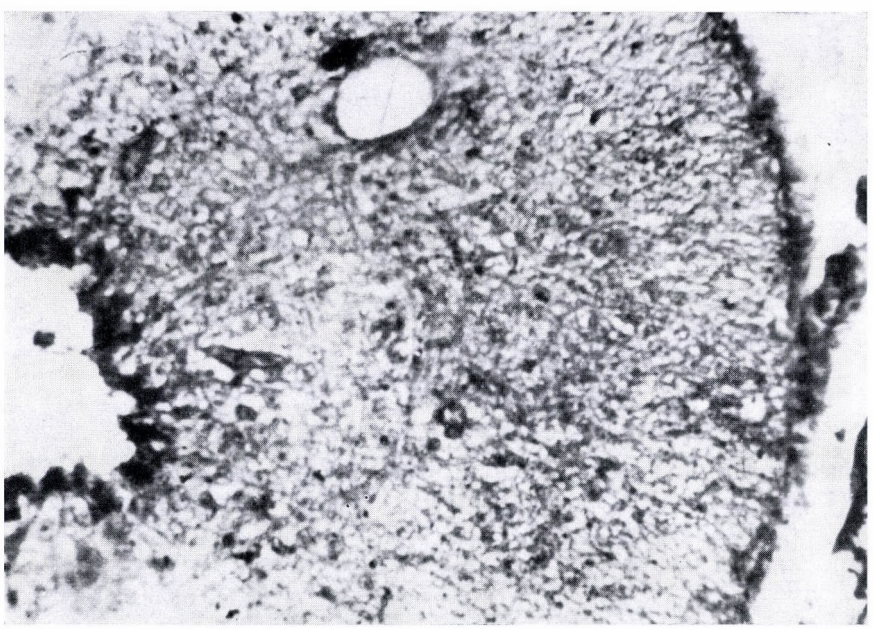

Fig. 14. Insulin treatment, anterior median eminence, Susa, paraldehyde-fuchsin-haematoxylin, × 620

e) *Insulin treatment.* The secretion disappears from the front part of the anterior median eminence. The reticular and palisadic strata are devoid of secretion. Even in the area of the fibrous layer there are only few aldehyde-fuchsin positive granules. In the anterior part of the posterior median eminence an aldehyde-fuchsin positive granulation occurs running in radial direction (Fig. 14).

4. *Pars nervosa*

The agents did not essentially affect the aldehyde-fuchsion positive secretion content of the pars nervosa. It slightly decreased under the influence of prednisolone and insulin, whereas metyrapone caused a certain accumulation of the stained neurosecretion.

Discussion

The agents applied in the present study brought about significant changes in corticotropic function.

All the investigated aldehyde-fuchsin positive and negative (tuberoinfundibular) cell groups of the hypothalamus have reacted to the agents. Thus, the results indicate that not only the neurones connected with adrenal function were affected, but there was a possibility of secondary neuroendocrine responses.

However, taking into consideration the tendency and extent of the changes, certain differences could be found between the cytological changes of the individual nuclei. The reaction of the preoptic and lateral divisions of the supraoptic nucleus occurred in parallel with the changes in adrenal function. The arcuate nucleus and the n. tuberis reacted to agents applied in the same way, except to 4-day prednisolone treatment. However, among the Gomori positive cell groups the origin of the axons reaching the median eminence could not be established.

The karyometric and histological results can only be interpreted by comparing them with the results of physiological investigations. Several observations indicate a parallelism between the aldehyde-fuchsin positive elements of the avian hypothalamus and its CRF activity. Apart from the median eminence, only the supraoptic region has a considerable CRF activity (PÉCZELY, 1969b). The CRF activity of the supraoptic area could not be decreased by thioglycolate treatment, it did not react to thirst, but definitely decreased upon the influence of prolonged metyrapone treatment (PÉCZELY, 1971, in press). On the other hand, a connection appears to exist between the aldehyde-fuchsin positive secretion content and the CRF activity of the median eminence (PÉCZELY and ZBORAY, 1967).

Metyrapone treatment for 4 and 14 days caused an increase in the function of every aldehyde-fuchsin positive cell groups (secretion and depletion, increase in nuclear volume). Four-day treatment resulted in a considerable depletion in the anterior median eminence, whereas 14-day treatment caused a significant transportation and accumulation of the secretion in the external zone together with a presumable further depletion.

Metyrapone treatment for 14 days increased the CRF activity of the median eminence (PÉCZELY, unpublished results) and caused a hypertrophy of the ACTH cells of the adenohypophysis (TIXIER-VIDAL et al., 1968; PÉCZELY and SZOKOLY, 1969).

Prednisolone treatment induced an accumulation of secretion in the aldehyde-fuchsin positive nuclei, while the changes in nuclear volumes were of a different character. The accumulation of the secretion took place in the neuro-haemal zone of the median eminence, while it disappeared in the reticular stratum. This shows that the transportation of secretion decreased toward the external zone and the neurohormone depletion was inhibited.

Similar histological changes have been observed in the median eminence under the influence of ACTH (PÉCZELY, 1966a).

In earlier studies, CRF activity of the median eminence was considerably decreased by prednisolone treatment (PÉCZELY, 1969a) and an accumulation of secretion in the epsilon cells as well as a parallel increase in pituitary ACTH content was noted (PÉCZELY and SZOKOLY, 1969).

The functions of all aldehyde-fuchsin positive cells are enhanced by insulin. Characteristic changes occur in the median eminence: the stained secretion disappears from the rostral part of the anterior median eminence, meanwhile in the front of the posterior median eminence many aldehyde-fuchsin positive granules appear. A similar change has been observed by KAWASHIMA et al. (1964) in the median eminence of Zonotrichia under the influence of thirst; the depletion was brought into connection with the hypertrophy of the adrenal cortex.

The median eminence of pigeons killed 8 hours subsequent to insulin treatment (40 I.U.) showed practically no CRF activity (PÉCZELY, 1969a).

These results render it probable that the CRF activity of the pigeon's hypothalamus is connected with the aldehyde-fuchsin positive neurosecretory system in the anterior hypothalamus and the median eminence. However, the methods used were unsuitable to determine the exact site of CRF formation.

It should be emphasized at the same time that according to literary data (FRANKEL et al. 1967b; FRANKEL, 1970; PÉCZELY, 1969b), the pars nervosa and the ADH system do not play any considerable role in the regulation of corticotropic function either in vivo or in vitro. The histological results are in accordance with the above statements, since the neurosecretion

content of the neurohypophysis was not significantly altered either by ACTH (PÉCZELY, 1966a) or by metyrapone, prednisolone and insulin. Metyrapone and insulin caused an increase, while prednisolone a decrease in nuclear volumes, mainly in the arcuate nucleus of the tubero-infundibular area. The role of the ventral tuberal area in the regulation of corticotropic function has been shown by FRANKEL et al. (1967a) using the experimental lesion technique. At the same time, the tubero-infundibular region showed no considerable CRF activity in vitro (PÉCZELY, 1969b), so that it seems improbable that the CRF should be formed in this region.

Monoamine containing cells of periventricular localization have been found by SHARP and FOLLETT (1968; 1969) in the infundibular area, the axons of which together with those of the non-fluorescing aldehyde-fuchsin negative cells of the most lateral localization, terminate in the external zone of the anterior and posterior median eminence. According to these authors (SHARP and FOLLETT, 1969), in the quail the fluorescence originates from dopamine and norepinephrine, which presumably play a role in the regulation of adenohypophysial functions.

It has been shown in the rat by AKMAYEV and DONÁTH (1965) that the fluorescing substances of the median eminence react well to adrenalectomy and hydrocortisone treatment. Nevertheless, some authors (CARR and MOORE, 1968; HIRS and MOORE, 1968; BARRY 1969) claim that there is no correlation between the catecholamine content of the brain and the corticotropic functions, and metyrapone and cortisone did not alter the fluorescence of the infundubular nucleus.

Both the literary data and the results of our histological investigations indicate that the tubero-infundibular area might be connected with the regulation of ACTH secretion. It may be assumed that this area modulated the CRF activity of birds at the level of the median eminence either as part of the monoaminergic system of the hypothalamus or through cholinergic mechanisms. This assumption is supported by the results of MATSUI (1966; 1969b) who described synaptic and synaptic-like connections between the monoaminergic and neurosecretory fibres as well as between the monoaminergic and glial fibres of the median eminence in the pigeon.

REFERENCES

1. AKMAYEV, I. G., DONÁTH, T.: (1965) Die Katecholamine der Zona palisadica der Eminentia mediana des Hypothalamus bei Adrenalectomie, Hydrocortison-Verabreichung und Stress. Z. mikr.-anat. Forsch. **74,** 83—91. — 2. ARAI, Y.: (1963) Diencephalic Necrosecretory Centers of the Passerine Bird, Zosterops Palpebrosa japonica. J. Fac. Sci. Univ. Tokyo Sect. IV. **10,** 1—3. — 3. ASSENMACHER, I.: (1958) Recherches sur le controle hypothalamique de la fonction gonadotrope préhypophysaire chez le Canard. Arch. Anat. micr. Morph. exp. **47,** 447—572. — 4. ASSENMACHER, I., TIXIER-VIDAL, A.: (1965) Hypothalamic-pituitary Relations. In: Proc. Second Int. Congr. Endocrinology Excerpta med. Found. Congr. Ser.

Pp. 131—145 — 5. BARRY, J.: (1969) Étude histophysiologique des monoamines dans l'axe hypothalamo-préhypophysaire de divers rangeurs. Colloque de neuroendocrinologie. Pp. 12—14. — 6. BERN, H. A., NISHIOKA, R. S., MEWALDT, L. R., FARNER, D. S.: (1966) Photoperiodic and Osmotic Influence on the Ultrastructure of the Hypothalamic Neurosecretory System of the White Crowned Sparrow, Zonotrichia leucophrys gambellii. Z. Zellforsch. **68,** 198—227. — 7. CARR, L. A., MOORE, K. E.: (1968) Effects of Reserpine and Methyl-Tyrosine on Brain Catecholamines and the Pituitary Adrenal Response to Stress. Neuroendocrinology 3, 285—302. — 8. COMPHER, M.: (1969) Effects of Hypothalamic Lesions upon the Thyroid Gland and the Pars Intermedia of the Pituitary Gland in the Eastern Spotted Newt. Anat. Rec. **163,** 171—172. — 9. EGGE, A. S., CHIASSON, R. B.: (1963) Endocrine Effects of Diencephalic Lesions in the White Leghorn Hen. Gen. comp. Endocr. **3,** 346—361. — 10. FARNER, D. S., OKSCHE, A.: (1962) Neurosecretion in Birds. Gen. comp. Endocr. **2,** 113—147. — 11. FRANKEL, A. I., GRABER, J. W., NALBANDOV, A. V.: (1967a) The Effect of Hypothalamic Lesions on Adrenal Function in Intact and Adenohypophysectomised Cockerels. Gen. comp. Endocr. **8,** 387—396. — 12. FRANKEL, A. I., GRABER, J. W., NALBANDOV, A. V.: (1967a) The Effect of Hypothalamic Lesions on Adrenal Function in Intact and Adenohypophysectomised Cockerels. Gen. comp. Endocr. **8,** 387—396. — 13. FRANKEL, A. I.: (1970) Neurohumoral Control of the Avian Adrenal: A Review. Poultry Sci. **49,** 869—921. — 14. GOOS, H. J. TH., OORDT, P. G. W. J.: (1969) Extirpation of the Preoptic Nucleus and a Subsequent Propylthyouracil (PTU) Treatment in Xenopus levis tadpoles. Abstr. V. European Conf. Endocrinology P. 66. — 15. GRABER, J. W., FRANKEL, A. I., NALBANDOV, A. V.: (1967) Hypothalamic Center Influencing the Release of LH in the Cockerel. Gen. comp. Endocr. **9,** 187—192. — 16. HALÁSZ, B., PUPP, L., UHLARIK, S.: (1962) Hypophyseotropic Area in the Hypothalamus. J. Endocr. **25,** 147—154. — 17. HIRS, G. H., MOORE, K. E.: (1968) Brain Catecholamines and the Reserpine Induced Stimulation of the Pituitary Adrenal System. Neuroendocrinology **3,** 398—405. — 18. KANEMATSU, S., MIKAMI, S.: (1969) Hypothalamic Control of Thyroid in Chickens. Seminar on Hypothalamus and Endocrine Functions in Birds. Tokyo, Pp. 27—28. — 19. KARTEN, H. J., HODOS, W.: (1967) A Stereotaxic Atlas of the Brain of the Pigeon (Columba livia). Johns Hopkins Press. Baltimore pp. 60—108. — 20. KAWASHIMA, S., FARNER, D. S., KOBAYASHI, Y., OKSCHE, A., LORENZEN, L.: (1964) The Effect of Dehydration on Acid Phosphatase Activity, Cateptic Proteinase Activity and Neurosecretion in the Hypothalamo-hypophyseal System of the White Crowned Sparrow, Zonotrichia leucophrys gambellii. Z. Zellforsch. **62,** 149—181. — 21. KOBAYASHI, H., BERN, H. A., NISHIOKA, R. S., HYODO, Y.: (1961) The Hypothalamo-hypophyseal Neurosecretory System of the Parakeet, Melopsittacus undulatus. Gen. comp. Endocr. **1,** 545—564. — 22. KOBAYASHI, H., HIRANO, T., MATSUI, T.: (1966) Accumulation of Aldehyde-fuchsin Stainable Material in the Posterior Median Eminence Following Total Hypophysectomy or Adenohypophysectomy in the Pigeon. J. Fac. Sci. Univ. Tokyo, Sect. IV. **11,** 1—9. — 23. LEGAIT, H.: (1959) Contribution à l'étude morphologique et expérimentale du système hypothalamo-neurohypophysaire de la poule Rhode-Island. Thèse, Nancy. — 24. MATSUI, T.: (1966a) Effect of Prolonged Daily Photoperiods on the Hypothalamic Neurosecretory System of the Tree Sparrow (Passer montanus saturatus). Endocr. jap. **13,** 23—38. — 25. MATSUI, T.: (1966b) Fine Structure of the Posterior Median Eminence of the Pigeon, Columba livia domestica. J. Fac. Sci. Univ. Tokyo, Sect. IV. **11,** 49—70. — 26. MATSUI, T.: (1969) Possible Ependymal and Glial Function in the Pigeon and Rat Median Eminence. Seminar on Hypothalamus and Endocrine Functions in Birds, Tokyo. P. 21. — 27. MUNSICK, R. A.: (1964) Neurohypophysial Hormones of Chickens and Turkeys. Endocrinology **75,** 104—112. — 28. MUNSICK, R. A., SAWYER, W. H., VAN DYKE, H. B.: (1960) Avian Neurohypophysial Hormones: Pharmacological Properties and Tentative Identification. Endocrinology **66,** 860—871. — 29. OEHMKE, H. J., PRIEDKALNS, J., VAUPEL VON HARNACK, OKSCHE, A.: (1969) Fluorescens und elektronenmikroskopische Untersuchungen am Zwischenhirn-Hypophysen System von Passer domesticus. Z. Zellforsch. **95,** 109—133. — 30. OKSCHE, A., LAWS, F. D., KAMEMOTO, F. J., FARNER, D. S.: The Hypothalamo-hypophyseal Neurosecretory System of the White Crowned Sparrow (Zonotrichia leucophrys gambellii). Z. Zellforsch. **51,** 1—41 — 31. OKSCHE, A., WILSON, W. O., FARNER, D. S.: (1964) The Hypothalamic Neurosecretory System of Coturnix coturnix japonica. Z. Zellforsch. **61,** 688—709. — 32. OKSCHE, A., FARNER, D. S., SERVENTY, D. L., WOLF, F., NICHOLS, C. A.: (1963) The Hypothalamo Hypophysial Neurosecretory System of the Zebra Finch, Taenopyga castanotis. Z. Zellforsch. **58,** 846—914. — 33. OOTA, Y., KOBAYASHI, H.: (1962) Fine Structures of the Median Eminence and Pars nervosa of the Pigeon. Annot. zool. jap. **35,** 128—138. — 34. PÉCZELY, P.: (1966a) Effect of ACTH on the Hypothalamic Neurosecretion of the Pigeon (Columba livia domestica L.). Acta biol. Acad. Sci. hung. **16,** 291—310. — 35. PÉCZELY, P.: (1966b) Effect of Thirst and Water Load on the Hypothalamic Regulation of the Adrenal in the Pigeon (Columba livia domestica L.). Acta morph. Acad. Sci.

hung. **14,** 227—244. — 36. PÉCZELY, P.: (1969a) Effect of the Median Eminence of the Pigeon (Columba livia domestica L.) on the Regulation of Adenohypophysial Corticotropin Secretion. Acta physiol. Acad. Sci. hung. **35,** 47—57. — 37. PÉCZELY, P.: (1969b) Localization of CRF in the Pigeon Diencephalon. IV. Congr. Hungarian Soc. Endocrinology and Metabolism, Budapest, Kossuth Pp. 42—43. — 38. PÉCZELY, P.: (1971) Acta physiol. Acad. Sci. hung. In press. — 39. PÉCZELY, P., ZBORAY, G.: (1967) Die Rolle der Eminentia mediana in der Zentralregulation der Nebenniere des Vogels. Gen. comp. Endocr. **9,** 517—518. — 40. PÉCZELY, P., SZOKOLY, M.: (1969) The Light and Electron Microscopic Localization of the ACTH Cell in the Pars distalis of the Pigeon (Columba livia domestica L.) Hypophysis. VI. Hungarian Conference on Electron Microscopy, Balatonszéplak, MTESZ P. 104. — 41. PÉCZELY, P., CALAS, A.: (1970) Ultrastructure de l'éminence médiane du pigeon (Columba livia domestica) dans diverses conditions expérimentales. Z. Zellforsch. **111,** 316—345. — 42. PORTER, J. C.: (1969) Site of Corticotropin Releasing Factor (CRF) Releasing Elements. Endocrinology, **84,** 1398—1403. — 43. RALPH, C. L., FRAPS, R. M.: (1959) Long Term Effects of Diencephalic Lesions on the Ovary of the Hen. Amer. J. Physiol. **197,** 1279—1283. — 44. RALPH, C. L., FRAPS, R. M.: (1960) Introduction of Ovulation in the Hen by Injection of Progesterone into the Brain. Endocrinology, **66,** 269—272. — 45. RODRIGUEZ, E. M., VEGA, J. A., LA MALFA, J. A.: (1967) The Different Origins of the Hypothalamo-hypophyseal Tracts of the Toad, Bufo arenarum. Abstr. IV. Conf. Comp. Endocr. Carlsbad, Acad. Press. P. 60. — 46. RODRIGUEZ, E. M.: (1969) Ultrastructure of the Neurohaemal Region of the Toad Median Eminence. Z. Zellforsch. **93,** 182—212. — 47. SHARP, P. J., FOLLETT, B. K.: (1968) The Distribution of Monoamines in the Hypothalamus of the Japanese Quail, Coturnix coturnix japonica. Z. Zellforsch. **90,** 245—262. — 48. SHARP, P. J., FOLLETT, B. K.: (1969) The Localization of Monoamines, Monoamine-oxidase and Acetylcholinesterase in the Quail Hypothalamo-hypophysial System. Seminar on Hypothalamus and Endocrine Functions in Birds, Tokyo, P. 18. — 49. STETSON, M. H.: (1969) The Role of the Median Eminence in Control of Photoperiodically Induced Testicular Growth in the White Crowned Sparrow, Zonotrichia leucophrys gambellii. Z. Zellforsch. **93,** 369—394. — 50. SZENTÁGOTHAI, J., FLERKÓ, B., MESS, B., HALÁSZ, B.: (1962) Hypothalamic Control of the Anterior Pituitary. Akadémiai Kiadó, Budapest. — 51. UEMURA, H., KOBAYASHI, H.: (1963) Effect of Prolonged Daily Photoperiods and Estrogen on the Hypothalamic Neurosecretory System of the Passerine Bird, Zosterops palpebrosa japonica. Gen. comp. Endocr. **3,** 253—264. — 52. TIXIER-VIDAL, A. FOLLETT, B. K., FARNER, D. S.: (1968) The Anterior Pituitary of the Japanese Quail Coturnix japonica. The Cytological Effects of Photoperiodic Stimulation. Z. Zellforsch. **92,** 610—635. — 53. VAN TIENKOHEN, A., JUHÁSZ, L. P.: (1961) The Chicken Telencephalon, Diencephalon and Mesencephalon in Steretaxic Coordinates. J. comp. Neurol. **185,** 36. 40—54. WILSON, F. E.: (1967) The Tubero Infundibular Neuron System: A Component of the Photoperiodic Control Mechanism of the White-crowned Sparrow, Zonotrichia leucophrys gambellii. Z. Zellforsch. **82,** 1—24.

DIE WIRKUNG DER METOPIRON-, PREDNISOLON- UND INSULIN-BEHANDLUNG AUF DEN HYPOTHALAMUS DER HAUSTAUBE

P. PÉCZELY

Der Hypothalamus von Haustauben, die nach vier- und vierzehntägiger Behandlung mit 10 mg/die Metopiron, nach viertägiger Behandlung mit 3×5 mg/die bzw. zwölftägiger Behandlung mit 5 mg/die Prednisolon und acht Stunden nach einmaliger intravenöser Verabreichung von 40 IE Insulin getötet wurden, wurde mit histologischen und karyometrischen Methoden untersucht. Viertägige Metopironverabreichung verursacht in den präoptischen, lateralen und medialen Zellgruppen des N. supraopticus und im N. arcuatus Kernvolumenvergrößerung, Funktionsanstieg der acidophyl-positiven (AF +) neurosekretorischen Zellen, ferner starke Sekretausscheidung in der vorderen Eminentia mediana. Vierzehntägige Metopirongaben rufen in den präoptischen und lateralen Gruppen des N. supraopticus, im N. paraventricularis und im N. arcuatus starke Kernvolumenvergrößerung, bedeutenden Sekrettransport der AF + Zellen, und in der vorderen Eminentia mediana das Auftreten einer großen Masse von AF + Sekret herbei. Viertägige Prednisolonadministration hat in der präoptischen Zellengruppe des N. supraopticus, im N. paraventricularis und im N. arcuatus ausgeprägte Kernvolumenverminderung, Akkumulation des Sekrets der neurosekretorischen Zellen und in der vorderen Eminentia mediana Sekretanhäufung geringeren Grades zur Folge. Zwölftägige Prednisolonbehandlung bewirkt in den präoptischen und lateralen Gruppen des

N. supraopticus, im N. paraventricularis, im N. arcuatus und N. tuberis bedeutende Kernvolumenverminderung bzw. in den neurosekretorischen Zellen Sekretakkumulation und im Stratum palisadicum der vorderen Eminentia mediana Sekretanhäufung. Nach Insulingabe tritt mit Ausnahme des N. entopeduncularis in sämtlichen untersuchten Zellgruppen eine bedeutende Kernvolumenvergrößerung auf. Die Sekretproduktion der neurosekretorischen Zellen steigt an, der vordere Teil der vorderen Eminentia mediana wird völlig entleert, während im vorderen Teil der hinteren Eminentia mediana AF + Sekret erscheint. Die angewandten Eingriffe riefen keine auffallenden Veränderungen im Sekretgehalt der Pars nervosa herbei. Die Resultate deuten darauf, daß das AF + Neurosekretionssystem im vorderen Hypothalamus — Eminentia mediana in engem funktionellen Zusammenhang mit der kortikotropen Aktivität steht. In der Steuerung der ACTH-Synthese dürfte jedoch auch dem N. arcuatus eine wichtige Rolle zukommen.

ВЛИЯНИЕ ДАЧИ МЕТОПИРОНА, ПРЕДНИЗОЛОНА И ИНСУЛИНА НА ГИПОТАЛАМУС ДОМАШНЕГО ГОЛУБЯ

П. ПЕЦЕЛИ

Гипоталамус голубей, забитых после четырехдневной и четырнадцатидневной дачи 100 мг метопирона в сутки, четырехдневной дачи 3 раза по 5 мг преднизолона в сутки, двенадцатидневной дачи 5 мг преднизолона в сутки и через 8 часов после однократной внутривенной инъекции 40 МЕ инсулина, был исследован гистологическими и кариометрическими методами. Четырехдневная дача метопирона обуславливает в предзрительной, латеральной и медильной клеточных группах надзрительного ядра и в дугообразном ядре увеличение ядерного объема, повышение функции ацидофильно-положительных (AF +) нейросекреторных клеток и в переднем среднем возвышении значительное выделение секрета. Четырнадцатидневное введение метопирона вызывает в предзрительной и боковой группах надзрительного ядра, в паравентрикулярном и дугообразном ядрах значительное увеличение ядерного объема и усиленный транспорт секрета AF + клеток, и в переднем среднем возвышении появление большой массы AF + секрета. Четырехдневная дача преднизолона приводит в предзрительной группе надзрительного ядра, в паравентрикулярном и дугообразном ядрах к выраженному уменьшению ядерного объема, к аккумуляцию выделения нейросекреторных клеток и в переднем среднем возвышении к накоплению секрета меньшего размера. Двенадцатидневная дача преднизолона вызывает в предзрительной и латеральной клеточных группах надзрительного ядра, в паравентрикулярном в дугообразном ядрах и в n. Tuberis значительное уменьшение ядерного объема, в нейросекреторных клетках накопление секрета, а в палисадном слое переднего среднего возвышения аккумуляцию выделения. После введения инсулина, за исключением n. entopeduncularis, во всех исследовавшихся клеточных группах наступает значительное увеличение ядерного объема. Повышается образование выделения в нейросекреторных клетках, передняя часть переднего среднего возвышения совершенно опорожняется, в то время как в передней части заднего среднего возвышения появляется AF + секрет. В pars nervosa применяемые автором вмешательства не вызывали поразительных изменений в содержании секрета. Результаты указывают на то, что AF + нейросекреторная система переднего гипоталамуса — среднего возвышения находится в тесной функциональной связи с кортикотропной активностью. В то же время полагается, что в регулировании секреции АКТГ дугообразное ядро также играет важную роль.

Dr. Péter PÉCZELY: ELTE Ált. Állattani és Összehasonlító Bonct. tsz. Budapest VIII., Puskin u. 3., Hungary

Acta Morphologica Acad. Sci. Hung. 19 (2), pp. 123—130, 1971

Institute of Pathophysiology and Institute of Anatomy (Head: Prof. Dr. I. KROMPECHER), University Medical School, Debrecen

EFFECT OF REPTILASE ON THROMBOHAEMORRHAGIC REACTIONS

S. TÓTH, G. LÉVAI and T. SZILÁGYI

(Received June 25, 1970)

Administration of reptilase promotes the development and increases the intensity of the generalized Shwartzman reaction in the rabbit. It induces severe thrombohaemorrhagic and necrotic changes in the kidney of all animals.

Thrombohaemorrhagic and mastocalcergic changes induced according to SELYE et al. in rats were aggravated by reptilase treatment while this had no effect on acute conditioned necrosis.

The present experiments supplied further information about the role of blood-clotting in the examined states.

According to JANCSÓ [4], there is a correlation between experimental inflammation and blood coagulation. It was shown in our earlier experiments [12] that reptilase considerably intensified the local Shwartzman reaction.

SELYE et al. have elaborated various methods to induce inflammatory and thrombohaemorrhagic changes [10], necrosis [7] and calcification [8] in rats.

It was after these antecedents that we studied the effect of reptilase on several reactions of this kind as also on the development of the Shwartzman phenomenon.

Materials and methods

Generalized Shwartzman reaction. Intravenous DL_{20} amounts of E.coli 0111 endotoxin prepared according to Boivin were administered to rabbits with body weights of 2000 ± 200 g, and the injection was repeated after 24 hours. The animals were killed after another 24 hours and the gross renal lesions evaluated (0 = unchanged, 1 = moderate, 2 = marked, 3 = grave haemorrhagic necrosis). At the same time, specimens obtained for histological study were fixed in Susa's solution, embedded, and stained with Endes' trichrome [2], Weigert's staining and in some cases with PAS. A number of rabbits received after the second dose of endotoxin a single intravenous injection of 1 KU reptilase (i.e. one unit of Klobusitzky Haemocoagulase "Disperga", Dr. C. SZALÁGYI, Vienna); another group (controls) received 1.5 KU reptilase instead of the second endotoxin injection.

Wistar rats of 100 g weight were used in another series of experiments. In the control animals (i.e. those not treated with reptilase), reactions of medium intensity were induced.

Thrombohaemorrhagic phenomena. A group of rats was injected with 2 mg carrageenin (Marine Colloids Inc., USA) and members of another group with 2 mg $ScCl_3$ (K and K Laboratories, USA) in 1 ml volume intravenously. At the same time, the animals of both groups received into the right hind paw 100 μg adrenaline (G. Richter Ltd., Hungary) in a volume of 0.1 ml. One group then received intramuscularly 0.5 KU reptilase, the other physiological saline. Intensity of the graded (0—3) reactions was measured after 24 hrs.

Mastocalcergy. Simultaneously with the intravenous injection of 5 neutral lead acetate $(CH_3COO)_2$, (Fisher Scientific Co., USA) 175 μg 5-HT (5-hydroxytryptamine creatinine sulphate,

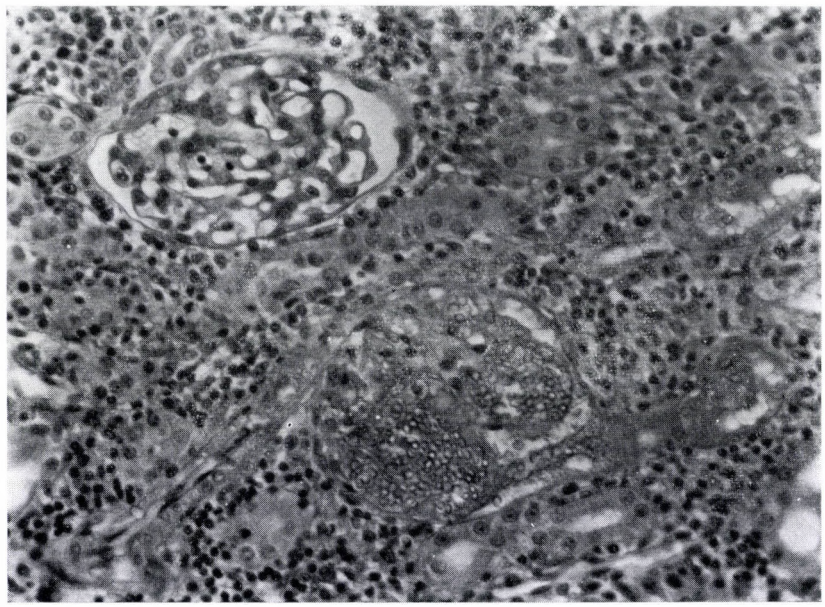

Fig. 1. Glomerulus with intact nuclear staining beside impaired, segmentally necrotized glomerulus adhering to Bowman's capsule and showing vascular congestion. Note diminished nuclear staining (basophilia) in the majority of tubules, further interstitial leucocytic infiltration. Haematoxylin-eosin, × 380

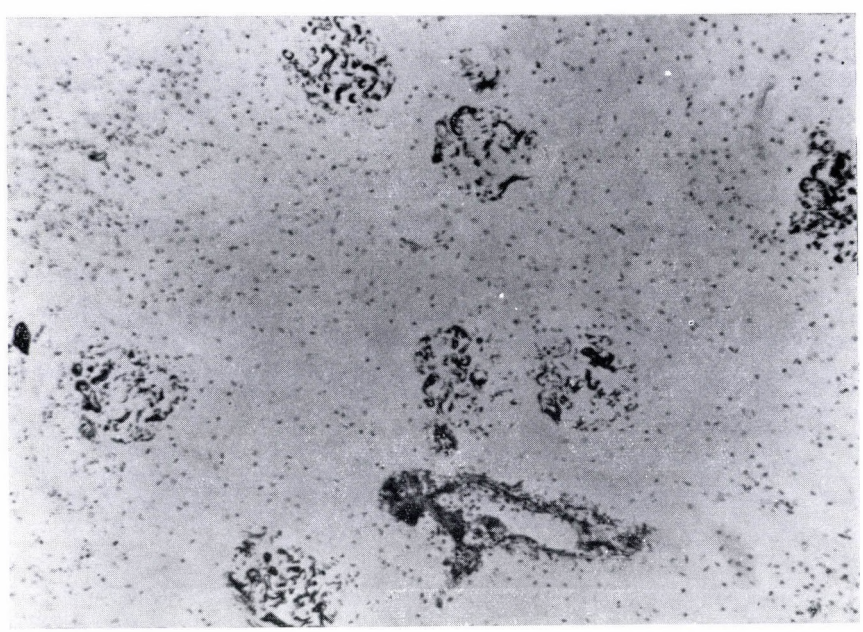

Fig. 2. Weigert-positive substance in the glomerular capillary walls. Weigert's staining, × 140

Merck, Germany) or 150 μg 48/80 (Wellcome Research Laboratories, Canada) was injected subcutaneously into the back of the rats in volumes of 1 ml. To other rats also 0.5 KU reptilase was administered intramuscularly and the injection repeated 12 hrs later. The extent of calcification was determined on the sixth day.

Acute conditioned necrosis. One group received intravenously 1 mg 5-HT, the other 0.1 mg 48/80 and simultaneously also a deep intracutaneous injection of 200 mg NaCl in 2 ml volume into the back. The reptilase-treated animals were injected intramuscularly with 0.5 KU. Evaluation took place 24 hrs later.

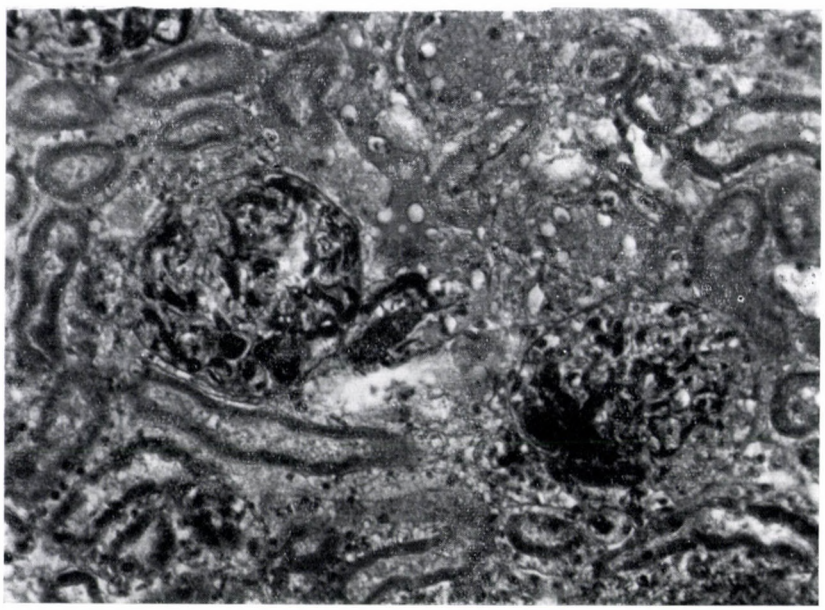

Fig. 3. Endes-positive substance in the capillaries of both glomeruli, especially at the vascular pole. Vascular congestion. Endes' trichrome, × 340

Results

Gross inspection of the kidney revealed signs of the Shwartzman reaction in all rabbits treated with reptilase (Table I) and only in about 66% of the controls.

The kidney of rabbits which had received reptilase showed extensive haemorrhage and necrosis. The vessels were hyperaemic, and the hyperaemia

Table I

Effect of reptilase on the generalized Shwartzman phenomenon

Number of animals	Treatment	Intensity of renal lesions*				Average intensity of reaction
		0	1	2	3	
9	Control	3	3	3	0	1.0
11	Reptilase	0	4	4	3	1.9

* 0 = unchanged, 1 = moderate, 2 = marked, 3 = grave

turned into congestion at some points of the cortex (Fig. 1). Numerous vessels were obstructed by an erythrocyte mass in which the nuclear staining of the leucocytes and the presence of fibrin were observable. Staining with Endes' trichrome revealed a brick-red granular substance in the wall of certain vessels which gave a positive fibrin reaction with Weigert's staining (Figs 2, 3). This phenomenon appeared also in the basement membrane of the glomeruli.

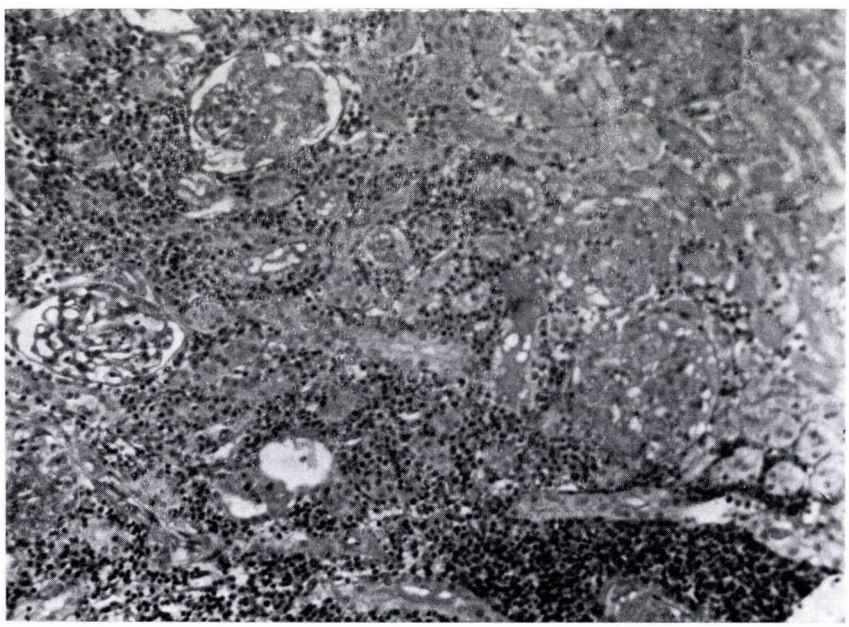

Fig. 4. Glomeruli and tubules with slight or no nuclear staining in the necrotic area (right upper corner). Massive interstitial leucocytic infiltration at the boundary of necrotic area. Haematoxylin-eosin, × 180

Stained with PAS, the substance reacted positively in the vessel walls and in the glomerular membranes alike.

There were necrotic areas in the cortex where the nuclear staining was weak or absent in the epithelial cells of the tubules and in several glomerules. Signs of demarcation were observed at the periphery of the necrotized areas (Fig. 4). These lesions were focal in mild and extended over the entire cortex in grave cases.

The histological changes were considerably more serious than the renal lesions observable in the generalized Shwartzman phenomenon and appeared rather as special forms of ischaemic necrosis.

Administration of reptilase notably increased the intensity of the thrombohaemorrhagic phenomenon, no matter whether carrageenin or $ScCl_3$ has been used in pretreatment (Table II).

Table II

Effect of reptilase on the thrombohaemorrhagic phenomenon

Number of animals	Treatment	Degree of reaction*				Average intensity of reaction
		0	1	2	3	
	Carrageenin + adrenaline					
11	0.5 ml physiol. saline	3	1	4	3	1.6
14	Reptilase	0	0	5	9	2.6
	$ScCl_3$ + adrenaline					
15	0.5 ml physiol. saline	2	8	5	0	1.2
14	Reptilase	0	1	5	8	2.5

* See Table I

The mastocalcergic reaction was likewise enhanced in the reptilase treated group at the sites of the 5-HT and 48/80 injections. Calcification extended to the deep dorsal muscles (Table III). That reptilase intensified this reaction is worthy of note because only calcification and necrosis but no inflammatory or thrombohaemorrhagic changes were seen by the sixth day.

Reptilase treatment had no effect on acute conditioned necrosis which on gross examination appeared to have a thrombohaemorrhagic character (Table IV, Fig. 5).

Table III

Effect of reptilase on the mastocalcergic reaction

Local treatment	Areas of calcification, cm · cm	
	Controls	After reptilase
5-HT	1.0	3.0
	1.0	3.0
	2.0	6.0
	2.0	9.0
	1.0	3.0
Average	1.4	4.8
48/80	3.5	8.0
	4.5	16.0
	4.5	6.0
	4.0	6.0
	4.0	9.0
Average	4.1	9.0

Table IV

Effect of reptilase on conditioned acute necrosis

Systemic treatment	Area in cm · cm at site of local treatment	
	Controls	After reptilase
1 mg 5-HT	10.0	7.5
	7.0	10.0
	10.0	6.0
	7.5	8.0
	9.0	7.0
Average	8.7	7.5
0.1 mg 48/80	6.0	5.0
	3.5	7.5
	4.0	4.0
	6.0	5.0
	8.0	6.0
Average	5.5	5.5

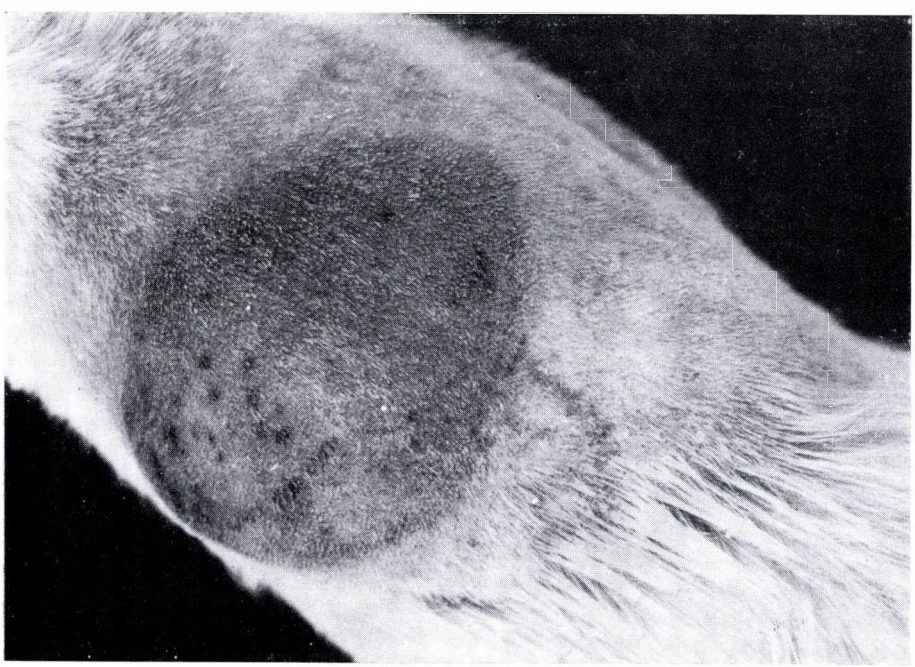

Fig. 5. Acute conditioned necrosis in rat, 24 hrs after its onset

Discussion

Reptilase, a thrombin and thrombokinase-like substance prepared from the venom of the snakes Bothrops jararaca and Lachesis atrox, is known to enhance thrombohaemorrhage, necrosis and calcification. In this view our findings point to the role of blood clotting in these reactions.

Although young rabbits (weighing 1000 to 1200 g) are the most susceptible in this respect, a generalized Shwartzman reaction cannot be elicited in every case by the usual method [11], whereas reptilase invariably provokes it even in adult rabbits. The reaction manifested itself with severe thrombohaemorrhagic and necrotic phenomena and the appearance of a Weigert and PAS-positive substance.

Thrombocytes play a decisive role in the generalized Shwartzman phenomenon [3, 5]; they are agglutinated by the endotoxin used for provoking the reaction [1]. Reptilase, too, agglutinates the thrombocytes [6] and in this way it presumably enhances the Shwartzman reaction or in rats, the thrombohaemorrhagic phenomena. Of course, owing to its thrombin-like action, reptilase promotes coagulation also directly which explains the enhancement of the thrombohaemorrhagic reaction.

Reptilase intensifies the mastocalcergic reaction; the thrombohaemorrhagic character was no longer marked when the experiment was evaluated. Thrombohaemorrhage obviously occurs at the onset of the injury and that time reptilase exerts its aggravating effect.

It is clear from the control experiments that reptilase in itself does not elicit the examined reactions but enhances them markedly once they have started. Reptilase had no effect on acute conditioned necrosis. This necrosis, in contrast to the mastocalcergic reaction and the thrombohaemorrhagic phenomena cannot be prevented by heparin pretreatment [9].

REFERENCES

1. Des Prez, R. M., Horowitz, H. I., Hook, E. W.: (1961) Effects of Bacterial Endotoxin on Rabbit Platelets. I. Platelet Aggregation and Release of Platelet Factors in vitro. J. exp. Med. **114,** 857. — 2. Endes, P.: (1954) Kombinált trichrom festés. Kísérl. Orvostud. **6,** 479. — 3. Horowitz, H. I., Des Prez, R. M., Hook, E. W.: (1962) Effects of Bacterial Endotoxin on Rabbit Platelets. II. Enhancement of Platelet Factor 3 Activity in vitro and in vivo. J. exp. Med. **116,** 619. — 4. Jancsó, N.: (1961) Inflammation and the Inflammatory Mechanisms. J. Pharm. Pharmacol. **13,** 577. — 5. McKay, D. G.: (1963) A Partial Synthesis of the Generalized Shwartzman Reaction. Fed. Proc. **22,** 1373. — 6. Morse, E. E., Jackson, D. P., Conley, C. L.: (1967) Effects of Reptilase and Thrombin on Human Blood Platelets and Observations on the Molecular Mechanism of Clot Retraction. J. Lab. clin. Med. **70,** 106. — 7. Selye, H.: (1966) Mast Cells and Necrosis. Science **152,** 1371. — 8. Selye, H., Caruso, P. L., Tuchweber, B.: (1965) Various Forms of Anaphylactoid Reaction Demonstrable by Mastocalcergy. Brit. J. exp. Path. **46,** 86. — 9. Selye, J., Somogyi, A., Végh, P.: (1967) Gyulladás és stress a pluricausalis betegségek koncepciójának megvilágításában. Orv. Hetil. **108,** 2449. — 10. Selye, H., Tuchweber, B., Rohan, P.: (1966) Metal-induced Sensitization for the Production of Different Types of Tissue Reactions by Adrenaline. Brit. J.

exp. Path. **47,** 281. — 11. SMITH, R. T., THOMAS, L.: (1954) Influence of Age upon Response to Meningococcal Endotoxin in Rabbits. Proc. Soc. exp. Biol. (N.Y.) **86,** 806. — 12. TÓTH, S., SZILÁGYI, T., KASSAY, L., BARZÓ, E.: (1967) The Effect of Haemocoagulase (Reptilase) on the Local Shwartzman Phenomenon. Acta microbiol. Acad. Sci. hung. **14**, 371.

DIE WIRKUNG DER REPTILASE AUF DIE THROMBOHAEMORRHAGISCHEN REAKTIONEN

S. TÓTH, G. LÉVAI und T. SZILÁGYI

Reptilasebehandlung führte an Kaninchen zum Auftreten und zur Intensivierung der generalisierten Schwartzman-Reaktion. Laut den Ergebnissen der histologischen Untersuchungen entstehen in den Nieren *aller* Kaninchen schwere thrombohaemorrhagische und nekrotische Veränderungen.

Im Rattenversuch verstärkte die Reptilasebehandlung ebenfalls die nach SELYE und Mitarbeitern hervorgerufene thrombohaemorrhagische Erscheinung bzw. die mastokalzergische Reaktion; dagegen übte sie keine Wirkung auf die akute konditionierte Nekrose aus.

Unsere Versuche ergeben weitere Angaben zur Bedeutung der Blutgerinnung bei den untersuchten Erscheinungen.

ДЕЙСТВИЕ РЕПТИЛАЗЫ НА ТРОМБОГЕМОРРАГИЧЕСКИЕ РЕАКЦИИ

Ш. ТОТ, Г. ЛЕВАИ и Т. СИЛАДЬИ

Введение рептилазы повышает у кроликов интенсивность и развитие генерализованной реакции Шварцмана. Согласно гистологическим исследованиям в почках *всех* кроликов возникают тяжелые тромбогеморрагические и некротические изменения.

В опытах на крысах после дачи рептилазы также наблюдалось усиление тромбогеморрагического явления или мастокальцергической реакции, вызванной по методу. Селье и сотрудников; в противоположность этому введение рептилазы не оказало действия на острый кондиционированный некроз.

Эксперименты авторов предоставляют новые данные о значении свертывания крови при изученных явлениях.

Dr. Sándor TÓTH
Dr. Géza LÉVAI
Dr. Tibor SZILÁGYI
Debrecen, Kórélettani Intézet, Hungary

Acta Morphologica Acad. Sci. Hung. 19 (2), pp. 131—139, 1971

Department of Medical Biology (Head: Prof. G. CSABA), Semmelweis University of Medicine, Budapest

DYNAMICS OF THE CORTISONE-EFFECT ON MAST CELL FORMATION

G. CSABA and L. HODINKA

(Received July 15, 1970)

A study has been made of the dynamics of the cortisone effect. Cortisone was found to exert both acute and prolonged effects. A single dose elicits synchronously a destruction and the formation of mast cells whereas later their destruction dominates at the periphery. This is followed by a regeneration in the lymphatic organs, but destruction of mature cells occurs even after 5 days. Prolonged treatment caused a similar destruction as a single dose but mast cell formation increased slowly. After cortisone treatment a large number of mast cells was found in the bone-marrow, showing the same reaction as those in the thymus and lymphatic organs.

There was a difference in behaviour between the peritoneal mast cells and those in tissues. Among the latter in the thymus and lymph nodes there occurred stem cells containing only biogenic monoamines while such cells were not found among the peritoneal ones. It is supposed that the formation of mast cells takes place only in the lymph organs and perhaps in the bone-marrow, and only a maturation of these cells occurs at the periphery. Upon the influence of strong stimuli, histamine appears in the epithelial structures of thymus, too.

Introduction

Cortisone is known to induce mast cell formation [13], to enhance the development of young mast cells in the lymphatic organs and their maturation at the periphery. The hormone causes at the same time a degranulation of mast cells [9]. These effects of cortisone have been noted after both acute and prolonged treatment [9], but it is not clear what a connection exists between the mast cell formation and destruction induced by cortisone and the dosage, the length of treatment and perhaps other factors. Similarly it is not clear whether these effects are similar or different in the organs of mast cell production and storage.

Experiments have therefore been performed to study the following questions.

1. How are correlated the effects of cortisone on the formation and destruction of mast cells?

2. Do the peritoneal and tissue mast cells react identically to cortisone?

3. How does the relation of heparin and biogenic amines change in the cortisone-induced tissue and peritoneal mast cells?

Material and methods

A) A total of 24 male, inbred Wistar CB rats of 200 g body weight were used. Half of them received a single intramuscular 10 or 5 mg per 100 g body weight dose of cortisone acetate (Adreson, Organon). Specimens were obtained 1, 3 and 5 days later from two animals each. The other group was treated with 5 mg per 100 g body weight of cortisone acetate three or six times and specimens were obtained 1, 3 and 5 days after the treatment from two animals each. The thymus, an axillary lymph node and a bone-marrow sample were fixed in cold absolute ethanol, embedded in paraffin and subjected to iron-alum alcian blue-safranin staining [10]; paraformaldehyde induction (P) according to FALCK [15] for the demonstration of serotonin fluorescence; orto-phthal-aldehyde induction (OPT) according to JUHLIN and SHELLEY [17] for the demonstration of histamine fluorescence. Furthermore, the abdominal cavity of the rats was washed with identical quantities of an isotonic solution of sodium citrate; from the washing fluid thick drops were prepared and stained with alcian blue-safranin.

B) In these experiments 10 male Wistar CB rats of 150—180 g body weight were used. Four animals served as controls while 6 rats were treated intramuscularly with 5 mg per 100 g body weight of cortisone acetate. Three of the animals were studied 24 hours after a single dose whereas the other three after three days treatment. Either the OPT or the P reaction was carried out first on the mast cell preparations described above. Pictures were taken from 20 fields of fluorescent preparations then they were stained with alcian blue-safranin. The corresponding areas were identified and the number of fluorescing and stained cells was compared.

Results

A/1. One day after a single 10 mg per 100 g body weight dose of cortisone a limited number of mast cells was in the thymus while they were abundant in the lymph node and the bone-marrow (Fig. 1). The great majority of the mast cells in the lymph node was alcian blue-positive, several forms of development could be found in the thymus, whereas in the bone-marrow there were only a few safranin-positive and mostly alcian blue-positive mast cells. Most of them were considerably damaged, disrupted. Many fluorescing cells were observed in the organs. Most of those in the thymus were found at the corticomedullary border. A number of peritoneal mast cells was found; few were degranulated but plenty of so-called "cadaver cells" [3] occurred (Fig. 2). The majority of cells seemed abnormal.

Three days after treatment, the number of mast cells was increased in the thymus (Fig. 3) while in the lymph node it decreased as compared to the situation observed after one day. A large amount of mast cells was observed in the bone marrow, practically all of them were damaged. A high number of mast cells was revealed by the OPT and P methods. Among the peritoneal mast cells many "cadaver cells" were seen, with a wide alcian blue-positive halo surrounding them (Fig. 4). Intact mast cells could not be found.

Five days after the treatment, few mast cells could be seen in the thymus, while they were numerous in the lymph node and a vast number of degranulated ones was present in the bone marrow. The fluorescence was of moderate intensity. The number of peritoneal mast cells was high and they were mostly undamaged.

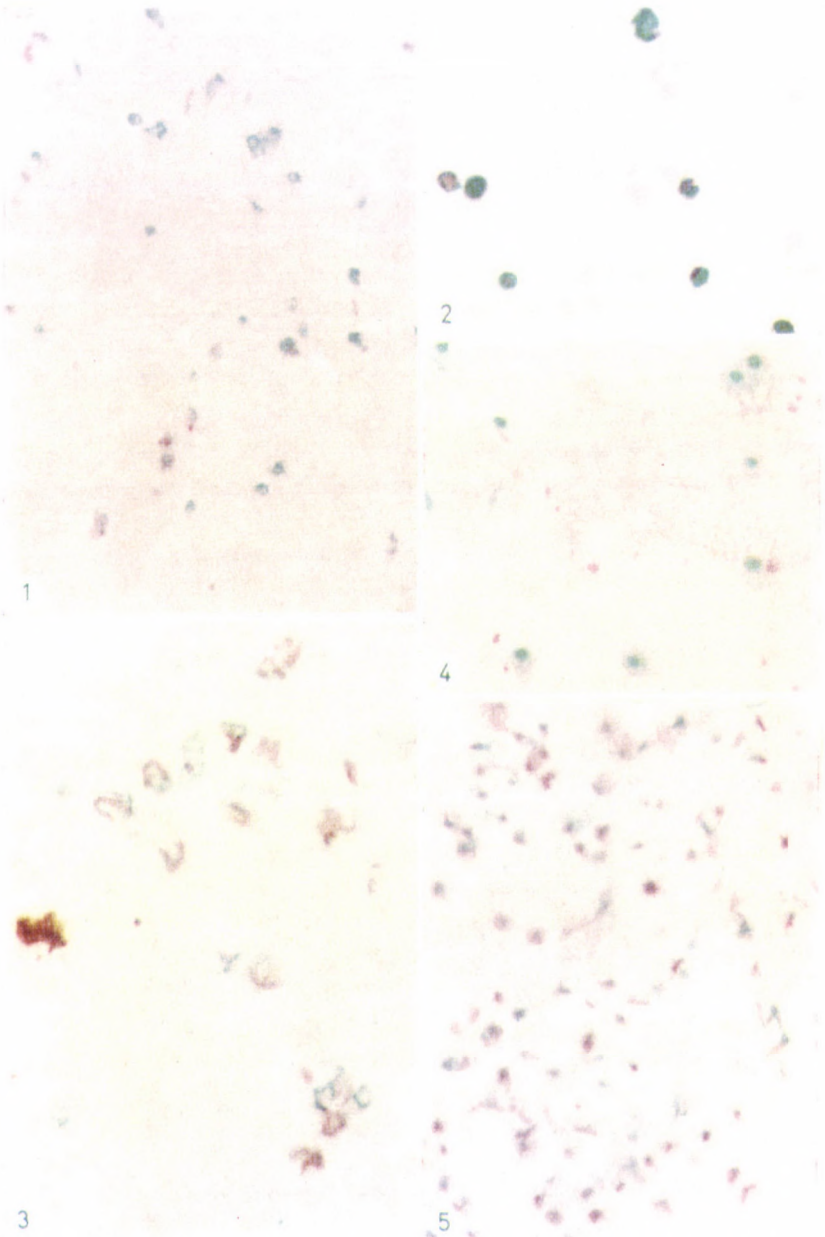

Fig. 1. Bone-marrow one day after a single 10 mg per 100 g body weight dose of cortisone. Mostly alcian blue-positive mast cells. Alcian blue-safranin, 25 × 10

Fig. 2. Peritoneal mast cells one day after a single 10 mg per 100 g body weight dose of cortisone. "Cadaver cells" and degranulating mast cells. Alcian blue-safranin, 25 × 10

Fig. 3. Numerous degranulating mast cells in the thymus, 3 days after a single 10 mg per 100 g body weight dose of cortisone. Alcian blue-safranin, 40 × 10

Fig. 4. Peritoneal mast cells, 3 days after a single 10 mg per 100 g body weight dose of cortisone. The alcian blue-positive cells are surrounded by an alcian blue-positive halo. Alcian blue-safranin, 25 × 10

Fig. 5. Bone-marrow overcrowded with mast cells, one day after a single 5 mg per 100 g body weight dose of cortisone. Alcian blue safranin, 25 × 10

A/2. One day after a single 5 mg per 100 g body weight dose of cortisone a limited number of mast cells was present in the thymus, hardly any were overcrowded with degranulated mast cell (Fig. 5). A great number showed OPT and P fluorescence in the thymus and lymph node (Fig. 6), their amount outnumbered that of stained cells. A large number of peritoneal mast cells occurred; they seemed to be intact.

Three days subsequent to the treatment, the number of mast cells decreased both in the organs and the peritoneal fluid. Almost every peritoneal cell showed an alcian blue-positive halo and they were of "cadaver" character. Few fluorescing cells were present in the thymus and the lymph node.

Five days after treatment the organs contained few mast cells and there occurred only alcian blue-positive ones in the bone marrow. They were partly degranulated. Similarly, a few of them were revealed by the fluorescence method. The peritoneal mast cells were not degranulated but they were not entirely normal.

A/3. One day after the three times repeated administration of 5 mg per 100 g body weight of cortisone a limited number of mast cells occurred in the organs and peritoneal fluid, and they were mostly degranulated, and few of them displayed fluorescence.

Three days after treatment, both the organs and the peritoneal fluid contained many mast cells. They did not seem normal, and plenty "cadaver cells" occurred. Cytoplasmatic granulation as well as degranulation were frequent, fluorescing cells were few.

Five days subsequent to the last treatment, a medium amount of degranulated mast cells were surrounded by an alcian blue-positive halo. The number of fluorescing cells corresponded to that of stained ones.

A/4. One day following the six time repeated administration of 5 mg per 100 g body weight of cortisone a vast number of mast cells was found in both the organs and the peritoneal fluid. Many of them were degranulated, the amount of fluorescing cells was identical with that of stained ones.

Three days subsequent to treatment, the number of mast cells was high in both the organs and the peritoneal fluid, but their incidence was lower than one day after treatment. The cells were degranulated, except those of the peritoneal fluid which seemed intact, but stained mainly with alcian blue. The amount of fluorescing cells corresponded to that of stained ones.

Five days after the last treatment, many mast cells were observed in both the organs and the peritoneal fluid. There were numerous safranin-positive forms among the mast cells of the bone-marrow and the peritoneum. Many fluorescing cells could be seen in the thymus (Fig. 7), the cells lining the cysts showed OPT fluorescence (Fig. 8).

B) Among the 286 mast cells taken from controls and animals treated with cortisone for 1 or 3 days, not a single cell was found to contain only one

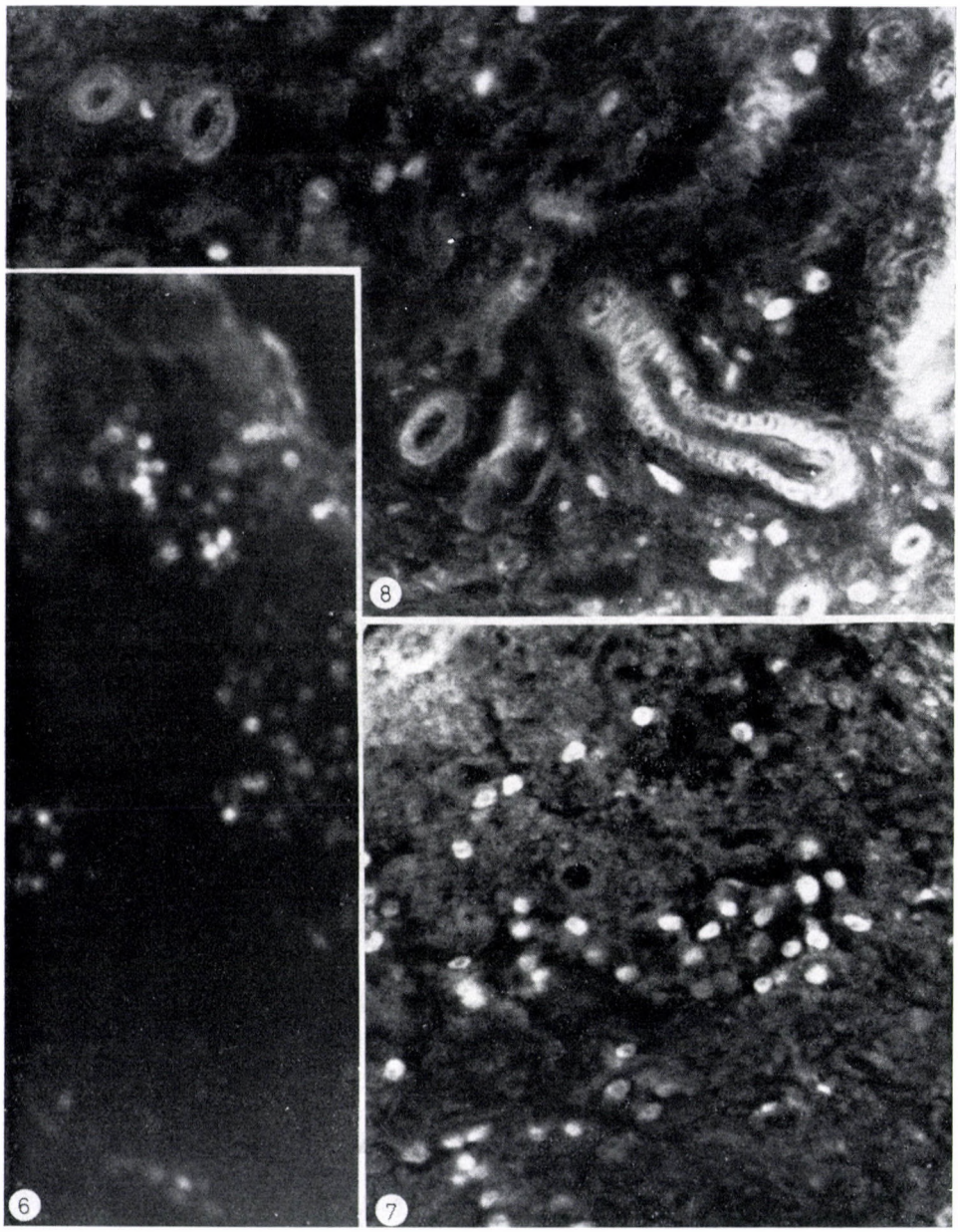

Fig. 6. Strongly fluorescing lymphoid cells in a lymph node, 3 days after a 5 mg per 100 g body weight dose of cortisone. Fluorescence is localized in the cytoplasm, the area of the nucleus shows no flurescence. One hour paraformaldehyde induction, 25 × 10

Fig. 7. Large number of mast cells in the thymus 5 days after a six times repeated 5 mg per 100 g body weight dose of cortisone. OPT reaction, 25 × 10

Fig. 8. Fluorescing epithelial lining cells surrounded by mast cells in the thymus, 5 days after a six times repeated 5 mg per 100 g body weight dose of cortisone. OPT reaction, 25 × 10

component. All the cells contained biogenic amines and heparin. The cells of the cortisone-treated animals were similar in this respect. Results are summarized in Table I.

Table I

Number of cells containing serotonin, histamine and heparin

	Control	Cortisone		Sum total
		1 day	3 days	
Histamine + Heparin —	0	0	0	0
Histamine + Heparin +	45	52	47	144
Histamine — Heparin +	0	0	0	0
Serotonin + Heparin —	0	0	0	0
Serotonin + Heparin +	39	55	48	142
Serotonin — Heparin +	0	0	0	0

Discussion

A number of papers [22] discussed the effect of cortisone on the mast cells. Without supposing the inductive role of cortisone in mast cell formation, it has been stated that the number of mast cells increases [21] or decreases [1, 2, 4] under the influence of cortisone, or the hormone is indifferent in this respect [14, 18, 23, 24]. Thus the possibility arose that cortisone might have manifold effect on the mast cells, the more so as our earlier experiments [8, 9, 13] where the inductive effect of cortisone in the mast cell formation has been observed, its destructive, degranulating effect has also been recorded.

The present findings, although they did not solve the problem, throwed some light on the dynamics of the cortisone effect. Thus, cortisone proved to have both acute and prolonged effects on the mast cells. Twenty-four hours after the single cortisone treatment, there was a great number of degranulated, and decomposed mast cells, while there also appeared newly formed cells. Comparing this fact with our earlier results [7] demonstrating that glucocorticoids are increasing the number of mast cells after a few minutes and cause a degranulation, one can conclude that the constructive and destructive effects

of cortisone start almost synchronously. Mast cell formation in the lymphatic organs was intense after 3 days, whereas in the peritoneum the destruction dominated. Five days after a single dose, the destructive effect still persisted while the formation of new cells was expressed. On the basis of these observations one may assume that immediately after cortisone administration the drug accelerates the development of suitable intact cells and after an exhaustion of the cell pool, the destruction of mast cells will dominate. Later, on the third day, again new cells become suitable for mast cell transformation and regeneration of the stores begins from them.

After the prolonged cortisone treatment, the destruction did not seem to be more intense than after a single dose, indicating a strong effect of cortisone on the mast cells. The formation of new cells gradually increased and reached a maximum on the fifth day. At the same time, histamine fluorescence was observed in the epithelial elements of the thymus, demonstrating the ability of the entodermal epithelium of this organ to produce biogenic amines. The cells of almost every entodermal endocrine gland contained serotonin [5, 16, 19, 20] but this was not shown in the thymus. The phenomenon allowed to assume that the formation of biogenic monoamines should be considered a general capacity of the entodermal cells, manifesting itself in the thymus only under the influence of extreme inductive effects.

The bone-marrow may contain a vast number of mast cells in special situations such as after cortisone treatment. The presence of mast cells in the bone-marrow of rats has not been proved unequivocally [22]. On the basis of our findings it may be stated that mast cells are present in the bone marrow and the changes of the mast cell reactions run parallel with those of the lymphatic organs. It seems likely that the presence of mast cells in the rat's bone marrow has remained unrecognized owing to technical reasons, *viz.* the majority of the cells is alcian blue-positive, failing thus to be stained with basic dyes at an acid pH.

Quantitative conclusions cannot be drawn from our findings. Thus, we could not decide the significance of the great number of mast cells in the bone-marrow during the regeneration subsequent to cortisone treatment (see group A/4 at 5 days). It is possible that the stem cells arrive from the thymus in the bone-marrow or vice versa. Further investigations are needed to decide this question.

It seemed from our findings that the peritoneal mast cells and those of tissues behave differently. Disintegration and disruption of tissue mast cells were of a higher degree and varied more in time than that of the peritoneal ones. This may have been the consequence of the different techniques applied in the case of tissues and of the thick smears. However, if this is not the case, one has to suppose the peritoneal mast cells to be more resistant than those of tissues.

The difference between the two kinds of mast cell appeared also in the ratio of amines to heparin. It has been shown earlier [9] that while cortisone increases the destruction of mast cells at the periphery, new cells are formed in the thymus and lymph nodes. Our present findings showed that cells containing biogenic amines without heparin did not occur at the periphery, whereas they were present in the lymphatic organs. This allowed to assume that, as a result of the biogenic amine effect [11] heparin synthesis started in the lymphatic organs and by the time the cells are arriving to the periphery, perhaps through the blood stream [12], even the youngest forms contain all three components of the granules. This supports the assumption that under normal circumstances mast cell formation does not take place at the periphery, where only the maturation of the youngest, lymphoid forms occurs.

REFERENCES

1. ASBOE-HANSEN, G.: (1952) The Mast Cell. Cortisone Action on Connective Tissue. Proc. Soc. exp. Biol. (N. Y.) **80,** 677. — 2. ASBOE-HANSEN, G.: (1957) On the Structure and Functions of the Mast Cells. In: Connective Tissue. Ed.: R. E. Tunbridge, Blackwell, Oxford. — 3. BURTON, A. L.: (1963) Studies on Living Normal Mast Cells. Ann. N. Y. Acad. Sci. **103.** 245. — 4. CAVALLERO, C., BRACCINI, C.: (1952) Effect of Cortisone on the Mast Cells of the Rat. Proc. Soc. exp. Biol. (N. Y.) **78,** 141. — 5. CEGRELL, L.: (1968) The Occurrence of Biogenic Monoamines in the Mammalian Endocrine Pancreas. Acta physiol. scand. Suppl. 314. — 6. CRONBERG, S.: (1961) The Effect of Hydrocortisone on the Mast Cells in the Peritoneal Fluid and Mesentery of the Rat. Acta chem. scand. **7,** 156. — 7. CSABA, G., KULLMANN, L.: (1963) On the Physiological Control of Connective Tissue Mast Cells. Acta biol. Acad. Sci. hung. **14,** 8. 175. — 8. CSABA, G., DUNAY, C., OLÁH, I., TÖRŐ, I.: (1967) Effect of Glucocorticoids on the Thymus I. Histochemical and Electronmicroscopic Investigations of Mast Cell Formation. Acta biol. Acad. Sci. hung. **18,** 345. — 9. CSABA, G., SURJÁN, L. JR., FISCHER, J., TÖRŐ, I. JR.: (1969) On the Mechanism of Mast Cell Formation I. Effect of Glucocorticoids on the Mast Cells of Normal and Thymectomized Rats. Acta Biol. hung. **20,** 57. — 10. CSABA. G.: (1969) Mechanism of the Formation of Mast Cell Granules. II. Cell-free Model. Acta biol. Acad. Sci. hung. **20.** 205. — 11. CSABA. G.: (1969) Mechanism of the Formation of Mast Cell Granules III. Self-regulating System of Granule Formation. Acta biol. Acad. Sci. hung. **20,** 211. — 12. CSABA, G., HODINKA, L., SURJÁN, L. JR.: (1969) Transport of Mast Cells by the Blood Circulation. Experientia. (Basel) **25,** 735. — 13. CSABA, G. KISS, J., OLÁH, I.: (1970) Mechanism of the Formation of Mast Cell Granules. IV. Electronmicroscope Autoradiographic Experiments with ^{3}H Hydrocortisone. Acta biol. Acad. Sci. hung. **21,** 85. — 14. DEVITT, J. E. PIROZYNSKY, W. J., SAMUELS, P. B.: (1953) Mast Cell Resistance to Hormonal Influence. Proc. Soc. exp. Biol. (N. Y.) **83,** 335. — 15. FALCK B.: (1962) Observations on the Possibilities of the Cellular Localization of Monoamines by a Fluorescence Method. Acta phys. scand. Suppl. 197. — 16. FALCK, B., LARSON, B., MECKLENBURG, C., v. ROSENGREN, E., SVENSAEUS, K.: (1964) On the Presence of a Second Specific Cell System in Mammalian Thyroid Gland. Acta physiol. scand. **62,** 491. — 17. JUHLIN, L., SHELLEY, W. B.: (1966) Detection of Histamine by a new Fluorescent O-phtolaldehyde stain. J. Histochem. Cytochem. **14,** 525. —18. PADAWER, J., GORDON, A. S.: (1956) Endocrine Influence on the Mast Cells of the Rat. Anat. Rec. **124,** 659. — 19. PEARSE, A. G. E.: (1966) 5-hydroxytryptophan Uptake by Dog Thyroid "C" Cells, and its Possible Significance in Polypeptide Hormone Production. Nature (Lond.) **211,** 598. — 20. PEARSE, A. G. E.: (1969) The Cytochemistry and Ultrastructure of Polypeptide Hormone-Producing Cells of the APUD Series and the Embryologic, Physiologic and Pathologic Implications of the Concepts. J. Histochem. Cytochem. **17,** 303. — 21. ROMANI, J. C.: (1953) L'influence de la cortisone sur les mastocytes du tissu conjonctif et de quelques organes chez le rat. C. R. Soc. Biol. (Paris) **147,** 391. — 22. SELYE, H.: (1965) The Mast Cells. Butterworth, Washington, D. C. — 23. SMITH, D. E., LEWIS, Y. S.: (1954) Influence of Hypophysis and Adrenal Cortex Upon Tissue Mast Cell of the Rat. Proc. Soc. exp. Biol. (N. Y.) **87,** 515. — 24. SPEIRS, R. S., WENCK, V.: (1957) Effect of Cortisone on the Cellular Response During Allergic Inflammation. Acta haemat. (Basel) **17,** 271.

DYNAMIK DER KORTISONWIRKUNG BEI DER BILDUNG DER MASTZELLEN

G. CSABA und L. HODINKA

Bei der Untersuchung der Dynamik der Kortisonwirkung stellten die Verfasser im Laufe ihrer Untersuchungen fest, daß die Kortisonwirkung gleichzeitig akut und dauerhaft ist. Eine einmalige Kortisondosis induziert gleichzeitig die Destruktion und die Bildung von Mastzellen, später tritt an der Peripherie die Destruktion in den Vordergrund, welcher in den lymphoiden Organen die Regeneration folgt, aber die Destruktion der reifen Zellen dauert auch noch dann (nach fünf Tagen) an. Im Falle prolongierter Behandlung ist die Destruktion nicht größer, als nach einmaliger Dosis, aber die Zellbildung verstärkt sich nur langsam. Im Knochenmark ist nach Kortisonbehandlung eine große Menge von Mastzellen zu finden und ihre Reaktion ist mit jener der im Thymus und in den lymphatischen Organen befindlichen Mastzellen identisch.

Zwischen dem Benehmen der Mastzellen der Gewebe und des Bauchfells besteht ein Unterschied. In den Mastzellen in den Geweben (im Thymus, in den Lymphknoten) kommen auch nur biogene Amine enthaltende Urzellen vor, während das zwischen den peritonealen Mastzellen nicht der Fall ist. Verfasser nehmen an, daß die Bildung der Mastzellen nur in den lymphatischen Organen — vielleicht im Knochenmark — vor sich gehen und daß dann an der Peripherie nur die weitere Reifung dieser Zellen geschieht. Auf Einwirkung eines sehr starken Reizes erscheint auch in den Epithelialgebilden des Thymus Histamin.

ДИНАМИКА ДЕЙСТВИЯ КОРТИЗОНА НА ОБРАЗОВАНИЕ ТУЧНЫХ КЛЕТОК

Д. ЧАБА и Л. ХОДИНКА

При изучении динамики действия кортизона авторами было установлено, что гормон оказывает равным образом как острое, так и прочное действие. Разовая доза кортизона вызывает деструкцию и образование тучных клеток одновременно, а затем на периферии получает перевес деструкция, после чего в лимфоидных органах происходит регенерация. Однако деструкция зрелых клеток продолжается и в этой фазе (после пяти дней). В случае длительной дачи кортизона деструкция не превышает разрушения, наблюдаемого под влиянием разовой дозы, однако образование клеток повышается только медленно. В костном мозгу после введения кортизона обнаруживается большая масса тучных клеток, причем их реакция подобна реакции тучных клеток, находящихся в зобной железе и в лимфатических органах.

Между поведением тканевых и перитонеальных тучных клеток наблюдается разница. В тканевых тучных (в клетках зобной железы, в лимфатических узлах) обнаруживаются также первобытные клетки, содержащие только биогенные амины, в то время как среди перитонеальных тучных клеток нет таких клеток. Авторы полагают, что образование тучных клеток осуществляется только в лимфатических органах — возможно еще и в костном мозгу — и что на периферии происходит лишь дальнейшее созревание этих клеток. Под влиянием очень сильного раздражения в эпителиальных образованиях зобной железы появляется также гистамин.

Dr. György CSABA
Dr. László HODINKA
Budapest IX., Tűzoltó u. 58, Hungary

Acta Morphologica Acad. Sci. Hung. 19 (2), pp. 141—149, 1971

Institute of Histology and Embryology (Director: Prof. I. Törő), Semmelweis University Medical School

STUDIES ON THE ORGANON VASCULOSUM LAMINAE TERMINALIS

III. VASCULARIZATION OF THE ORGANON VASCULOSUM LAMINAE TERMINALIS IN THE RAT

T. Wenger and B. Aros

(Received July 30, 1970)

The vascular apparatus in the organon vasculosum laminae terminalis (OVLT) of the rat has been studied by means of Indian ink injection. As in numerous vertebrates, the OVLT of the rat has a particularly characteristic vascular network. Its vessels form multiple anastomoses, are wider than those of the adjacent organs, and run tortuous courses. The OVLT receives its vessels from the preoptic artery which form a uniform system of anastomoses. The whole plexus is shaped like a truncated cone whose base faces the ependyma. The vessels do not reach the lumen of the third ventricle, nor do they protrude between the ependymal cells. The efferent vessels are thinner and run partly to the anterior commissure and partly to the optic chiasma. A number of other vessels, running in the lamina terminalis towards the anterior commissure, are likewise emitted by the preoptic artery; they fork off at the level of the OVLT and do not communicate at its height with the vessels of this organ.

Theories regarding the function of the OVLT are still speculative and require further investigation.

The anterior part of the third cerebral ventricle is constituted by the lamine terminalis in which there is a characteristic vascular and cellular pattern in the area above and in front of the optic chiasma. It has been termed organon vasculosum laminae terminalis (to be called OVLT in the following) by Hofer [6] and Mergner [8]. Since the OVLT is morphologically similar to the subfornical organ and the area postrema, Hofer classified it also as a circumventricular organ.

Literature contains several papers on the vascularization of the OVLT. Duvernoy and Koritké [1, 2, 3, 5], having studied its vascular structure in numerous vertebrates, found that — although more or less different in the various species — it was nevertheless typical and closely similar to the vascular apparatus of the area postrema and the subfornical organ.

There are several reports on the light- and electron-microscopic structure of the organ [6, 8, 12, 15] which was found to be present in every vertebrate. Since the available literature did not seem to contain data in respect of the albino rat, a study has been made of the vascular pattern of the OVLT in the rat.

Material and method*

Ten laboratory male albino rats (Rattus norvegicus) with body weights from 150 to 200 g were anaesthetized with ether and injected with 4- and 8-fold diluted Indian ink through

* The authors are indebted to Prof. J. G. Koritké for assistance in the use of the method described.

the initial se ment of the aorta. Gelatin was added to the diluted Indian ink at the ratio 2—3 g/100 ml, and the fluid was administered at body temperature. The brain was removed and fixed in 4 and 10% solutions of formalin; some brains embedded in paraffin, and then serially sectioned in the horizontal and the sagittal plane to thicknesses of 10, 100 and 180 micra. Other brains were treated according to SPALTEHOLZ (v. ROMEIS [11]). Some sections were stained with haematoxylin-eosin, others left unstained.

We compared the OVLT of each animal with its own subfornical organ and median eminence.

Results

Examination of the vascular structure was investigated with the knowledge of the light- and electron-microscopic picture of the OVLT. By this the organ of the rat consists of an outer and an inner part. The outer part, abutting on the preoptic cistern, contains a few vessels surrounded by a wide perivascular space in which collagen fibres and connective tissue cells are observed. The external area contains moreover nerve and glial fibres. The inner area is separated from the third ventricle by the ependyma which is stratified in the area of the OVLT. There are numerous capillaries below; these, too, are surrounded by perivascular zones and are narrower than their counterparts in the outer area. Also a few so-called parenchymal cells are visible. The nerve fibres contain many dense-core granules.

The OVLT receives its vessels from the initial segment of the preoptic artery (Figs 1, 6), a branch of the anterior cerebral artery, originating from the main trunk above the optic chiasma [3, 8]. The vessels are running along approximately horizontal courses. They enter the lamina terminalis without emitting branches and ramify into capillaries after a short path (Fig. 2) along which they do not form anastomoses (Fig. 6). A plexus of anastomosing wide capillaries is formed immediately beneath the pia mater which extends as far as the ependymal cells (Figs 2, 3). This anastomotic structure resembles a vascular glomerulus in the shape of a truncated cone whose base confronts the ependymal cells. No vessels were observed between the ependymal cells, in the interior of the ventricle or on the apical surface of the ependyma. Vessels were dilated along certain segments (Fig. 4). Dilatations were especially marked at the points of anastomoses. As many as four or five vessels converge to some of these points, a phenomenon which turns the entire plexus into a sort of labyrinth.

It was obvious from the sections (Fig. 5) that the vessels of the OVLT were more closely packed and their anastomoses much more abundant than those of the adjacent hypothalamic areas.

In the lower and upper part of the glomerular structure the vessels of the OVLT unit to form capillaries whose lumina are narrower than those of the anastomosing vessels. Some of the capillaries run towards the optic chiasma, others to the anterior commissure (Figs 5, 6). There are two or three of the latter: after a long course they reach the anterior commissure and disappear

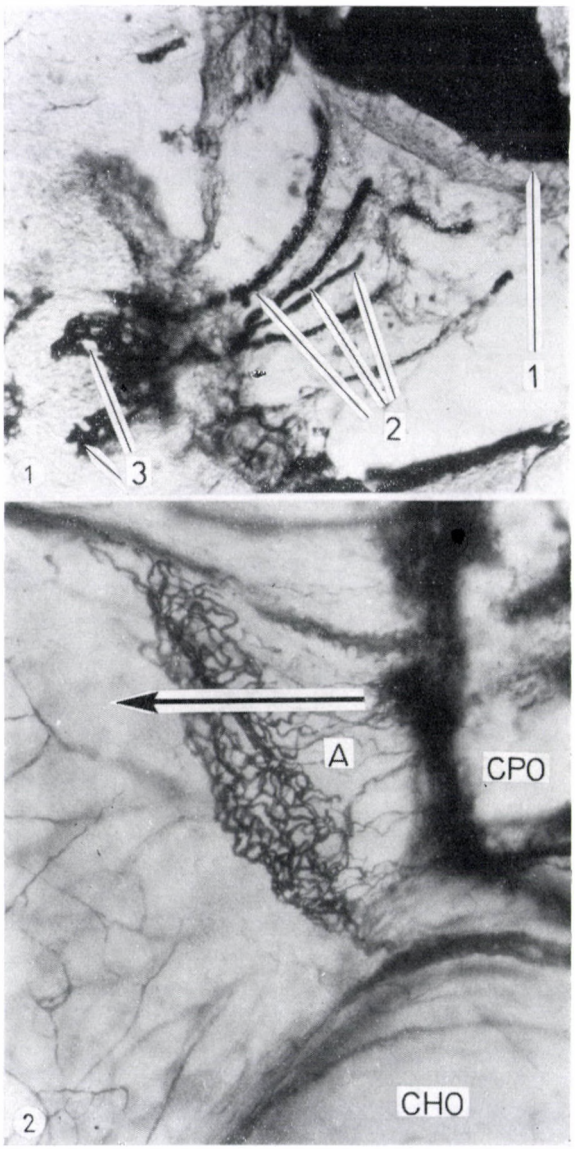

Fig. 1. Horizontal section of the preoptic cistern at the level of the OVLT. Arising from the preoptic artery (1), three or four vessels are running horizontally (2) through the cistern to the lamina terminalis (3) to ramify there. 100 micra; × 16

Fig. 2. Sagittal section showing the vascular structure of the OVLT. After a short segment at the outside of the OVLT (A), a rich plexus of anastomoses is formed. Note the comparative tenuity and scarcity of vessels in the adjacent areas. CPO = preoptic cistern; CHO = optic chiasma. Arrow points to lumen of ventricle. 100 micra; × 40

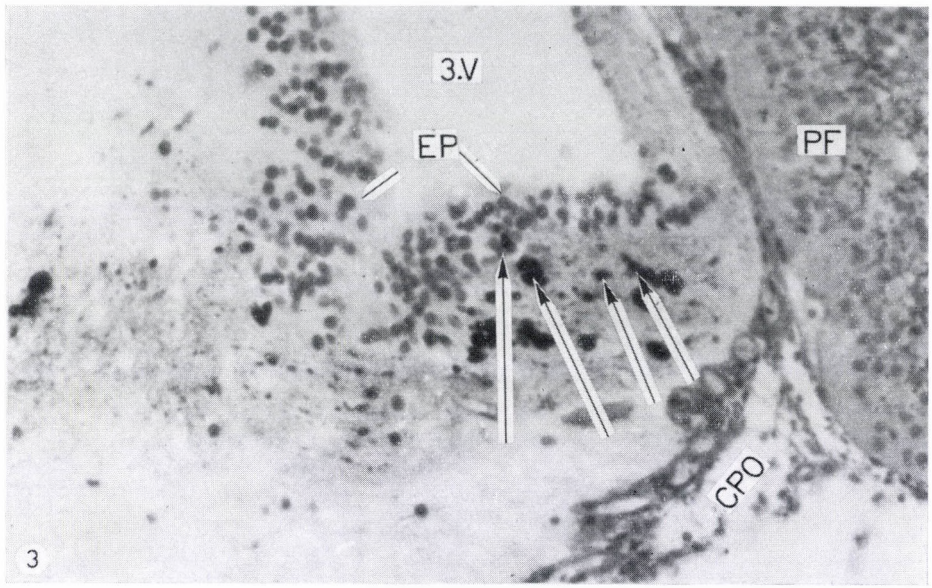

Fig. 3. Parasagittal section of OVLT. Arrows point to vessels filled with Indian ink. They do not reach the lumen of the ventricle. 3 V = third ventricle; EP = ependyma of OVLT; CPO = preoptic cistern; PF = frontal lobe. 15 micra; haematoxylin-eosin, × 60

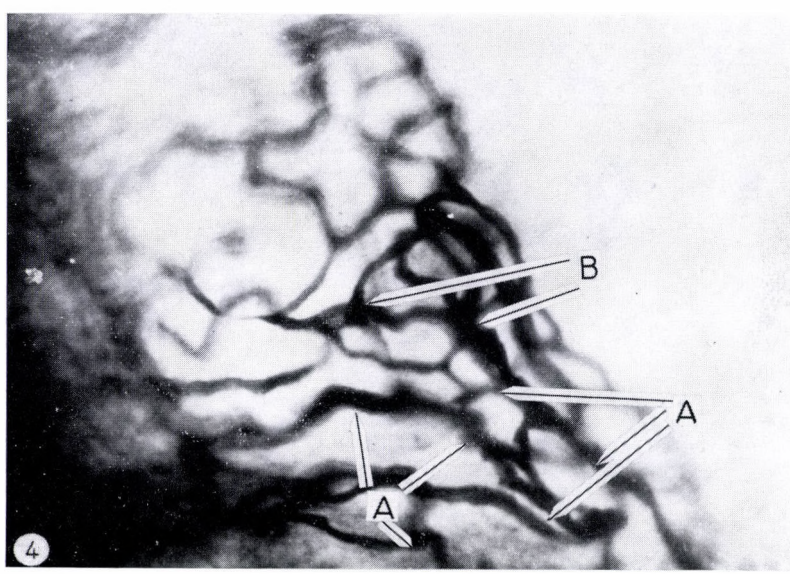

Fig. 4. Vascular pattern of OVLT. Note dilatations (A) and multiple anastomoses (B). 120 micra; × 160

there. They probably empty into the pericommissural vascular plexus. The vessels running towards the optic chiasma pierce the surface of the brain and empty into the preoptic vein together with other vessels. We observed no

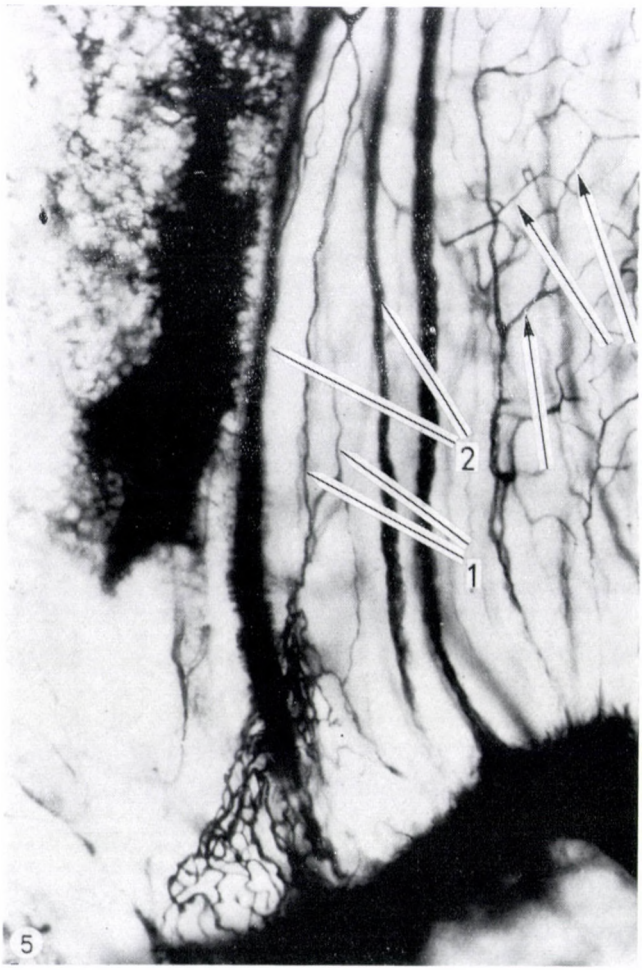

Fig. 5. Parasagittal section showing part of the OVLT and the lamina terminalis. Vessels arising from the vascular bed of the OVLT, run toward the anterior commissure (1). System of thicker vessels running parallel to the former (2). Arrows point to capillaries of a different character in the adjacent parts of the brain. 120 micra, × 25

direct communication between the vessels of the OVLT and those of the subfornical area, nor did we find connections between the vessels of the OVLT and the median eminence. The vascular pattern of these two areas was strikingly similar, whereas the vascular similarity between the OVLT and the subfornical organ appeared to be less pronounced.

Another vascular system encountered in the area of the OVLT originates directly from the preoptic artery, enters the lamina terminals at the level of the OVLT and runs steeply upward to the anterior commissure (Figs 5, 6). These vessels are wider than those running to the OVLT and do not communicate with them at the level of the organ.

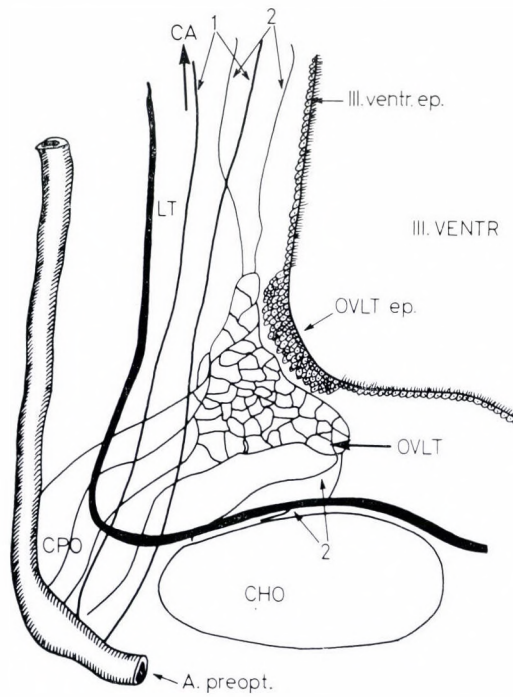

Fig. 6. Schematic illustration of lamina terminalis in the sagittal plane at the level of the OVLT. The preoptic artery sends direct branches to the OVLT; they run in the outer part of the OVLT to form a plexus of multiple anastomoses. Vessels lead from this capillary system to the anterior commissure (CA) and the optic chiasma (CHO) (2). Arrow points to the direction in which vessels of the lamina terminalis travel towards the anterior commissure. These vessels arise from the preoptic artery at the level of the vessels of the OVLT (1). LT = lamina terminalis; III VENTR = third ventricle of the brain; CPO = preoptic cistern; III ventr. ep. = = normal ventricular ependyma; OVLT ep. = ependyma of OVLT

Discussion

The characteristic vascular pattern of the OVLT (dilatation, intricate anastomoses, tortuous course, thin efferent vessels) was unmistakably clear in every animal. The picture of the organ and its surroundings was pratically identical in all cases.

Our observation that the vessels of the OVLT are wider than those of the adjacent areas agrees with the findings of Duvernoy and Koritké [3].

The dilatations described by them [5] in humans were clearly visible in the rats, too, Like the vascular configuration of all circumventricular organs, that of the OVLT is also remarkably different from the vascular pattern of the adjacent hypothalamic and telencephalic areas, a phenomenon giving support to the contention of HOFER and MERGNER [6, 8, 9] that the OVLT is a circumventricular organ.

WEINDL et al. [13] mention vessels which project into the lumen of the third ventricle. We have failed to note this, nor did we find vessels between the ependymal cells. This agrees with our earlier observation that a direct communication between the ependymal cells and the vessels is possible only if the basement membrane of the perivascular area is in contact with the ependyma feet [14].

The efferent vessels of the OVLT are narrower than those which constitute the anastomotic network. The morphological pattern shows a similarity to the portal system, as already noted by MONNIER [10] in humans. The idea that one is dealing here with a kind of portal system is supported by the fact that the capillaries of the OVLT are similar to those of the pituitary portal apparatus [4]. Wider anastomosing and narrowed efferent vessels point to special conditions of pressure which must, of course, entail functional consequences. The area is unfortunately so hidden and its afferent system so ramified that OVLT, based on its structure, are more or less speculative. Whether as a shunt or as an anastomosis, it may play some role in breaking through the barrier between blood and cerebrospinal fluid. This supposition is confirmed by the fact that, in the rat, only a few ependymal cells separate the vessels or rather the perivascular space from the lumen of the ventricle.

It is, on the other hand, possible that the OVLT is involved in the process of neuro-humoral regulation, a theory advanced by us on the basis of previous findings. Structurally, the vessels of the OVLT are similar to those of the pituitary portal system. Numerous nerve fibres with dense-core vesicles were observed in the vicinity of the vessels. Some vessels in the rat are lined by fenestrated endothelium. This, in combination with the vascular arrangement, justifies the assumption that the OVLT is involved in neuro-humoral regulation, but this assumption will have to be tested thoroughly.

REFERENCES

1. DUVERNOY, H., KORITKÉ, J. G.: (1962) Sur l'architecture vasculaire de la lame terminale chez les oiseaux. (Paris) R. C. Acad. Sci. **255,** 567. — 2. DUVERNOY, H., KORITKÉ, J. G.: (1963) L'angioarchitectonie comparée de l'organe vasculaire de la lame terminale chez les oiseaux. Acta anat. (Basel) 54, 354. — 3. DUVERNOY, H., KORITKÉ, J. G.: (1964) Contribution à l'étude de l'angioarchitectonie des organes circumventriculaires. Arch. Biol. (Liège) **75,** suppl. 849. — 4. DUVERNOY, H., KORITKÉ, J. G.: (1968) Les vaisseaux sous-épendymaires du recessus hypophysaire. Z. Hirnforsch. **10,** 227. — 5. DUVERNOY, H., KORITKÉ, J. G., MON-

NIER, G.: (1969) Sur la vascularisation de la lame terminale humaine. Z. Zellforsch. **102,** 49. — 6. HOFER, H.: (1958) Zur Morphologie der circumventriculären Organe des Zwischenhirns der Säugetiere. Verh. dtsch. zool. Ges. Frankfurt, pp. 202—251. — 7. MELLINGER, J.: (1964) Les relations neuro-glandulaires dans l'appareil hypothalamo-hypophysaire de la rousette, Scyliorchinus caniculus (L.). Arch. Anat. (Strasbourg) **47,** 1. — 8. MERGNER, H.: (1959) Untersuchungen am Organon vasculosum laminae terminalis (Crista supraoptica) im Gehirn einiger Nagetiere. Zool. Jb. Abt. Anat. Ontog. **77,** 290. — 9. MERGNER, H.: (1961) Die Blutversorgung der Lamina terminalis bei einigen Affen. Z. Zool. **165,** 140. — 10. MONNIER, G.: (1968) Sur la vascularisation de la lame terminale de l'encéphale chez l'homme. These, Besancon. — 11. ROMEIS, B.: Mikroskopische Technik. Leibniz, München 1948. — 12. RÖHLICH, P., WENGER, T.: (1969) Elektronenmikroskopische Untersuchungen am Organon vasculosum laminae terminalis der Ratte. Z. Zellforsch. **102,** 483. — 13. WEINDL, A., SCHWINK, A., WETZSTEIN, R.: (1967) Der Feinbau des Gefäßorgans der Lamina terminalis beim Kaninchen. I. Die Gefäße. Z. Zellforsch. **79,** 1. — 14. WENGER, T., RÖHLICH, P.: (1969) Electronmicroscopical Investigation of the Organon vasculosum laminae terminalis in the Rat and in the Rhesus Monkey. In: Circumventricular Organs and Liquor. Ed. G. Sterba. Fischer, Jena 1969. Pp. 167—171. — 15. WENGER, T., TÖRK, I.: (1968) Studies on the Organon vasculosum laminae terminalis. II. Comparative Morphology of the Organon vasculosum laminae terminalis of Fishes, Amphibia, Reptilia, Birds and Mammals. Acta biol. Acad. Sci. hung. **19,** 82.

UNTERSUCHUNGEN AM ORGANON VASCULOSUM LAMINAE TERMINALIS

III. Vaskularisation des Organon vasculosum laminae terminalis von Ratten

T. WENGER und B. AROS

Verfasser untersuchten mittels Tuschinjektionsmethode das Gefäßnetz der Lamina terminalis des Organon vasculosum (OVLT). Die OVLT besitzt auch bei Ratten, wie bei vielen anderen Wirbeltieren ein charackteristisches Gefäßnetz: die Gefäße geben untereinander vielfache Anastomosen, sind weiter als die in der umgebenden Hirnsubstanz befindlichen Gefäße und besitzen einen gewundenen Verlauf. Die OVLT erhält die Gefäße von der A. praeoptica. Auf dem Gebiete des Organs bilden die Gefäße ein einheitliches Anastomosensystem. Das ist ein mit seiner Basis auf das basale Ende der Ependyma gerichteter Pyramidalstutz. Die Gefäße erreichen nicht das Lumen der III. Hirnkammer und erstrecken sich nicht zwischen die Ependymazellen. Der Abfluß der OVLT-Gefäße geht in zwei Richtungen vor sich. Einerseits in Richtung der Commissura anterior, anderseits gehen die dünneren abführenden Gefäße in Richtung des Chiasma opticum. Von der A. praeoptica zweigen in der Höhe der OVLT die in der Lamina terminalis zur Commissura anterior verlaufenden Gefäße, welche in der Höhe des Organs nicht mit dessen Gefäßen in Verbindung kommen.

Wir besprachen aufgrund des morphologischen Bildes auch die vorstellbare Rolle des Organs. Die Funktion ist aber aufgrund der bisherigen Untersuchungen noch nicht vollständig klärbar.

ИЗУЧЕНИЕ ТЕРМИНАЛЬНЫХ ПЛАСТИНОК СОСУДИСТОГО ОРГАНА

III. Васкуляризация терминальной пластинки сосудистого органа крысы

Т. ВЕНГЕР и Б. АРОШ

Методом иньекции туши была изучена васкуляризация терминальной пластинки сосудистого органа. Она обладает у крысы, точно так же как и у многочисленных видов позвоночных, характерной сосудистой сетью: сосуды образуют многократные анастомозы друг с другом, они более широкие чем сосуды окружающего вещества головного мозга и имеют извилистый ход. Терминальная пластинка сосудистого органа получает сосуды из предзрительной артерии. На территории органа сосуды образуют единую систему анастомозов. Форма этой системы напоминает отсеченный конус, основание которого обращено к базальному концу эпендимы. Сосуды не достигают просвета III-го желудочка и не проникают среди эпендимальные клетки. Отведение сосудов терминальной пластинки сосуди-

стого органа имеет два направления. Отводящие сосуды, которые более тонкие чем сосуды органа, идут, с одной стороны, к передней спайке, а с другой — к перекресту зрительных нервов. Также от предзрительной артерии ответвляются на уровне терминальной пластинки сосудистого органа сосуды, идущие в терминальной пластинке к передней спайке, которые на уровне органа не образуют анастомозов с сосудами последнего.

На основе морфологической картины обсуждается также предположительная роль органа. Однако на основе проводившихся до сих пор исследований еще нельзя полностью выяснить функцию органа.

Dr. Tibor WENGER
Dr. Béla AROS
Budapest IX., Tűzoltó u. 58., Hungary

Acta Morphologica Acad. Sci. Hung. 19 (2), pp. 151—158, 1971

Department of Biology, Jawaharlal Institute of Postgraduate Medical Education and Research, Pondicherry, India

RECOVERY OF SPERMATOGENESIS AFTER THE WITHDRAWAL OF TESTOSTERONE TREATMENT IN RANA HEXADACTYLA LESSON

S. KASINATHAN and S. L. BASU

(Received August 5, 1970)

Inhibition of spermatogenesis at the secondary spermatogonial stages by testosterone treatment in *Rana hexadactyla*, has been shown. In some species of mammals and also in adult human cases it has been observed that cessation of testosterone therapy results in the restitution to normal of the inhibited germinal epithelium and interstitial elements. The present experiments were conducted to study whether such restitution was possible in frogs after steroid treatment. It was observed that one month after extraction of the testosterone pellet, the spermatogenetic processes had recovered. Significance of the recovery of spermatogenesis after withdrawal of the exogenous inhibitory substance is discussed.

Inhibitory effects of the male sex hormones on spermatogenesis in rats and other mammals have been reported by several workers using a wide range of doses of androgens in animals of various age groups. Small doses of androgen caused greater injury than the larger ones [12]. RUBINSTEIN and KURLAND [14] reported that testosterone propionate in small doses stimulated the germinal epithelium, while its higher doses inhibited testicular growth and spermatogenesis. SHAY et al. [15] reported that in young rats treatment with 3 mg of testosterone propionate weekly led to a decrease of testicular weight, inhibition of sperm maturation and damage to interstitial tissue. They also noted that after the treatment had been discontinued, spermatogenesis was partially restored and some of the animals became fertile. Similar observations were made in adult humans [8—11] where testicular function improved after the cessation of testosterone administration.

Recent investigations into the influence of testosterone on *Leptodactylus chacuensis* [6], *Rana temporaria* [17], *Rana esculenta* [18], *Rana tigrina* [1], *Bufo melanostictus* [2], *Rana pipiens* [5] and *Rana hexadactyla* [4] have shown that the steroid inhibited the formation of secondary spermatogonia, thus preventing a further increase in spermatogenetic activity.

The present investigation was designed to demonstrate whether recovery of spermatogenesis was possible in *Rana hexadactyla* after the cessation of testosterone treatment which had caused spermatogonial inhibition.

Materials and methods

Adult male frogs, *Rana hexadactyla*, weighing approximately 60 g, and 90 mm snout to vent length were locally collected and used in the experiment. Testosterone (Organon Laboratory, England, Batch No. 9364) was implanted in the form of pellets (approximately 15 mg) into the dorsal lymph sac of each frog. The animals were kept under similar conditions for 2 months and fed with earthworms twice weekly. The implanted steroid pellet was examined periodically.

After one month of testosterone treatment, 5 animals were autopsied and from the rest of the frogs the hormone pellet was removed. The latter frogs were autopsied after the withdrawal of hormone treatment in two groups on the 15th and 30th day respectively. Total body weight and testicular weight as calculated relative to body weight were recorded. The testes were fixed in Bouin's fluid, embedded in paraffin, sectioned at 7 μ, and stained with haemalum and eosin. For quantitative assessment of spermatogenetic activity the process was divided into six different stages based on the number of cells in a nest and specific cytological details, as described by VAN OORDT [16]. The salient features of these stages are as follows:

Stage 0 Primary spermatogonia
I Secondary spermatogonia, less than 10 cells in a cell nest
II Secondary spermatogonia, more than 10 cells in a cell nest
III Primary spermatocytes
IV Secondary spermatocytes
V Spermatids

The number of stages were counted in 100 seminiferous tubules selected from 25 different transverse sections of each animal.

In addition to the testosterone treated animals, control animals were similarly treated and their testicular tissue was processed as above.

Two sets of experiments were conducted during the months December, 1967, till February 1968, and March till May, 1969, to note the effect of the seasonal variations on the recovery of spermatogenesis.

Results

In the first set of experiments in the months December, 1967, till February, 1968, secondary spermatogonia *(Stage I)* and spermatids *(Stage V)* were inhibited by the testosterone treatment (Table I). The number of Stage I cell-nests was significantly less ($p < 0.01$) in this group. Stage II of the secondary spermatogonia showed many picnotic cells in their cell-nests in the treated animals. In view of the picnosis, these cell-nests were regarded as non-functional and have not been represented in Table I. Spermatozoa were found mostly in bundles attached to Sertoli's cells. The interstitial tissue appeared to be sparse (Fig. 2).

The second set of experiments conducted from March till May, 1969, showed a similar effect. In *Stage II* there was picnosis, but the reduction of

Plate I

1. Section through testis of control frog showing the presence of all spermatogenetic stages and sperms (haemalum and eosin, × 450). *2.* Section through testis of testosterone treated (one month) frogs showing inhibitory effect of the hormone on Stage I and II of the spermatogenetic cell-nests (haemalum and eosin, × 450). *3.* Section through testis of frogs 15 day after testosterone pellet withdrawal. Slight recovery of the spermatogenesis (haemalum and eosin, × 450). *4.* Section through testis of frogs one month after testosterone pellet withdrawal. Note remarkable recovery of inhibited spermatogenetic cell-nests (haemalum and eosin, × 450)

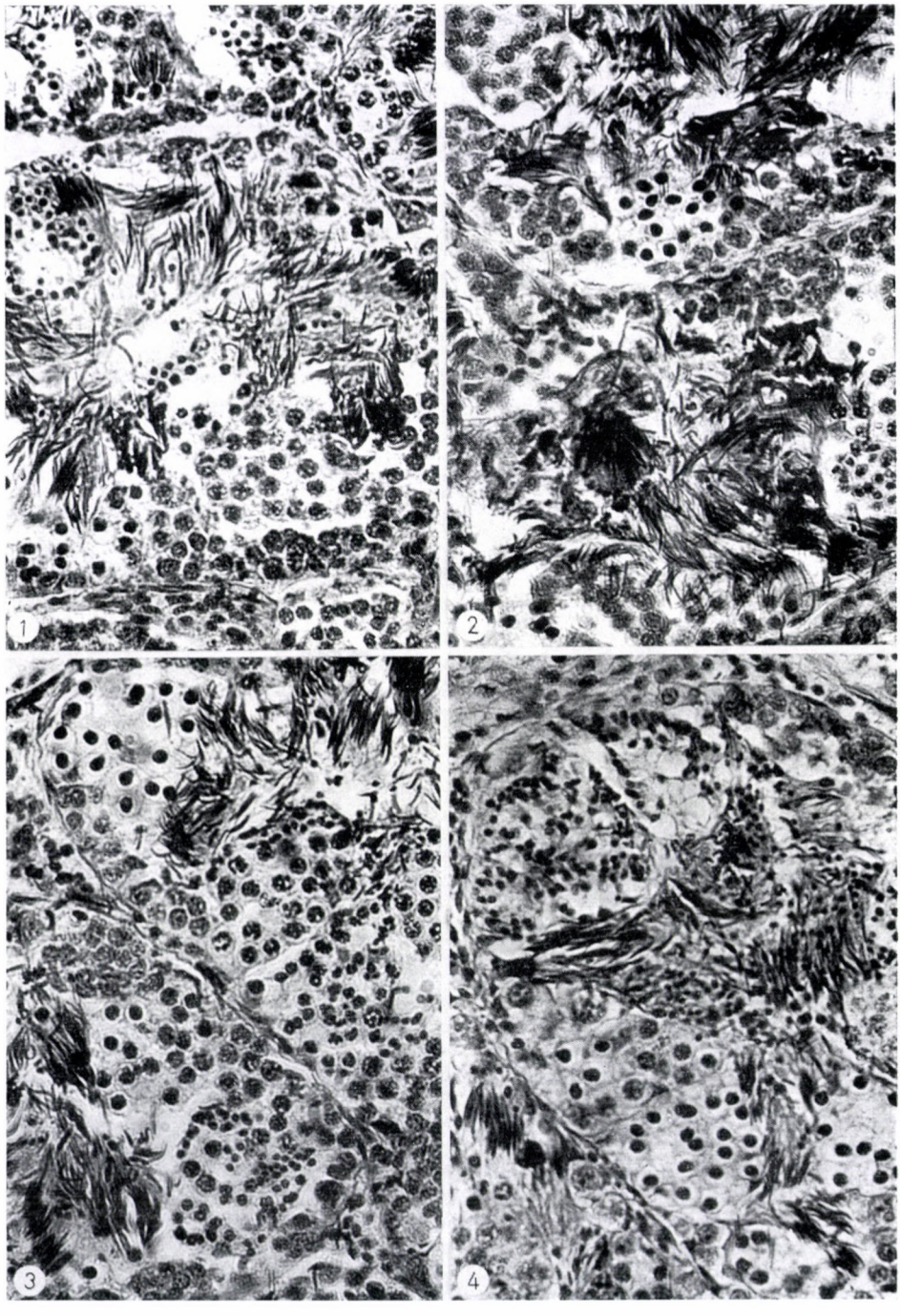
1
2
3
4

Table I

Spermatogenetic stages of experimental and control frogs, Rana

Series	Experimentals							
	No. of animals	Stage 0	Stage I	Stage II	Stage III	Stage IV	Stage V	Relative testicular weight (mg)
Dec., 1967, till Febr., 1968								
Testosterone treated			*3)*				*1)*	
(one month)	5	0.96	0.18	*4a*	3.35	0.89	0.31	0.94
		±0.16	±0.06		±0.81	±0.47	±0.17	±0.03
15 days after pellet					*1)*			
extraction	5	0.90	0.43	2.20	3.95	0.40	0.10	0.60
		±0.05	±0.16	±0.05	±0.20	±0.05	±0.10	±0.03
One month after						*1)*		
pellet extraction	5	1.12	1.61	2.25	4.73	0.09	0.20	0.52
		±0.24	±0.39	±0.23	±.021	±0.08	±0.18	±0.08
March till May, 1969								
Testosterone treated		*1)*	*1)*		*2)*	*1)*		
(one month)	5	1.26	0.58	*4b)*	3.10	0.30	0.21	0.46
		±0.30	±0.14		±0.48	±0.09	±0.08	±0.13
15 days after pellet	5	1.18	0.98	2.75	4.18	0.08	0.12	0.39
extraction		±0.16	±0.18	±0.08	±0.38	±0.06	±0.09	±0.08
One month after					*1)*			
pellet extraction	5	0.80	1.53	2.24	5.25	—	—	0.57
		±0.20	±0.28	±0.39	±0.58			±0.33

1) p 0.05 — significance at 5% level
2) p 0.02 — significance at 2% level
3) p 0.001 — significance at 0.1% level

the cell-nest number in stages 0, I and IV was significant only at the 5% level ($p < 0.05$). Relative testicular weight decreased significantly in comparison to the controls (Table I).

After withdrawal of the testosterone pellet a gradual revival of the suppressed stages (0, I and II) was noted. Although 15 days after the extraction, few cell-nests of Stage II still revealed picnotic conditions, one month after testosterone pellet withdrawal recovery was significant in all the frogs (Table I and Figs 3, 4).

hexadactyla, showing gradual recovery after testosterone treatment

Controls							
No. of animals	Stage 0	Stage I	Stage II	Stage III	Stage IV	Stage V	Relative testicular weight (mg)
5	0.93 ±0.16	1.28 ±0.21	2.82 ±0.60	4.13 ±0.81	0.87 ±0.30	0.62 ±0.04	1.11 ±0.05
5	0.88 ±0.02	1.10 ±0.25	2.80 ±0.05	5.18 ±0.17	0.53 ±0.27	0.65 ±0.25	0.56 ±0.04
5	0.92 ±0.20	1.12 ±0.09	2.05 ±0.14	4.70 ±0.21	0.33 ±0.13	0.35 ±0.00	0.59 ±0.06
5	0.53 ±0.24	1.05 ±0.10	3.40 ±0.35	4.93 ±0.24	0.03 ±0.00	0.03 ±0.00	1.02 ±0.45
5	0.75 ±0.20	1.23 ±0.02	3.18 ±0.22	5.10 ±0.60	0.03 ±0.02	0.05 ±0.02	0.48 ±0.01
5	0.98 ±0.14	1.05 ±0.16	1.89 ±0.07	4.34 ±0.37	0.06 ±0.02	0.10 ±0.06	0.63 ±0.07

4a) & *4b)* contained picnotic cells in the cell-nests. Hence counting, Nos. (4a = 2.13 ± 0.09 & 4b = 2.76 ± 0.36) have not been represented in the Table.
± indicates standard deviation.

The data obtained (Table I) were analysed statistically by the split plot technique (Table II) to determine the differences in the spermatogenetic progress between the treated and hormons withdrawal groups and the controls. It is evident from Table II that inhibition and revival of spermatogenesis showed a 1% level of significance, while the difference in the spermatogenetic progress and the days of treatment was significant only at the 5% level ($p < 0.05$) in both experimental series.

RUBINSTEIN et al. [14] reported that small doses of testosterone propionate are stimulating spermatogenesis. RANDOLPH et al. [13] then showed

that testosterone propionate maintained spermatogenesis even in hypophysectomised rats. SHAY et al. [15] on the other hand observed that testosterone propionate caused testicular inhibition but once treatment had ceased, spermatogenesis was restored and the rats again became fertile. Cases of spermatogenetic revival and even enhancement have been observed in adult humans too [9, 10, 7, 8, 11]; this was regarded as a "rebound recovery".

Table II

Analysis of variance of data on revival of spermatogenesis after testosterone treatment in Rana hexadactyla

(Values significant at the *5% and **1% levels)

Sources of variation	Degrees of freedom	Control (C) sum of squares	Exp. (E) sum of squares	CE sum of squares	$(E\text{-}Bc)^2$ sum of squares	Mean squares	F
Replicates	1	0.3886	0.0225	0	0.0254	0.0254	—
Days	2	0.1766	0.4045	0	0.4057	0.2029	3.52*
Stages	5	84.9587	72.2982	75.7552	59.8679	11.9736	207.52**
Interaction between days and stages	10	0.5245	5.3572	0.1391	5.3771	0.5337	9.25**
Error	17	1.0660	0.9888	0.0919	0.9809	0.0577	—
	35	87.1144	79.0712	75.9862	66.6571	—	—

Recently it has been shown that testosterone treatment and its effect on spermatogenesis is mostly inhibitory on the secondary spermatogonial level [4]. A similar effect has been noted in *Rana hexadactyla* after the implantation of 5 mg [3] and 15 mg (present experiment) testosterone pellets. This result corroborates the earlier reports on the inhibitory action of testosterone in various frogs and toads [1, 2, 4, 5, 6, 17, 18].

In the present experiment we have planned to study the recovery of the spermatogenetic processes after cessation of testosterone treatment. In both experimental groups, spermatogenesis in general as well as the cell counts 15 and 30 days after testosterone treatment revealed a gradual revival to normal conditions. In mammals an enhancement of spermatogenesis was noted after the cessation of testosterone treatment and the phenomenon was termed "rebound recovery". In *Rana hexadactyla*, no such rebound phenomenon occurred, but it was clear that conditions one month after the withdrawal of testosterone treatment had returned to normal. Hence the action of the testosterone reflected the similar functional aspect noted in some mammals.

The present observation has confirmed our view concerning the direct action of exogenous testosterone on testicular tissue [5]. It might be suggested

that exogenous testosterone acts as a shield between the spermatogonial cell-nests and the circulating hypophyseal gonadotrophins responsible for gonadal maintenance. As soon as this blocking effect is withdrawn by extracting the pellet, the pituitary hormone slowly acts upon the germinal epithelium and ultimately revives the spermatogonial cells. It may also be suggested that steroid treatment is lowering the sensitivity of the germinal epithelium to gonadotrophins necessary for the maintenance of spermatogenesis. Hence, recovery is possible when the steroid is withdrawn and seminiferous epithelial sensitivity is revived.

Acknowledgements. We are indebted to the Director of Organon Laboratories, England, for the gift of the hormone pellets. Thanks are also due to Mr. R. Rangaswamy for statistical analysis.

REFERENCES

1. Basu, S. L.: (1962a) A Study of the Spermatogenesis of Common Indian Frog (Rana tigrina) Treated with Testosterone. Naturwissenschaften, **49,** 188. — 2. Basu, S. L.: (1962b) Impact of Some Endo- and Exogenous Factors on the Spermatogenesis of Common Indian Toad, Bufo melanostictus Schneider. Proc. zool. Soc. **15,** 163. — 3. Basu, S. L.: (1968) Effects of Testosterone and Estrogen on Spermatogenesis on Rana hexadactyla Lesson. J. exp. Zool. **169,** 133. — 4. Basu, S. L.: (1969) Effect of Hormones on the Salientian Spermatogenesis in vivo and in vitro. Gen. comp. Endocr. Suppl. **2,** 203. — 5. Basu, S. L., Jean Nandi: (1965) Effects of Testosterone and Gonadotrophins on Spermatogenesis in Rana pipiens Schreber. J. exp. Zool. **159,** 93. — 6. Cei, J. M., Andreozzi, M. L., Acosta, D. I.: (1955) Hormonas Esterolicas Y Correlaciones Hipofisogenitales. Effectos Antigonadotropos en el Ciclo Espermatogenetico de Leptodactylus chaquensis. Arch. Farm. Bioquim. Tucuman. **7,** 119. — 7. Charny, C. W.: (1956) Treatment of Male Infertility with Large Doses of Testosterone. J. Amer. med. Ass. **160,** 98. — 8. Getzoff, P. L. : (1955) Clinical Evaluation of Testicular Biopsy and the Rebound Phenomenon. Fertil. and Steril. **6,** 465. — 9. Heckel, N. J., McDonald, J. H.: (1952) The Rebound Phenomenon of the Spermatogenetic Activity of the Human Testis Following the Administration of Testosterone Propionate. Fertil. and Steril. **3,** 49. — 10. Heller, C. G., Nelson, W. O., Hill, I. B., Hendeisch, E., Maddock, W. O., Jungek, E. C., Paulsen, C. A., Mortimore, G. E.: (1950) Improvement in Spermatogenesis Following Depression of the Human Testis with Testosterone. Fertil. and Steril. **1,** 415. — 11. Hooker, C. W. (1948) Biology of the Interstitial Cells of Testis. Recent Prog. Hormone Res. **3,** 173. — 12. Moore, C. R., Price, D.: (1930) The Question of Sex Hormone Antagonism. Proc. Soc. exp. Biol. (N. Y.) **28,** 38. — 13. Randolph, P. W., Lostroh, A. J., Grattarola, R., Square, P. G., Li, C. H.: (1959) Effect of Ovine Interstitial Cell Stimulating Hormone on Spermatogenesis in the Hypophysectomized Mouse. Endocrinology **65,** 433. — 14. Rubinstein, H. S., Kurland, A. A.: (1941) The Effect of Testosterone Propionate. Endocrinology **28,** 485. — 15. Shay, H., Gerson-Cohen, J., Paschkis, Karl, E., Fels Samuel, S.: (1941) Inhibition and Stimulation of Testis in Rats Treated with Testosterone Propionate. Endocrinology, **28,** 485. — 16. Van Oordt, P. G. W. J.: (1956) Regulation of the Spermatogenetic Cycle in the Common Frog (Rana temporaria).Thesis. Utrecht University, G. W. Van der Wiel and Co., Arnhem, Holland. — 17. Van Oordt, P. G. W. J., Basu, S. L.: (1960) The Effect of Testosterone on the Spermatogenesis of the Common Frog Rana temporaria. Acta endocr. (Kbh.) **33,** 103. — 18. Van Oordt, P. G. W. J., Schouten, S. C. M.: (1961) Effects of Testosterone on the Spermatogenesis of Edible Frog, Rana esculenta. J. Reprod. Fertil. **2,** 61.

DAS WIEDEREINSETZEN DER SPERMATOGENESE NACH DEM EINSTELLEN DER TESTOSTERONBEHANDLUNG BEI RANA HEXADACTLYA LESSON

S. KASINATHAN und S. L. BASU

Die Hemmung der Spermatogenese in der sekundären Spermatogonien-Phase durch Testosteronbehandlung bei Rana hexadactyla wurde bereits früher festgestellt. Bei einigen Säugetierarten, sowie auch bei erwachsenen Menschen wurde beobachtet, daß nach Einstellen

der Testosteronverabreichung im gehemmten Keimepithel und in den interstitiellen Elementen die Regeneration einsetzt und der Normalzustand wiederhergestellt wird. In der vorliegenden Arbeit wurden Experimente durchgeführt, um zu ermitteln, ob auch in Fröschen eine solche Regeneration nach Steroidbehandlung möglich ist. Es wurde der Nachweis erbracht, daß einen Monat nach der Entfernung der Testosteron-Pille die Spermatogenesisprozesse wiedereinsetzen und — ähnlich wie bei den Säugern — den Zustand vor der Behandlung erreichen. Die vermutete Bedeutung der exogenen Inhibitorsubstanz wird gleichfalls besprochen.

ВОССТАНОВЛЕНИЕ СПЕРМАТОГЕНЕЗА ПОСЛЕ ПРЕКРАЩЕНИЯ ВВЕДЕНИЯ ТЕСТОСТЕРОНА У RANA HEXADACTYLA LESSON

С. КАСИНАТАН и С. Л. БАСУ

Торможение сперматогенеза в фазе вторичных сперматогониев после введения теостостерона у Rana hexadactyla было установлено уже раньше. У некоторых видов млекопитающих и у взрослых людей наблюдали, что после прекращения дачи тестостерона заторможенный зародышевый эпителий и интерстициальные элементы восстанавливаются до состояния в норме. В настоящей работе были проведены эксперименты в целях уяснения вопроса о том, возможно ли такое восстановление сперматогенеза у лягушки после введения стероида. Установлено, что через месяц после удаления пилюли тестостерона процессы сперматогенеза возобновляются и достигают состояния, предшествовавшего введению стероида, подобно как и у млекопитающих. Обсуждается также предположительное значение экзогенного ингибиторного вещества.

S. KASINATHAN
S. L. BASU
Dep. of Biology, JIPMER, Pondicherry-6, India

Acta Morphologica Acad. Sci. Hung. 19 (2), pp. 159–173, 1971

Department of Histology (Head: Prof. P. A. MOTAVKIN) Medical Institute of Vladyvostok, USSR

HISTOCHEMICAL CHARACTERISTICS OF ACETYLCHOLINESTERASE OF THE NERVES INNERVATING THE BRAIN VESSELS

P. A. MOTAVKIN and T. V. DOVBISH

(Received December 10, 1970)

The neural apparatus of the cerebral blood vessels has been studied in 36 adult cats. The pia mater of the cortex of cerebral hemispheres and cerebellum as well as that of the basilar and tectal parts of the brain stem has been prepared for the demonstration of acetylcholinesterase and cholinesterase by the methods of GEREBTZOFF, KOELLE and GOMORI. Neural apparatuses of the intracerebral vessels were investigated in sections cut from brain fixed in 10% neutral formaldehyde. As inhibitor, physostigmine was used.

The basilar, cerebellar, posterior, internal carotid, anterior and medial cerebral arteries and all those of the pia mater more than 400 μ in diameter displayed two cholinergic plexuses: an adventitial and an interlaminary one, the latter being situated at the border of the outer and middle layers. The arteries less than 400 μ in diameter have only one superficial plexus. Around the intramedullary vessels, cholinergic nerves 10—20 μ thick can be found. In the cerebellar cortex, the mesencephalon at the level of the nucleus ruber and in the tuber cinereum, muscle cells and endothelial cells contain acetylcholinesterase. It is assumed that the mediator is released along the whole fibre forming synapses with the muscle cells.

Introduction

In the neural regulation of the brain vessels, according to KLOSOWSKY (1951), one can regard as proved that the vasodilatatory innervation is represented by special parasympathetic fibres. The majority of physiologists dealing with cerebral haemodynamics share this opinion because the dilatatory effect of stimulation of certain nerves is more expressed on the pial arteries than the constrictory one of stimulated sympathetic pathways.

Namely, 18—50% dilatation of the brain vessels was found stimulating the n. vagus (KEDROV and NAUMENKO, 1954; FINESINGER and PUTNAM, 1933), the n. petrosus superficialis maior (CHOROBSKY and PENFIELD, 1932) and the vestibular apparatus (KLOSOWSKY, 1951). Stimulating the latter, the impulse reaches the pial vessels of the frontoparietal region through Darkschewits' nucleus where the preganglionic fibres of the oculomotor nerve originate (KLOSOWSKY et al., 1951). However, the presence of parasympathetic conducting elements going to the brain vessels has never been proved in these nerves, using neurohistological and experimental-morphological methods (LAZORTHES, 1956).

Thus, revealing the haemodynamical mechanisms of the brain circulation is an important task of modern histochemistry the methods of which are able to clear up the main points of the neural conducting elements directly in the tissues.

Acetylcholinesterase is one of the substances playing a central role in the maintenance of the specific functional activity of the nervous system. It occurs in the neural elements releasing acetylcholine upon the influence of nerve impulses (KOELLE, 1962), and both the pre- and postsynaptic membranes contain the enzyme. It is synthetized intracellularly and arrives gradually to the site of its effect along the neural processes (MICHELSON and ZEIMAL, 1970). From the presence of acetylcholinesterase one may judge of the cholinergic nature of the nerve fibres (FOLKOW, 1952; UVNÄS, 1966) and all such fibres may be assumed to be parasympathatic ones in the postganglionic region of the vegetative nervous system (DALE, 1935).

Histochemical studies of acetylcholinesterase deserves interest in this relation, and especially as regards the nerves of the blood vessels of the brain and the spinal cord. Data concerning the cholinergic fibres of these vessels have been published recently (BELIKOV et al. 1970; KROCHINA et al. 1970; LAVRENTEVA et al. 1968; PALASHENKO and POTEMKINA, 1970); these papers give a detailed description of cholinergic fibres of many intracerebral arteries. However, there is no consistent and systematic characterization of the cholinergic apparatus of the total arterial system of the brain. This will form the subject of the present paper.

Material and methods

The neural apparatuses of the blood vessels of the brain were investigated in 36 cats. Adult animals of both sexes were used. They were killed by thiopental or bled to death. The brain was removed immediately. The pia mater of the cortex of cerebral hemispheres and cerebellum as well as that of the basilar and tectal parts of the brain stem has been prepared, mounted on slides and treated accordingly.

Pieces of the brain fixed in 10% neutral formaldehyde were used for demonstrating the neural apparatuses of intracerebral vessels. Sections 10—15 μ thick were cut either by a freezing microtome or a cryostate. Acetylcholinesterase activity was investigated by the thiocholine methods of KOELLE, GOMORI and GEREBTZOFF. Acetylthiocholine iodide was used as substrate. Cholinesterase activity was demonstrated with butyrylthiocholine iodide as the substrate, this allowed the differentiation of the two enzymes on the basis of the degree of activity. The duration of incubation was tested experimentally; it was not less than one and not more than one and a half hour. Localization of the enzyme was indicated by the brown copper sulphide granules. Control sections were treated with eserine before incubation.

The results obtained by the different methods were essentially identical. The most intense reaction could be observed at pH 6.2—6.8 in 1—1.5 hour with all three methods. The reaction product was of uniform distribution along the nerve fibres.

For a quantitative evaluation of cholinergic fibres found on the vessels different in diameter, the transversal and longitudinal bundles were counted and processed statistically. Longitudinal bundles were considered those forming an angle of less than 45° with the longitudinal axis of the vessel (LAVRENTEVA et al., 1968).

Results

After optimal incubation, acetylcholinesterase activity was indicated by small, yellow, brown or dark brown granules. The localization of these granules formed during the reactions corresponded to single nerve fibres, bundles and small nerves. After longer incubation, small crystallized deposits appeared around the nerves. The longer the incubation the greater was their number. Voluminous conglomerates consisting of rough, yellowish, bright crystals had formed on incubation longer than two hours. This phenomenon was observed more frequently in sections prepared by Gerebtzoff's method than in the case of the Gomori and Koelle techniques. There was no acetylcholinesterase activity in the elements forming the wall of large arteries, thus the nervous fibres rich in enzyme could be seen with good contrast and brightness. On rare occasions there occurred forms consisting of angulated nuclear granules localized in small chains, the arrangement of which corresponded to that of single nerve fibres and small nerves in the wall of the vessel. On the basis of their localization, these nuclei most probably belonged to the Schwann cells forming the outer layer around the nerve fibres. Precipitation of granulated deposits in the karyoplasm is, according to PORTUGALOV (1955), an evidence of the nuclear localization of the enzyme. Nevertheless, this point of view is not shared by all cytochemists; some of them consider these deposits artefacts. However, the latter opinion cannot be regarded as correct since biochemical methods do not deny the presence of acetylcholinesterase in the nuclear apparatus (DIXON and WEBB, 1966). As it has been pointed out above, besides acetylcholinesterase also cholinesterase was investigated in every experiment.

The pictures obtained during the investigations of the latter enzyme considerably differed from those resulting from the acetylcholinesterase reaction. Finely granular, diffusely dispersed deposits could be seen in the entire wall of the vessels. Nerve bundles or single fibres appeared in an indistinct form before the background. Moreover, for distinction of acetylcholinesterase from cholinesterase, eserine was used. A previous incubation with this agent inhibited the reaction of acetylcholinesterase.

A typical neural network was found in the arterial wall by means of demonstration of acetylcholinesterase, containing different amounts of cholinergic nerve fibres in different arteries.

A. basilaris (Fig. 1)

At the junction of the vertebral arteries, a dense cholinergic network was found on the a. basilaris, consisting of thick nerve bundles 20—30 μ in diameter. The number of such bundles varied between 1—18 in different animals. The nerves of the right and left vertebral arteries partly remained on

their own side, partly decussated to the opposite side at the beginning of the a. basilaris. Thus, the nerves of right and left vertebral arteries are mixed in the plexus of the a. basilaris.

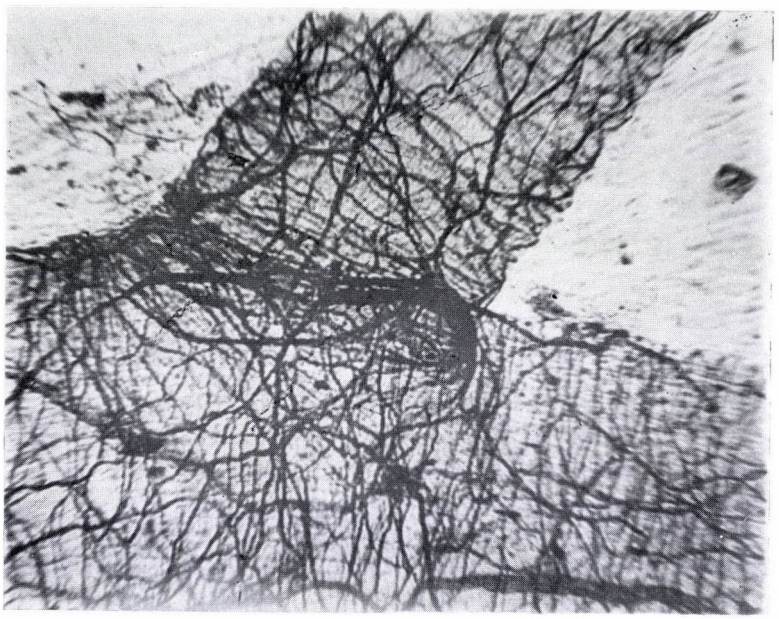

Fig. 1. Function of vertebral arteries and origin of a. basilaris. Note the superficial and deep cholinergic plexuses. Method of Koelle for acetylcholinesterase. Microphoto, FMN-3, objective 10, Gamal 7; height of chamber, 104 cm

In the cat, the a. basilaris in the oblong medulla, measured 1157 $\pm$ 119 μ in diameter.

It has been revealed by counting that in the a. basilaris longitudinal nerves are dominant (15 $\pm$ 1) in the region of the oblong medulla. The number of transversal nerve bundles was somewhat less (9 $\pm$ 3.8) (Fig. 2).

The diameter of the a. basilaris decreases to 844 $\pm$ 44.6 μ at the level of the pons. The superficial nerve plexus is more dense here and at the same time the number of thick bundles decreases in it. In different parts of the artery this number fluctuates between 1 and 5. The number of longitudinal nerve bundles remains unchanged (14 $\pm$ 2.2).

At the same time, the number of thin transversal stipes noticeably increases and this is the reason for the higher density of the cholinergic plexus (20 $\pm$ 8.8). The average values show that the density of the neural plexus is not uniform in the different regions of the a. basilaris. The plexus becomes especially dense at the sites where the largest vessels such as the cerebellar

ones are branched off. Besides the superficial plexus there is a deep one in the total area of the basilar artery, localized between the outer and middle layers. It consists of thin nerve stipes dispersed in single nerve fibres.

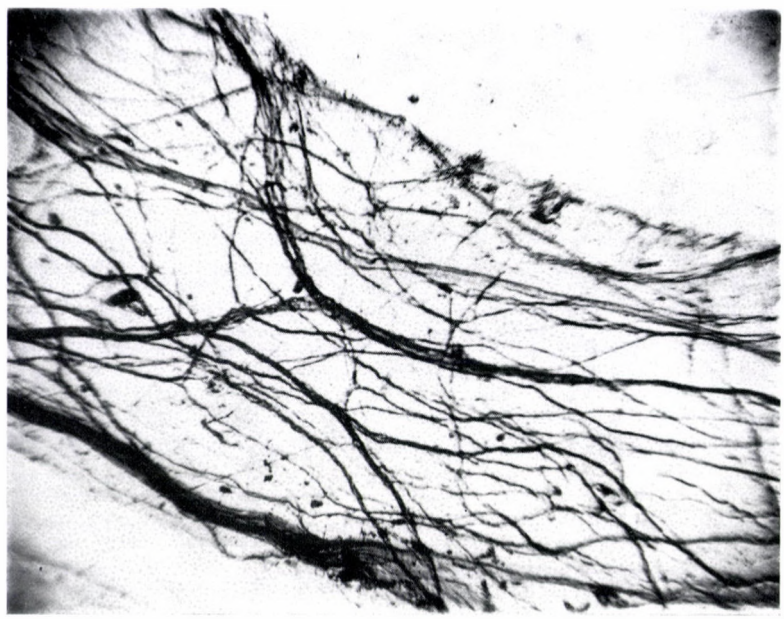

Fig. 2. A. basilaris in the area of pons. Cholinergic plexus with preponderating transversal bundles and fibres. Method of Koelle, microphoto, FMN-3, obj. 10, Gamal 7; height of chamber, 104 cm

A. cerebellaris (Fig. 3)

The neural plexus of the a. basilaris spreads over to the cerebellar vessels. It is composed mainly by thin nerve stipes not more than 11 μ in diameter. The plexus covers the whole area of the vessels and in distal parts it becomes rarer and wide-meshed. The increase in the number of nerve stipes can always be observed at the branching off of smaller vessels. Bundles originate from the superficial plexus, running to the core of the wall. They form a deep plexus situated on the muscle cells. There were no essential differences in the structure of the cholinergic plexuses of different cerebellar arteries. This is the reason why the quantitative characteristics of the cholinergic nerve plexus are given on the basis of one of the anterior inferior cerebellar arteries. Statistical evaluation revealed that the number of longitudinal bundles strongly varies along the vessel (12 ± 5.3). This indicates that they are not uniformly distributed in the proximal and distal parts of the artery: there are more of

them in the former than in the latter part. The same was the situation with the transversal nerve fibres. Their number amounts to 21 ± 7.8. Their high scattering indicates the variability in the structure of the plexuses at different sections of the same vessel.

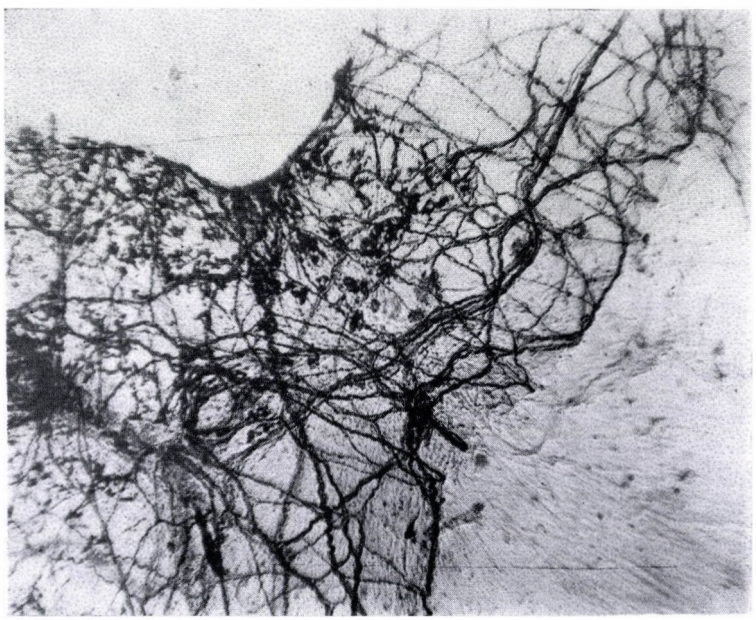

Fig. 3. Beginning of a. cerebellaris anterior inferior; the upper right part of the a. basilaris can be seen. Cholinergic plexus and pigment cells. Method of Gomori, microphoto, FMN-3, obj. 10, Gamal 7, height of chamber, 104 cm

Posterior cerebral arteries (Figs 4 and 5)

The cholonergic plexuses of the posterior cerebral arteries are continuous with those of the a. basilaris. The density of the neural plexus increases at the origin of the a. cerebralis posterior and remains almost unchanged as far as the origin of the a. communicans posterior. Longitudinal and transversal nerve bundles (7 ± 2.3 and 32 ± 0.2, respectively) forming superficial and deep plexuses can be observed along the whole a. cerebralis posterior which have measures 739 ± 106 μ in diameter. The low variation coefficient indicates that the number of transversal bundles is nearly identical along the whole vessel in different animals. Among the longitudinal and transversal stipes thin ones occur with not less than 11 μ in diameter. More thick ones appear only in rare instances.

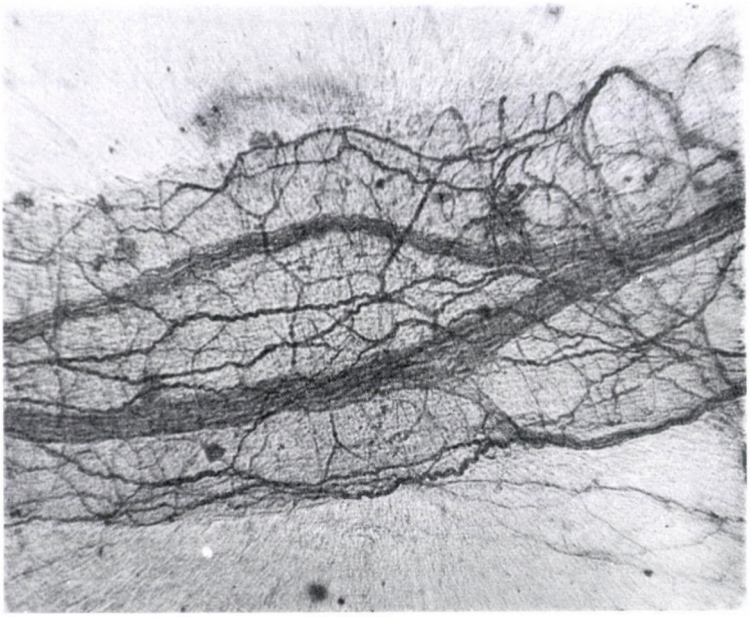

Fig. 4. A. cerebralis posterior. Cholinergic plexus with large nerve stipes. Methodof Koelle, microphoto, FMN-3, obj. 10, Gamal 7; height of chamber 104 cm

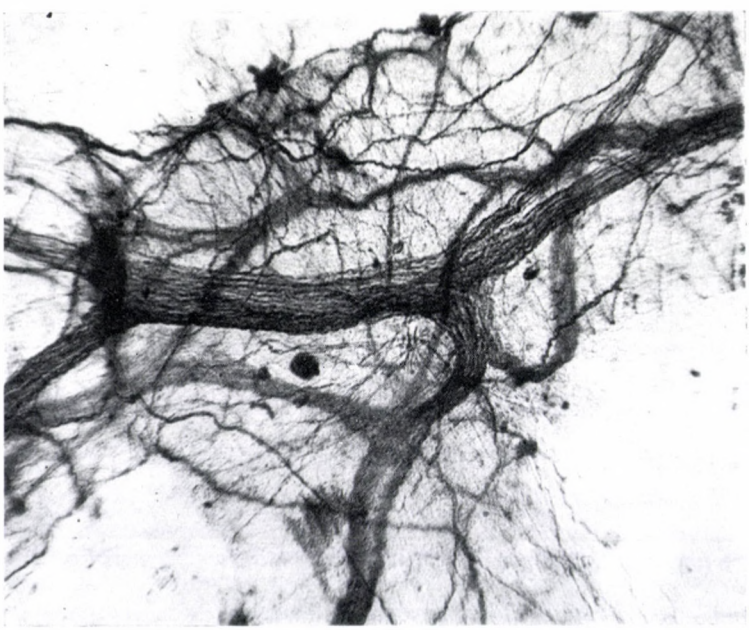

Fig. 5. Caudal part of circulus arteriosus Willisi. Above, a. cerebralis posterior; bottom, a. communicans posterior. Cholinergic plexus with large nerves. Method of Koelle, microphoto, FMN-3, obj. 10, Gamal 7; height of chamber, 104 cm

A. carotis interna

In the cats this artery represents a significantly reduced vessel (TANDLER, 1902), which is rarely well developed showing a diameter of 956 ± 119 μ. Its distal part gives off the anterior cerebral, communicating posterior and medial cerebral arteries. In the wall of the a. carotis interna one can find two plexuses, a superficial and a deep one. The first consists of thin nerve stipes and considerably thick nerves. At certain sections of the vessel one can see three to five times ramifying nerves of 20—32 μ thickness. These nerves pass over to the other side of the vessel; interchanging bundles, they give thin side branches ramifying later. The complex of thin and thick stipes composes the outer plexus.

The deep plexus is composed of thin stipes. They form a wide meshed network between the adventitious and muscular layers. Transversal bundles (26 ± 4) are dominant in the plexuses as compared with the longitudinal ones (9 ± 4.5).

A. cerebralis media (Fig. 6)

This vessel is the thickest one (642 ± 48 μ) of the three branching off of the a. carotis interna. Its outer plexus contains mainly thin bundles less than 11 μ in diameter. The number of transversal (14 ± 9.6) and longitudinal

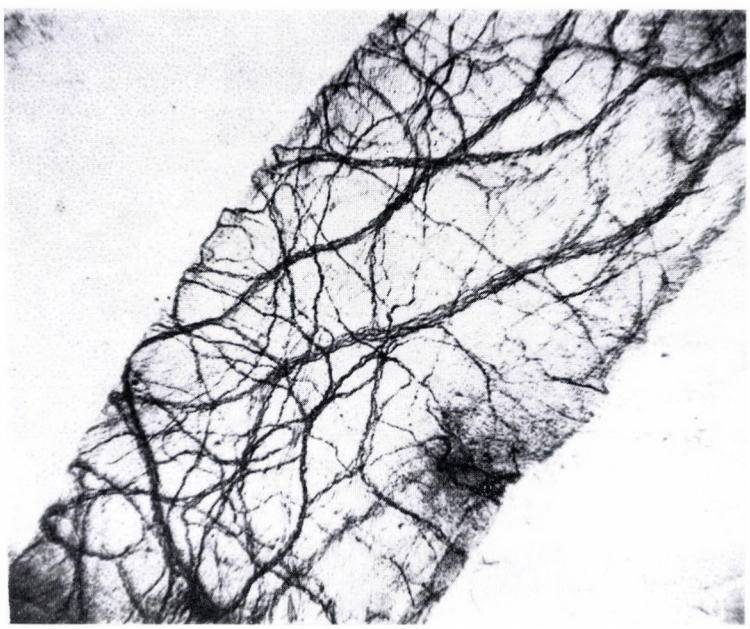

Fig. 6. A. cerebralis media. Cholinergic plexus. Method of Koelle, microphoto, FMN-3, obj. 10, Gamal 7; height of chamber, 104 cm

(8 ± 3.1) stipes varies strongly, indicating a great variability of the structure of neural plexuses along the artery. There is also an internal, wide-meshed plexus in the wall of the a. cerebralis media, consisting of thin nerve stipes.

Arteries of the pia mater (Fig. 7)

These vessels represent branches of the large arteries of the carotid and vertebral systems. Their diameter fluctuates between 400 and 100 μ or less. The number of cholinergic fibres is about the same in the vessels measuring

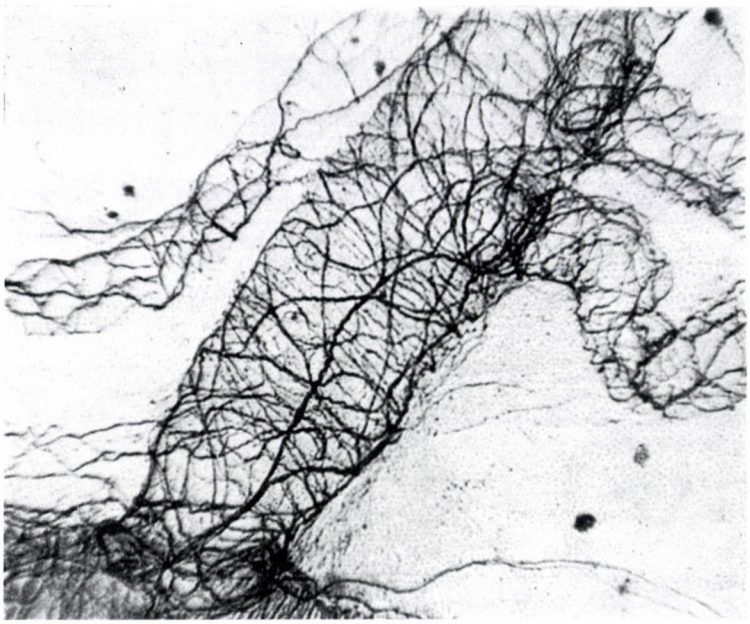

Fig. 7. Arteries of pia mater, cholinergic neural plexus. Method of Koelle, microphoto, FMN-3, obj. 10, Gamal 7; height of chamber 104 cm

400 μ in diameter as in the main branches of the a. basilaris and a. carotis interna. The number of longitudinal and transversal fibres amounts to 11 ± 3.8 and 13 ± 1.2, respectively on the cat, these vessels represent the last cerebral arteries in the wall of which superficial and deep plexuses are separated. In all the thinner arteries one can find the superficial plexus. Counting the nerve fibres of the vessels of different thickness revealed that the decrease in vascular thickness was followed by a gradual decrease in the number of both longitudinal and transversal fibres. Thus, their number amounts to 12 ± 2.3 and 4 ± 2.5 in an artery of 300 μ thickness whereas only to 6 ± 1.5 and 3 ± 1.8 in one measuring 200 μ in diameter.

The decrease in the number of transversal fibres is more expressed than in that of longitudinal ones as compared with the larger vessels. As a conse-

quence, the differences between the vessels of 400 and 300 μ thickness are statistically significant concerning the transversal fibres ($p > 99\%$). In the arteries less than 100 μ in diameter, transversal fibres occur at random. The number of longitudinal bundles decreases gradually and the difference becomes statistically significant in the vessels of 200 μ thickness ($p > 99.9\%$).

Intracerebral arteries (Figs 8 and 9)

The blood vessels of the pia mater and the brain represent an anatomical unity. Thus the neural apparatus of the pial vessels is directly continuous with that of the intramedullary ones (MOTAVKIN and TICHVINSKAYA, 1969; BAKAY, 1941; HUMPHREYS, 1939).

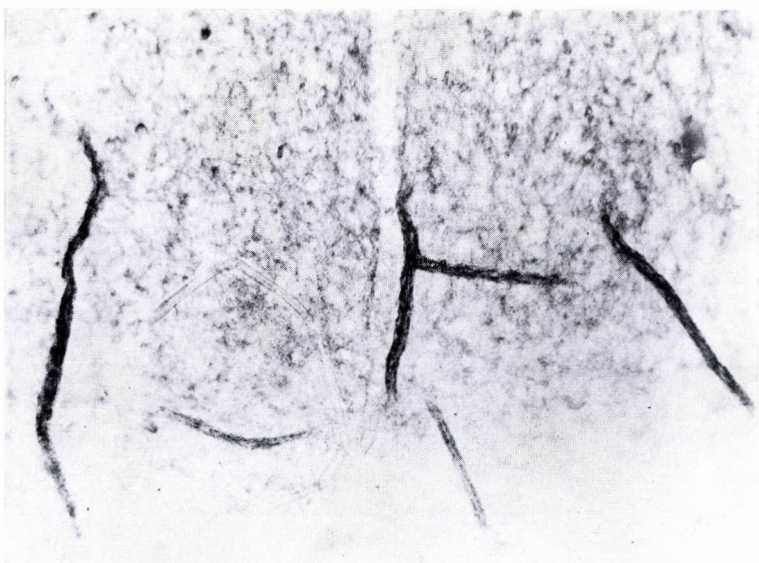

Fig. 8. Cholinergic nerves of the vessels in the cortex of cerebral hemispheres. Method of Gerebtzoff, microphoto, magnification × 100

However, there are no data concerning the histochemical characteristics of intracerebral nerves. Investigating their acetylcholinesterase activity, small cholinergic nerves were found to enter the brain substance together with the blood vessels. Such nerves of 10—20 μ thickness have been found in the medulla oblongata, mesencephalon and cortex of the cerebral hemispheres. They could be followed into the pia mater and the brain where they ramified at the branching off of the vessels.

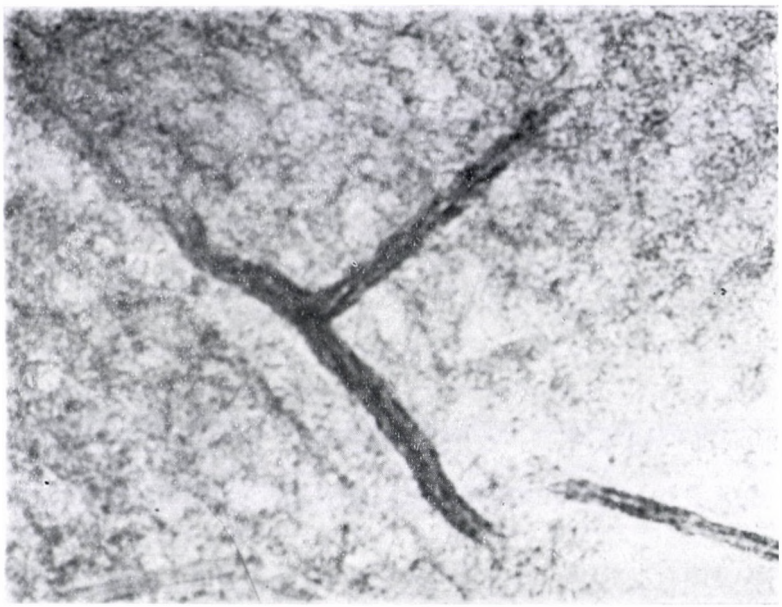

Fig. 9. Cholinergic nerves of the vessels in the cortex of cerebral hemispheres. Method of Koelle for acetylcholinesterase; microphoto, magnification × 200

Acetylcholinesterase activity of capillary vessels of the brain (Fig. 10)

Using the methods of Koelle and Gerebtzoff, numerous copper sulphide granules were seen in the wall of precapillary arterioles and capillaries. In consequence of this, the capillary network can perfectly be seen in certain parts of the brain such as the cerebellar cortex, medulla oblongata in the mesencephalon at the level of the nucleus ruber and the tuber cinereum. In the vessels, besides diffusely localized granules there are areas displaying a considerable concentration of granules. These parts are of longitudinal direction, intense black in colour and frequently occur at the sites where the arteriole forms capillaries.

With butyrylthiocholine iodide, the staining of capillary vessels is weak and the precapillary arterioles cannot be seen, indicating the presence of acetylcholinesterase and cholinesterase in the capillary vessels. Control experiments with eserine are most convincing in this respect. An incubation of sections in eserine solutions for 2 hours inhibits but does not totally abolish the reaction with acetylthiocholine. After 10 to 12 hours incubation the reaction is so intensely inhibited that the capillary network cannot be seen. The results obtained allow to assume that precapillary arterioles and capillaries occur in certain parts of the brain, the muscle and endothelial cells of which contain acetylcholinesterase.

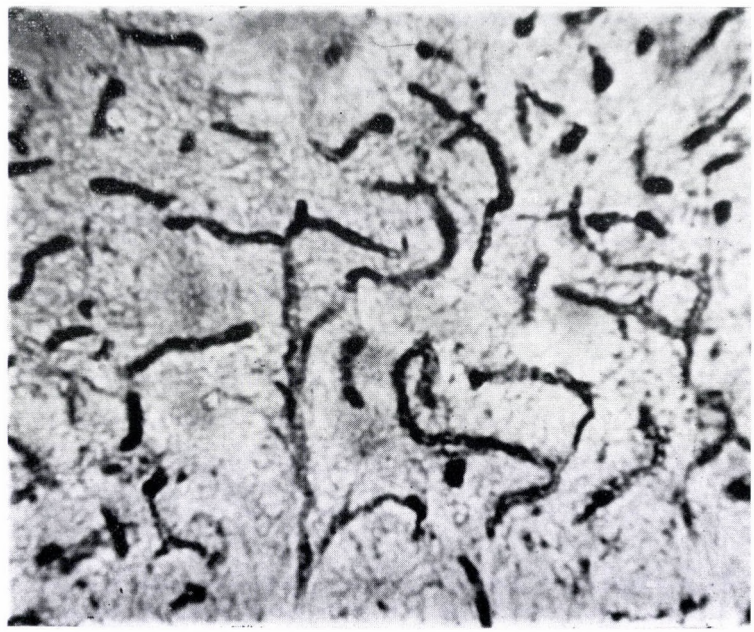

Fig. 10. Mesencephalon at the level of the nucleus ruber. Network of capillary vessels. Method of Gerebtzoff, microphoto; magnification, × 100

Discussion

The above study of acetylcholinesterase activity the localization of which indicates the presence of acetylcholine metabolism, revealed the cholinergic neural apparatus. In the overwhelming majority of cases it was evident that its nerves belong to the parasympathetic nervous system (DALE, 1935).

Two cholinergic plexuses, a superficial and a deep one, have been found in the a. basilaris; a. cerebellaris; a. cerebralis anterior, posterior and media; a. carotis interna; all arteries of the pia mater, the diameter of which is not less than 400 μ. These plexuses are in a close anatomical connection, since the deep one represents a continuation of the outer one in the vascular wall. The superficial plexus is composed of thick nerves situated in the periadventitious and outer layers of the vessels. The deep plexus consists of thin nerve stipes and single cholinergic fibres situated between the adventitia and middle layer and contacting the smooth muscle cells.

Counting of cholinergic nerves and statistical analysis of the values obtained indicate that the density of the cholinergic plexus increases with the increase in the number of transversal nerve stipes.

The cholinergic plexus of a. carotis interna seems to be at a higher degree of development than that of a. basilaris, since in the first vessel the transver-

sal stipes preponderate ($p > 99\%$) while the number of longitudinal bundles is the same in both of them. The branches of the a. basilaris, namely the a. cerebellaris anterior inferior and a. cerebralis posterior are more rich in transversal nerve fibres ($p > 99\%$) than the a. basilaris itself.

There is no difference in the number of nerve fibres in the a. carotis interna and the a. cerebralis media ($p < 95$). At the same time there are more transversal fibres in the plexus of the a. cerebralis posterior and anterior than in that of the a. carotis interna ($p < 95\%$ in both cases).

The density of the cholinergic plexuses is about the same in the a. cerebellaris inferior and in all the branches of the internal carotid ($p < 95\%$ in all cases).

The a. cerebralis posterior is poor in longitudinal nerve bundles as compared with the a. cerebralis anterior and media ($p > 95\%$ and $p > 99\%$, respectively). With the narrowing of the arteries, first the deep plexus ceases. It is lacking already in the vessels 300 μ in diameter. The decrease of the number of transversal stipes is more expressed in the same direction than that of the longitudinal ones.

Thus the results obtained on the basis of acetylcholinesterase activity are in agreement with those obtained by means of silver impregnation of the same material (BAKAY, 1941). In both cases the presence of two plexuses has been revealed. Nevertheless with the histochemical demonstration of acetylcholinesterase the nerves are seen more perfectly and at the same time there is a possibility of clarifying their functional significance which cannot be achieved by impregnation methods.

The extra and intramedullary network of the blood vessels of the brain is continuous anatomically. One could thus expect that the nerves of pial arteries also proceed along their branches into the brain. This has been evidence in many cases (ERKHOV, 1969; MOTAVKIN and TICHVINSKAYA, 1969). For this reason the problem of innervation of the own vessels of the brain is one of the most important questions. Further observations in this field may be necessary for completing the general theory of cerebral blood circulation.

We have been the first to succeed in demonstrating that the intramedullary nerves consist of cholinergic fibres proceeding into the brain together with the vessels of the pia mater. These nerves 10—20 μ in diameter can be observed on the largest intracerebral arteries of the medulla oblongata, the mesencephalon and the cortex of the cerebral hemispheres.

It would be important to clarify how far the intramedullary nerves spread and whether they go over to the smallest arterioles and capillaries. The question remains open, since our negative results cannot be assumed to be definitive. We have failed to observe neural elements on the small intracerebral arterioles and capillaries; this may, however, be explained by the fact that some other elements of these vessels also contain acetylcholinesterase. These data concern-

ing the extraneural localization of acetylcholinesterase are in agreement with the wide occurrence of the enzyme. Electron microscopic evidence has been published of the presence of acetylcholinesterase in both smooth muscle cells and connective tissue elements (NAIK and CAUNA, 1970; ROBINSON, 1970).

Cholinergic fibres are in synaptic contact with the smooth muscle cells (KROKHINA et al., 1970), where acetylcholine is liberated, the dilatatory factor of the brain vessels (KEDROV and NAUMENKO, 1954).

Thus, the results obtained explain that the cerebral arteries react better in the direction of dilatation owing to the presence of a well-developed cholinergic neural apparatus.

REFERENCES

1. BAKAY, L.: (1941) Arch. Psychiat. Nervenkr. **113,** 412—427. — 2. CHOROBSKY, I., PENFIELD, W.: (1932) Arch. Neurol. Psychiat. **28,** 1257—1289. — 3. DALE, H.: (1935) Proc. roy. Soc. B **28,** 391. — 4. DIXON, M., WEBB, E.: (1966). Ферменты. Изд. Мир, Москва. — 5. FINESINGER, I., PUTNAM, T.: (1933) Arch. Neur. Psychiat. **14,** 775—794. — 6. FOLKOW, B.: (1952) Physiol. Rev. **35,** 629. — 7. HUMPHREYS, S.: (1939) Arch. Neur. Psychiat. **41,** 1207—1221. — 8. KOELLE, G.: (1962) J. Pharm. Pharmacol. **14,** 65—90. — 9. LAZORTHES, G.: (1956) Acta neuroveget (Wien) **14,** 74—86. — 10. NAIK, N., CAUNA, N.: (1970) IX Int. Congress of Anatomists, Leningrad, Abstract of papers, P. 92. — 11. ROBINSON, P.: (1970) IX Int. Congress of Anatomists, Leningrad, Abstract of papers, P. 108. — 12. UVNÄS, B.: (1966) Fed. Proc. **25,** 1618. — 13. TANDLER, I.: (1902) Akad. Wiss. math. naturw. Kl. 67, No. 677, 1899. — 14. Беликов, А. А., Довбыш, Т. Б., Мотавкин, П. А.: (1970) IX Int. Congr. Anatomists, Leningrad, Abstract of papers, P. 14. — 15. Ерхов, И. С.: (1969) Функциональная и прикладная анатомия венозной системы. Изд. Медицина, Москва, стр. 205—207.—16. Кедров, А. А., Науменко, А. И.: (1954) Вопросы физиологии внутричерепного кровообращения с клиническими их освещением, Медгиз, Ленинград. — 17. Клосовский, Б. Н.: (1951) Циркуляция крови в мозгу, Медгиз, Москва. — 18. Клосовский, Б. Н., Космарская, В. Н., Афвнасьева, М. Е.: (1951) Бюллетень экспериментальной биологии и медицины, **31,** 295—299. — 19. Крохина, Е. М., Бородуля, А. В., Плечкова, Е. К.: (1970) IX. Int. Congr. Anatomists, Leningrad, Abstract of papers, P. 72. — 20. Лаврентьева, Н. Б., Мчедлишвили, Г. И., Плечкова, Е. К.: (1968) Бюллетень экспериментальной биологии и медицины, **64,** 110—113. — 21. Михельсон, М. Я., Зеймаль, Э. В.: (1970) Ацетилхолин. Изд. Наука, Ленинград. — 22. Мотавкин, П. А., Довбыш, Т. В.: (1970) Бюллетень экспериментальной биологии и медицины, **70,** 113—116. — 23. Мотавкин, П. А., Тихвинская, Б. Т.: (1969) Бюллетень экспериментальной биологии и медицины, X, № 1, 84—87. — 24. Мчедлишвили, Г. И.: (1968) Функция сосудистых механизмов головного мозга. Их роль в регуляции и в патологии мозгового кровообращения. Издат. Наука, Ленинград. — 25. Палащенко, Л. Д., Потемкина, С. Д., : (1970) Материалы первой Всероссийской научной конференции по проблеме· Общие закономерности морфогенеза и регенерации, Москва, стр. 108—109. — 26. Португалов, В. В.: (1955) Очерки гистофизиологии нервных окончаний, Медгиз, Москва.

HISTOCHEMISCHE CHARAKTERISTIKEN DER AZETYLCHOLINESTERASE IN DEN DIE GEHIRNGEFÄßE INNERVIERENDEN NERVEN

P. A. MOTAVKIN und T. V. DOVBISH

Im Gehirn von 36 erwachsenen Ratten wurde der Nervenapparat der Blutgefäße untersucht. Die Pia mater der Großhirnrinde und das Kleinhirn, wie auch die basilaren und tectalen Teile des Gehirnstammes wurden zum Nachweis der Azetylcholinesterase und Cholinesterase nach dem Verfahren von Gerebtzoff, Koelle und Gomori präpariert. Der Nervenapparat der intrazerebralen Gefäße wurde an Schnitten von Gehirnstückchen nach Fixation in 10%igem Formaldehyd untersucht. Als Inhibitorsubstanzien dienten Eserinlösungen.

Die A. basilaris, A. cerebellaris, A. cerebralis posterior, A. carotis interna, A. cerebralis anterior, A. cerebralis media und sämtliche Arterien der Pia mater mit einem Diameter von

über 400 μ haben zwei cholinerge Geflechte: ein adventitiales und ein interlaminares Geflecht, wobei des letztere an der Grenze der äußeren und mittleren Schichten lokalisiert ist. Die Arterien mit einem Diameter von weniger als 400 μ besitzen nur einen oberflächlichen Plexus. In der Umgebung der Intramedullargefäße finden sich cholinerge Nerven von 10 bis 20 μ Dicke. In der Kleinhirnrinde, auf dem Niveau des Nucleus ruber im Mesencephalon und im Tuber cinereum enthalten die Muskel- und Endothelzellen Azetylcholinesterase. Vermutlich wird der Mittler entlang der ganzen, mit den Muskelzellen Synapsen bildenden Faser freigesetzt.

ГИСТОХИМИЧЕСКАЯ ХАРАКТЕРИСТИКА АЦЕТИЛХОЛИНЭСТЕРАЗЫ СОСУДИСТЫХ НЕРВОВ ГОЛОВНОГО МОЗГА

П. А. МОТАВКИНА и Т. В. ДОВБЫШ

Изучался нервный аппарат кровеносных сосудов головного мозга у 36 взрослых кошек. С коры больших полушарий, коры мозжечка, основания и крыши мозгового ствола снималась мягкая оболочка и в таком виде обрабатывалась на ацетилхолинэстеразу и холинэстеразу методами Жеребцова, Кёлле и Гомори. Нервный аппарат внутримозговых сосудов изучался на срезах, изготовленных из фиксированных в 10% нейтральном формалине кусочков мозга. В качестве ингибитора использовались растворы эзерина.

На основной, мозжечковой, задней мозговой, внутренней сонной, передней мозговой, средней мозговой и всех артериях мягкой оболочки диаметром не менее 400 мк установлено два холинергических сплетения: адвентициальное и межслоевое, располагающееся на границе наружной и средней оболочки. На артериях, диаметр которых меньше 400 мк, имеется одно поверхностное сплетение. В веществе мозга около интрамедуллярных сосудов обнаружены холинергические нервы толщиной 10—20 мк. В коре мозжечка, среднем мозгу на уровне красного ядра и в сером бугре мышечные и эндотелиальные клетки содержат ацетилхолинэстеразу. Предполагается, что медиатор выделяется на всем протяжении волокна, которое образует с мышечными клетками непрерывный синапс.

P. A. Motavkin
T. V. Dovbish
Department of Histology, Medical University, Vladivostok, USSR

Acta Morphologica Acad. Sci. Hung. 19 (2), pp. 175—185, 1971

Institute of Experimental Medicine (Director: Dr. E. STARK), Hungarian Academy of Sciences* and Second Institute of Pathological Anatomy (Director Prof. H. JELLINEK), Semmelweis Medical University, Budapest

VASCULAR INJURY ASSOCIATED WITH ACUTE PANCREATITIS INDUCED BY OIL OR Na-DEOXYCHOLATE

Z. NAGY, M. PAPP* and A. BÁLINT

(Received December 11, 1970)

Acute pancreatitis has been induced in pigeons by the intraductal injection of sunflower oil or Na-deoxycholate. To visualize vascular leakage, the birds were given intravenously a colloidal iron tracer solution which then was detected by means of the Prussian-blue reaction. An increase in vascular permeability was demonstrated in both oil-induced and Na-deoxycholate-induced acute pancreatitis. In oil-induced pancreatitis, vascular leakage was of the histamine-type. In Na-deoxycholate-induced pancreatitis, direct vascular damage occurred in addition to the histamine type leakage. Local release of vasoactive substances is supposed to be a common factor in the vascular effects of edible oil and Na-deoxycholate.

In acute pancreatitis, vasoactive substances may be formed in the pancreas (FORELL, 1955; HOLLENBERG et al., 1962; THAL et al., 1963; KATZ et al., 1964; RYAN et al., 1965; AMUNDSEN et al., 1968; OFSTAD, 1969; POPIERAITIS et al., 1969) which are known to increase local vascular permeability (ANDERSON et al., 1967) through a partial dissociation of the endothelium (COTRAN et al., 1964, ZWEIFACH, 1964, 1965; WILHELM, 1965).

Bile or bile salts injected into the pancreas were shown to cause direct injury of the acinar cells by surface activity (WANKE et al., 1966; WANKE, 1968; SUM et al., 1970). There was reason to suppose that bile salts would cause a direct impairment also of the endothelium (COTRAN, MAJNO, 1964).

As no literary data have been available on the nature of the structural damage of pancreatic vessels in acute pancreatitis, changes of the permeability and ultrastructure of pancreatic vessels were examined in acute pancreatitis of pigeons induced by intraductal administration of edible oil or sodium deoxycholate.

Material and methods

In 16 pigeons, weighing 400—500 g, under ether anaesthesia the pancreatic gland was exposed from an abdominal incision. Into the ventral lobe of the pancreas was injected through the excretory duct commercial sunflower oil, or 1% Na-deoxycholate solution in Tris-HCl buffer, or physiological saline, each in a 0.1—0.2 ml dose without controlled pressure. In a fourth group of pigeons the pancreas was left intact. Each experimental group consisted of 4 pigeons. To visualize vascular leakage the birds in each group were given intravenously 2 ml/100 g body weight of colloidal iron solution (Ferrlecit, Natterman, Köln) (STAUBESAND, 1963; JELLINEK et al., 1969); one bird received the iron simultaneously with the abdominal incision, while the other 3 birds received it 2 hours later. One hour after the injection of iron i.e. at 1 and 3 hours after the abdominal incision, the birds were anaesthetized with ether.

Pancreatic lobes treated and not treated (dorsal lobe) with oil from one and the same bird were placed in saturated $CuSO_4$ solution for a few minutes (Benda reaction). Into the pancreatic arteries of the other birds a polyethylene cannula was tied (PAPP, 1970) and through this cannula the vascular system of the gland was washed with a 2% isotonic neutral formalin solution of 3—4°C temperature (HOLT et al., 1961) at a pressure of 100—130 mm Hg. Subsequently the pancreas was fixed *in situ*, in 1.5% glutaraldehyde solution of 3—4°C temperature. Part of the specimens secured from the fixed pancreas were postfixed in neutral formalin for 24 hours, embedded in paraffin and cut into sections which were stained with haematoxylin and eosin or subjected to the Prussian-blue reaction for the light microscopic detection of colloidal iron tracer. The other part of pancreas specimens was fixed in 1.5% glutaraldehyde of 4°C for 2 hours, for electron microscopic examination. Subsequently, they were immersed in phosphate buffer for 24 hours, postfixed in 1% osmium tetroxide buffered according to MILLONIG (1961), and finally embedded in Araldite.

After the removal of Araldite semi-thin sections were made and stained with toluidine blue or subjected to the Prussian-blue reaction (IMAI et al., 1968). Light microscopic examination of this material allowed the selection of damaged vascular wall portions for the orientation of sectioning for electron microscopy. Ultra-thin sections, prepared with LKB III Ultratome, were stained with lead citrate and uranyl acetate. The micrographs were prepared with a JEM 6AS electron microscope.

Results

In normal untreated pancreatic gland's specimens, light microscopic examination of the Prussian-blue reaction showed the absence of the colloidal iron tracer from the walls of small arteries and veins and large elastic arteries (Fig. 1). Electron microscopy showed few clumps of the tracer in the endothelium of pancreatic blood capillaries.

In the pancreatic glands treated with edible oil, acute pancreatic necrosis developed (Figs 2a, 2b). The associated changes of the acinar parenchyma will be reported elsewhere (PAPP et al., 1971). Under the light microscope the Prussian-blue reaction indicated the presence of iron tracer in the vessels and perivascular tissues (Fig. 3) and in the arteriolar walls (Fig. 4). In semithin sections the vascular structure appeared normal, with broadening of the media at sites (Fig. 7). The subintimal deposition of the tracer was clearly indicated by the Prussian-blue reaction (Fig. 8). Electron microscopy revealed open inter-endothelial junctions in the walls of arterioles, venules and capillary vessels, with deposition of clumps of the tracer in the patent junctions (Plate I). At sites the junctions opened only up to the adherent zonule (Plate I/a), the processes of the endothelial cells were drawn apart (Plate I/a), and here and there sac-like distensions between the processes (Plate I/e, f). The tracer substance was present interendothelially (Plate I/b) and also in the vesicles around the junctions (Plate I/c, d). In the muscular-type arteries there was gap formation and a large amount of homogenously distributed tracer substance appeared between the smooth muscle cells of the media (Plate II/a, b).

In the pancreas treated with sodium deoxycholate, extensive necrosis of the acinar parenchyma developed; on light microscopic examination the Prussian-blue reaction indicated the perivascular presence of the tracer sub-

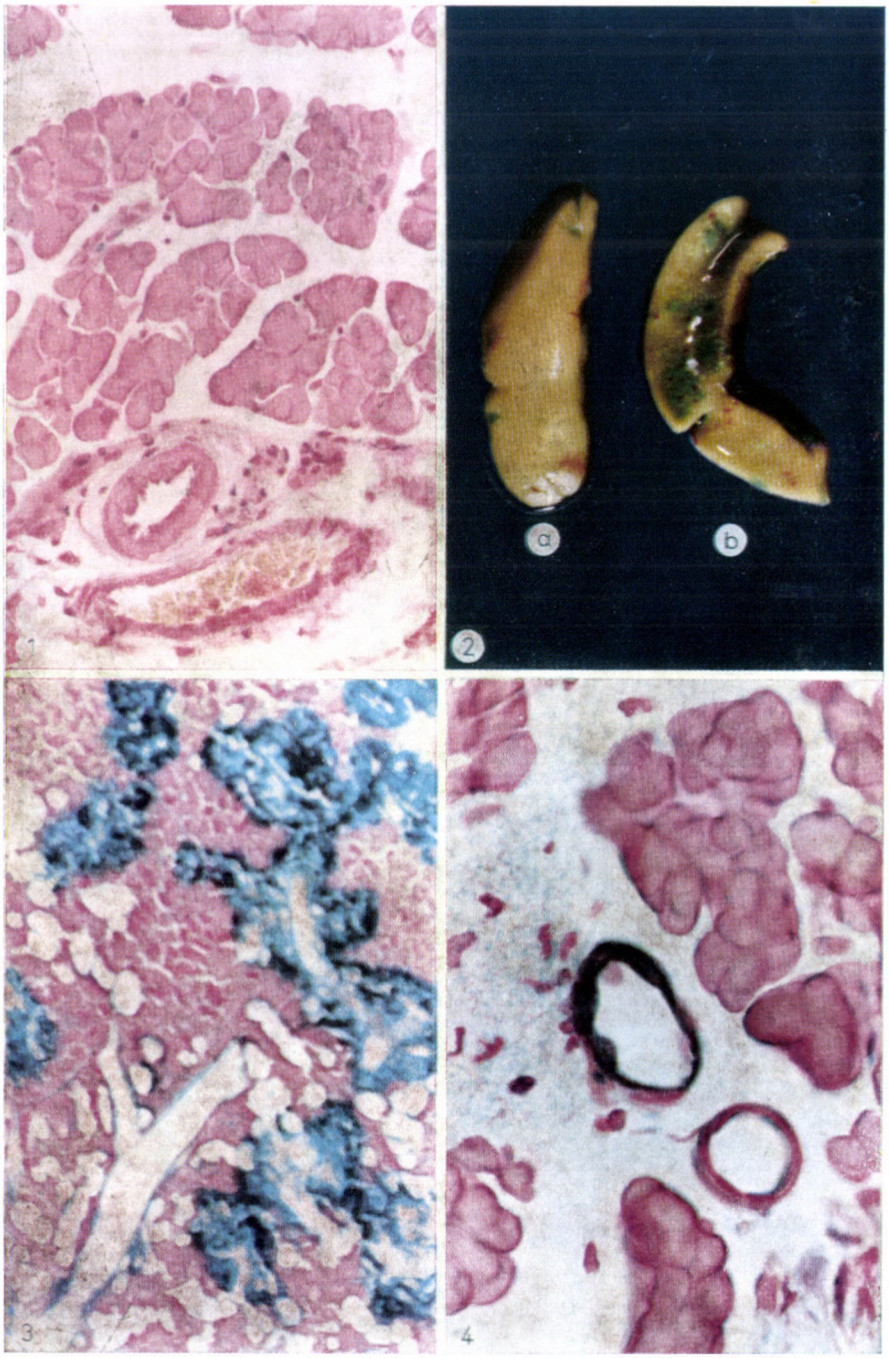

Fig. 1. Normal pancreas. The Prussian-blue reaction is negative in the vessel walls and also perivasculary. In the lumen of the vein there are red blood cells. × 200

Fig. 2. Oil-treated (b) and normal untreated pancreatic lobe (a) from one and the same pigeon. On the surface of the oil-treated lobe the necrotic area is green-coloured (Benda reaction). × 1

Fig. 3. Pancreas 3 hours after treatment with edible oil. The excretory ductules are distended and dissolved oil droplets left round impressions in the acinar parenchyma. The Prussian-blue reaction is positive in the perivascular area. × 160

Fig. 4. Pancreas 3 hours after treatment with edible oil. Note distended arteriole and vein between the acini. Positive Berlin-blue reaction in vascular wall and perivascular area. × 280

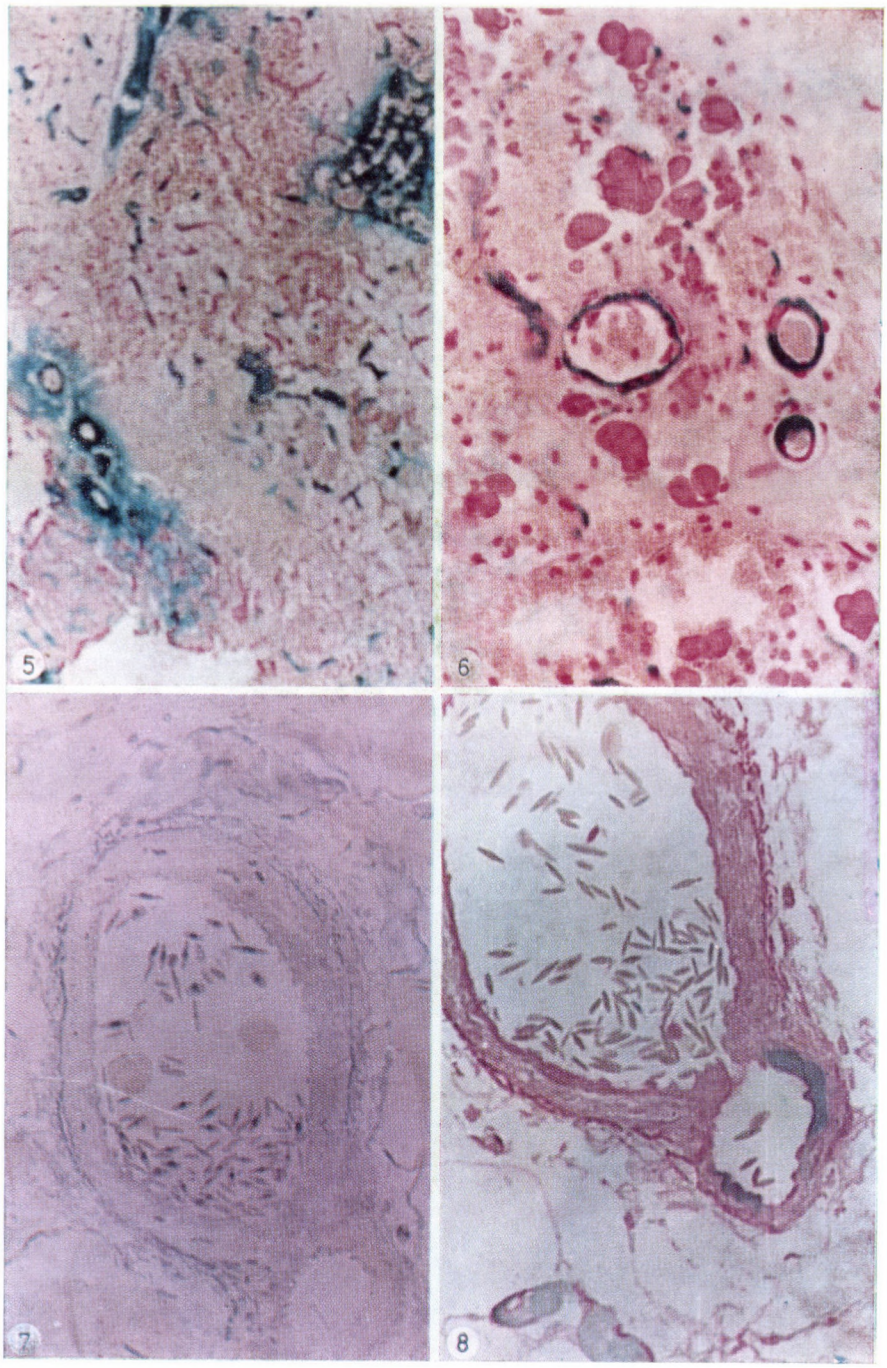

Fig. 5. Pancreas 3 hours after treatment with Na-deoxycholate. Positive Prussian-blue reaction in perivascular area. Extravasated red blood cells. × 160

Fig. 6. Pancreas 3 hours after treatment with Na-deoxycholate. The acinar structure is disorganised. The walls of arterioles, veins and capillaries show a. positive Prussian-blue reaction. × 240

Figs 7, 8. Semi-thin sections (Pancreas treated with edible oil)

Fig. 7. The vascular structure appears normal with broadening of the med. ai. at sites. × 520

Fig. 8. The subintimal deposition of the tracer is clearly indicated by the Prussian-blue reaction. × 530

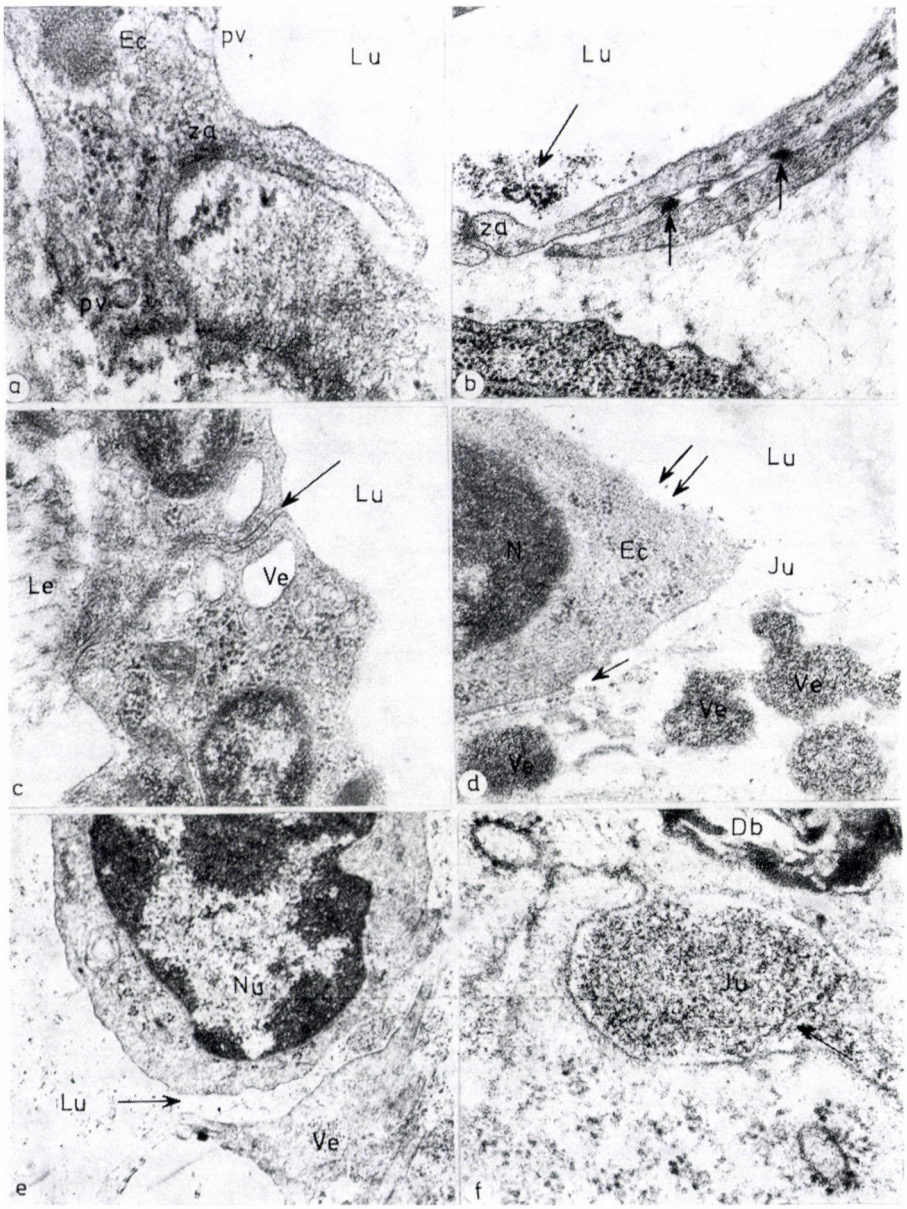

Plate I

Pancreas treated with edible oil (1 hour). The electron micrograph of a small arteriole and blood capillaries shows tracer clumps (↑) in the distended interendothelial junctions (Ju) and in the pinocytotic vesicles (pv). *a)* The interendothelial junction distended up to the adherent zonula (za) comprises particles of tracer substance (× 62 000). *b), e)* Tracer material in vascular lumen (Lu) and subendothelial space (*b* = × 54 000; *e* = × 28 000). *c), d)* Large vesicles (Ve) filled with tracer substance *(d)* in the surroundings of junctions *(c, d)* (*c* = = × 84 000; *d* = × 35 000). *f)* Tracer substance in patent inter-endothelial junction (× 72 000). Ec = endothelial cell; Nu = nucleus; Db = dense body; Le = elastic lamina; ↑↑ = injured endothelial cells

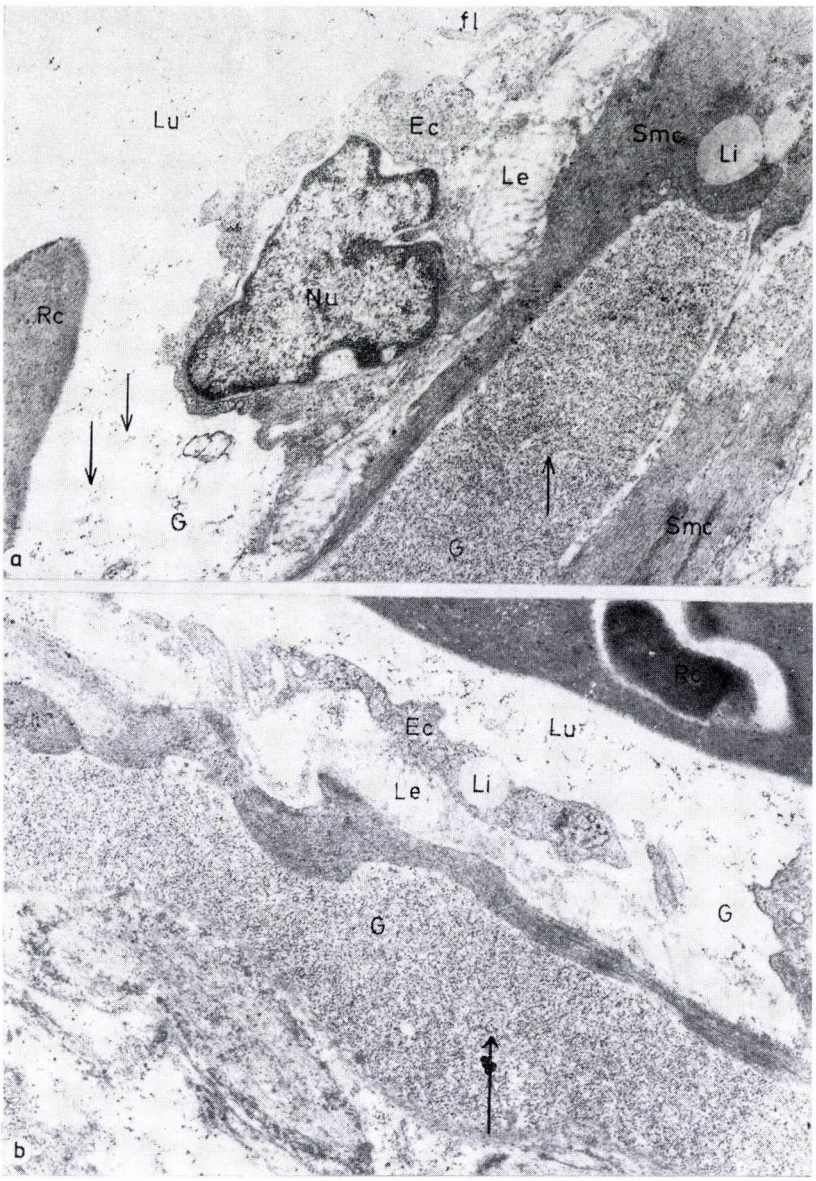

Plate II

Pancreas treated with edible oil (3 hours). Clumps of tracer substance (↑) in the wall of the small artery and in the gaps (G) between the rounded up endothelial cells (Ec) and smooth muscle cells (Smc). The vascular lumen (Lu) contains red blood cells (Rc) and clumps of tracer substance. (*a* = × 19 000; *b* = × 22 000). Nu = nucleus; Li = lipid droplets; Le = elastic lamina; fl = flap

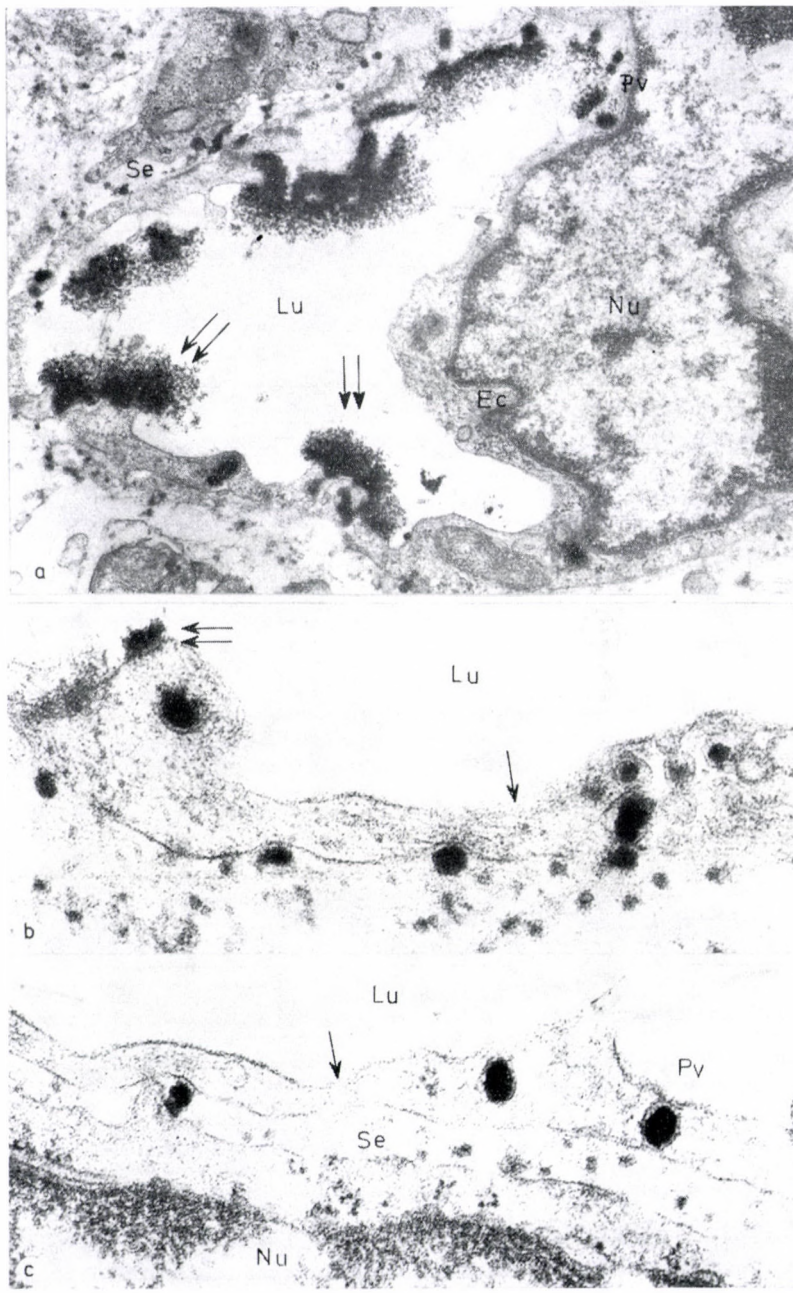

Plate III

Pancreas treated with Na-deoxycholate (1 hour). *a)* Clumps of precipitated iron tracer (↑↑) along the luminal surface (Lu) of the endothelium of a capillary vessel (Ec) and in the subendothelial space (Se) (× 30 000). *b), c)* The tracer deposited along the surface is transported into the subendothelial space by pinocytotic vesicles (Pv). There are tracer clumps in the endothelial cytomembranes (↑↑) (× 84 000). Nu = nucleus

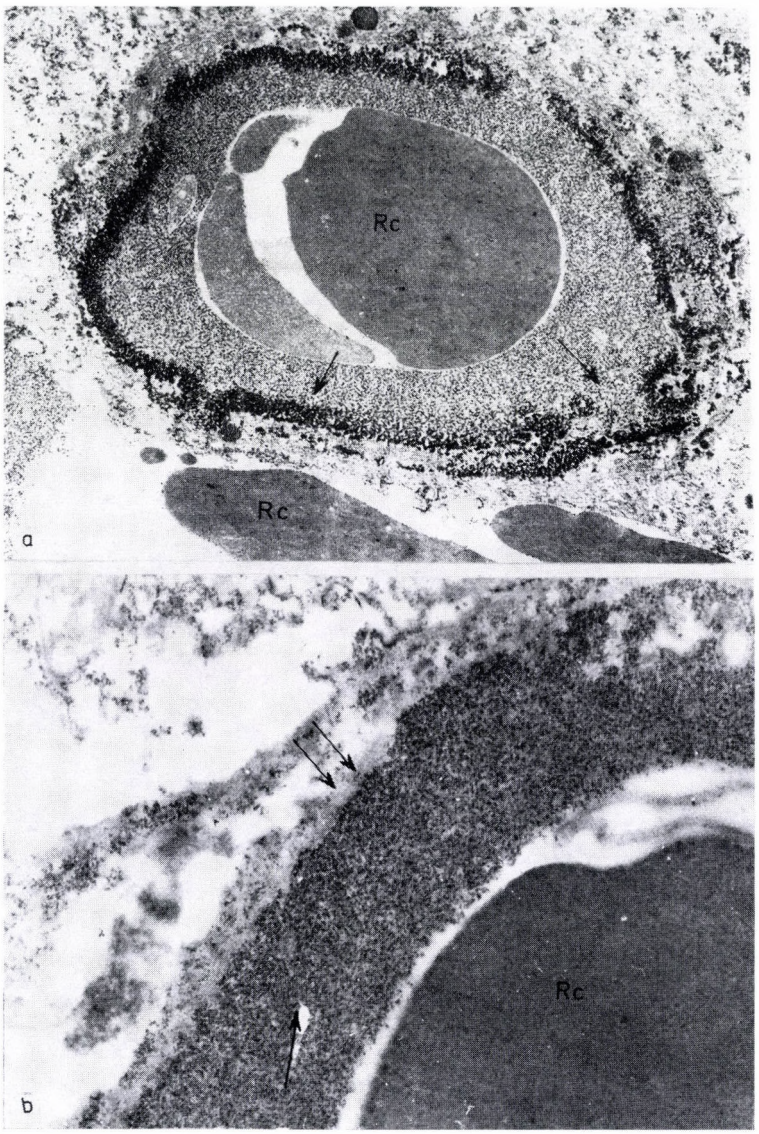

Plate IV

Pancreas treated with Na-deoxycholate (3 hours). *a)* The injured endothelium has been replaced by tracer substance (↑) in ring-like fashion. The vascular lumen contains tracer substance and red blood cells (Rc) (× 21 000). *b)* Part of injured capillary wall (not counterstained). Note retention of tracer substance (↑) by the basement membrane (↑↑) (× 30 000)

stance (Fig. 5). In semi-thin sections, not only the walls of blood capillaries and veins, but also those of the muscular-type small arteries showed the Prussian-blue reaction, as if the vascular walls were soaked with the tracer flowing around the endothelial and smooth muscle cells. There was a marked

extravasation of red blood cells (Fig. 6). In the endothelial cells, electron micrographs revealed the presence of vesicles containing considerable amounts of tracer substance and showing different phases of vesicular transport (Plate III/b, c). At sites a confluent precipitate of tracer substance was seen on the surface of the affected endothelial cells (Plate III/a). At other sites, the tracer was seen in the necrotized endothelial cells and, being retained by the basement membrane as by a barrier, surrounding the blood capillaries in a ring-like pattern (Plate IV/a). Retention of tracer substance within the vascular wall by the basement membrane was clearly apparent also in not counter-stained preparations (Plate IV/b).

Discussion

Deposition of tracer substance in, or its passage across, the vascular wall suggests a notable increase in vascular permeability (MAJNO et al., 1961; COTRAN et al., 1964; ROWLEY, 1964). It is known that normally very little or no tracer substance can pass across the vascular wall. In acute pancreatitis induced with edible oil, an increase in vascular permeability was demonstrated by means of colloidal iron tracer substance. The vascular leakage was of the histamine type (COTRAN et al., 1964) in that the interendothelial junctions had opened up and gaps had formed in the vascular wall.

An increase in vascular permeability was noted also in Na-deoxycholate-induced acute pancreatitis. Ultrastructurally, in addition to the histamine type vascular leakage (COTRAN et al., 1964), the increased transendothelial transport of the tracer by vesicles suggested the occurrence of another type of vascular leakage, related to the direct impairment of the vessel wall (COTRAN et al., 1964). Direct endothelial damage resulted first in tracer precipitation along the luminal surface of the endothelium; upon deterioration of the latter the tracer had advanced up to the basement membrane which retained it within the vessel wall. Direct vascular impairment was suggested also by an extravasation of considerable amounts of red blood cells.

The early endothelial damage in the pancreatic capillary vessels upon the intraductal injection of bile salts was noted also by others (DOERR et al., 1965; WANKE, 1968) without, however, giving consideration to the type of vascular leakage. In both oil-induced and Na-deoxycholate-induced increase of vascular permeability, the local release of vasoactive substances may have been a common factor. The same was suggested by the increase of vaso-active substances in the blood upon intraductal administration of bile (THAL et al., 1963; OFSTAD, 1969, 1970). Injection of bile into the pancreas through Santorini's duct produced an immediate temporary increase in flow in the superior pancreatico-duodenal artery (MALLET-GUY et al., 1971) and, in

due course, in the amount of blood drained by the pancreatico-duodenal vein (EGDAHL, 1958). Injection of vasoactive polypeptides, histamine or serotonin, into the pancreatico-duodenal artery had similar effects (PAPP et al., 1967). From the above it follows that the vascular response to tissue injury of the pancreas does not differ from that of the skin, where tissue injury increases local blood flow and vascular leakage (ASCHHEIM et al., 1961; SPECTOR et al., 1964, 1965; ZWEIFACH, 1965).

REFERENCES

1. AMUNDSEN, E., OFSTAD, E., HAGEN, P. O.: (1968) Experimental Acute Pancreatitis in Dogs I. Hypotensive Effect Induced by Pancreatic Exudate. Scand. J. Gastroent. **3,** 659—664. — 2. ANDERSON, M. C., SCHOENFELD, F. B., IAMS, W. B., SUWA, M.: (1967) Circulatory Changes in Acute Pancreatitis. Surg. Clin. N. Amer. **47,** 127—140. — 2/a. ASCHHEIM, E., ZWEIFACH, B. W.: (1961) Kinetics of Blood Protein Leakage in Inflammation. Circ. Res. **9,** 349—357. — 3. COTRAN, R. S., MAJNO, G.: (1964) A Light and Electronmicroscopic Analysis of Vascular Injury. Ann. N. Y. Acad. Sci. **116,** 750—764. — 4. DOERR, W., DIEZEL, P. B., GRŐZINGER, K. H., LASCH, H. G., NAGEL, W., ROSSNER, J. A., WANKE, M., WILLIG, F.: (1965) Pathogenese der experimentellen autodigestiven Pankreatitis. Klin. Wschr. **43,** 125—136. — 5. EGDAHL, R. H.: (1958) Mechanism of Blood Enzyme Changes Following the Production of Experimental Pancreatitis. Ann. Surg. **148,** 389—393. — 6. FORELL, M. M.: (1955) Zur Frage des Entstehungsmechanismus des Kreislaufkollapses bei der akuten Pankreasnekrose. Gastroenterologia (Basel) **84,** 225—251. — 7. HOLLENBERG, M., KOBOLD, E. E., PRUETT, R., THAL, A. P.: (1962) Occurrence of Circulating Vasoactive Substances in Human and Experimental Pancreatitis. Surg. Forum **13,** 302—304. — 8. HOLT, S. I., HICKS, R. M.: (1961) Studies on Formalin Fixation for Electron Microscopy and Cytochemical Staining Purposes. J. Biophys. Biochem. Cytol. **11,** 31—46. — 9. IMAI, Y., SUE, A., YAMAGUCHI, A.: (1968) A Removing Method of the Resin from Epoxy-embedded Sections for Light Microscopy. J. Electr. Micr. **17,** 84. — 10. JELLINEK, H., NAGY, Z., HÜTTNER, I., BÁLINT, A., KÓCZÉ, A., KERÉNYI, T.: (1969) Investigations of the Permeability Changes of the Vascular Wall in Experimental Malignant Hypertension by Means of a Colloidal Iron Preparation. Brit. J. exp. Path. **50,** 13—16. — 11. KATZ, W., SILVERSTEIN, M., KOBOLD, E. E., THAL, A. P.: (1964) Trypsin Release, Kinin Production and Shock. Arch. Surg. **89,** 322—328. — 12. LEWIS, G. P.: (1960) Active Polypeptides Derived from Plasma Proteins. Physiol. Rev. **40,** 647—676. — 13. LEWIS, G. P.: (1964) Plasma Kinins and Other Vasoactive Compounds in Acute Inflammation. Ann. N. Y. Acad. Sci. **116,** 847—854. — 14. MAJNO, G., PALADE, G. E.: (1961) Studies on Inflammation. I. The Effect of Histamine and Serotonin on Vascular Permeability: an Electron Microscopic Study. J. Biophys. Biochim. Cytol. **11,** 571—606. — 15. MAJNO, G., PALADE, G. E., GUTTA, I., SCHOEFL, G. I.: (1961) Studies on Inflammation II. The Site of Action of Histamine and Serotonin Along the Vascular Tree: a Topographic Study. J. Biophys. Biochem. Cytol. **11,** 607—626. — 16. MALLET-GUY, P., PAPP, M., SWITALSKA, CH., UNGVÁRY, GY., VARGA, B.: (1971) Les modifications précoces du débit sanguin dans les pancréatites aiguës expérimentales. Lyon Chir. **67,** 87—23. — 17. MILLONING, G.: (1961) Advantages of a Phosphate Buffer for OsO_4 Solutions in Fixation. J. appl. Physics **32,** 1637. — 18. OFSTAD, E.: (1969) Formation and Destruction of Plasma Kinins During Experimental Hemorrhagic Pancreatitis in Dogs. Scand. J. clin. Labor. Invest. **24,** Suppl. **107,** 169—171. — 19. OFSTAD, E.: (1970) Formation and Destruction of Plasma Kinins During Experimental Acute Hemorrhagic Pancreatitis in Dogs. Scand. J. Gastroent **5,** Suppl. **5,** 1—44. — 20. PAPP, M.: (1970) About the acinar-enzymatic, vascular-inflammatory and interstitial-lymphatic components in the origin of acute pancreasnecrosis. Thesis, Budapest. — 21. PAPP, M., MAKARA, G. B., VARGA, B.: (1967) Effects de la bradykinine, de la kallidine, de la sérotonine, et de l'histamine sur le flux sanguin du pancréas. Arch. int. Pharmacodyn. **165,** 31—36. — 22. PAPP, M., NAGY, Z., FODOR I.: (1971) Ultrastructure of Pancreatic Acinar Parenchyma in Acute Experimental Pancreatitis of Pigeons. Acta Morphol. Acad. Sci. Hung. In press. — 23. POPIERAITIS, A. S., THOMPSON, A. G.: (1969) The Site of Bradykinin Release in Acute Experimental Pancreatitis. Arch. Surg. **98,** 73—76. — 24. ROWLEY, D. A.: (1964) Venous Constriction as the Cause of Increased Vascular Permeability Produced by 5-hydroxytriptamine, Histamine, Bradykinin and 48/80 in the Rat. Brit. J. exp. Path. **45,** 56—57. — 25. RYAN, J. W., MOFFAT, J. G., THOMPSON, A. C.: (1965) Role of Bradykinin System in Acute He-

morrhagic Pancreatitis. Arch. Surg. **91,** 14—24. — 26. SPECTOR, W. G., WILLOUGHBY, D. A.: (1964) Vasoactive Amines in Acute Inflammation. Ann. N. Y. Acad. Sci. **116,** 839—846. — 27. SPECTOR, W. G., WILLOUGHBY, D. A.: (1965) Chemical Mediators II. In: Microvascular Aspects of Tissue Injury. Zweifach, B. J., Grant, L., McCluskey, R. T. (Eds.) Pp. 427—448. Academic Press, New York. — 28. STAUBESAND, J.: (1963) Zur Histophysiologie des Herzbeutels. II. Mitteilung. Elektronenmikroskopische Untersuchungen über die Passage von Metallsolen durch mesotheliale Membranen. Z. Zellforsch. **58,** 915—952. — 28/a. SUM, P. T., BENCOSME, A., BECK, I. T.: (1970) Pathogenesis of bile-induced acute pancreatitis in the dog: experiments with detergents. Amer. J. Dig. Dis. **15,** 637—646. 29. THAL, A. P., KOBOLD, E. E., HOLLENBERG, M. J.: (1963) The Release of Vasoactive Substances in Acute Pancreatitis. Amer. J. Surg. **105,** 708—713. — 30. WANKE, M.: (1968) Experimentelle Pankreatitis. Proteolytische, lipolytische und biliäre Form. Thieme, Stuttgart. — 30/a. WANKE, M., NAGEL, W., WILLIG, F.: (1966) Formen der experimentellen Pankreatitis patho-anatomisch gesehen. Frankfurt. Z. Pathol. **75,** 207—221—31. WILHELM, D. L.: (1965) Chemical Mediators I. In: Microvascular Aspects of Tissue Injury. Zweifach, B. J., Grant, L., McCluskey, R. T. (Eds.) Academic Press, New York, Pp. 389—425. — 32. ZWEIFACH, B. W.: (1964) Microcirculatory Aspects of Tissue Injury. Ann. N. Y. Acad. Sci. **116,** 831—838. — 33. ZWEIFACH, B. W.: (1965) Microvascular Aspects of Tissue Injury. In: Microvascular Aspects of Tissue Injury. Zweifach, B. J., Grant, L., McCluskey, R. T. (Eds.) Academic Press, New York, Pp. 161—196.

VON ÖL ODER NATRIUM-DEOXYCHOLAT HERVORGERUFENE MIT AKUTER PANKREATITIS EINHERGEHENDE GEFÄßSCHÄDIGUNG

Z. NAGY, M. PAPP und A. BÁLINT

Durch intraduktale Injektion von Sonnenblumenöl oder Natriumdeoxycholat wurde bei Tauben eine akute Pankreatitis hervorgerufen. Zur Veranschaulichung der Gefäßpermeabilität erhielten die Vögel intravenös eine kolloide Eisenlösung, welche mit einer Preussischblau-Reaktion bestimmt wurde. Eine Erhöhung der Gefäßpermeabilität wurde in beiden Fällen durch Öl und durch Natriumdeoxycholat induzierter akuter Pankreatitis nachgewiesen. Bei der durch Öl induzierten Pankreatitis gehörte die Erhöhung der Gefäßpermeabilität zum Histamintyp. Bei der durch Natriumdeoxycholat induzierten Pankreatitis trat die direkte Gefäßschädigung zu der Permeabilitätserhöhung vom Histamintyp hinzu. Das lokale Freiwerden von vasoaktiven Stoffen ist wahrscheinlich ein gemeinsamer Faktor der Wirkung von Speiseöl und Natriumdeoxycholat.

ВЫЗЫВАЕМОЕ РАСТИТЕЛЬНЫМ МАСЛОМ ИЛИ ДЕЗОКСИХОЛАТОМ НАТРИЯ СОСУДИСТОЕ ПОРАЖЕНИЕ, СОПРОВОЖДАЮЩЕЕСЯ ОСТРЫМ ПАНКРЕАТИТОМ

З. НАДЬ, М. ПАПП и А. БАЛИНТ

Внутрипроточным введением подсолнечного масла или дезоксихолата натрия был вызван у голубей острый панкреатит. Для выявления проницаемости сосудов птицам внутривенно вводился коллоидный раствор железа, который был определен реакцией с прусской синькой. В обоих случаях острого панкреатита, индуцированного введением растительного масла и дезоксихолата натрия, было выявлено повышение проницаемости сосудов. При индуцированном растительным маслом панкреатите повышение сосудистой проницаемости принадлежало к гистаминовому типу. При индуцированном дезоксихолатом натрия панкреатите к повышению проницаемости сосудов гистаминового типа присоединилось таковое, вызванное прямым поражением сосудов. Местное освобождение вазоактивных веществ, вероятно, совместный фактор при действии растительного масла и дезоксихолата натрия.

Dr. Zoltán NAGY
Dr. Miklós PAPP
Dr. András BÁLINT
Budapest VIII., Szigony u. 43, Hungary

Acta Morphologica Acad. Sci. Hung. 19 (2), pp. 187—201, 1971

Second Institute of Pathology (Director: Prof. H. JELLINEK), Semmelweis Medical University, Budapest

VASCULAR CHANGES IN SMALL AND LARGE ARTERIES IN RAPID HYPERTENSION AS AN ATHEROSCLEROSIS PROVOKING FACTOR

H. JELLINEK

(Received December 11, 1970)

A study of atherosclerosis associated with rapid hypertension has been made. Acute hypertensive vascular changes appear to constitute the initial phenomenon in chronic arteriosclerosis. The development of acute lesions depends mainly on the degree of the acute damage, and the type of fibrinoid (subendothelial or medial) depends on the tissular structure of the vessel wall. These factors and the subsequent cell proliferation give rise to a musculo-elastic intimal thickening equivalent to atherosclerosis. The subendothelial fibrinoid transforms into a hyaline, lipid-containing lesion of the atherosclerotic type. The appearance of lipids is secondary and plays no role in the development of the vascular lesions.

It is generally accepted that atherosclerosis is initiated by several processes rather than a primary factor [1, 2]; actually, the condition appears to represent the end-product of a complex disease. Of the factors possible involved in the combination of pathologic processes leading to atherosclerosis psychic and nervous effects, hormonal disorders, anomalies of lipid metabolism, infectious and allergic processes have been studied in detail. All these factors have been shown to induce in the vessel wall the degenerative and proliferative changes characteristic of atherosclerosis. Many authors are of the opinion that both human and experimental hypertension may promote or intensify the atheromatous changes [3—6].

We have studied the pathogenesis of human and experimental vascular disease for more than a decade. Among others, we have shown that factors of different nature induced vascular lesions of identical morphology in humans as well as in experimental animals [7].

Extensive studies on more than 1500 animals with experimental renal hypertension, revealed certain relationships of hypertensive vascular lesions and atherosclerosis [8—28]. The pathomechanism of the hypertensive vascular change seems to be poorly understood; some new information emerging from our studies is therefore presented in this paper.

The pathogenesis of hypertensive vascular changes was found to be identical in small, medium-size and large arteries. Nevertheless, the progression and severity of the changes depended largely on the structure of the affected vessel.

Lesions consisting of various stages of fibrinoid necrosis were most typical in the small vessels. The first microscopic change seen in the initial phase of the hypertensive condition was a necrosis of the smooth muscle cells in the media. The necrotic cells stained black with Mallory's phosphotungstic acid haematoxylin (PA) and red with PAS; on polarisation optical examination they showed an increased birefringence after aniline reaction (Figs 1, 2). Electron-microscopically, a pale swollen type and an osmiophilic dark type of necrotic muscle cell could be distinguished (Fig. 3). GARDNER [29] postulated that the initial muscle cell necrosis was preceded by a morphologically undetectable prenecrotic phase consisting of certain biochemical processes.

Simultaneously with the muscle cell necrosis, the vascular wall developed a tendency to imbibe and accumulate blood plasma. Initially, this change may not be readily visualized. It seems, nevertheless, to constitute a prelude to the prenecrotic process (Fig. 4) which initiates the necrosis of muscle cells.

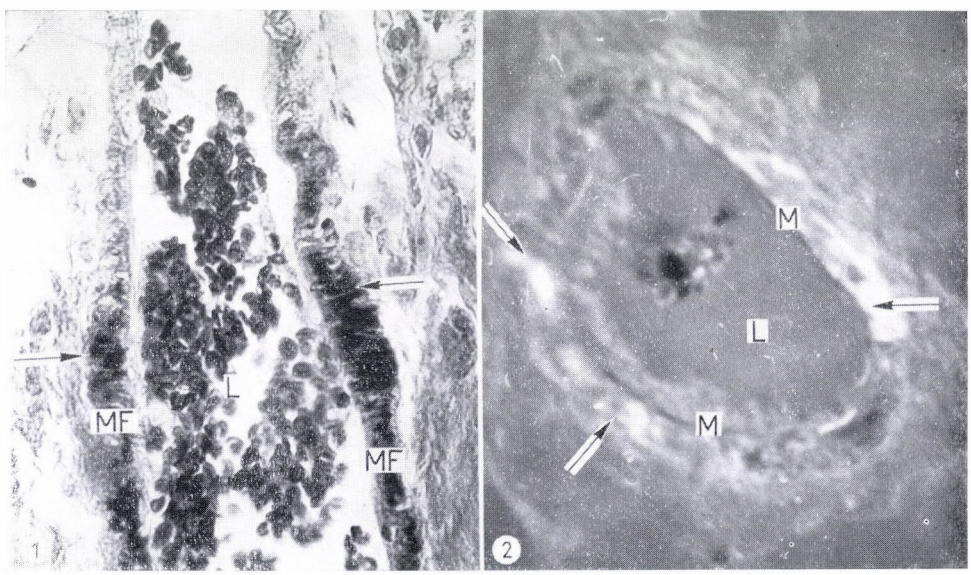

Fig. 1. Small artery with lamellar elastic membrane. Note necrotic muscle cells (arrows) in the media (media fibrinoid (MF)) typical of acute hypertension. L: vascular lumen. Mallory's phosphotungstic acid haematoxylin dye (PTA)

Fig. 2. Increased birefringence of necrosed muscle cells (arrows) in polarized light, after aniline reaction. The dark internal elastic membrane (M) is clearly seen. There is no birefringence in the subendothelial space. L: vascular lumen

Blood plasma accumulated in the vascular wall gives rise to the typical lesion known as fibrinoid necrosis [12, 30—35]. At this stage the vascular fibrinoid stains characteristically red with Azan and black with PTA (Fig. 5).

The consequences of muscle cell necrosis and the penetration of plasma depend mainly on the anatomical structure of the vascular wall. In the small vessels, necrosis and penetration of plasma follow in rapid succession to form the typical vascular fibrinoid, while in vessels with a distinct internal elastic membrane, the process becomes divided into stages.

The internal elastic membrane temporarily blocks the passage of the penetrating plasma, thus the two components of the lesion evolve separately. The necrotic muscle cells in the media form the media fibrinoid and the plasma retained in the subendothelial space above the internal elastic membrane forms the subendothelial fibrinoid. These two forms of fibrinoid are clearly differentiated by PTA staining (Fig. 6) and their non-identity has been confirmed by their dissimilar polarisation optical, phase contrast and fluorescence microscopic properties as well [19, 23].

Segregation of the two components of vascular fibrinoid is the more pronounced, the stronger the vessel's internal elastic membrane. In large muscular arteries, as e.g. in the femoral artery, hypertensive accumulation of plasma is of extreme degree, but the strong resistant internal elastic membrane considerably limits its passage into the media. Thus in the large vessels the change is only partial by the time when the vascular fibrinoid has fully evolved in the small vessels. In the large vessels, muscle cell necrosis is also less pronounced (Fig. 7).

Simultaneously with an advanced stage of subendothelial fibrinoid formation in the femoral artery, aortic lesions are still of the early type. There are some small vacuoles in the

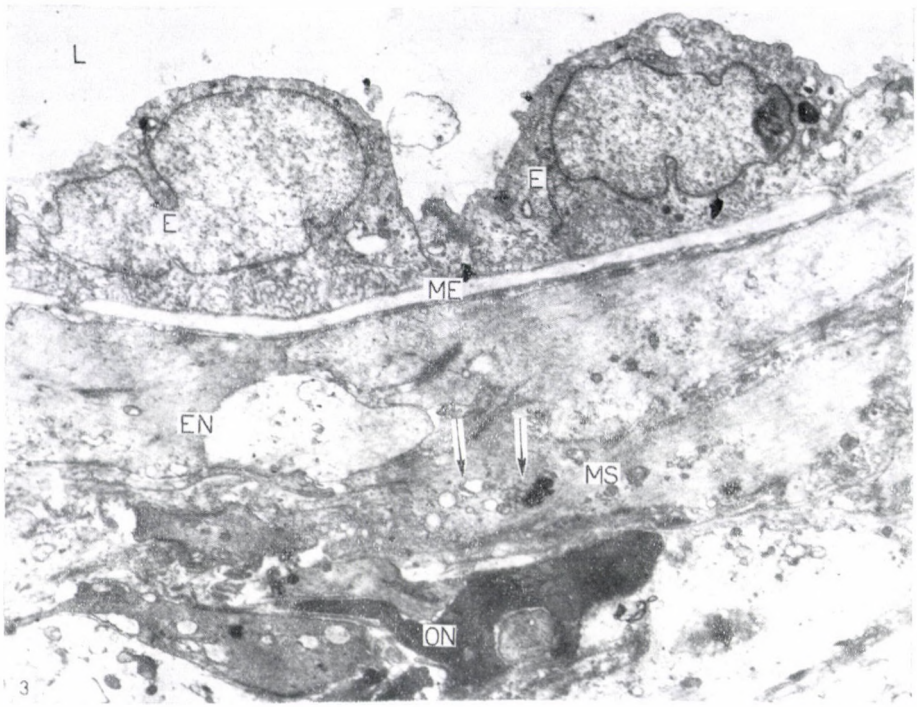

Fig. 3. Electron micrograph of a small artery. Endothelial cells (E) above the internal elastic membrane (ME). Note swollen pale cell necrosis (EN) and osmiophilic dark cell necrosis (ON) in the media. Some muscle cells (MS) of apparent structural integrity enclose cytoplasmic vacuoles and myeline figures (arrow). L: vascular lumen

aortic endothelial cells, subendothelium and smooth muscle cells (Fig. 8). Accumulation of plasma in the subendothelial space takes place subsequently and tends to progress (Fig. 9).

Apparently, the media fibrinoid and subendothelial fibrinoid represent the early phase of hypertensive vascular change.

Later, not only further progression of the lesions, but regenerative phenomena also occur. The three main alternatives of the further fate of the fibrinoid are as follow.

1. The subendothelial fibrinoid undergoes a hyaline transformation. In this phase, its original red staining with Azan changes into blue and its black staining with PTA into yellow (Fig. 10). Electronmicroscopically, this stage is marked by the appearance in the subendothelial space of bodies with a periodic structure [19] (Fig. 11) which may be responsible for the increased birefringence and altered staining properties. This is followed by a condensation process of hyaline during which the bodies with periodic structure successively lose their structure (Fig. 12) until the entire subendothelial hyaline deposit has assumed a homogeneous appearance in conventional micrographs, while electronmicroscopically it is found to contain myelin figures and lipid-like substances (Fig. 13). This is the final complex arterial lesion resulting from hypertensive vascular changes: from the subendothelial fibrinoid to hyaline formation.

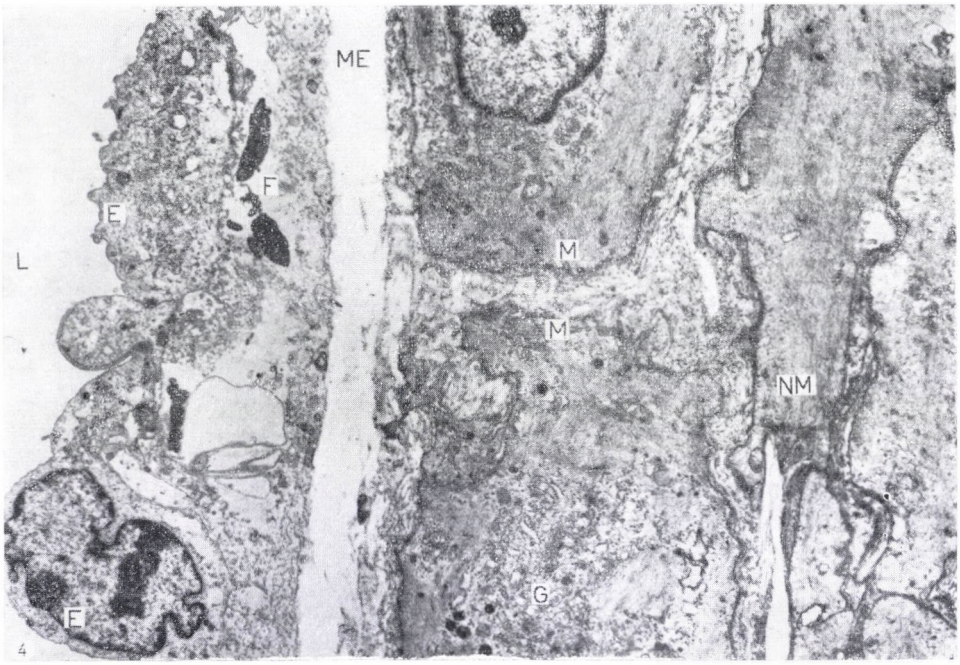

Fig. 4. Section from hypertensive aorta. Few fibrin clumps (F) in the subendothelial space. in the media the Golgi complexes (G) of the muscle cells (M) are enlarged. Perhaps it is this stage of the change which corresponds to the prenecrotic phase. ME: internal elastic membrane; NM: relatively normal muscle cells in the media; E = endothelial cells; L: lumen

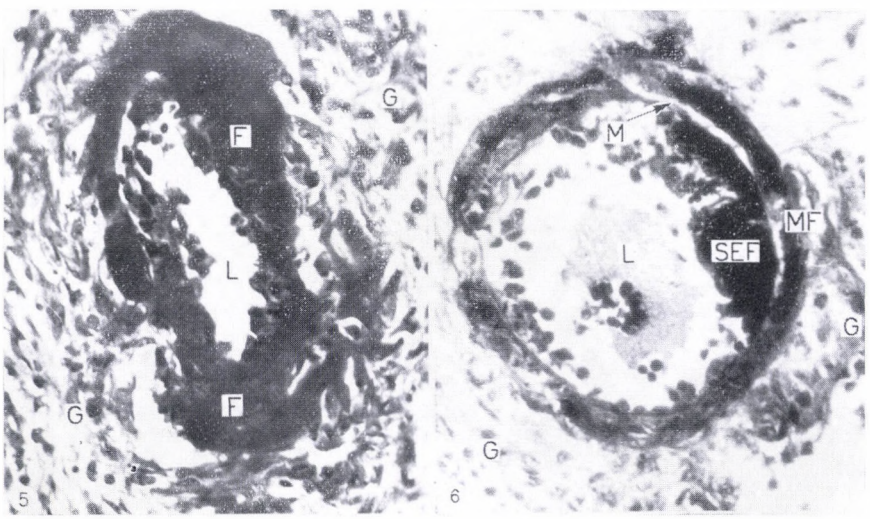

Fig. 5. Typical vascular fibrinoid (F) and perivascular granulation (G) arising from mural necrosis and of extravasated plasma within and outside the vessel wall. L: lumen. PTA stain
Fig. 6. The two components of the vascular fibrinoid in a small vessel with internal elastic membrane (M →). Subendothelial (SEF) and media fibrinoid (MF) are distinguishable on staining with PTA. G: perivascular granulation. L: vascular lumen

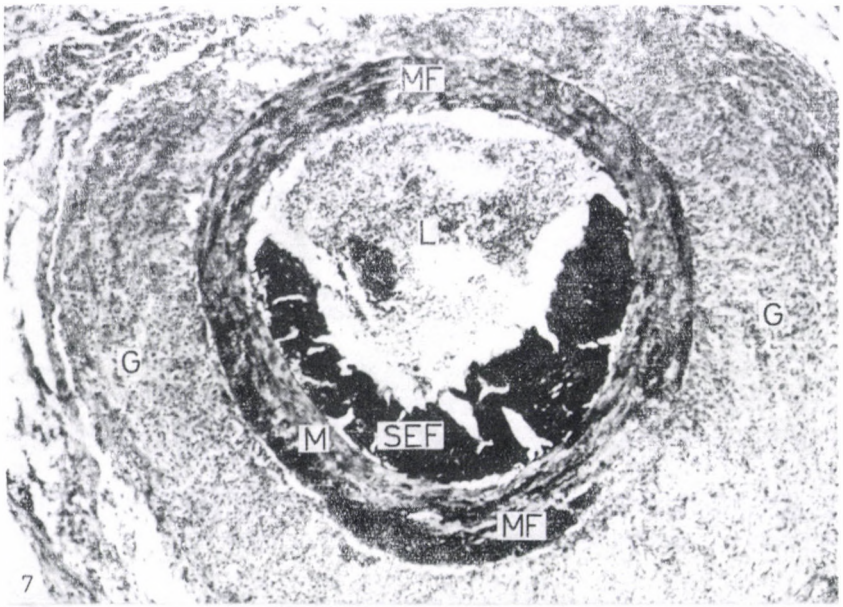

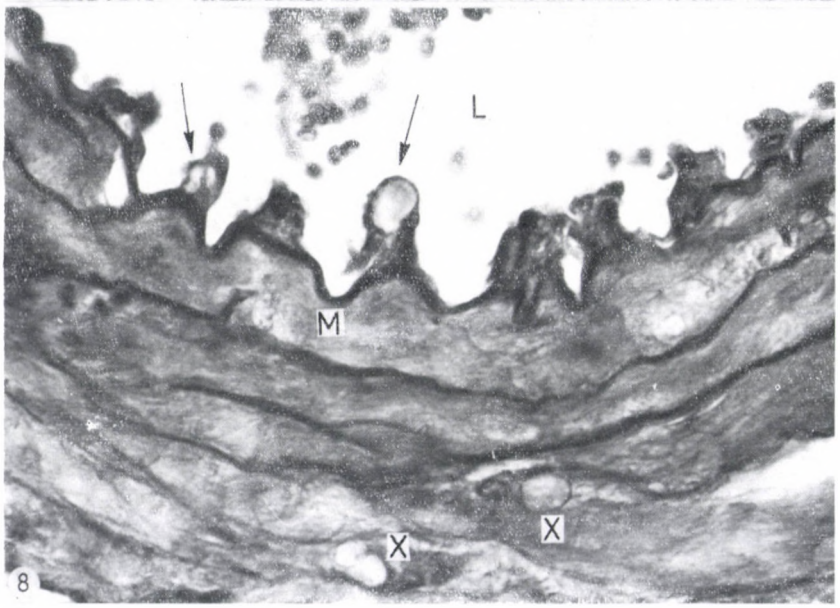

Fig. 7. Subendothelial fibrinoid (SEF) above the distinct internal elastic membrane (M) of a large muscular artery. A few necrotic muscle cells (MF) are present in the media. G: granulation; L: lumen. PTA stain

Fig. 8. Early hypertension. Part of the endothelial cells in the aortic wall surround large vacuoles (arrows) and protrude into the lumen (L) above the internal elastic membrane (M) like vacuoles. In the media there are a few vacuolized muscle cells (X). H-E stain

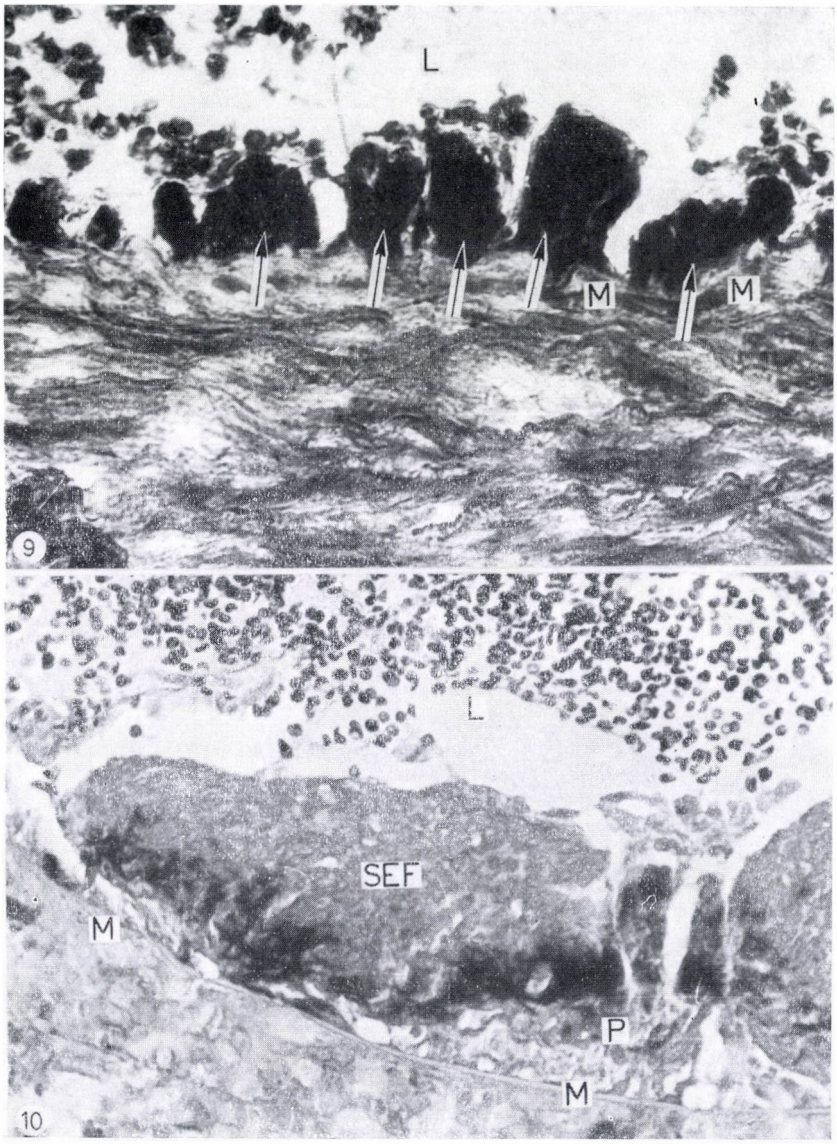

Fig. 9. Subendothelial fibrinoid (arrows) above the internal elastic membrane (M) of the aorta on the 70th day of experimental hypertension. The lesions stain black with PTA. L: vascular lumen

Fig. 10. The subendothelial fibrinoid (SEF) tends to lose affinity to PTA which is clearly seen in Fig. 8. PTA-positivity is now apparent only along the internal elastic membrane (M). The same phenomenon is observed on staining with Azan, when a gradual red to blue colour transformation occurs. P: slight intimal proliferation; L: lumen

2. Sometimes the subendothelial fibrinoid was phagocyted. This was often apparent in conventional micrographs and was verified by the presence of intracellular fibrin structures in electron micrographs (Fig. 14). With the progress of phagocytosis, the fibrinoid was replaced by proliferation which contained many foam cells (Fig. 15) and, as revealed electronmicroscopically, also muscle cells. Thus the subendothelial fibrinoid was replaced by intimal proliferation consisting of several cell rows.

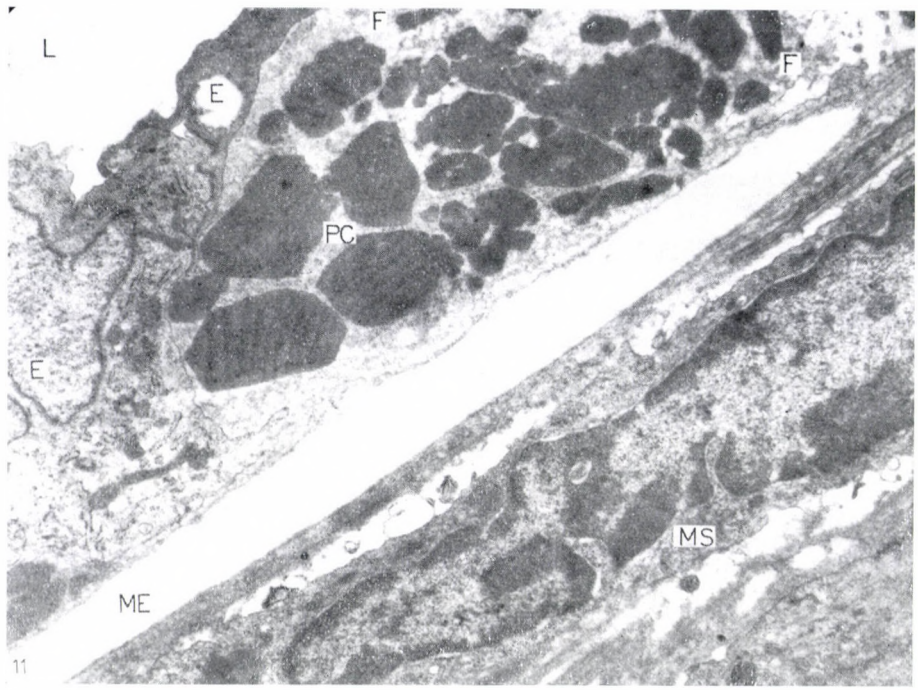

Fig. 11. Electron micrograph of small artery in acute hypertension. In the subendothelial space between the endothelial cells (E) and the internal elastic membrane (ME), fibrin-like (F) material and typical crystal-like bodies with periodic structure (PC) are apparent. L: lumen; MS: normal muscle cells in the media

3. If the damage to the media was slight, necrosis was limited to single smooth muscle cells and no subendothelial fibrinoid developed. The regression of the media fibrinoid gave rise to a proliferative process in the area corresponding to the media of small vessels. The proliferation resulted in a thickening of the intima (Fig. 16) and a consequent narrowing of the vascular lumen. Specific staining for elastic fibres revealed the presence of a newly formed elastic lamella [21, 28] which sometimes appeared to consist of several layers (Fig. 17).

Between the layers there were cells exhibiting the characteristic staining properties of smooth muscle cells. Their electron microscopic counterparts appeared as large, pale, undifferentiated cells and muscle cells.

The decisive role of the structure of the vascular wall in the nature of the change is illustrated in Fig. 18 which shows sections from different vessels of a rat after 60 days of hypertension. In the small arteries, the lesions brought about cicatrization, while in the large muscular artery the transformation of subendothelial fibrinoid into intimal proliferation is still in progress. In the aorta, subendothelial fibrinoid and single muscle cell necroses are seen. Thus the hypertensive vascular changes appear to depend mainly on the mural structure and the time factor.

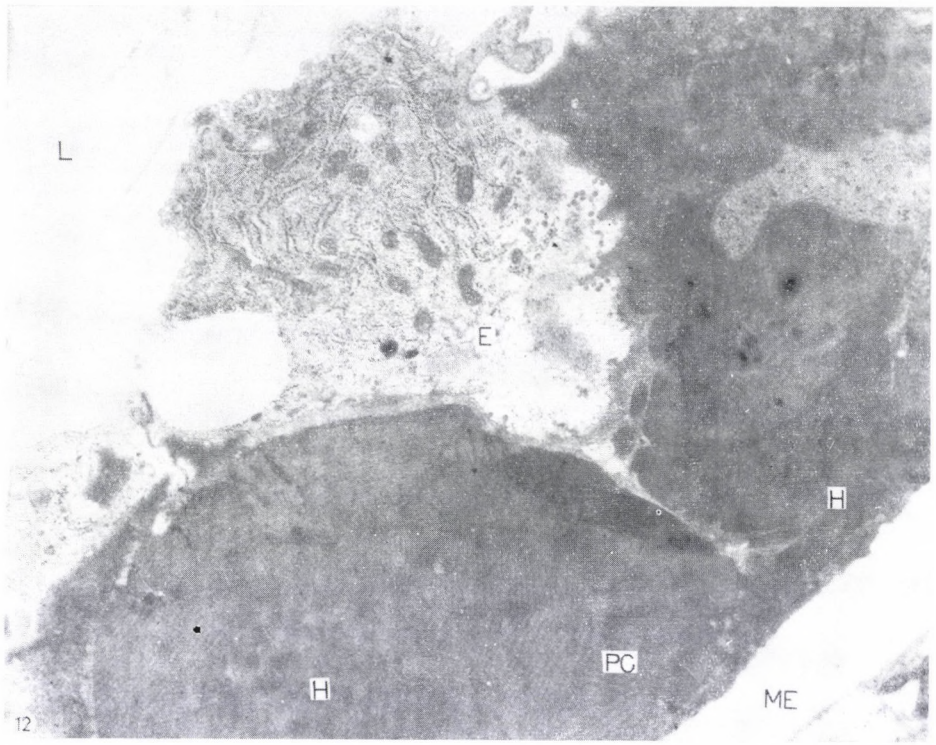

Fig. 12. Electron micrograph of a small artery in the advanced stage of hypertension. The crystalline bodies have closely approximated each other. The periodic structure (PC) tends to disappear, though it is still apparent in places. Finally, the lesion assumes a homogeneous, hyaline-like appearance (H). ME: internal elastic membrane; E: endothelial cell; L: lumen

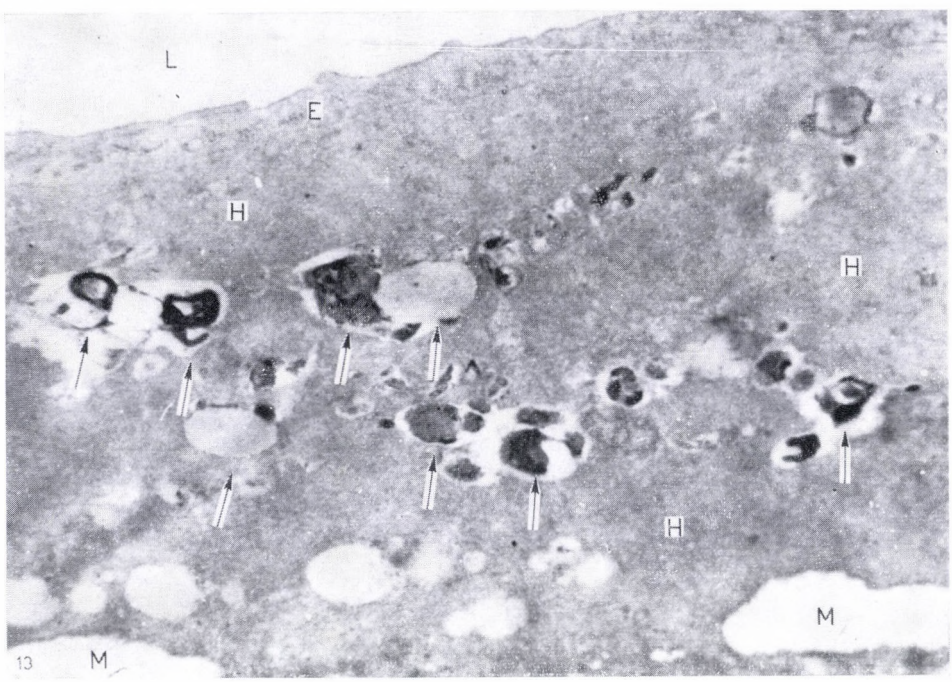

Fig. 13. Electron micrograph of subendothelial fibrinoid in the stage of staining blue with Azan. Above the internal elastic membrane (M) and between the row of endothelial cells (E) a homogeneous hyaline substance, lipid droplets and myelin figures (arrows) are seen. L: lumen

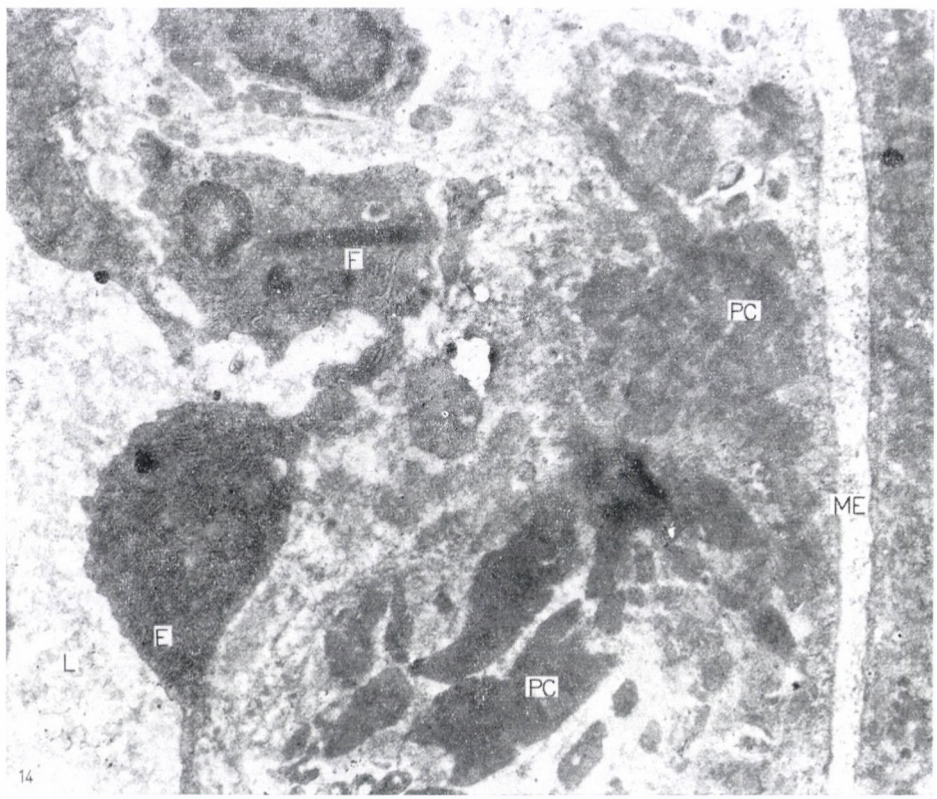

Fig. 14. Electron micrograph of subendothelial fibrinoid in the stage of staining red with Azan (small artery). Phagocytosis of the fibrinoid by cells from the proliferating intima has started: note the fibrin structure (F) within the phagocytes. PC: periodically structured bodies; ME: internal elastic membrane; E: endothelial cell; L: lumen

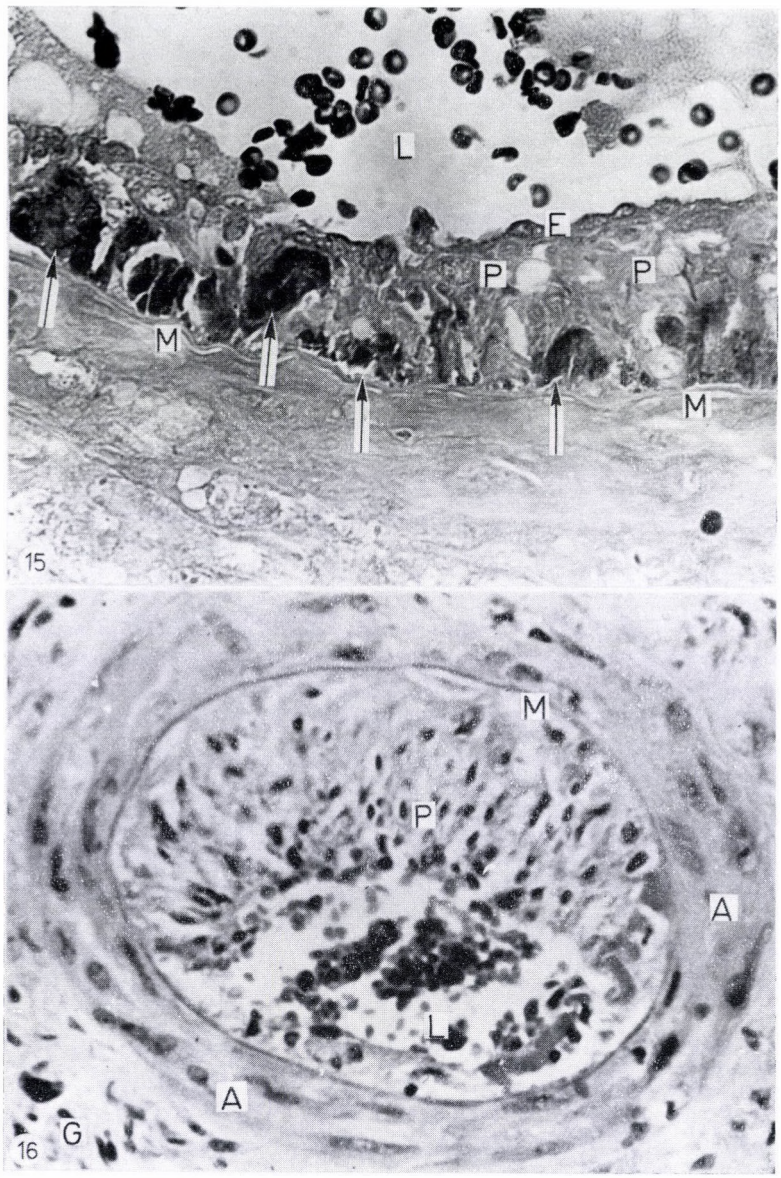

Fig. 15. Phagocytosis of subendothelial fibrinoid (arrows) in an elastic vessel in chronic hypertension. Phagocytosis is followed by endothelial (E) and muscle cell proliferation. Some of the cells have a foamy cytoplasm (at P). M: internal elastic membrane; L: lumen. Azan stain

Fig. 16. Chronic hypertensive changes in small artery. Note mitotic cells in the vessel wall (A) and proliferating cells (P) above the internal elastic membrane (M). L: lumen; G: granulation. H-E stain

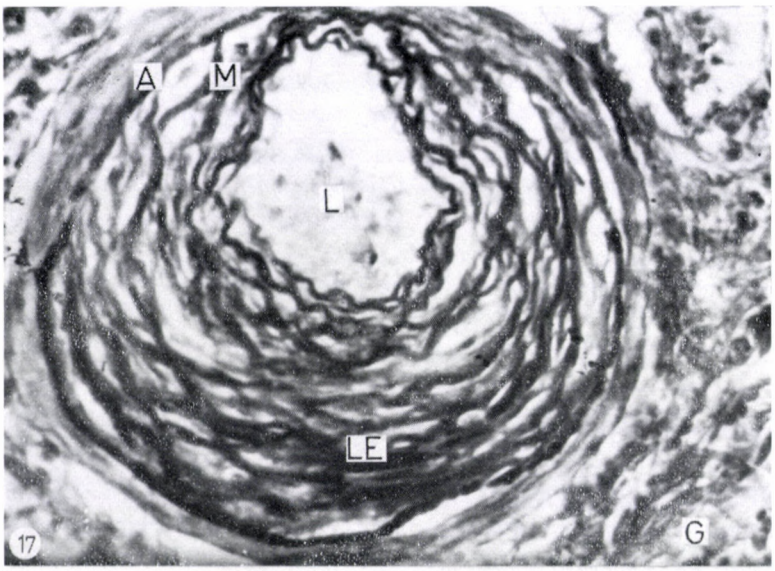

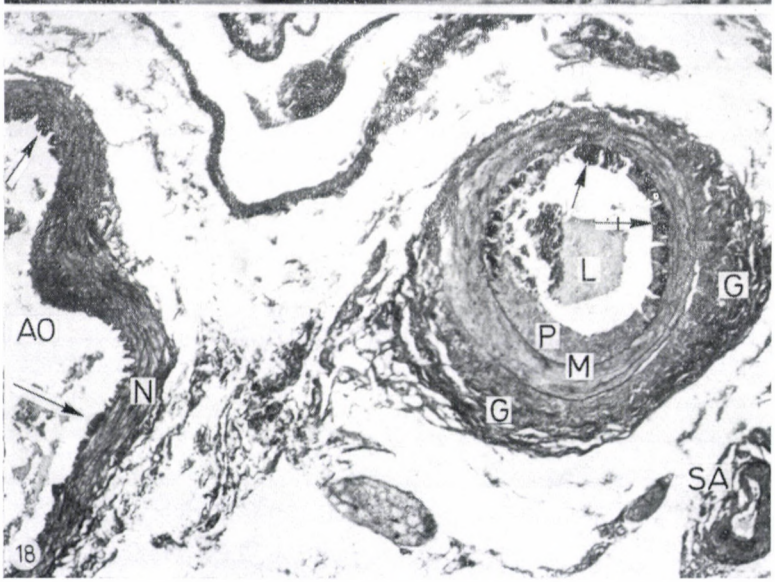

Fig. 17. Chronic hypertensive change in small artery. Multiple row of newly formed elastic membranes (LE) (lamellar elastosis) appear above the original internal elastic membrane (M). A: vessel wall; L: lumen; G: perivascular granulation. Resorcin-fuchsin-Van Gieson's stain

Fig. 18. Mural changes in different vessel types on the 70th day of experimental hypertension. Small artery (SA): part of the wall is undamaged, part of it is thickened and cicatrized. Large muscular artery (L): part of the subendothelial fibrinoid (arrow) is still seen with proliferating cells scattered along its surface (marked by arrow →); at P only a row of proliferating cells is seen above the internal elastic membrane (M). The vessel is surrounded by perivascular granulation (G). Aorta (AO) with some subendothelial fibrinoid (arrows) and occasional single muscle cell necrosis (N). PTA stain

Evaluation

It appears that the two morphological components of hypertensive vascular change, viz. subendothelial plasma deposit and muscle cell necrosis are decisive factors in the development of atherosclerosis. With either component, regeneration phenomena are preceded by a damage to the vascular wall [36] and this is the point where the nomenclatural dispute has arisen in respect of the characterization of the vascular fibrinoid. Certain authors have attributed the primary role to muscle cell necrosis [29, 37] while others to the penetration of plasma into the vascular wall [30, 32—34, 38—40, 52]. Our own experience suggests that both factors are of equal importance in the development of a typical vascular fibrinoid.

In this context, the question arises whether in hypertension the lipids play a role in the development of lesions in the small vessels. The foregoing considerations imply that the primary vascular damage consists of various degrees of fibrinoid necrosis. When examining hypertensive vascular changes for the occurrence and localization of lipids, we found that in the early phase sudanophilic material was present exclusively in the necrotic smooth muscle cells; the subendothelial fibrinoid in contrast to the opinion of other authors [51] showed no affinity to lipid stains [27]. In the subendothelial lesion, lipids were demonstrable exclusively in macrophages appearing in a later phase and finally after hyalinization. The same was suggested by examinations for nonspecific esterase which, too, occurred in the above localization [16]. Thus, the lipids apparently play no primary role in the development of the vascular hyaline change.

A certain terminological confusion has arisen from the equivocal definition of the terms "fibrin" and "hyaline". The fibrinoid necrosis of the vessel wall stains red and black, whereas vascular hyalinosis stains blue and yellow, with Azan and PTA, respectively. But an unequivocal definition is actually not as simple as that, because of the staining properties the vascular wall depends mainly on the time of examination.

The acute vascular change shows the staining characteristics of fibrin, whereas the advanced lesion those of hyaline. BELL [41] postulated a correlation between the severity of hypertension and vascular hyalinization. This is apparently influenced by the extent of plasma penetration and muscle cell necrosis. SMITH [42] suggested that hyaline sclerosis was related to essential malignant hypertension.

In this context the appearance of fibrin points to the degree of severity rather than to a specific vascular change. This accounts for the fact that along this line even histochemistry has failed to disclose new details, as the results depend mainly on the phase of change in which the examination is undertaken.

As indicated by the present findings, rapidly developing hypertension produced acute vascular changes. In slowly progressing hypertension, chronic changes of the hyaline type prevailed. The same was found on reducing blood pressure with hypotensive drugs, in response to which small vessel lesions of the benign hypertension type developed [44].

In the case of slowly progressing hypertension, the vascular wall adapts itself to a certain extent to the raised blood pressure in that the muscle cells hypertrophize [45] and subsequently proliferate. This appears only natural when it is considered that muscle cell necrosis may be followed by regeneration and the development of a new multilamellar elastic fibre and muscle cell layer.

Intimal proliferation subsequent upon single muscle cell necrosis has recently been observed under the traditional atherogenic diets [47, 48]. It is now generally accepted that the intimal proliferation consists of smooth muscle cells [1, 2, 21, 28, 47, 50] which undergo a secondary transformation to foam cells, as observed by us [26] in experimental hypertension of the rat.

Examination of primary vascular lesions associated with various pathological conditions has revealed a close morphological similarity of the vascular fibrinoid regardless of the type of the disease. Vascular fibrinoid of exactly the type described here was found in collagenoses, renal diseases, tuberculous meningitis, polyarteritis, lupus erythematodes, scleroderma and the Schwartzman phenomenon. As to the vascular changes in part of these conditions, we may state that, in addition to fibrinoid necrosis, proliferation and hyalinization appeared in due course, in analogy with the hypertensive vascular lesions [13].

In a review on induced hypertensive vascular changes DUSTIN JR. [46] writes: ". . . the suggestion that arteriolar hyalinosis may be the equivalent of atheroma formation in the large arteries may be useful for further research."

It may be concluded from the evidence presented that the acute vascular fibrinoid change which has a subendothelial and medial component plays a decisive role in the further fate of the vascular wall. The result is either a hyaline of a cellular proliferative atheroma and we hope to have succeeded in disclosing the process of their evolution. Apparently, the sclerotic transformation of the vessel wall takes a similar course not only in hypertension, but also in other conditions associated with acute vascular damage.

REFERENCES

1. CONSTANTINIDES, P.: Experimental Atherosclerosis, Elsevier Publishing Company, Amsterdam—London—New York 1965. — 2. CONSTANTINIDES, P.: (1968) Lipid Deposition in Injured Arteries (EM study), Arch. Path. **85,** 280. — 3. HEPTINSTALL, R. H., BARKLEY, H., PORTER, K. A.: (1958) Relative Roles of Blood Cholesterol Level and Blood Pressure Level in the Production of Experimental Aortic Atheroma in Rabbits. Angiology, **9,** 87. — 4. PATERSON, J. C., MILLS, JEAN, LOCKWOOD, C. H.: (1960) The Role of Hypertension in the Progression of Atherosclerosis. Canad. med. Ass. J., **82,** 65. — 5. MCGILL, H. C. JR., FRANK, M. H.,

GEER, J. C.: (1961) Aortic Lesions in Hypertensive Monkeys. Arch. Path. **71,** 96. — 6. GIERTSEN, J. C.: (1966) Atherosclerosis in an Autopsy Series. 7. Relation of Hypertension to Atherosclerosis. Acta path. mikrobiol. scand. **67,** 305. — 7. JELLINEK, H.: (1967) Fibrinoid Vascular Changes Showing the Same Morphologic Pattern Following Induction by Various Experimental Conditions. Angiology **18,** 547. — 8. JELLINEK, H., SZEMENYEI, K., KERÉNYI, T., HÜTTNER, I.: (1966) Effect of Painting with Acid on Muscular Type Small Arteries. Acta morph. Acad. Sci. hung. **14,** 165. — 9. JELLINEK, H., HÜTTNER, I., KERÉNYI, I., POGÁTSA, G., GÁBOR, GY.: (1966b) Fibrinoid Necrosis of the Vascular Wall Induced by Noradrenaline. Acta morph. Acad. Sci. hung. **14,** 183. — 10. JELLINEK, H., VERESS, B., HÜTTNER, I., KERÉNYI, T.: (1966) Über die Morphologie der lymphstauungsbedingten Koronarveränderungen, Frankf. Z. Path. **75.** 331. — 11. JELLINEK, H., GÁBOR, GY., SOLTI, F., VERESS, B.: (1967a) The Problem of the Coronary Changes Due to Disturbance of Vascular Wall Permeability. Angiology **18,** 179. — 12. JELLINEK, H., NAGY, Z., HÜTTNER, I., BÁLINT, A., KÓCZÉ, A., KERÉNYI, T.: (1969) Investigations of the Permeability Changes of the Vascular Wall in Experimental Malignant Hypertension by Means of a Colloidal Iron Preparation. Brit. J. exp. Path. **50,** 13. — 13. JELLINEK, H.: (1971) Failure of Etiological Differentiation of Human Diseases Associated with Fibrinoid Necrosis. Angiology. In press. — 14. JELLINEK, H.: (1971) The Role of the Elastic Membrane in the Development of the Two Forms of Vascular Fibrinoid: The Subendothelial and Media Fibrinoid. Angiology. In press. — 15. HÜTTNER, I., JELLINEK, H., KERÉNYI, T., SZEMENYEI, K.: (1966) Fibrinoid Necrosis of the Vascular Wall Induced by Painting with Acid. Acta morph. Acad. Sci. hung. **14,** 169. — 16. HÜTTNER, I., VERESS, B., TÓTH, A., KONYÁR, É., KERÉNYI, T., JELLINEK, H.: (1967a) Die Anwendung der unspezifischen Esterasereaktion zur Untersuchung der Zellnekrose. Acta histochem. (Jena) **26,** 10. — 17. HÜTTNER, I., KERÉNYI, T., VERESS, B., TÓTH, A., KONYÁR, É., JELLINEK, H.: (1967b) Über die Verteilung der alkalischen Phosphatase in der Gefäßadventitia von Ratten bei experimenteller Hypertonie. Acta histochem. (Jena) **26,** 21. — 18. HÜTTNER, I., KERÉNYI, T., VERESS, B., JELLINEK, H., POGÁTSA, G., GÁBOR, GY.: (1967c) Coronarveränderungen nach Gabe von Noradrenalin und Isodihydroperparin. Frankf. Z. Path. **76,** 107. — 19. HÜTTNER, I., KERÉNYI, T., JELLINEK, H.: (1968) Fibrin Formations in Vascular Fibrinoid Change in Experimental Hypertension: An Electron Microscopic Study. Exp. molec. Path. **9,** 309. — 20. KÁDÁR, A., JELLINEK, H., VERESS, B.: (1969) The Ultrastructure of Cell Elements and Fine Fiber Production of Regenerating Great Vessels. VIth Congr. Int. Angiologia. Barcelona. Editorial Cientifico-Médica. Barcelona. Pp. 895. — 21. KÁDÁR, A., VERESS, B., JELLINEK, H.: (1969) Ultrastructural Elements in Experimental Intimal Thickening. II. Study of the Development of Elastic Elements in Intimal Proliferation. Exp. molec. Path. **11,** 212. — 22. KERÉNYI, T., HÜTTNER, I., JELLINEK, H.: (1966b) Über die Entwicklung der periodischen Struktur im subendothelialen Fibrinoid. Z. mikr.-anat. Forsch. **74,** 2. — 23. KERÉNYI, T., JELLINEK, H., HÜTTNER, I., GORÁCZ, GY., KONYÁR, É.: (1966a) Fibrinoid Necrosis of the Vascular Wall in Experimental Malignant Hypertension. Acta morph. Acad. Sci. hung. **14,** 175. — 24. SZEMENYEI, K., KÓCZÉ, A., JELLINEK, H.: (1968) Experimental Injury of Muscular-type Blood Vessels by Chemical Agents. Acta morph. Acad. Sci. hung. **16,** 157. — 25. VERESS, B., KERÉNYI, T., HÜTTNER, I., JELLINEK, H.: (1966) The Phases of Muscle Necrosis. J. Path. Bact. **92,** 511. — 26. VERESS, B., KÓCZÉ, A., JELLINEK, H.: (1969) Morphology of Early Large Vessel Lesions in Experimental Hypertension. Brit. J. exp. Path. **50,** 600. — 27. VERESS, B., JELLINEK, H., KÓCZÉ, A., VENESZ, I.: The Distribution of Lipids in Malignant Hypertensive Fibrinoid Necrosis. J. Atheroscler. Res. **10,** 55. — 28. VERESS, B., KÁDÁR, A., JELLINEK, H.: (1969) Ultrastructural Elements in Experimental Intimal Thickening. — 29. GARDNER, D. L.: (1963) Arteriolar Necrosis and the Prenecrotic Phase of Experimental Hypertension. Quart. J. exp. Physiol. **48,** 156. — 30. VAZQUEZ, J. J., DIXON, F. J.: (1958) Immunohistochemical Analysis of Lesions Associated with "Fibrinoid Change". Arch. Path. **66,** 504. — 31. GARDNER, D. L.: (1962) Arterial Necrosis Caused by Methoxamine: a Comparison between Acute Experimental Hypertensive Arterial Disease in the Rat and Lesions Caused by a Sympathomimetic Amine. Brit. J. exp. Path. **43,** 213. — 32. GIESE, I.: (1967) The Pathogenesis of Hypertensive Vascular Disease. Dan. med. Bull. **14,** 259. — 33. STILL, W. J. S.: (1967) The Early Effect of Hypertension on the Aortic Intima of the Rat. Amer. J. Path. **51,** 721. — 34. OLSEN, F.: (1968) Penetration of Circulating Fluorescent Proteins into Walls of Arterioles and Venules in Rats with Intermittent Acute Angiotension-hypertension. Acta path. microbiol. scand. **74,** 325. — 35. WIENER, J., LATTES, R. G., MELTZER, B. G., SPIRO, D.: (1969) The Cellular Pathology of Experimental Hypertension. IV. Evidence for Increased Vascular Permeability. Amer. J. Path. **54/2,** 187. — 36. JAMES, T. N.: (1967) Pathology of Small Coronary Arteries. Amer. J. Cardiol. **20,** 679. — 37. MUIRHEAD, E. E., TURNER, L. B., GROLLMANN, A.: (1951) Hypertensive Cardiovascular Disease. Nature and Pathogenesis of the Arteriolar Sclerosis Induced by Bilateral Nephrectomy as Revealed by a Study of its Tinctorial Characteristics. Arch.

Path. **52,** 266. — 39. ANITSCHKOW, N.: In: Arteriosclerosis. Ed. Cowdry, E. V. McMillan, New York 1933. P. 271. — 39. SCHÜRMAN, P., MCMAHON, H. E.: (1933) Die maligne Nephrosklerose, zugleich ein Beitrag zur Frage der Bedeutung der Blutgewebsschranke. Virchows Arch. path. Anat. **291,** 47. — 40. MOVAT, H. Z., MORE, R. H.: (1957) The Nature and Origin of Fibrinoid. Amer. J. clin. Path. **28,** 331. — 41. BELL, E. T.: Renal Diseases. Lea and Febiger. Philadelphia. 1946. — 42. SMITH, J. P.: (1955) Hyaline Arteriosclerosis in the Kidney. J. Path. Bact. **69,** 147. — 43. GOLDBLATT, H.: (1970) Studies on Experimental Hypertension. VII. A Production of the Malignant Phase of Hypertension. J. exp. Med. **67,** 809. — 44. KOJIMAHARA, M.: (1967) Healing and Exacerbation of Arterial Lesions in Rats with Experimental Hypertension, with Special Reference to Effects of Antihypertensive Drugs on Arterial Lesions. Gunma J. med. Sci. **16,** ... — 45. ZOLLINGER, H. U.: (1959) Die hypertensive Arteriolopathie. Schweiz. Z. allg. Path. **22,** 262. — 46. DUSTIN, P. JR.: (1962) Arteriolar Hyalinosis. Int. Rev. exp. Path. **1,** 73. — 47. THOMAS, W. A., FLORENTIN, R. A., NAM, S. CH., KIM, D. N., JONES, R. M., LEE, K. T.: (1968) Preproliferative Phase of Atherosclerosis in Swine Fed Cholesterol. Arch. Path. **86,** 6. — 48. IMAI, H., THOMAS, A. W : (1968) Cerebral Atherosclerosis in Swine: Role of Necrosis in Progression of Diet-induced Lesions from Proliferative to Atheromatous Stage. Exp. molec. Path. **8,** 330. — 49. FRENCH, J. E.: (1966) Atherosclerosis in Relation to the Structure and Function of the Arterial Intima, with Special Reference to the Endothelium. Int. Rev. exp. Path. **5,** 253. — 50. CHIDONI, J. J., O'NEAL, R. M.: (1967) Ultrastructure of Human Atheroma. Exp. molec. Path. **3,** 378. — 51. ENDES, P., TAKÁCS-NAGY L.: (1952) Bioptische Untersuchungen der Niere bei essentieller Hypertonie. Acta morph. Acad. Sci. hung. **2,** 191—203. — 52. ENDES, P., TAKÁCS-NAGY, L., RUBÁNYI, P., GÖMÖRI, P.: (1955) The Pathogenesis of Malignant Hypertension. Acta morph. Acad. Sci. hung. **5,** 113.

HYPERTENSIVE VERÄNDERUNGEN IN KLEINEN UND GROSSEN ARTERIEN ALS EIN FAKTOR DER ATHEROSKLEROSE

H. JELLINEK

Verfasser beschäftigt sich mit der Frage der Pathogenese der zur Hypertonie hinzutretenden Atherosklerose. Er stellt fest, daß die akuten Gefäßveränderungen bei der Hypertonie die Einleitung der chronischen atherosklerotischen Erscheinungen darstellen. Die Schwere der akuten Schädigung wirkt auf das Entstehen akuter Gewebsveränderungen, die Gewebsstruktur der Gefäßwand entscheidet dagegen welche Erscheinungsform der fibrinoiden Nekrose zustandekommt. Diese führen gemeinsam als Ergebnis der Zellproliferation zur Myoleastofibrose als arteriosklerotisches Aequivalent in den kleinen Gefäßen. Aus dem subendothelialem Fibrinoid entstehen hyalinöse, Lipoid enthaltende atherosklerotische morphologische Veränderungen. Die Lipoide besitzen keine Bedeutung bei der Entstehung der Veränderungen in den kleinen Gefäßen, sie sind nur sekundär nachzuweisen. Die Lamina elastica enthaltenden großen Gefäße antworten gleich auf die hypertonische Schädigung mit Proliferation der Gefäßwand und führen zu der gleichen Intimaproliferation und zu den gleichen atheromatösen Erscheinungen, wie andere zur Atherosklerose führenden aetiologischen Faktoren.

ГИПЕРТОНИЧЕСКИЕ ИЗМЕНЕНИЯ В КРУПНЫХ И МЕЛКИХ АРТЕРИЯХ, КАК ФАКТОР АТЕРОСКЛЕРОЗА

Г. ЕЛЛИНЕК

Автором был изучен патогенез атеросклероза, присоединяющейся к гипертонии. Он констатирует, что острые гипертонические изменения сосудов являются началом хронических атеросклеротических явлений. Степень тяжести острого поражения влияет на развитие острых тканевых изменений, а гистологическая структура сосудистой стенки является решающим фактором возникновения той или иной формы проявления фибриноидного некроза. Эти факторы в результате пролиферации клеток вызывают совместно мио-эласто-фиброз в мелких сосудах в качестве атероклеротического эквивалента. Из субэндотелиального фибриноида развиваются гиалиновые, содержащие липоиды изменения с атеросклеротической морфологией. В развитии изменений мелких сосудов липоиды не играют роли, их можно выявить только вторично. Крупные сосуды, обладающие эластической пластинкой, реагируют на гипертоническое поражение по аналогии мелких сосудов пролиферацией сосудистой стенки, и они показывают такую же пролиферацию интимы и подобные атероматозные явления, как под влиянием прочих этиологических факторов, приводящих к атеросклерозу.

Dr. Harry JELLINEK, Budapest IX., Üllői út 93, Hungary

Acta Morphologica Acad. Sci. Hung. 19 (2), pp. 203—213, 1971

Institute of Experimental Medicine, Hungarian Academy of Sciences (Director: Dr. E. STARK) and Institute of Pathological Anatomy, Postgraduate Medical School,* (Director: Dr. T. KÁDÁR) Budapest, Hungary

THE LYMPHATICS IN OEDEMATOUS SKIN

SZ. VIRÁGH,* M. PAPP and I. RUSZNYÁK

(Received December 15, 1970)

Oedema was induced in the hindlimb of rats, either by treatment with dextran or by perfusion. The lymph capillaries became dilated and took a cylindrical shape below the papillary layer and the subcutis. The connective-tissue lamellae disintegrated, part of the connective-tissue fibres detached from the endothelial cells of the lymphatics, while the remaining ones lost their connection with the swollen connective tissue of the cutis and aponeurosis. Many of the intracellular junctions of the lymphatics were open. Postcapillary lymphatics of the hindlimbs were dilated, the popliteal lymph-nodes swollen, and lymph flow was enhanced from the lumbar lymphatic trunk. The dilated lymphatics failed to collapse either in response to hyaluronidase injected into the oedematous skin or after the inhibition of pinocytosis.

The results have shown, in agreement with data obtained by others, that the lymphatics are pulled apart by the connective tissue fibres attached to the endothelium during the initial phase of oedema formation. As oedema progresses, dilatation of the lymphatics is maintained by the increased passage of oedema fluid through the open intercellular junctions of the lymphatics into the lumen, i.e. lymph flow is augmented. Enhanced lymph flow is impeded mechanically by the regional lymph nodes, the result of which is a retrograde dilatation of the postcapillary lymphatics and larger lymph vessels of the extremity.

The lymphatic endothelium is connected to the surrounding tissues by fibres (PULLINGER, FLOREY, 1935) and fine filaments (LEAK, BURKE, 1966, 1968, 1970; CASLEY-SMITH, 1967a). It is generally believed that when the connective tissue is distended by oedema fluid, these anchoring fibres and filaments tighten and the lymphatic vessel walls are pulled apart (PULLINGER, FLOREY, 1935; CASLEY-SMITH, 1967a).

In earlier studies we found that in dextran-induced oedema the collagen fibres decreased in number, became detached from the lymphatics and some of them disintegrated; collagen fibres were rarely seen attached to the lymphatics (VIRÁGH, PAPP, TÖRŐ, RUSZNYÁK, 1966). We assumed that the lymphatics were dilated by the increased lymph content entering the lumen, partly due to increased pinocytosis and partly through opened intercellular junctions by increased interstitial pressure (GUYTON, 1965).

In a subsequent work, CASLEY-SMITH (1967a) reported that local hyaluronidase detached the connective fibres and filaments from the vessel wall, and so the increased connective-tissue tension failed to pull apart the lymphatic endothelium; hence the lymphatics collapsed.

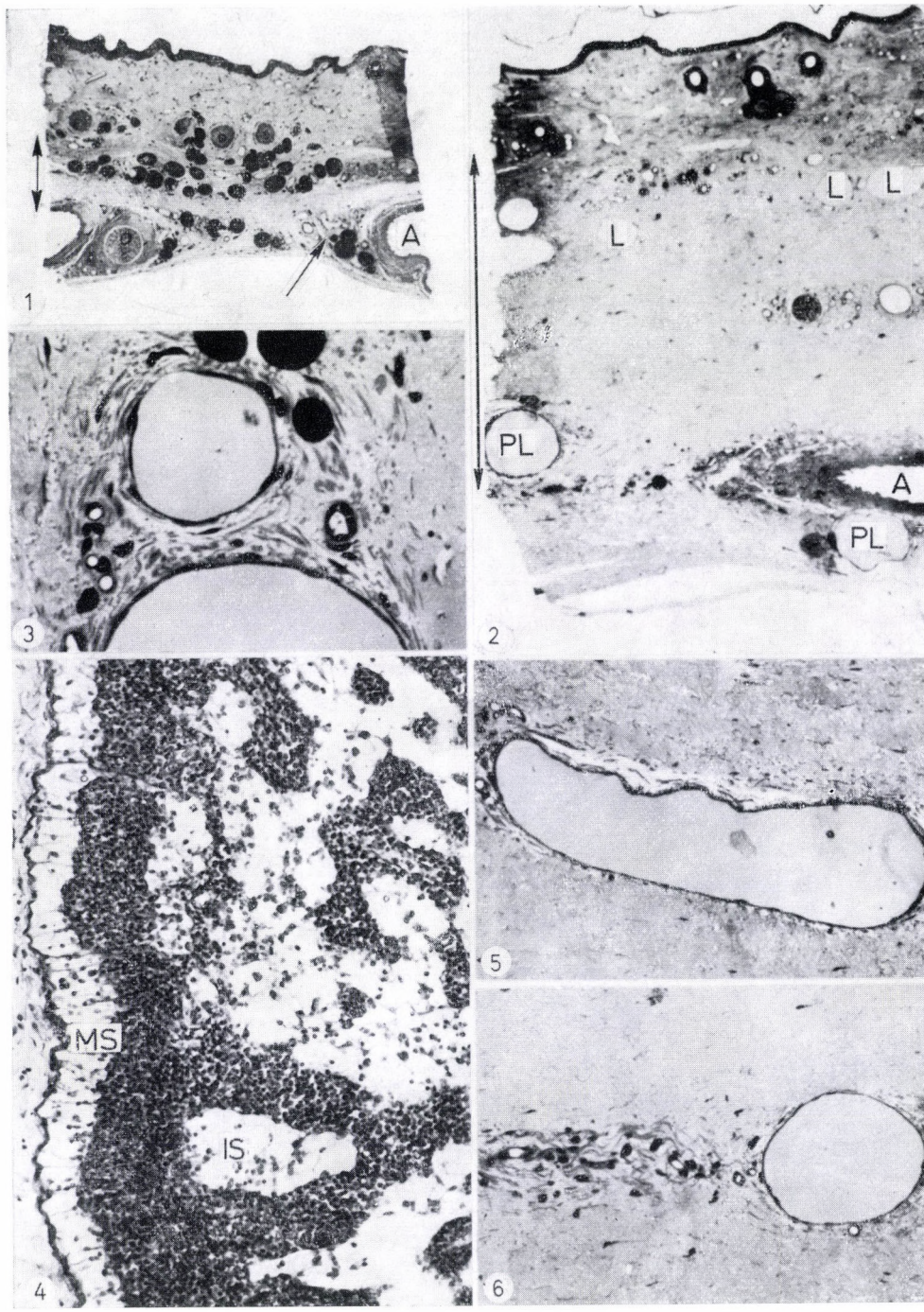
A
1
L
L
L
PL
A
PL
2
3
MS
IS
4
5
6

The finding that the lymph nodes resist to lymph flow (PAPP, MAKARA, HAJTMAN, 1971) has given us new impetus to carry out further studies. At the same time, we have attempted to verify our hypothesis concerning the importance of pinocytosis. We have therefore investigated whether the lumina of the lymphatics are collapsed if pinocytosis is inhibited or on local treatment with hyaluronidase; further, whether the resistance of the popliteal lymph node to flow promotes retrograde dilatation of the lymphatics in the skin of the oedematous limb.

Material and methods

Male albino rats of the CFE strain weighing 250—300 g were used in the experiments.

For functional studies (i) intact animals were anaesthetized intraperitoneally with pentobarbital (4 mg/100 g) and lymph was collected from the thoracic duct (BOLLMAN, CAIN, GRINDLAY, 1948) or the lumbar lymphatic trunk. The arterial blood pressure was measured in the abdominal aorta. Statistical analyses were performed with the Student's t test. Animals with dextran-induced oedema were anaesthetized and lymph was collected from them as from the intact animals.

For morphological purposes, oedema was induced with dextran (VIRÁGH et al. 1966; CASLEY-SMITH 1967a) and in one group of animals the popliteal lymph nodes were removed from the hindlimb, or from the stump of the hindlimb amputated immediately before dextran injection. In another group the animals were given either 150 IU of hyaluronidase (Hyason, Organon) in 0.05 ml of physiological saline, or 0.05 ml of saline, or homologous serum, or 0.1 ml of paraffin oil, always intracutaneously and interdigitally. Some rats were injected intravenously with ouabain, 200 μg/100 g bw. (ii). In a second group of rats anaesthetized intraperitoneally with sodium pentobarbital, the abdominal portion of the aorta and the inferior vena cava were divided. The peripheral stumps were cannulated, and the lower part of the body was perfused through the aorta by a Harvard peristaltic pump, at a rate of 3 to 4 ml/min for 60 to 120 min; the T-extension of the cannula allowed continuous measurement of the perfusion pressure by a mercury manometer.

The perfusion fluids employed were as follows.

(a) a mixture of equal amounts of canine blood serum and physiological saline;

(b) a mixture of equal amounts of canine blood serum and 0.02 *M* KCN;

(c) a mixture of equal amounts of canine blood serum and 0.01 *M* dinitrophenol.

Hyaluronidase was used to dissolve the filaments attached to the lymphatic endothelium (CASLEY-SMITH 1967a), ouabain to inhibit $Na^+ - K^+$ dependent ATPase (RIDDERSTAP and BONTING, 1969), and KCN (DETERRA and RUSTAD, 1959; GORDON and KING, 1960; CASLEY-SMITH, 1964, 1965, 1969) and dinitrophenol (SCHUMAKER, 1958) to inhibit pinocytosis in the lymphatic endothelium.

Specimens for morphological examination were obtained from the dorsal, in some animals from the plantar skin of the paw, 5 and 30 min after the intracutaneous injections, 30 and 60 min after the intravenous injection, and between the 30th and 120th min of perfusion.

To prepare adequate specimens for electron microscopic studies, in most of the animals the hindlimb was perfused with Plasmodex (Biogal Ltd., Debrecen) through the abdominal

Fig. 1. Normal rat paw skin fixed by perfusion. ↕ approximate width of subcutis. A: arteries. ↑: irregular lymph capillary in aponeurosis. × 50

Fig. 2. Paw skin, dextran-induced oedema. ↕ : widened subcutis. L: round dilated lymphatics. In the aponeurosis, two dilated postcapillary lymphatics (PL) and artery (A). × 50

Fig. 3. Connective tissue fibres surrounding dilated lymphatics near border of cutis. × 300

Fig. 4. Portion of popliteal lymph node, dextran-induced oedema. Dilated intermediary sinuses (IS); obvious tension of reticular fibres in dilated cortical sinus (MS). Paraffin embedding, trichrome staining, × 120

Fig. 5. The two postcapillary lymphatics in the aponeurosis in Fig. 2 are seen to unite deeper down. Lymphatics surrounded by connective tissue, fibres and cells. The extent of lymphatic dilatation can be judged from the blood capillaries seen in the left top corner. × 100

Fig. 6. Tangential section of the lymphatic in Fig. 5. Most connective tissue fibres are disintegrated around the lymphatic

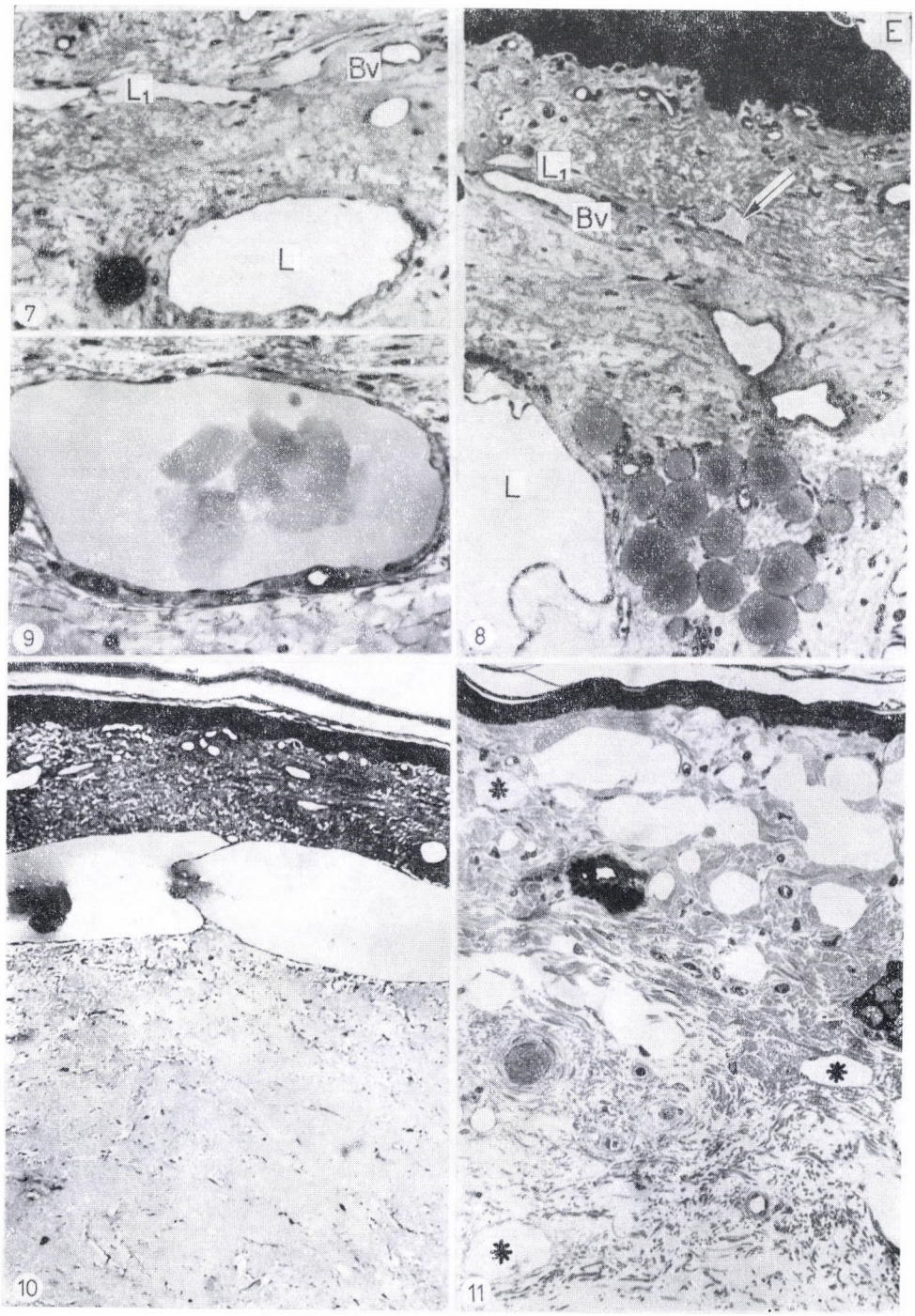
L1
Bv
L
7
9
E
L1
Bv
L
8
10
11

aorta, then fixed by glutaraldehyde at body temperature, the pH being adjusted by a phosphate buffer to between 7.2 and 7.4. In some of the animals, tissue specimens were taken with utmost care from the skin of the intact and oedematous hindlimb, then fixed in glutaraldehyde at room temperature, by the immersion method. After fixation, the hindlimb skin specimens were prepared for electron microscopic investigation, by a method described previously (VIRÁGH et al., 1966). Type JEM 6C and SEM III electron microscopes were used.

The tissue samples fixed and prepared for electron microscopy were examined also under the light microscope. The specimens were embedded in an oriented fashion, to obtain a cross-sectional plane perpendicular to the epidermis, thus allowing examination of the cutis, subcutis and aponeurosis in toto. Sections 1 to 2 μ thick were prepared and stained with toluidine blue, either after removal of the embedding substance or in some instances leaving it intact. The popliteal lymph nodes were fixed in 4% formalin, then embedded in paraffin; the 4 to 6 μ sections were stained by the trichrome method.

Results

Normal skin is known to display collapsed lymph capillaries irregular in shape. In dextran-induced oedema the texture of some skin layers was loosened in various degrees. In a strip of about 500 μ width, the lymphatics in the subepidermal connective tissue were irregular in shape and showed no dilatation. Oedematous loosening of the connective tissue began beneath the sebaceous glands and the hair follicles, where the tissue lamellae had separated, the collagenous fibres disintegrated and, in the direction of the cutis, the lymphatics grew wider (Fig. 2). Lymphatic dilatation was less pronounced in skin fixed by immersion than in skin fixed by perfusion. The amount of oedema fluid was greatest in the subcutis; the distance between the cutis and the aponeurosis was about five times the normal (Figs 1 and 2). A thin wreath of connective-tissue fibres surrounded the lymphatics (Fig. 3), but these fibres were not attached to the cutis and the aponeurosis, in which the nerves and the blood vessels were surrounded by connective tissue fibres. In the aponeurosis, lymph capillaries with variable lumina, and postcapillary lymph vessels surrounded by smooth-muscle cells varying in number (PFLEGER, 1964) were observed. The connective tissue fibres around them had no attachement to the connective tissue of either the tendon sheaths or the cutis (Figs 2, 5, 6).

Electron microscopy showed even more conspicuously that the number of connective-tissue fibres adhering to the surface of the lymph capillaries was less than normal (Fig. 12). In the oedema fluid disorganized filaments of

Fig. 7. Oedematous paw skin treated with hyaluronidase. L_1: moderately dilated irregular lymphatic near the epidermis. Under it disorganized connective tissue with considerably distended lymphatic (L). BV: blood vessel. × 150

Fig. 8. Turning the block at 90° angle still revealed L_1, as moderately dilated and irregular in shape as in Fig. 7. BV: blood vessel. E: epidermis. ↑: subepithelial narrow lymphatic. L: dilated lymphatic. × 150

Fig. 9. Oedematous paw skin treated with hyaluronidase. Dilated lymphatic in the aponeurosis is overlain with collagen fibres. × 280

Fig. 10. Oedematous paw skin treated with saline induced considerable dilatation of the valvular lymphatic below the cutis. Near the valves the lymph stained a deep dark. × 190

Fig. 11. Normal paw skin after intradermal paraffin oil injection. The oil separated the collagen bundles in the cutis and dilated the lymphatics (*) × 190

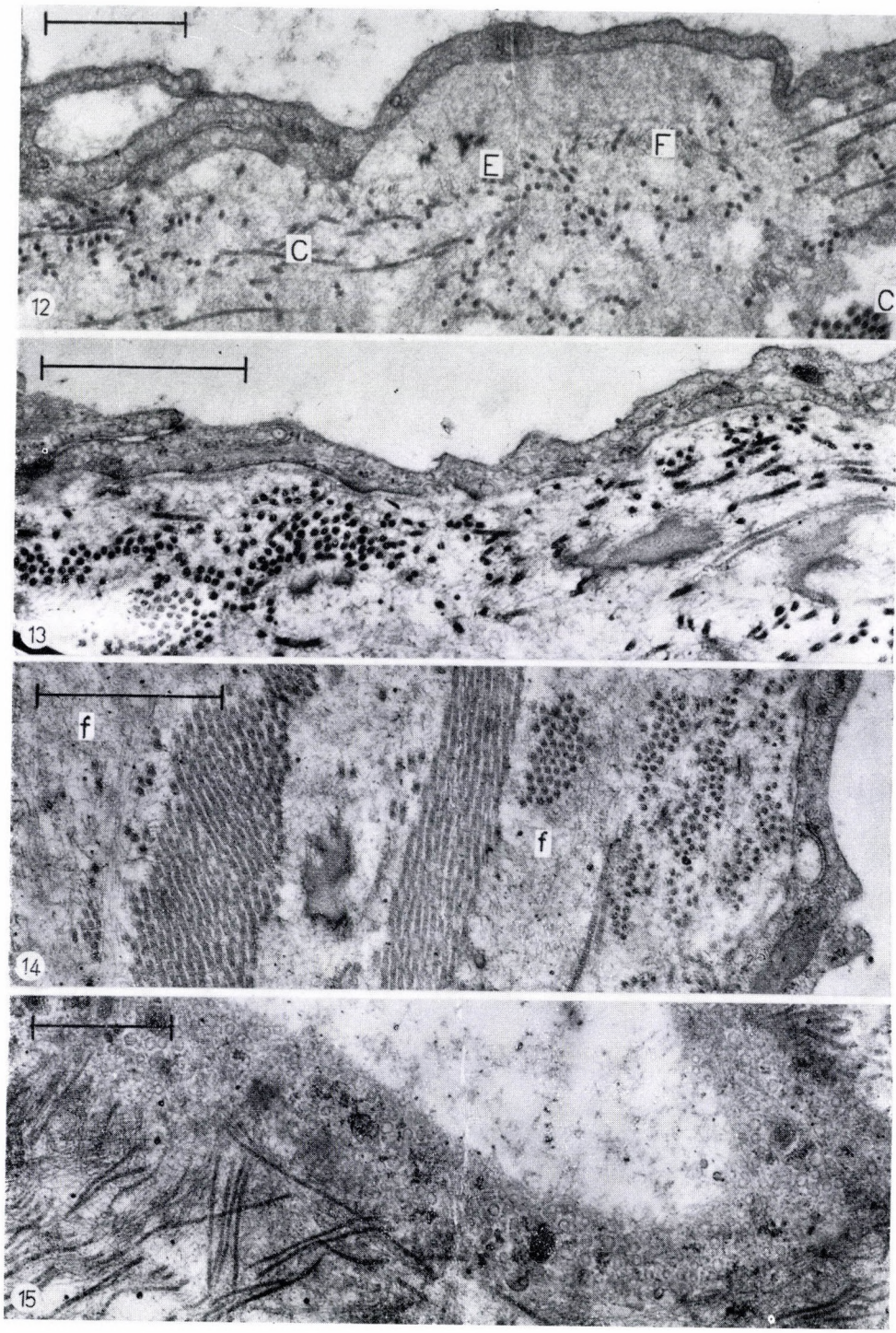
E
F
C
C
12
13
f
f
14
15

70—100 Å thickness were observed. Several of the interendothelial junctions of the dilated lymphatics were open.

As seen under the light microscope, hyaluronidase injected into the oedematous skin caused no collapse of the lymph capillaries in either of the skin layers. It did not reduce lymphatic dilatation in the cutis and the subcutis, but increased it at the site of injection (Figs 7, 8, 9). Nor did electron microscopy reveal a higher degree of detachment of connective tissue fibres from lymphatics under the action of hyaluronidase than under that of oedema (Figs 13, 14). Whether injected into normal or oedematous skin, both physiological saline and homologous serum induced a considerable dilatation at the site of injection (Fig. 10). Intracutaneous or subcutaneous paraffin oil caused the connective-tissue plates to separate, entered the gaps between them, and not infrequently forced its way into the capillary lumina, dilating them (Fig. 11).

Inhibition of pinocytosis with KCN, ouabain or dinitrophenol induced no lymphatic collapse. In the capillary endothelium pinocytotic vesicles were seen in large numbers (Fig. 15). Blocking with KCN or dinitrophenol the function of the endothelial cells and the perivascular smooth-muscle cells in the blood and lymph capillaries resulted in substantial dilatation.

Table 1

Lymph flow from the lumbar lymphatic trunk in intact anaesthetized rats and in anaesthetized rats with dextran-induced oedema

Groups	No. of rats	Lymph flow, mg/120' mean ± S.E.
Intact	7	81.4 ± 14.7
Dextran-induced oedema	7	164.7 ± 8.6[b]

[b] $p < 0.01$

In dextran-induced oedema dilated lymph vessels were seen in the hilus of the popliteal lymph nodes. Around the nodes, gross oedema was visible. The cortical and medullary sinuses of the lymph noedes were dilated (Fig. 4). Dextran produced no sinusal dilatation in the popliteal lymph node in the stump of the hindleg ablated immediately before dextran.

Fig. 12. Electron micrograph of a portion of a lymph capillary in the subcutis of oedematous paw skin. The connective tissue is disrupted. Collagenous (C) and elastic fibres as well as fine connective tissue filaments (F) disorganized and detached from the luminal surface of the endothelium (⊢⊣ = 1 μ)

Fig. 13. Electron micrograph of a portion of a lymphatic in the subcutis of oedematous paw skin treated with hyaluronidase. Structure as in Fig. 12. (⊢⊣ = 1 μ)

Fig. 14. Electron micrograph of a portion of a lymphatic in the cutis of oedematous paw skin. f: delicate filaments in the interstice (⊢⊣ = 1 μ)

Fig. 15. Electron micrograph of a tangential section of a lymphatic capillary in oedematous paw skin after ouabain. An endothelial cell full of pinocytotic vesicles (⊢⊣ = 1 μ)

Table II

Lymph flow from the thoracic duct in intact anaesthetized rats, and in anaesthetized rats with dextran-induced oedema

Groups	No. of rats	Lymph flow, μl/min mean ± S.E.	Arterial blood pressure. mmHg, mean ± S.E.
Intact	19	14 ± 1.2	107.1 ± 3.78
Dextran-induced oedema	20	9.8 ± 0.8[b]	79.5 ± 2.09[a]

[a] $p < 0.001$
[b] $p < 0.01$

During dextran oedema, lymph flow from the lumbar lymphatic trunk increased significantly (Table I) while flow from the thoracic duct showed a significant decrease (Table II) due to a significant fall in blood pressure.

Discussion

The present results appear to suggest that dilatation of the lymphatics during oedema is not produced by an increased tension of the connective tissue fibres.

Our findings are inconsistent with those of CASLEY-SMITH (1967a) as in the present study hyaluronidase did not cause a collapse of the dilated lymphatics in the oedematous skin. Were they to collapse in the sense of CASLEY-SMITH (1967a) and of other authors (LEAK and BURKE, 1966, 1968; BURKE and LEAK, 1970) hyaluronidase ought to resolve the connective-tissue fibres still adhering to the lymphatic endothelium in oedema. Of this there was, however, no sign either in the material of CASLEY-SMITH (1967a) or in ours. A disturbing element is that CASLEY-SMITH (1967a) demonstrated dilated lymph vessels without stating in which skin layer he found them; whether in retained connective tissue, where they are not distended, or in disorganized tissue, where they are.

As in the present work neither the inhibition of pinocytosis with KCN or dinitrophenol, nor the inhibition of Na^+—K^+-dependent ATPase with ouabain, has made the lymphatics to collapse, we have to revise our former suggestion that in incipient oedema dilatation of the lymphatics is caused by the increased fluid which by way of pinocytosis enters the lumina.

Solutions enter the lymphatics while being injected into the skin (PULLINGER and FLOREY, 1935) and cause dilatation of the lymph vessels depending on transmural pressure (KATZ, 1969). Their entry is facilited by the open junctions (CASLEY-SMITH, 1967b). Closed junctions open readily in response to movements, swelling of tissue, and flow of fluid into the lymphatics (CASLEY-

SMITH, 1967c); moreover they are opened, similarly as blood vessels, by locally released vasoactive substance (MAJNO, PALADE, GUTTA and SCHOEFFEL, 1961) liberated from the mast cells in dextran oedema. Oedema also develops in and around the lymph nodes.

Our present findings clearly show that in the early phase of oedema the fibres attached to the lymphatics are capable of pulling apart their walls. This appears to substantiate the suggestion of PULLINGER and FLOREY (1935) that the collagenous fibres attached to the endothelium have a share in producing lymphatic dilatation.

According to the present findings the connective tissue bundles undergo disintegration as oedema progresses, fibres become detached from the endothelium, and those that remain attached lose their contact with the stratum papillare of the cutis and with the connective tissue of the aponeurosis.

*

Acknowledgement. The authors are indebted to Mrs. B. Hajtman and G. Folly for statistical analyses.

REFERENCES

1. BOLLMAN, J. L., CAIN, J. C., GRINDLAY, J. H.: (1948) Techniques for Collection of Lymph from Liver, Small Intestine or Thoracic Duct of Rat. J. Lab. clin. Med. **33,** 1349. — 2. BURKE, J. F., LEAK, L. V.: (1970) Lymphatic Capillary Function in Normal and Inflamed States. Progress in Lymphology II. Second Congr. of Lymphology. Miami. G. Thieme Verlag. Stuttgart, 1968. P. 81. — 3. CASLEY-SMITH, J. R.: (1964) An Electron Microscopic Study of Injured and Abnormally Permeable Lymphatics. Ann. N. Y. Acad. Sci. **116,** 803. — 4. CASLEY-SMITH, J. R.: (1965) Endothelial permeability. II. The passage of particles through the lymphatic endothelium of normal and injured ears. Brit. J. exp. Path. **46,** 35. — 5. CASLEY-SMITH, J. R.: (1967a) Electron Microscopical Observations on the Dilated Lymphatics in Oedematous Regions and their Collapse following Hyaluronidase Administration. Brit. J. exp. Path. **48,** 680. — 6. CASLEY-SMITH, J. R.: (1967b) The Fine Structure, Properties and Permeabilities of the Lymphatic Endothelium. Experientia (Basel) Suppl. **14,** 19. — 7. CASLEY-SMITH, J. R. (1967c) The Fine Structure and Permeabilities of Lymphatics under Some Pathological Conditions. Experientia (Basel) Suppl. **14,** 124. — 7/a. CASLEY-SMITH, J. R.: (1969) The Dimensions and Numbers of Small Vesicles in Cells, Endothelial and Mesothelial and the Significance of These for Endothelial Permeability. J. Microscop. **90,** 251. — 8. DE TERRA, N., RUSTAD, R. C.: (1959) The Dependence of Pinocytosis on Temperature and Aerobic Respiration. Exp. Cell Res. **17,** 191. — 9. GORDON, G. B., KING, D. W.: (1960) Phagocytosis. Amer. J. Pathol. **37,** 279. — 10. GUYTON, A. C.: (1965) Interstitial Fluid Pressure: II. Pressure-volume Curves of Interstitial Space. Circulat. Res. **16,** 452. — 11. KATZ, A. J., CHEN, YU, MORENA, A. H.: (1969). Flow through a Collapsible Tube. Experimental Analysis and Mathematical Model. Biophys. J. **9,** 1261. — 12. LEAK, I. V., BURKE, J. F.: (1966) Fine Structure of the Lymphatic Capillary and the Adjoining Connective Tissue Area. Amer. J. Anat. **118,** 785. — 13. LEAK, I. V., BURKE, J. F.: (1968) Ultrastructural Studies on the Lymphatic Anchoring Filaments. J. Cell Biol. **36,** 129. — 14. MAJNO, G., PALADE, G. E., GUTTA, I., SCHOEFL. G. J.: (1961) Studies of Inflammation. II. The Site of Action of Histamine and Serotonin along the Vascular Tree: a Topographic Study. J. Biophys. Biochim. Cytol. **11,** 607. — 15. PAPP, M., MAKARA, G. B., HAJTMAN, B.: (1971) The Resistance of in situ Perfused Lymph Trunks and Lymph Nodes to Flow. Experientia. (Basel) **27,** 391. — 16. PFLEGER, L.: (1964) Histologie und Histopathologie cutaner Lymphgefäße der unteren Extremitäten. I. Mitteilung, Morphologie der cutanen Lymphgefäße. Arch. klin. exp. Dermat. **221,** 1. — 17. PULLINGER, B. D., FLOREY, H. W.: (1935) Some Observations on the Structure and Functions of Lymphatics: their Behaviour in Local Oedema. Brit. J. exp. Path. **16,** 49. — 18. RIDDERSTAP, A. S., BONTING, S. L.: (1969) $Na-K^{++}$-activated ATPase and Exocrine Pancreatic Secretion

in vitro. Amer. J. Physiol. **217**, 1721. — 19. RAMACHANDRU, G. N.: (1963) Int. Rev. of Connective Tissue Research. (D. A. Hall, Ed.) Academic Press, New York P. 127. — 20. SCHUMAKER, V. N.: (1958) Uptake of Protein from Solution by Amoeba proteus. Exp. Cell Res. **15**, 314. — 21. VIRÁGH, SZ., PAPP, M., TÖRŐ, I., RUSZNYÁK, I.: (1966) Cutaneous Lymphatic Capillaries in Dextran-induced Oedema of the Rat. Brit. J. exp. Path. **47**, 563.

ÜBER DIE LYMPHGEFÄSSE DER ÖDEMATÖSEN HAUT

SZ. VIRÁGH, M. PAPP und I. RUSZNYÁK

Durch Behandlung mit Dextran oder mittels Perfusion wurde in den hinteren Gliedmaßen von Ratten ein Ödem erzeugt. Die Lymphkapillaren erweiterten sich und nahmen unter dem Stratum papillare und der Subcutis eine zylindrische Gestalt an. Die Bindegewebslamellen disintegrierten; ein Teil der bindegewebigen Fasern löste sich von den Endothelzellen der Lymphgefäße, während der Rest der Fasern seine Verbindung mit dem geschwollenen Bindegewebe der Haut und der Aponeurose verlor. Viele der interzellulären Junktionen der Lymphgefäße waren offen. Die postkapillären Lymphgefäße der hinteren Extremität waren erweitert, die popliteälen Lymphknoten oedematös geschwollen, und der Lymphstrom war vom lumbalen Lymphstrang erhöht. Die erweiterten Lymphgefäße kollabierten weder nach Injektion von Hyaluronidase in die ödematöse Haut, noch nach Hemmung der Pinozytose.

Die Ergebnisse zeigen in Übereinstimmung mit Daten der Literatur, daß die Lymphgefäße durch die Bindegewebsfasern, die am Endothel haften, während der Anfangsphase der Ödembildung beiseite gezogen werden. Mit fortschreitendem Ödem wird die Dilatation der Lymphgefäße infolge der erhöhten Passage der ödematösen Flüssigkeit durch die offenen interzellulären Junktionen der Lymphgefäße in das Lumen erhalten, d. h. der Lymphfluß ist vergrößert. Der erhöhte Lymphfluß wird durch die regionalen Lymphknoten mechanisch behindert, wodurch eine retrograde Dilatation der postkapillären und größeren Lymphgefäße der Extremität auftritt.

ЛИМФАТИЧЕСКИЕ СОСУДЫ В ОТЕЧНОЙ КОЖЕ

С. ВИРАГ, М. ПАПП и И. РУСНЬЯК

Введением декстрана или при помощи перфузии авторы вызывали отеки в задних конечностях крыс. Лимфатические капилляры стали расширенными и принимали под папиллярным слоем и в подкожном слое цилиндрическую форму. Пластинки соединительной ткани показали дезинтеграцию, часть волокон соединительной ткани отделилась от эндотелиальных клеток лимфатических сосудов, тогда как остальные волокна потеряли связь с набухшей соединительной тканью кожи и апоневроза. Много внутриклеточных соединений лимфатических сосудов задних конечностей были расширенными, подколенные лимфатические узлы оказались увеличенными и ток лимфы осуществялся из поясничного лимфатического сосудистого ствола. Расширенные лимфатические сосуды не спадались ни после введения гиалуронидазы в отечную кожу, ни вследствие торможения пиноцитоза.

Результаты экспериментов показали, что — в полном согласии с данными других исследователей, — в начальной фазе образования отека лимфатические сосуды разорваются волокнами соединительной ткани, связанными с эндотелием. По мере прогрессирования отека расширение лимфатических сосудов поддерживается повышенным током отечной жидкости через открытые внутриклеточные соединения лимфатических сосудов в просвет, то есть ток лимфы является повышенным. Ускоренный ток лимфы механически задерживается регионарными лимфатическими узлами, в результате чего наблюдается ретроградное расширение посткапиллярных лимфатических сосудов и более крупных лимфатических сосудов конечностей.

Dr. Szabolcs VIRÁGH Orvostovábbképző Intézet, Budapest XIII., Szabolcs u. 33, Hungary

Dr. Miklós PAPP, Dr. István RUSZNYÁK } MTA Kísérleti Orvostudományi Kutató Intézet. Budapest VIII., Szigony u. 43, Hungary

INDEX

Morphologia Normalis et Experimentalis

Péczely, P.: Effect of Metyrapone, Prednisolone and Insulin Treatment on the Domestic Pigeon's Hypothalamus 105

Tóth, S.—Lévai, G.—Szilágyi, T.: Effect of Reptilase on Thrombohaemorrhagic Reactions 123

Csaba, G.—Hodinka, L.: Dynamics of the Cortisone-effect on Mast Cell Formation 131

Wenger, T.—Aros, B.: Studies on the Organon vasculosum laminae terminalis III. Vascularization of the Organon vasculosum laminae terminalis in the Rat 141

Kasinathan, S.—Basu, S. L.: Recovery of Spermatogenesis after the Withdrawal of Testosterone Treatment in *Rana hexadactyla* Lesson 151

Motavkin, P. A.—Dovbish, T. V.: Histochemical Characteristics of Acetylcholinesterase of the Nerves Innervating the Brain Vessels 159

Nagy, Z.—Papp, M.—Bálint, A.: Vascular Injury Associated with Acute Pancreatitis Induced by Oil or Na-Deoxycholate 175

Jellinek, H.: Vascular Changes in Small and Large Arteries in Rapid Hypertension as an Atherosclerosis Provoking Factor 187

Virágh, Sz.—Papp, M.—Rusznyák, I.: The Lymphatics in Oedematous Skin 203

A kiadásért felel az Akadémiai Kiadó igazgatója — Műszaki szerkesztő: Várhelyi Tamás
A kézirat nyomdába érkezett: 1971. VII. 11. — Terjedelem: 11 (A/5) ív, 58 ábra

71.72122 Akadémiai Nyomda, Budapest — Felelős vezető: Bernát György

The Acta Morphologica publish papers on experimental medical subjects in English, French, German and Russian.

The Acta Morphologica appear in parts of varying size, making up volumes.

Manuscripts should be addressed to:

Acta Morphologica, Budapest IX., Tűzoltó u. 58.

Correspondence with the editors and publishers should be sent to the same address.

The rate of subscription is $ 16.00 per volume.

Orders may be placed with "Kultúra" Foreign Trade Company for Books and Newspapers (Budapest I., Fő utca 32. Account No. 43-790-057-181) or with representatives abroad.

Les Acta Morphologica paraissent en français, allemand, anglais et russe et publient des travaux du domaine des sciences médicales expérimentales.

Les Acta Morphologica sont publiés sous forme de fascicules qui seront réunis en volumes.

On est prié d'envoyer les manuscrits destinés à la rédaction à l'adresse suivante:

Acta Morphologica, Budapest IX., Tűzoltó u. 58.

Toute correspondance doit être envoyée à cette même adresse.

Le prix de l'abonnement est de $ 16.00 par volume.

On peut s'abonner à l'Entreprise du Commerce Extérieur de Livres et Journaux «Kultúra» (Budapest I., Fő utca 32. Compte-courant № 43-790-057-181) ou à l'étranger chez tous les représentants ou dépositaires.

«Acta Morphologica» публикуют трактаты из области экспериментальных медицинских наук на русском, немецком, английском и французском языках.

«Acta Morphologica» выходят отдельными выпусками разного объема. Несколько выпусков составляют один том.

Предназначенные для публикации авторские рукописи следует направлять по адресу:

Acta Morphologica, Budapest IX., Tűzoltó u. 58.

По этому же адресу направлять всякую корреспонденцию для редакции и администрации. Подписная цена — $ 16.00 за том.

Заказы принимает предприятие по внешней торговле книг и газет «Kultúra» (Budapest I., Fő utca 32. Текущий счет № 43-790-057-181) или его заграничные представительства и уполномоченные.

Reviews of the Hungarian Academy of Sciences are obtainable at the following addresses:

ALBANIA
Drejtorija Qändrone e Pärhapjes dhe Propagandimit tä Librit
Kruga Konferenca e Päzes
Tirana

AUSTRALIA
A. Keesing
Box 4886, GPO
Sydney

AUSTRIA
GLOBUS
Höchstädtplatz 3
A-1200 Wien XX

BELGIUM
Office International de Librairie
30, Avenue Marnix
Bruxelles 5
Du Monde Entier
5, Place St. Jean
Bruxelles

BULGARIA
HEMUS
11 pl Slaveikov
Sofia

CANADA
Pannonia Books
2, Spadina Road
Toronto 4, Ont.

CHINA
Waiwen Shudian
Peking
P. O. B. 88

CZECHOSLOVAKIA
Artia
Ve Směčkách 30
Praha 2
Poštovní Novinová Služba
Dovoz tisku
Vinohradská 46
Praha 2
Mad'arská Kultura
Václavské nám. 2
Praha 1
SLOVART A. G.
Gorkého
Bratislava

DENMARK
Ejnar Munksgaard
Nörregade 6
Copenhagen

FINLAND
Akateeminen Kirjakauppa
Keskuskatu 2
Helsinki

FRANCE
Office International de Documentation et Librairie
48, rue Gay Lussac
Paris 5

GERMAN DEMOCRATIC REPUBLIC
Deutscher Buch-Export und Import
Leninstraße 16
Leipzig 701
Zeitungsvertriebsamt
Fruchtstraße 3—4
1004 Berlin

GERMAN FEDERAL REPUBLIC
Kunst und Wissen
Erich Bieber
Postfach 46
7 Stuttgart S.

GREAT BRITAIN
Blackwell's Periodicals
Oxenford House
Magdalen Street
Oxford
Collet's Subscription Import Department
Denington Estate
Wellingborough, Northants.
Robert Maxwell and Co. Ltd.
4—5 Fitzroy Square
London W. 1

HOLLAND
Swetz and Zeitlinger
Keizersgracht 471—487
Amsterdam C.
Martinus Nijhof
Lange Voorhout 9
The Hague

INDIA
Hind Book House
66 Babar Road
New Delhi 1

ITALY
Santo Vanasia
Via M. Macchi 71
Milano
Libreria Commissionaria Sansoni
Via La Marmora 45
Firenze
Techna
Via Cesi 16.
40135 Bologna

JAPAN
Kinokuniya Book-Store Co. Ltd.
826 Tsunohazu 1-chome
Shinjuku-ku
Tokyo
Maruzen and Co. Ltd.
P. O. Box 605
Tokyo-Central

KOREA
Chulpanmul
Phenjan

NORWAY
Tanum-Cammermeyer
Karl Johansgt 41—43
Oslo 1

POLAND
RUCH
ul. Wronia 23
Warszawa

ROUMANIA
Cartimex
Str. Aristide Briand 14—18
Bucureşti

SOVIET UNION
Mezhdunarodnaya Kniga
Moscow G—200

SWEDEN
Almquist and Wiksell
Gamla Brogatan 26
S—101 20 Stockholm

USA
F. W. Faxon Co. Inc.
15 Southwest Park
Westwood Mass 02090
Stechert Hafner Inc.
31. East 10th Street
New York, N. Y. 10003

VIETNAM
Xunhasaba
19, Tran Quoc Toan
Hanoi

YUGOSLAVIA
Forum
Vojvode Mišića broj 1
Novi Sad
Jugoslovenska Knjiga
Terazije 27
Beograd

29. XI. 1971 Index: 26017

Acta Morphologica

Academiae Scientiarum Hungaricae

ADIUVANTIBUS
J. BALÓ, P. ENDES, K. FARKAS, L. HARANGHY,
B. KELLNER, I. KÖRNYEY, I. KROMPECHER,
GY. ROMHÁNYI. E. SOMOGYI, J. SZENTÁGOTHAI

REDIGIT
I. TÖRŐ

TOMUS XIX * FASCICULUS 3

Akadémiai Kiadó Budapest

1971

ACTA MORPHOLOGICA

A MAGYAR TUDOMÁNYOS AKADÉMIA ORVOSTUDOMÁNYI KÖZLEMÉNYEI

SZERKESZTŐSÉG ÉS KIADÓHIVATAL: BUDAPEST V., ALKOTMÁNY U. 21.

Technikai szerkesztő:
Dr. Somogyi Endre

Az Acta Morphologica német, angol, francia és orosz nyelven közöl értekezéseket a kísérletes orvostudomány tárgyköréből.

Az Acta Morphologica változó terjedelmű füzetekben jelenik meg. Több füzet alkot egy kötetet.

A közlésre szánt kéziratok a következő címre küldendők:

Acta Morphologica, Budapest IX., Tűzoltó u. 58.

Ugyanerre a címre küldendő minden szerkesztőségi és kiadóhivatali levelezés.

Megrendelhető a belföld számára az Akadémiai Kiadónál (Budapest V., Alkotmány utca 21. Bankszámla 05-915-111-46), a külföld számára pedig a „Kultúra" Könyv- és Hírlap Külkereskedelmi Vállalatnál (Budapest I., Fő utca 32. Bankszámla: 43-790-057-181) vagy annak külföldi képviseleteinél és bizományosainál.

Die Acta Morphologica veröffentlichen Abhandlungen aus dem Bereiche der experimental-medizinischen Wissenschaften in deutscher, englischer, französischer und russischer Sprache.

Die Acta Morphologica erscheinen in Heften wechselnden Umfanges. Mehrere Hefte bilden einen Band.

Die zur Veröffentlichung bestimmten Manuskripte sind an die folgende Adresse zu senden:

Acta Morphologica, Budapest IX., Tűzoltó u. 58.

An die gleiche Anschrift ist auch jede für die Schriftleitung und den Verlag bestimmte Korrespondenz zu richten. Abonnementspreis pro Band: $ 16,00.

Bestellbar bei dem Buch- und Zeitungs-Außenhandels-Unternehmen »Kultúra« (Budapest I., Fő utca 32. Bankkonto Nr. 43-790-057-181) oder bei seinen Auslandsvertretungen und Kommissionären.

Acta Morphologica Acad. Sci. Hung. 19 (3), pp. 213—231, 1971

Section of Pathology (Head: Dr. J. Juhász), Postgraduate Medical School, Budapest

LIVER INJURY INDUCED BY ALPHA-NAPHTHYL-ISOTHIOCYANATE

Márta Balázs

(Received January 15, 1970)

Liver injury induced by the administration of alpha-naphthyl-isothiocyanate has been investigated by electron microscopic methods.

The acute stage was characterized by a damage to the bile secreting apparatus.

In the subacute stage severe, progressive alterations of the liver cell organelles, as well as a fascicular proliferation of ductular cells poor in organelles were in the foreground.

In the chronic experiment the pathological changes observed in the fine structure of liver cells progressed, but the intense ductular proliferation, conspicuous in the subacute experiment, regressed. This has been ascribed to a habituation to the compound administered twice weekly.

In a previous paper [3] an account was given of the results of light microscopic studies concerning the liver injury induced by acute, subacute and chronic administration of alpha-naphthyl-isothiocyanate (in the following: ANIT). In the acute experiments the septal and interlobular bile ducts showed cholangiotoxic changes, reaching a peak at 3 to 4 days after the onset of administration. During subacute administration cholestasis ceased, but a marked cholangio-plastic effect was noted. In the chronic experiments the hepatotoxic effect was in the foreground, while the ductular proliferation diminished, presumably due to habituation to the compound.

The effect of ANIT was first reported by Lopez and Mazzanti [12]. Since then, it has been widely studied by biochemical [18—21], histochemical [4, 6, 11, 25], immunological [31], light microscopic [3, 5, 7, 17, 30], as well as electron microscopic [22, 24, 26—29, 31] methods. The results obtained are somewhat conflicting and the mode of action is still unclear. We have therefore studied by electron microscopy the liver injury elicited by the acute, subacute and chronic administration of ANIT.

Material and methods

White rats of either sex, weighing 160 to 200 g, were used. The animals were fed a compressed, high-protein fodder supplemented with vitamins and minerals. Water was allowed ad libitum. ANIT was dissolved in sunflower oil and administered through a gastric tube.

In the acute experiment, 20 animals received a single 100 mg/kg body weight dose of ANIT, then 2 animals were sacrificed daily over 10 days. In the subacute experiment, 16 rats

were involved. They were given 100 mg/kg body weight of ANIT twice weekly and during the experiment lasting 1 to 8 weeks two animals were killed every week. In the chronic experiment, 10 animals were treated in the same way over five months. The 4 controls received at the same points of time sunflower oil through a gastric tube. The animals were killed by exsanguination.

For electron microscopic studies, small liver tissue specimens were fixed according to PALADE in buffered 2% OSO_4 solution, at +4°C for one hour. This was followed by dehydration in an ascending alcohol series and embedding in Araldite. Ultrathin sections were cut with a Porter Blum ultramicrotome. For contrasting, uranyl acetate and lead citrate were used. The electron micrograms were taken with a SEM 3—1 electron microscope.

Results

Group I. Acute experiment

After a single dose of ANIT, the biliary canaliculi became dilated gradually in 24 to 48 hours, reaching a peak on the 3rd or 4th day (Fig. 2). At that point of time all the canaliculi were markedly dilated. Most of the microvilli had disappeared, the canalicular cell surface was smooth. In the vicinity of the dilated canaliculi, diverticles representing canalicular bulgings were visible (Fig. 1). The cementing structures of the canaliculi were well preserved.

In individual liver cells, sequestration of cytoplasmic portions (Fig. 3) or autophagous vacuoles could be seen (Fig. 4). Otherwise the nuclei of cells, the fine structure of cytoplasmic organelles and the vascular surface of the cells were intact.

On the 5th or 6th day, the canalicular dilatation tended to decrease, the normal structure was restored at 7 to 10 days.

Group II. Subacute experiment

In addition to the canalicular changes observed in the acute experiment profound alterations were demonstrated in the cytoplasmic organelles of liver cells.

Changes of the endoplasmic reticulum and ribosomes

The commonest and most conspicuous change was an excessive dilatation of the endoplasmic reticulum, visible in the majority of liver cells. There parallel arrangement of the rough-surfaced endoplasmic reticulum practically ceased, cystic dilatation was apparent with a degranulation of the surface at many sites. In the hyaloplasm the free ribosome granules were usually in rosette-like arrangement, appearing as polyribosomes (Fig. 5). The smooth-surfaced endoplasmic reticulum formed small vesicles appearing in groups at the border of the pericanalicular zone or in other areas of the cytoplasm (Figs 5 and 6).

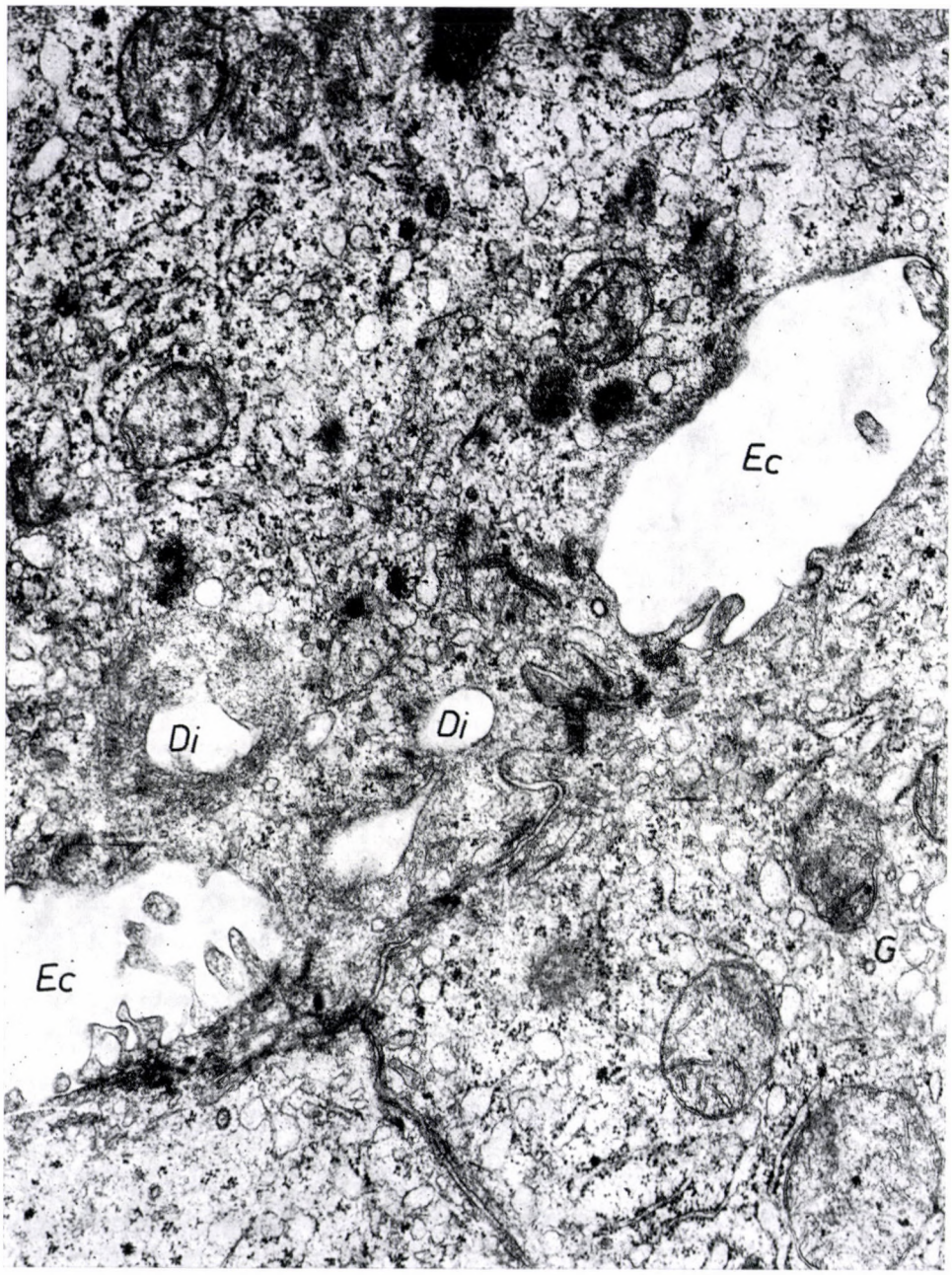

Fig. 1. Electron microscopic appearance of the liver of an animal killed 48 hours after a simple dose of ANIT. Between two liver cells, dilated biliary canaliculi (Ec), with partially destroyed microvilli and diverticles extending into the adjacent cytoplasm (Di). The organelles of the pericanalicular cytoplasmic parts are regular. ×35,000

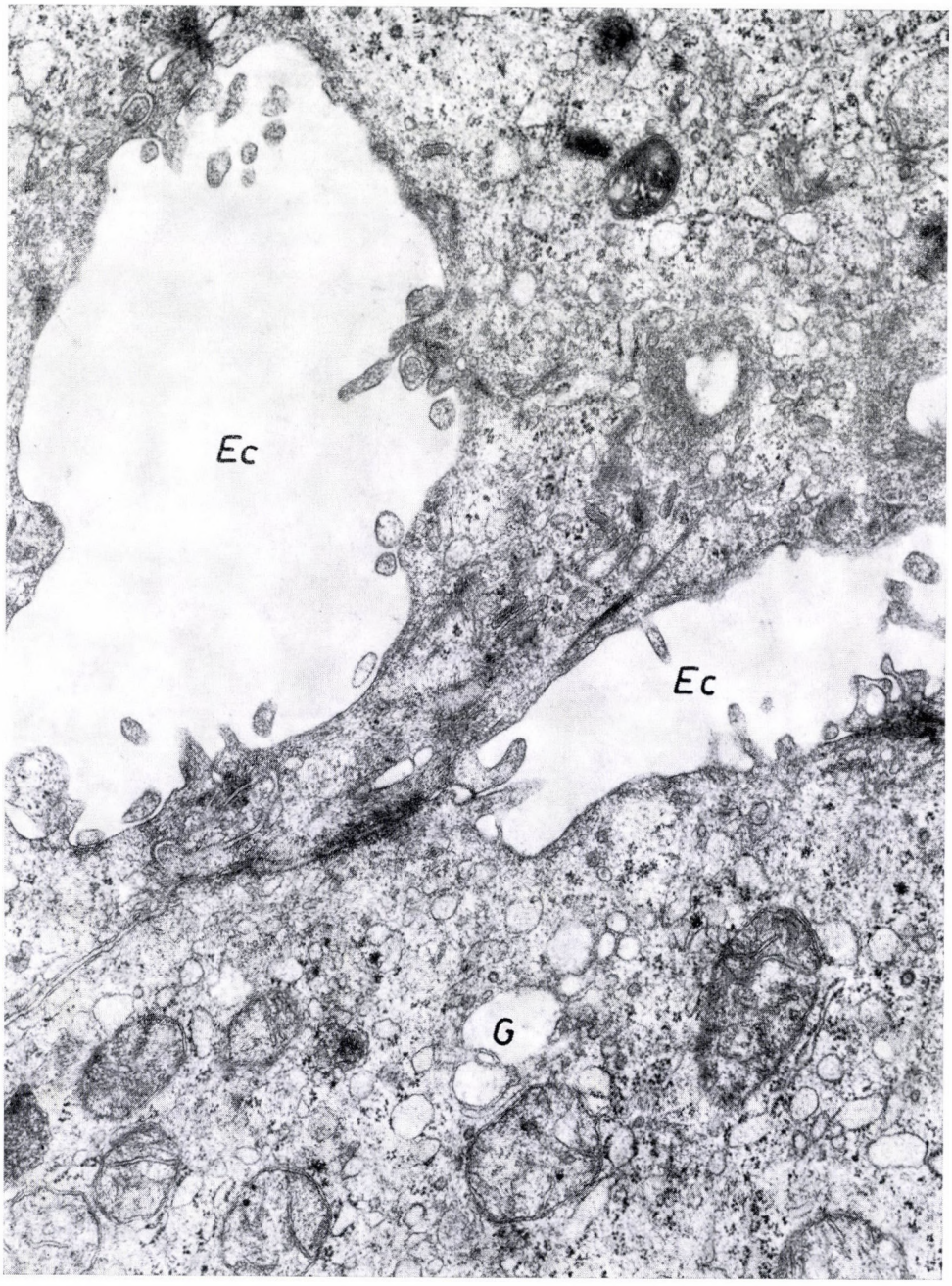

Fig. 2. Electron microscopic appearance of the liver of an animal killed 4 days after a simple dose of ANIT. Excessive dilatation of biliary canaliculi (Ec). The structures joining the cells together are well preserved. ×35,000

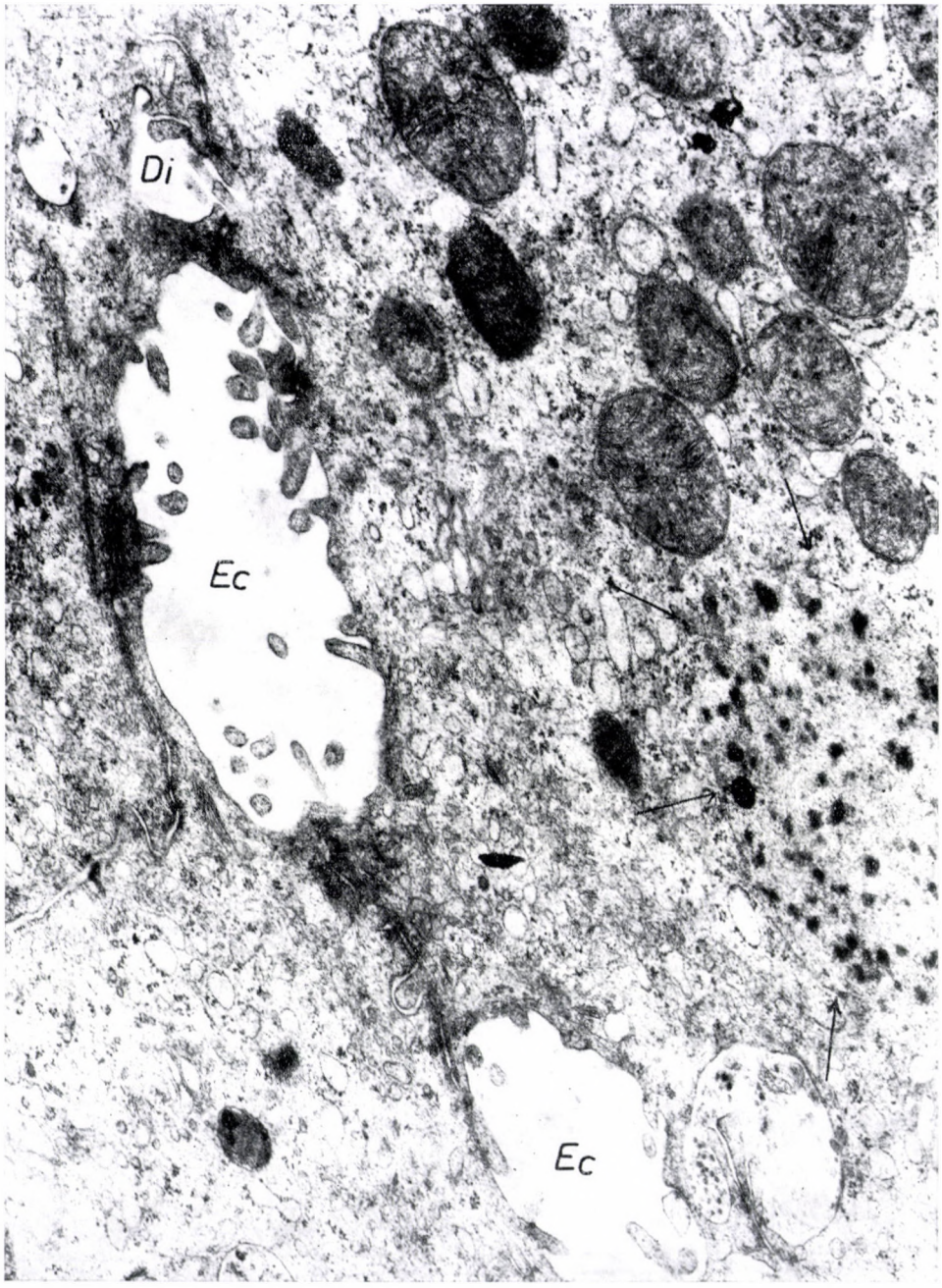

Fig. 3. Electron microscopic appearance of the liver of an animal killed 48 hours after a single dose of ANIT. Biliary capillaries in the interspace between three liver cells (Ec). The lumina are dilated, there are diverticula (Di) in the vicinity. In the areas marked by arrows the regular cytoplasmic organelles are absent. In their place partly finely granulated, partly coarse strongly eosinophilic structures have accumulated. At sites the marked areas are distinct from the adjacent cytoplasmic parts. Beside the sequestration of the marked area the fine structure of the cytoplasm is preserved. ×35,000

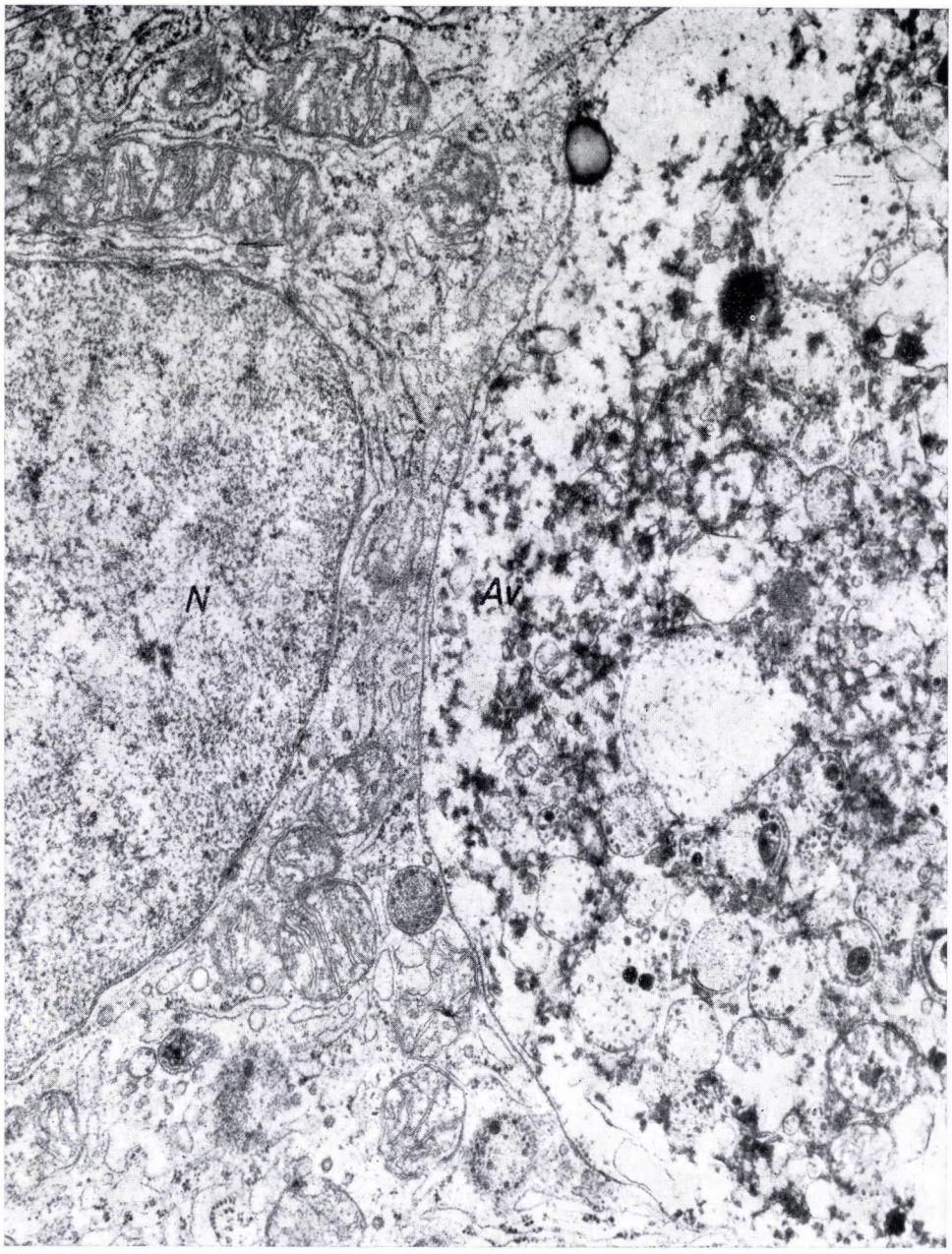

Fig. 4. Electron microscopic appearance of the liver of an animal killed 48 hours after a single dose of ANIT. On the left, part of a liver cell nucleus (N), on the right an extensive autophagous vacuole (Av) surrounded by a single membrane. In the areas adjacent to the autophagous vacuole the organelles of the liver cell show a well-preserved structure. ×35,000

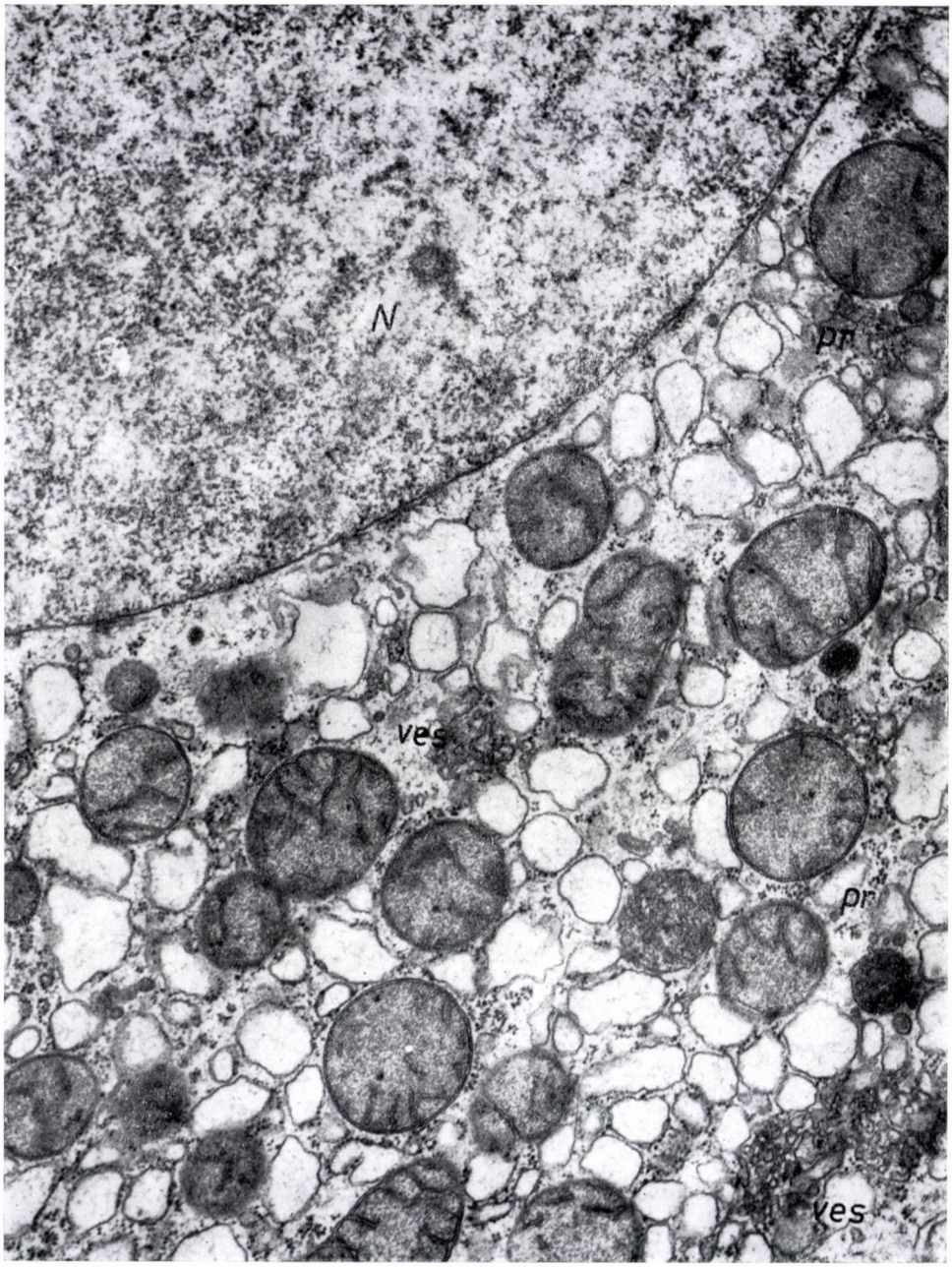

Fig. 5. Electron microscopic appearance of liver tissue from an animal killed after 4-week ANIT treatment. Part of the nucleus (N) of a liver cell is visible, with normal structure. In the cytoplasm the endoplasmic reticulum has decreased in amount, the rough-surfaced endoplasmic reticulum is present in vesicular form. The surface is degranulated at many sites, the ribosomal granules appear scattered or in rosette-like groups (pr) free in the hyaloplasm. In some areas a group-wise accumulation of smooth-surfaced vesicles (ves) is seen. The mitochondria vary in size, their crista system is disorganized. ×35,000

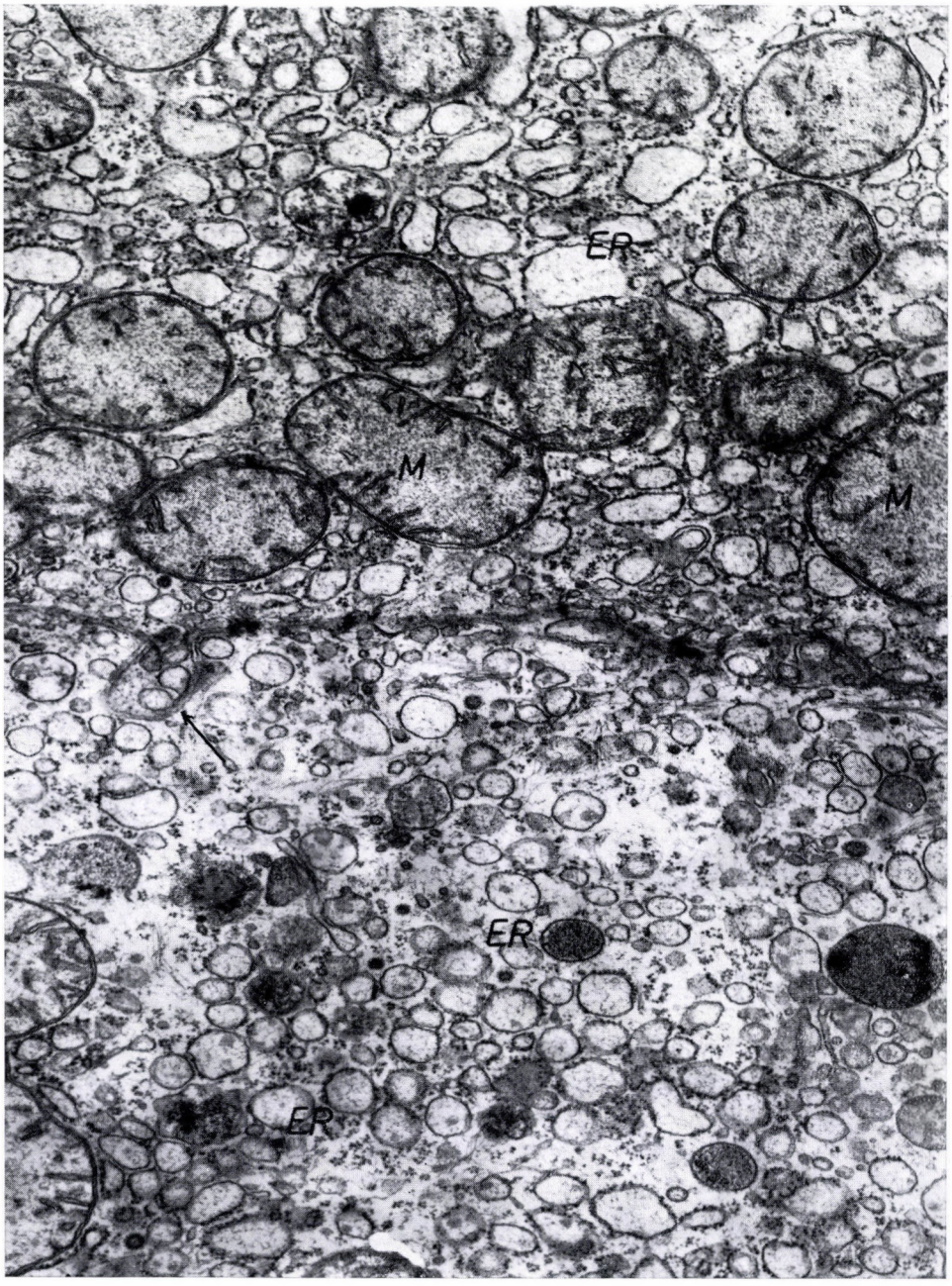

Fig. 6. Electron microscopic appearance of liver tissue from an animal killed after 5-month ANIT treatment. Between the adjacent parts of liver cells the lateral cell membrane is conspicuously tortuous in course. The arrow points at a glove finger-like bulge of the cell membrane. In the upper part, the mitochondria vary in shape and the cristae are fragmented (m). The rough membranes of the endoplasmic reticulum are vesicular (ER), degranulated at many sites. This phenomenon is particularly conspicuous in the bottom area . ×35,000

Changes of mitochondria

The mitochondria became varied in shape, size and density. The crista system was fragmented (Figs 5 and 6). The mitochondrial alterations were the most severe in those cells in which the dilatation and degranulation of the rough endoplasmic reticulum were most marked.

Other changes

The Golgi zones were extensive, with a marked increase in the number of lysosomes in their vicinity. The cell nuclei were apparently intact. No pathological changes worth mentioning were demonstrated at the vascular pole of the cells.

Group III. Chronic experiment

The changes of the cytoplasmic organelles of liver cells were even more marked than in Group II (Fig. 7). In some cells the mitochondria perished, necrobiosis had begun and large vacuoles with mammillary projections developed [26] (Fig. 7).

There were two conspicuous differences from the changes noted in the subacute period.

Regeneration and hypertrophy of biliary canaliculi

A number of biliary canaliculi showed a longitudinal increase, the canalicular cell surface was covered by closely packed microvilli, often elongated like the fingers of a glove (Fig. 8). In addition, there were dilated canaliculi with a reduced number of microvilli.

Changes in the Golgi region

Many Golgi lamellae were markedly dilated, the cisterns showing saccular distension contained round granules of medium electron density (Figs 9a and 9b). The Golgi apparatus retained its characteristic peribiliary localisation, but was often unusually extended. In its neighborhood "peribiliary corpuscles" of variable size and electron density were visible (Figs 9a and 9b).

Other changes

The nuclei of cells were normal in structure throughout. Binuclear cells often occurred. In the Disse space an increase of collagen fibrils was noted, otherwise the vascular pole of liver cells was intact.

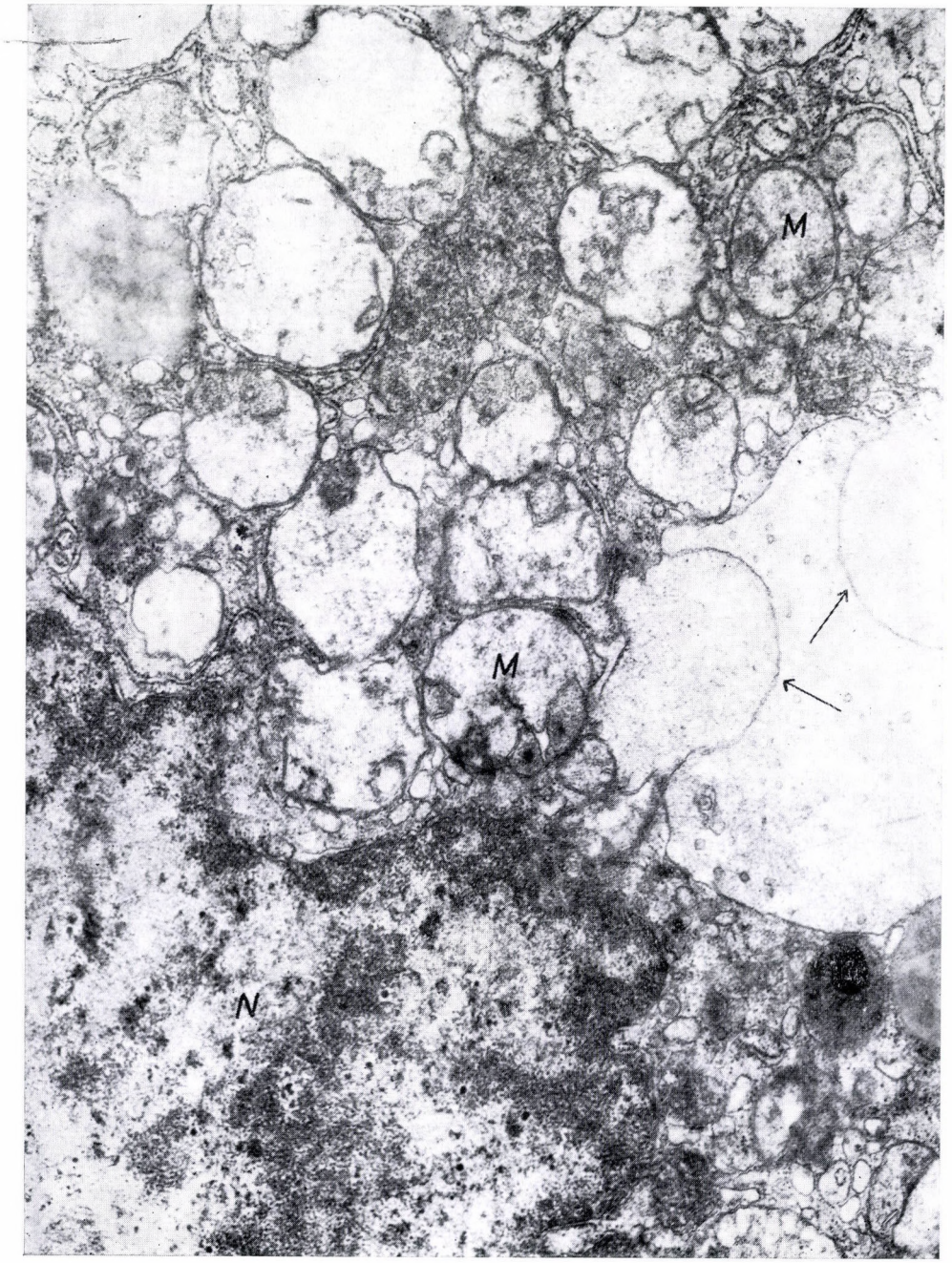

Fig. 7. Electron microscopic appearance of the liver from an animal killed after 5-month ANIT treatment. Part of the nucleus (N) and the cytoplasm of a liver cell is shown. The mitochondria exhibit severe alterations. Most of them are swollen, the crista system is extensively destroyed. On the right a large vacuole is visible. In the areas marked by arrows the organelle-free parts of the adjacent cytoplasms from "mammillary projections" (Steiner et al., 1963). ×35,000

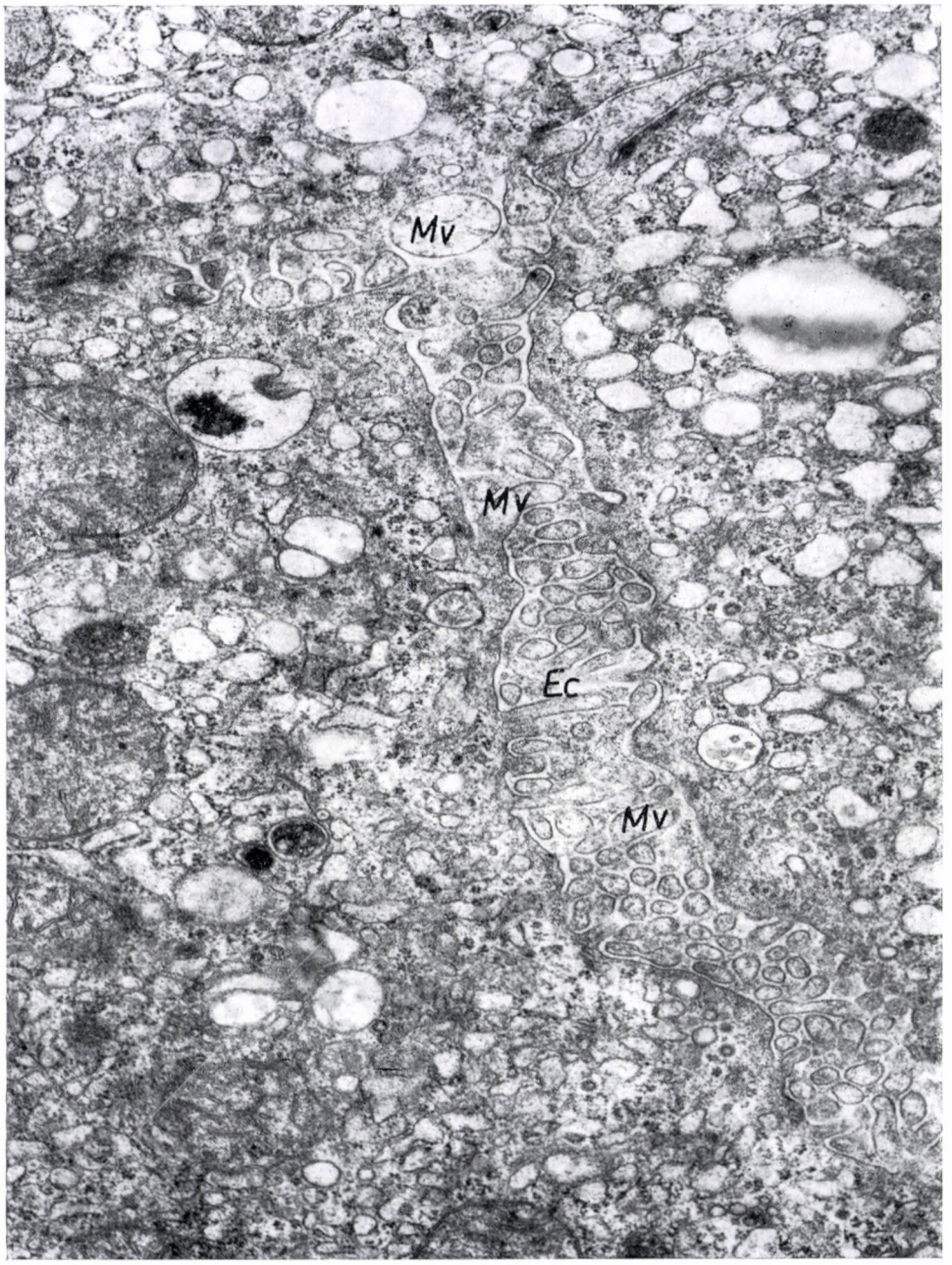

Fig. 8. Electron microscopic appearance of liver tissue from a rat killed after 5-month ANIT treatment. Note in between 3 liver cells an elongated biliary canaliculus (Ec), the canalicular surface is covered by many microvilli (Mv). ×35,000

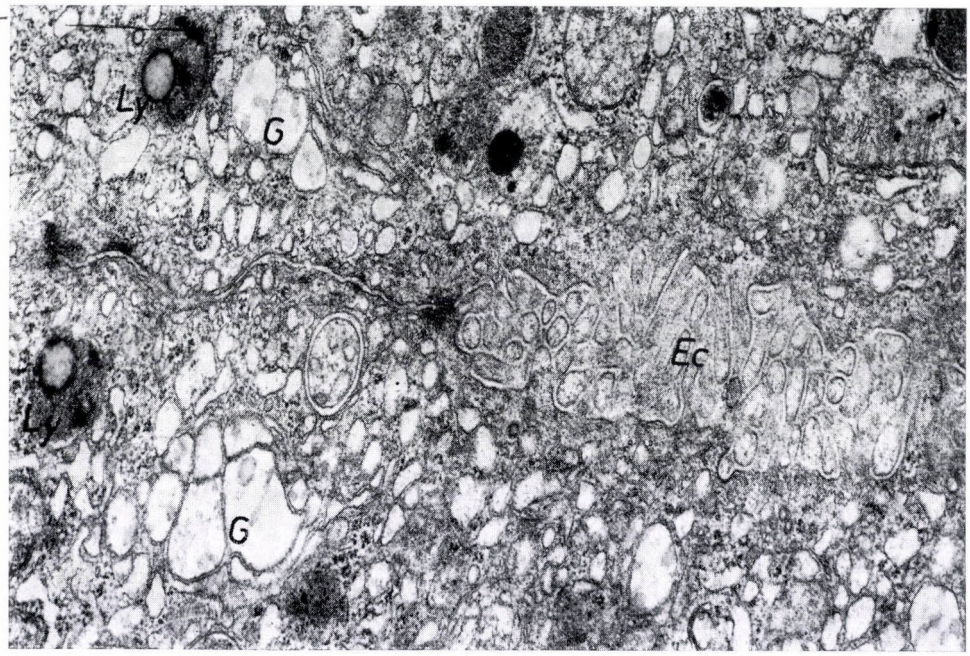

Fig. 9a. Electron microscopic appearance of liver tissue from an animal killed after 5-month ANIT treatment. Elongated biliary canaliculus (Ec) with many microvilli. Near the biliary canaliculus in both neighbouring liver cells an extensive Golgi zone is visible, with round deposits in their dilated saccules. In their vicinity, lysosomes (Ly) are visible. ×35,000

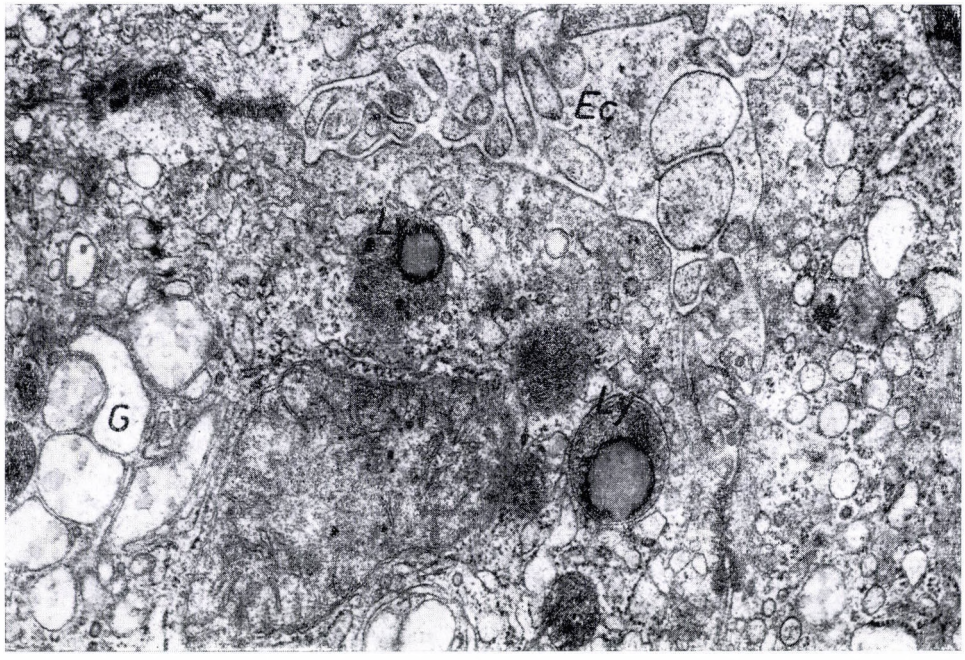

Fig. 9b. Electron microscopic appearance of liver tissue from an animal killed after 5-month ANIT treatment. In the vicinity of a biliary canaliculus (Ec) there is an extensive Golgi zone (G), with round deposits of medium electron density in the lumen of its sacculi. Lysosomes (Ly) between the Golgi zone and the biliary canaliculus. ×35,000

Ductular proliferation

As described previously [3], in response to subacute ANIT treatment, the trabecular, progressive proliferation of ductular cells became predominant, regressing in the course of chronic treatment.

Under the electron microscope, the ductular cells, arranged usually in groups or bundles, were sharply distinct from the adjacent liver cells. They were mostly oval in shape, had relatively large, round, oval or irregularly shaped nuclei. The cytoplasm contained few organelles and less and smaller mitochondria than did the liver cells. The characteristic features of the cytoplasm of proliferating ductular cells were a scarce, poorly developed endoplasmic reticulum, the few free ribosome granules and the low electron density (Fig. 10). Some single swollen microvilli occurred at some cellular junctions. Microvilli were visible on the liver cell surface bordering the proliferating ductular cells. A basement membrane was never observed around the proliferating ductular cells.

Some proliferating ductular cells were arranged in small groups and formed structures similar to ductules, but they never contained a lumen and no basement membrane developed around them (Fig. 11). These cells were often irregular, processed, ramifying several times. Autophagous vacuoles were common in their cytoplasm (Fig. 12).

Discussion

The hepatic changes induced by ANIT treatment may be classified into three main groups on the basis of electron microscopic evidence.

1) Changes of the bile secreting apparatus,
2) Changes of the liver cell organelles,
3) Ductular proliferation.

At 24 to 48 hours following a single dose of ANIT, the biliary canaliculi showed changes similar to those induced by ligation of the biliary ducts [1, 2]. The dilatation of canaliculi and the destruction of microvilli reached a peak on the 3rd day, in agreement with the results of light microscopic studies, in which the severest ductular destruction and the temporary rise in the serum bilirubin level were observed at the same point of time [3]. The damage to the canalicular membrane was attributed to a direct toxic action of ANIT by STEINER et al. [26, 28], as well as SPYCHER and RÄTTNER [23, 24]. The functional disturbance of the damaged canalicular membrane has been proved by enzyme chemical methods: in the affected canalicular membrane, ATPase [4], alkaline phosphatase and 5-nucleotidase [6] activity decreased.



Fig. 10. Electron microscopic appearance of liver tissue from an animal killed after 3-week ANIT treatment. There are ductular cells (DSI, DSII) in the interspace separating three liver cells (HI, HII, HIII). The ductular cells may be readily distinguished from the liver cells: their cytoplasm is lighter, they contain less organelles. The nuclei (N) are relatively large, the cytoplasmic lining is narrow. The nucleus of the ductular cell on the left (DSI) is round, on the right (DSII) it is oval, slightly irregular, at the junction of the two ductular cells a few microvilli (Mv) are visible. The surface of the liver cells is covered by microvilli in the areas adjacent to the ductular cells. $\times 21{,}000$



Fig. 11. Electron microscopic appearance of liver tissue from an animal killed after 3-week ANIT treatment. Three ductular cells (DSI, DSII, DSIII) with the narrow cytoplasmic margin of neighbouring liver cells. Between the ductular cells no lumen is visible and around them no basement membrane has formed. The cytoplasm is poor in organelles. The upper ductular cell (DSI) contains a large autophagous vacuole (Av). ×21,000

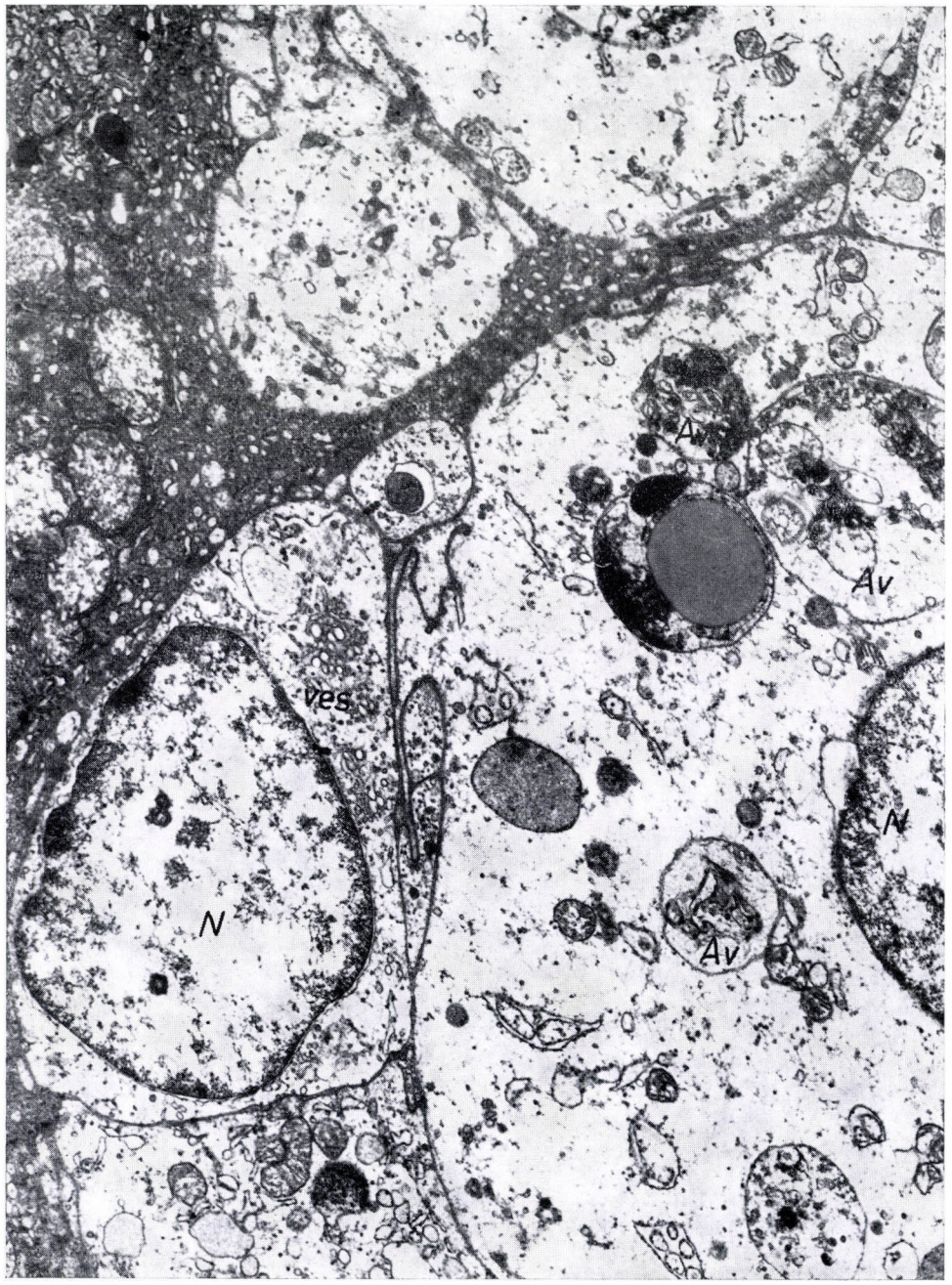

Fig. 12. Electron microscopic appearance of liver tissue from an animal killed after 4-month ANIT treatment. Parts of ductular cells are visible. Note the processed shape of the cells, the presence in the cytoplasm of many autophagous vacuoles (Av), as well as the accumulation in small groups of the small vesicles (vs) of smooth-surfaced endoplasmic reticulum. The ductular elements are in direct contact with the adjacent liver cell. No basement membrane has developed. ×21,000

Seven to ten days after a single dose of ANIT the fine structure of the canaliculi was completely restored. During subacute or chronic ANIT treatment, canalicular dilatation and destruction of microvilli occurred focally, while in other areas there were excessively distended biliary canaliculi, often with elongated microvilli resembling the fingers of a glove. According to SPYCHER and RÄTTNER [24] this phenomenon would be a sign of regeneration following destruction. In our material, dilated biliary canaliculi with partially or totally destroyed microvilli persisted throughout the experiment, and there were regenerated canaliculi possessing numerous elongated microvilli. Thus, according to our observations canalicular destruction and regeneration continuously varied during the experimental period. In chronic experiments. GOLDFARB et al. [9] found persistent hydrocholeresis after an initial cholestasis. Our results suggested that the extension of the biliary surface of liver cells and the increase of the secretory surface by the numerous elongated microvilli would be the morphological substrate of the enhanced secretory activity.

During subacute treatment the electron microscopic findings significantly differed from those obtained by light microscopy. While the conventional histological methods showed intact liver cell structures [3], electron microscopy revealed profound alterations, first of all in the ergastoplasm and the mitochondria. In the literature these are considered non-specific cellular reactions [24, 26].

In the chronic experiment the marked changes in the Golgi zones were conspicuous. By immunological methods, ZLOTNICK et al. [31] proved that, like the cancerogenic agents, ANIT in toxic doses produced alterations in the composition of the liver cell proteins. As demonstrated in the figures, the destroyed Golgi zones contained accumulations of foreign material in their elements exhibiting saccular distension. From this it has been concluded that in response to ANIT the bile underwent changes so that the Golgi apparatus was unable to eliminate it, and the foreign product stayed in between the elements of the Golgi zone. The increased numbers of lysosomes in the vicinity of the Golgi apparatus might also serve the uptake of this pathological product.

In our light microscopic studies [3] treatment with ANIT for 3 to 4 weeks resulted in an excessive vascular proliferation of the ductular cells, which proved to be reversible on continued administration. Electron microscopy then revealed underdeveloped ductular cells poor in organelles, and these processed cells with multiple ramifications were in loose contact with one another and their environment. There was no tendency to lumen formation and no basement membrane developed around the cells. Their cytoplasm exhibited an intense autophagous activity. In our opinion the anatomical basis of the reversibility of the process was represented by the small number of organelles in the ductular cells proliferating in response to ANIT and by the increased autophagous activity. At variance with our findings, STEINER and CARRUTHERS [27] found

in response to ANIT treatment a proliferation of well-developed cells rich in free ribosomes and organelles, similar to the ductular proliferation induced by a ligation of the bile ducts. It is assumed that the difference between our results and those published by other workers was due to the difference in the mode of ANIT administration.

REFERENCES

1. Balázs, M.: (1971) Kísérletes extrahepatikus cholestasis elektronmikroszkópos vizsgálata. Morph. Igazságü. Orv. Szle. **11,** 1. — 2. Balázs, M., Kertész, T.: (1969) Adatok a kísérletes extrahepatikus cholestasis pathomorphológiai képéhez. Kísérl. Orvostud. **21,** 181. — 3. Balázs, M., Medveczky, E.: (1968) Acute, Subacute and Chronic Effect of Alpha-naphthyl-isothiocyanate on the Liver of the Rat. Acta morph. Acad. Sci. hung. **16,** 413. — 4. Breitfellner, G., Holzner, J. H., Schumacher, A., Stefenelli, N.: (1966) Die elektronenoptischen und die nach enzymhistochemischer Darstellung der ATP-ase erkennbaren Veränderungen der Rattenleber bei experimenteller intrahepatischer Cholestase. Beitr. path. Anat. allg. Path. **134,** 267. — 5. Cameron, G. R., McLean, M. R., Prasad, L. B.: (1960) Recovery from the Bile Duct Hyperplasia Induced by Feeding Alpha-naphthyl-isothiocyanate to Rats. J. Path. Bact. **80,** 137. — 6. Desmet, V. J., Krstulovic, B., van Damme, B.: (1968) Histochemical Study of Rat Liver in Alpha-naphthyl isothiocyanate (ANIT) Induced Cholestasis. Amer. J. Path. **52,** 401. — 7. Eliakim, M., Eisner, M., Ungar, H.: (1951) Experimental Intrahepatic Obstructive Jaundice Following Ingestion of Alpha-naphthyl-isothiocyanate. Bull. Res. Counc. Israel. **8** E×7. — 8. Garay, E. R., Perez, V., Noir, B., Royer, M.: (1965) Chronic Intoxication Induced by Alpha-naphthylisothiocyanate. Arch. Path. **80,** 127. — 9. Goldfarb, S., Singer, E. J., Popper, H.: (1962) Experimental Cholangitis due to Alpha-naphthyl-isothiocyanate (ANIT). Amer. J. Path. **40,** 685. — 10. Ito, N., Marugami, M., Nakamura, H., Sasaki, S., Okajima, E., Kisimura, H.: (1962) On the Relationship between the Functional Activity of Reticulo-endothelial System and Quantitative Histology in the Liver of Rats Ingesting DL-ethionine, Thioacetamide or Gann. **53,** 235. — 11. Krstulovic, B., van Damme, B., Desmet, V. J.: (1968) Comparative Histochemical Study of Rat Liver in Bile-duct Ligation and in Alpha-naphthyl-isothiocyanate (ANIT) Intoxication. Amer. J. Path. **52,** 423. — 12. Lopez, M., Mazzanti, I.: (1955) Experimental Investigation on Alpha-naphthyl-isothiocyanate as a Hyperplastic Agent of the Biliary Ducts in the Rat. J. Path. Bact. **69,** 243. — 13. McLean, M. R., Rees, K. R.: (1958) Hyperplasia of Bile-ducts Induced by Alpha-naphthyl Isothiocyanate. Experimental Biliary Cirrhosis Free from Biliary Obstruction. J. Path. Bact. **76,** 175. — 14. Moran, E., Ungar, H.: (1964) The Effect of Intermittent Administration of Alpha-naphthyl Isothiocyanate to Rats. Amer. J. Path. **44,** 947. — 15. Moran, E., Eliakim, M., Suchowolski, A., Ungar, H.: (1961) Serum Vitamin B 12 and Glutamic-oxalacetic Transaminase in Experimental Intrahepatic Obstructive Jaundice. Gastroenterology, **40,** 408. — 16. Moran, E. M., Eliakim, M., Ungar, H.: (1965) The Effect of Cortisone on Cholangitis Induced by Alpha-naphthyl Isothiocyanate in Rats. Gastroenterology, **48,** 773. — 17. Phillips, M. J., Steiner, J. W.: (1964) Comparative Study of Alpha-naphthyl Isothiocyanate Induced Liver Injury. Lab. Invest. **13,** 779. — 18. Roberts, R. J., Plaa, G. L.: (1966) The Effect of Bile Duct Ligation, Bile Duct Cannulation and Hypothermia on Alpha-naphthyl Isothiocyanate Induced Hyperbilirubinaemia and Cholestasis in Rats. Gastroenterology, **50,** 768. — 19. Roberts, R. J., Plaa, G. L.: (1965) Potentiation and Inhibition of Alpha-naphthyl Isothiocyanate Induced Hyperbilirubinaemia and Cholestasis. J. Pharmacol. exp. Ther. **150,** 499. — 20. Roberts, R. J., Plaa, G. L.: (1967) Effect of Norethandrolone, Acetohexamide and Enovid on Alpha-naphthyl Isothiocyanate Induced Hyperbilirubinaemia and Cholestasis. Biochem. Pharmacol. **16,** 827. — 21. Roberts, R. J., Plaa, G. L.: (1967) Alteration of the Plasma Disappearance and Biliary Excretion Patterns of Exogenously Administered Bilirubin by Alpha-naphthyl Isothiocyanate. J. Pharmacol. exp. Ther. **155,** 330. — 22. Rouiller, Ch. (Ed.): The Liver. Vol. 2. P. 421. Academic Press, New York, 1964. — 23. Rättner, J. R., Spycher, M. A., Kuenzle, C.: (1964) Zur Pathologie des Ikterus. Der ANIT-induzierte Ikterus der Ratte, ein Modell einer durch Schädigung bedingten toxischen Hepatose. Path. et Microbiol. (Basel) **27,** 403. — 24. Spycher, M. A., Rättner, J. R.: (1964) Zur Pathologie des Ikterus. Elektronenmikroskopische Untersuchungen über die Frühveränderungen der Leber-Parenchymzellen beim Alpha-naphthyl-isothiocyanate induzierten Ikterus der Ratte. Path. et Microbiol.

Basel), **27,** 387. — 25. Stefenelli, N., Holzner, J. H.: (1965) Cholestasis in the Rat by One Dosage Alpha-naphthyl Isothiocyanate (ANIT). Histological and Enzyme Histochemical Changes in the Liver. Z. Ges. exp. Med. **139,** 762. — 26. Steiner, J. W., Baglio, Cm. M.: (1963) Electron Microscopy of the Cytoplasm of Parenchymal Liver Cells in Alpha-naphthyl Isothiocyanate Induced Cirrhosis. Lab. Invest. **12,** 765. — 27. Steiner, J. W., Carruthers, J. S.: (1963) Electron Microscopy of Hyperplastic Ductular Cells in Alpha-naphthyl Isothiocyanate Induced Cirrhosis. Lab. Invest. **12,** 471. — 28. Steiner, J. W., Phillips, M. J., Baglio, C. M.: (1963) Electron Microscopy of the Excretory Pathways in the Liver in Alpha-naphthyl Isothiocyanate Intoxication. Amer. J. Path. **43,** 677. — 29. Steiner, J. W., Phillips, M. J., Miyai, K.: (1964) Alpha-naphthyl Isothiocyanate (ANIT) Poisoning. Int. Rev. exp. Path. **3,** 65. — 30. Ungar, H., Moran, E., Eisner, M., Eliakem, M.: (1962) Rat Intrahepatic Biliary Tract Lesions from Alpha-naphthyl Isothiocyanate. Arch. Path. **73,** 427. — 31. Zlotnick, A., Horowitz, A., Ungar, H.: (1965) Alteration in Rat Liver Antigenicity by the Administration of Alpha-naphthyl Isothiocyanate. Israel J. Med. **1,** 244.

ELEKTRONENMIKROSKOPISCHE UNTERSUCHUNG DES DURCH α-NAPHTHYL-ISOTHIOCYANAT-(ANIT-)GABEN BEWIRKTEN LEBERSCHADENS

M. BALÁZS

Die unter Wirkung von α-Naphthyl-isothiocyanat-Gaben entstehenden experimentellen Leberveränderungen wurden elektronenmikroskopisch untersucht.

Das akute Stadium ist durch die Schädigung des Gallensekretionsapparates gekennzeichnet.

In der subakuten Phase stehen schwere progressive Veränderungen der Leberzellenorganellen, ferner die strangförmige Proliferation der an Organellen armen Zellen der Gallengänge im Vordergrund.

Im chronischen Versuch progredieren die in der Mikrostruktur der Leberzellen wahrnehmbaren pathologischen Veränderungen, während die im subakuten Versuch augenfällige intensive Proliferation der Gallengänge sich zurückentwickelt. Diese letzte Erscheinung wird mit der Gewöhnung an das Mittel erklärt, die mit der wöchentlich zweimaligen Verabreichung zusammenhängen dürfte.

ЭЛЕКТРОННОМИКРОСКОПИЧЕСКОЕ ИЗУЧЕНИЕ ПОРАЖЕНИЯ ПЕЧЕНИ, ВЫЗВАННОГО ДАЧЕЙ АЛЬФА-НАФТИЛЬ-ИЗОТИОЦИАНАТА (АНИТ)

М. БАЛАЖ

Автор изучал при помощи электронного микроскопа экспериментальные изменения печени, возникающие после дачи альфа-нафтиль-изотиоцианата (АНИТ).

Острая фаза характеризуется поражением секреторного аппарата желчи.

В подострой фазе на переднем плане находятся тяжелые, прогрессирующие изменения органелл печеночных клеток и фасцикулярное разрастание бедных органеллами клеток желчного протока.

В хроническом опыте прогрессируют патологические изменения, наблюдавшиеся в микроструктуре печеночных клеток, однако поразительное, интенсивное разрастание клеток желчных протоков, наблюдавшееся в подострой фазе, развивается обратно. Последнее явление автор объясняет привыканием к препарату, что предположительно связано с тем, что АНИТ давали два раза в неделю.

Dr. Márta Balázs, Orvostovábbképző Intézet, Budapest XIII., Szabolcs u. 33., Hungary

Acta Morphologica Acad. Sci. Hung. 19 (3), pp. 233—240, 1971

Oncopathological Research Institute (Director: Prof. B. KELLNER), Budapest

ELECTRON MICROSCOPIC STUDIES ON THE SPECIFICITY OF THE PA-SILVER REACTION

O. CSUKA and J. SUGÁR

(Received January 19, 1971)

The specificity of the periodic acid-silver methenamine reaction (PA-silver reaction, i.e. Schiff's periodic reaction adapted for electron-microscopic examinations) has been studied in tissues from various organs (kidney, breast, skin). After periodic acid oxidation by this method it is possible to demonstrate the presence of glycoproteins and sialomucin, which can be seen on the cell surfaces, in the cytoplasmic organelles (lysosomes, secretory granules) and in the basement membranes. Digestion with trypsin weakens the specific reaction in the basement membranes and on the cell surfaces, while digestion with neuraminidase does not have this effect. The non-specific reaction appearing in the cytoplasm and the nucleus without previous periodic acid oxidation can be considerably weakened by agents blocking the -SH group, such as p-chloromercuric benzoate or monoiodoacetic acid. Acetylation and the blocking of the aldehyde group render the specific reaction negative and arrest some of the non-specific reactions.

Introduction

The electron microscopic demonstration of carbohydrates can be achieved by various histochemical procedures. The presence of acid mucopolysaccharides can be demonstrated by means of metal colloids adsorptively bound by the negative surface charge such as iron colloid [2, 5, 6, 8, 19, 28], colloidal thorium [23] and ruthenium red [12, 13, 26]. The periodic acid-silver methenamine reaction (PA-silver reaction, i.e. Schiff's periodic reaction adapted for electron-microscopic examinations [16, 18, 20, 21, 22, 24, 25]) makes it possible to identify intracellular and extracellular glycoproteins and neutral mucopolysaccharides. The boundary between epithelium and connective tissue, which stains only slightly with metal colloids can clearly be shown with the PA-silver reaction which reveals the presence of glycoproteins at sites not amenable to light-microscopic inspection (cell coat, certain cytoplasmic organelles).

Periodic acid oxidation causes the transformation of 1,2 glycol and alpha aminohydroxy groups into aldehyde groups which reduce the silver from the argentohexamethylene tetramine solution. Without previous periodic acid oxidation the sections show non-specific deposits of silver in the nuclei, in the red blood cells, in the keratin, etc. In the present experiments, the specificity of the PA-silver reaction has been studied.

Material and method

Kidney and skin of Swiss mice, epithelial hyperplasia and carcinoma induced in the skin by 20-methyl-cholanthrene, human thyroid and mammary tissue served as test objects.

One cu.mm pieces of these tissues were fixed in a 2.5% solution of glutaraldehyde buffered by 0.14 M cacodylate at 4°C for 2 hours. The samples were washed overnight with this buffer (pH 7.2), dehydrated, and then embedded in Durcupan (ACM, Fluka). Sections prepared by means of an LKB ultramicrotome were collected in distilled water, oxidized for 20 to 25 min in a 1% solution of periodic acid at room temperature, washed in distilled water three times for 10 min and then left in distilled water for 8 hrs. Unoxidized sections served as controls. Both the oxidized and the unoxidized sections were incubated at 60°C for 60 to 180 min, depending on the type of tissue.

Composition of the incubation fluid: 40 ml of 3% hexamethylene tetramine, 5 ml of 5% silver nitrate, 5 ml of 2% sodium borate, pH = 9 [21]. After incubation the sections were washed in distilled water for 5 min and then rinsed twice in 5% sodium thiosulphate for 15 min. The sections were transferred from one solution to the other by means of a platinum loop, and only after this treatment were they placed on grids.

Blocking reactions. Blocking of the -SH groups was achieved in ultrathin sections by means of either 0.5 M monoiodoacetic acid or 10 mM p-chloromercuric benzoate (PCMB), at 60°C for 90 min. The pH was adjusted to 9.0 using sodium hydroxide. Blocking of the aldehyde group before and after periodic acid oxidation was carried out in ultrathin sections by treatment with a 2% solution of sodium bisulphite at 25°C for 180 min or at 60°C for 60 min.

Acetylation — known to esterify 1,2 glycol and 1,2 aminohydroxy groups — was carried out on the 1 cu.mm tissue fragments fixed in glutaraldehyde. The samples were then treated with a 1 : 3 mixture of acetic anhydride and pyridine at 60°C for 4—8 hrs [11].

Enzymatic digestion. The fixed blocks of tissue were digested using 0.1 mg/ml trypsin dissolved in phosphate buffer pH 7.6 at 37°C for 4—16 hrs. Digestion at 37°C with sialidase (300 U/ml *Vibrio cholerae*) dissolved in pH 6.0 phosphate buffer lasted 24 hrs.

Results

Following periodic acid oxidation, reduced silver appeared in the form of 20 to 30 Å electron-dense granules at the sites where glycoprotein was present, viz. on the surface of cells, in cytoplasmic organelles (lysosomes, secretory granules, ribosomes) and in the basement membranes (Figs 1, 2). Deposits of silver on the brush border of the proximal convoluted tubules of the kidney, in the numerous infoldings of the cell membranes facing the basement membrane in the cells of the proximal and distal convoluted tubules, and also on the surface of the endothelial cells of the capillaries, indicated the presence of a coat rich in glycoproteins. The presence and growth of this coat were demonstrated in numerous other test objects as well, e.g. in the induced hyperplasia and carcinoma of mice, and in human mammary disease. Digestion with trypsin diminished the staining reaction of the cell coat, while digestion with sialidase left it unchanged.

No deposits of silver were found on the cell surfaces after PA-silver reaction preceded by acetylation. -SH blocking agents had no effect on the intensity of the surface-bound reaction: nor did specific reactions, i.e. those bound to cytoplasmic structures (lysosomes, secretory granules, ribosomes), become weaker by -SH blockage.

PA-silver reaction was positive in respect of the basement membranes (basal laminae), and the collagenous and reticular fibres belonging to them, as

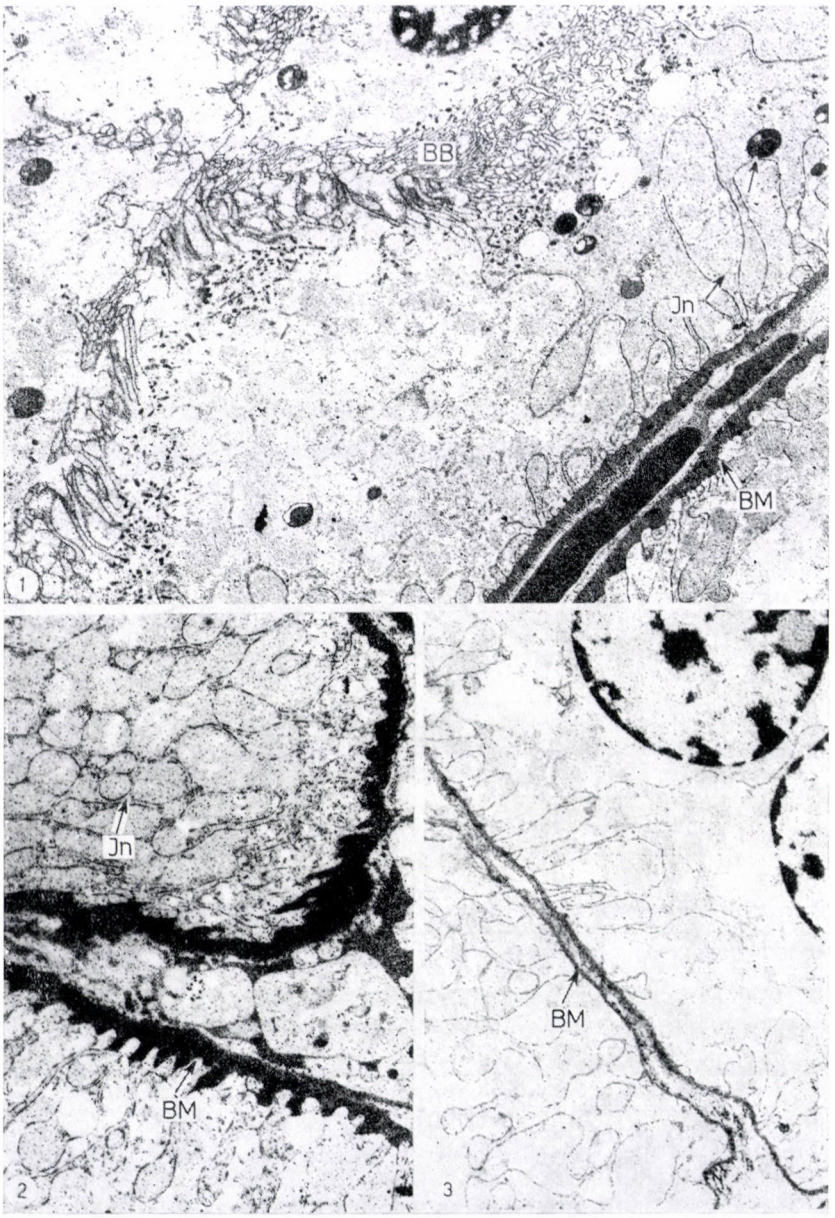

Fig. 1. PA-silver reaction in a proximal convoluted tubule of mouse kidney. Specific staining, as shown by deposits of electron-dense silver in the basement membrane (BM), the brush border (BB), membrane infoldings (In) and the cytoplasmic organelles (arrows) indicates the presence of glycoproteins. The fine granular diffuse staining of the cytoplasm and the staining of the nucleus are results of aspecific reactions. 2150×2.5

Fig. 2. PA-silver reaction in the basal part of a proximal convoluted tubule. Specific staining in the basement membrane (BM), and membrane infoldings (In). 2300×3.5

Fig. 3. PA-silver reaction after 6-hour digestion with trypsin. Note decreased staining of the basement membrane (BM) of the distal convoluted tubule as well as that of the infoldings of the membrane (arrow), as compared to Figures 1 and 2. 4000×2.5

well as on the cell surface facing the basement membranes. These three layers form an 800 to 1000 Å thick electron-dense zone in which it is difficult to distinguish them; only in the thyroid gland do the collagenous fibres give a somewhat stronger staining reaction, and can therefore be distinguished from the basement membrane. Digestion with trypsin reduces the staining of the basement membranes, while treatment with sialidase leaves it practically unchanged (Figs 3, 4). The staining of the basement membranes, and similarly that of the glomerular membranes is partially obliterated by acetylation and treatment with sodium bisulphite (Fig. 5). Residual staining after such treatment is the same as that exhibited by unoxidized control preparations.

Silver may be deposited without periodic acid oxidation in the nuclei, and also in a non-structure-bound form in the cytoplasm and in the collagenous fibres (Fig. 6). Blockage of the -SH group diminished the diffuse cytoplasmic reaction quite considerably, and, to a lesser extent, also the nuclear reaction, but it has no effect on the staining of Bowman's capsule, the epithelium and the basement membranes of the glomeruli (Fig. 7). Treatment with sodium bisulphite blots out the staining of the collagenous fibres.

Discussion

There are numerous references in the literature indicating the presence of carbohydrates covering the surface of cells [4, 5, 10, 17, 26]. Electron-microscopic histochemistry shows this coat to be composed of acid mucopolysaccharides [4, 5, 26] and glycoproteins [20, 21] and sialic acid — partially responsible for the negative charge of the cell surface — also gives the PA-silver reaction [20, 27]. After neuraminidase (sialidase) digestion, the intensity of the PA-silver reaction is unchanged, possibly because this treatment may remove only a terminal sialic acid moiety of the polysaccharide chain. The various carbohydrate components remaining on the cell surface continue to give a positive PA-silver reaction.

The lysosomes and ribosomes, and also the secretory granules of the thyroid and mammary cells give a positive reaction. The lysosomes take the stain because the glycoproteins are decomposed by their own enzymes: glycosidase [1, 14] and neuraminidase [7].

The PA-silver reaction in the ribosomes is not due to the aldehyde groups formed from carbohydrates, but to those formed from hydroxyamino acids (serine, threonine, hydroxylysine).

Electron-microscopic examination reveals several structures at the junction of the epithelium and the connective tissue, thus;

1) basement membrane (basal lamina) of medium electron density which is parallel to the basal cell surface;

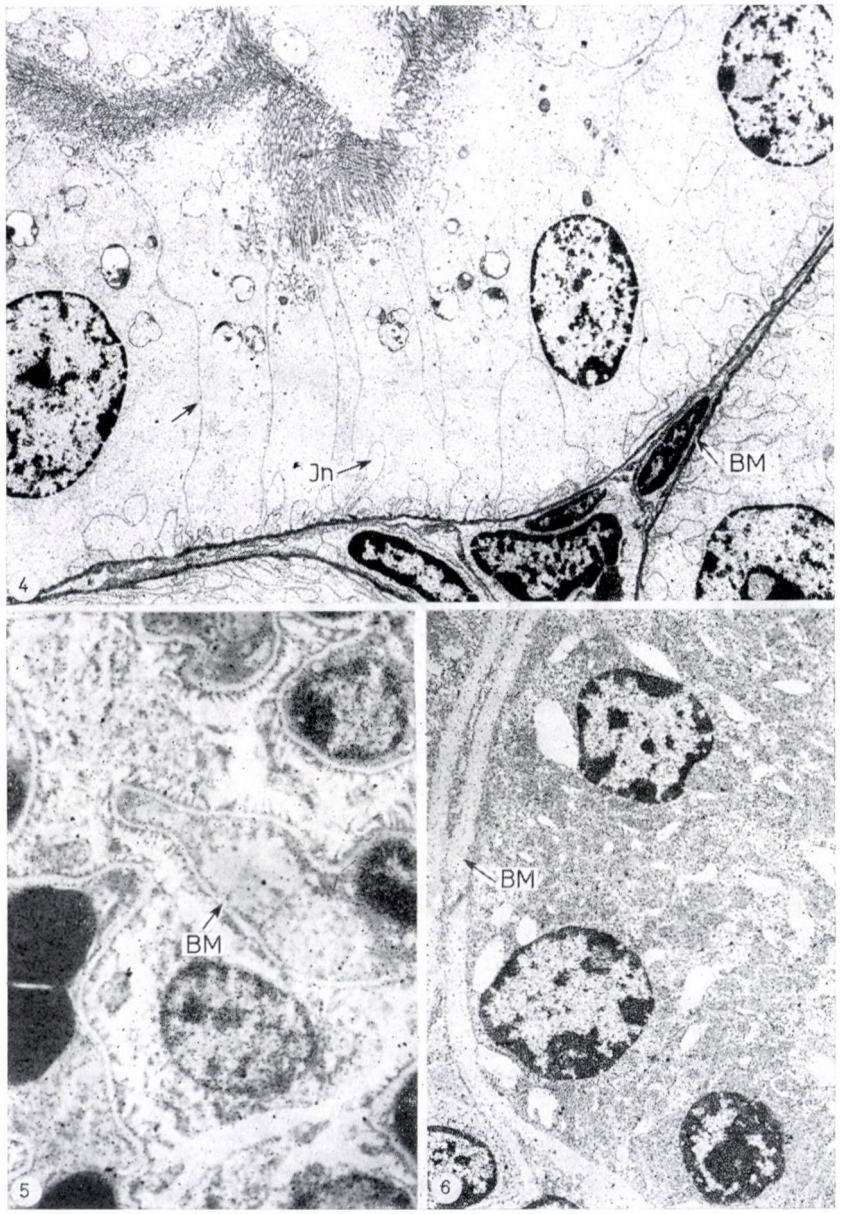

Fig. 4. 24-hour digestion with neuraminidase does not affect the staining of the basement membrane (BM), the cell surfaces (arrows) and the membrane infoldings (In). 1750×2.5

Fig. 5. PA-silver reaction following acetylation. The site of the extinguished specific staining of the glomerular basement membrane (BM) is occupied by an electron-lucent band. 1900×2.5

Fig. 6. Non-oxidized control section after silver-hexamethylene tetramine treatment. Aspecific staining of nucleus and cytoplasm; the basement membrane (BM) did not stain. 2450×2.5

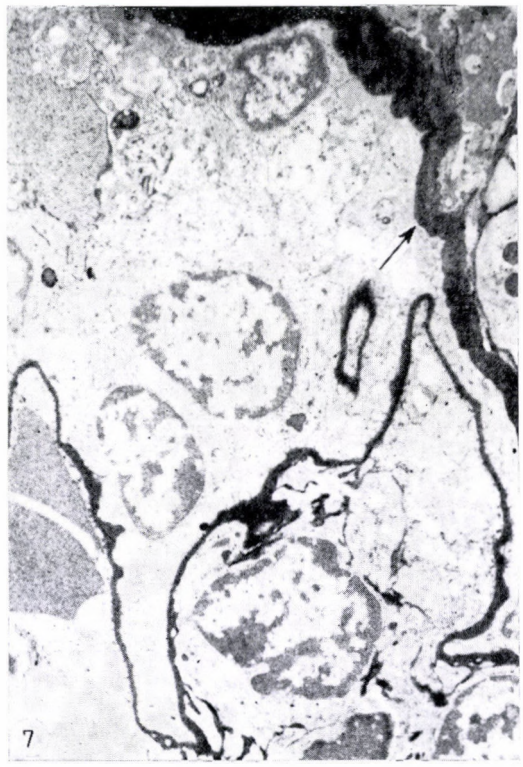

Fig. 7. PA-silver reaction in renal glomerulus following -SH blockage. The aspecific staining of the nucleus and cytoplasm has decreased, while the specific reaction of the glomerular basement membrane and Bowman's capsule is unchanged (arrow). 1750 × 2.5

2) an electron-lucent layer measuring 300 Å in thickness which lies between the basement membrane and the cell surface;

3) layer of reticular and collagenous connective-tissue fibres which is in close contact and constitutes a morphologically common structure with the basal lamina.

Biochemical analysis [9, 15] and the PA-silver technique demonstrate the presence of much glycoprotein at the boundary between epithelium and connective tissue. The fact that digestion with trypsin reduces the silver-methenamine staining of the basement membranes indicates that the majority of carbohydrate is bound to protein. Some authors [25] hold that only the collagenous fibre layer is stained by PA-silver and that this layer would represent the basement membrane visible under the light microscope.

All of the above mentioned three layers at the junction of epithelium and connective tissue and on the surface of the basal cells appeared to be PA-silver positive in our experiments, and we suggest that the whole of the electron-dense

zone formed by them represents the basement membrane seen under the light microscope.

The existence of non-specific reactions makes the examination of unoxidized preparations necessary. The reaction must not be regarded as specific unless it appears after periodic acid oxidation but does not do so in the unoxidized control sections [21].

Using various blocking procedures it was possible to clarify the causes of the non-specific staining observed without periodic acid oxidation.

Treatment with sodium bisulphite blocks the free aldehyde groups of the mucopolysaccharides contained in the fibres and so obliterates the staining of collagenous fibres [3]. The application of -SH blocking agents results in the blockage of -SH containing amino acids which weakens the diffuse non-specific staining of the cytoplasm. -SH blockage in the nucleus affects only the free -SH groups of the nascent proteins so that non-specific staining of the nucleus is slightly decreased, while the binding of silver by the basic proteins and the phosphates of the nucleic acid continues unchanged. Acetylation arrests all specific reactions, i.e. those occurring on the cell surfaces, as well as in the basement membranes, and also those shown by the cytoplasmic organelles. It is in this manner that the specific staining of the cell surfaces, the cytoplasmic granules, the colloids of the thyroid and that of the basement membranes has been verified.

REFERENCES

1. Beck, C., Mahadevan, S., Brightwell, R., Dillard, C. J., Tappel, A. L.: (1968) Chromatography of Lysosomal Enzymes. Arch. Biochem. **128,** 369. — 2. Curran, R. C., Clark, A. E., Lovell, D.: (1965) Acid Mucopolysaccharides in Electron Microscopy. The Use of the Colloidal Iron Method. J. Anat. **99,** 427—434. — 3. Davis, R. P., Janis, R.: (1966) Free Aldehydic Groups in Collagen and other Tissue Components. Nature (Lond.) **210,** 318—319. 4. Gasic, F., Gasic, T.: (1962) Removal and Regeneration of the Cell Coating in Tumour Cells. Nature (Lond.) **196,** 170—171. — 5. Gasic, G., Berwick, L.: (1963) Hale Stain for Sialic Acid-containing Mucins. Adaptation to Electron Microscopy. J. Cell Biol. **19,** 223—228. — 6. Gasic, G., Berwick, L., Sorrentino, M.: (1968) Positive and Negative Colloidal Iron as Cell Surface Electron Stains. Lab. Invest. **18,** 63—71. — 7. Horvát, Á., Touster, O.: (1968) On the Lysosomal Occurrence and Properties of the Neuraminidase of Rat Liver and of Ehrlich Ascites Tumor Cells. J. biol. Chem. **243,** 4380—4390. — 8. Jones, D. B.: (1969) Mucosubstances of the Glomerulus. Lab. Invest. **21,** 119—125. — 9. Kefalides, A. N., Denduchis, B.: (1969) Structural Components of Epithelial and Endothelial Basement Membranes. Biochemistry, **8,** 4613—4621. — 10. Langley, O. K., Ambrose, E. J.: (1964) Isolation of a Mucopeptide from the Surface of Ehrlich Ascites Tumour Cells. Nature (Lond.) **204,** 53—54. — 11. Lillie, R. D.: (1966) Histochemical Acylation of Aldehydes Produced by Periodic Acid Oxidation. J. Histochem. Cytochem. **14,** 529—538. — 12. Luft, J. H.: (1964) Electron Microscopy of Cell Extraneous Coats as Revealed by Ruthenium Red Staining. J. Cell Biol. **23,** 54. — 13. Luft, J. H.: (1966) Fine Structure of Capillary and Endocapillary Layer as Revealed by Ruthenium Red. Fed. Proc. **25,** 1773—1778. — 14. Mahadevan, C., Dillard, J., Tappel, A. L.: (1969) Degradation of Polysaccharides, Mucopolysaccharides, and Glycoproteins by Lysosomal Glycosidases. Arch. Biochem. **129,** 525—533. — 15. Mahieu, P., Winand, R. J.: (1970) Chemical Structure of Tubular and Glomerular Basement Membranes of Human Kidney. Eur. J. Biochem. **12,** 410—418. — 16. Marinozzi, U.: (1961) Silver Impregnation of Ultrathin Sections for Electron Microscopy. J. Biophys. Biochem. Cytol. **9,** 121—133. — 17. Miller, A., Sullivan, J. F., Katz, J. H.: (1963) Sialic Acid Content of the Erythrocyte and of an Ascites Tumor Cell of the

Mouse. Cancer Res. **23,** 485—490. — 18. MOVAT, H. Z.: (1961) Silver Impregnation Methods for Electron Microscopy. Amer. J. Clin. Pathol. **35,** 528—537. — 19. MOWRY, R. W.: (1958) Improved Procedure of the Staining of Acidic Polysaccharides by Müller's Colloidal (hydrous) Ferric Oxide and its Combination with Feulgen and the Periodic Acid-Schiff Reactions. Lab. Invest. **7,** 566—576. — 20. RAMBOURG, A., LEBLOND, C. P.: (1967) Electron Microscope Observations on the Carbohydrate-rich Cell Coat Present at the Surface of Cells in the Rat. J. Cell Biol. **32,** 27—53. — 21. RAMBOURG, A.: (1967) An Improved Silver Methenamine Technique for the Detection of Periodic Acid-reactive Complex Carbohydrates with the Electron Microscope. J. Histochem. Cytochem. **15,** 409—412. — 22. RAMBOURG, A., LEBLOND, C. P.: (1967) Staining of Basement Membranes and Associated Structures by the Periodic Acid-Schiff and Periodic-acid-silver Methenamine Techniques. (Letter to the Editor) J. Ultrastruct. Res. **20,** 306—309. — 23. REVEL, J. P.: (1964) A Stain for the Ultrastructural Localisation of Acid Mucopolysaccharides. J. Microscopy **3,** 535—544. — 24. SUZUKI, T., SEKIYOMA, S.: (1961) Application of Methenamine Silver Stain for Electron Microscopy. J. Electronmicroscopy (Tokyo) **10,** 36—42. — 25. SWIFT, J. A., SAXTON, C. A. J.: (1967) The Ultrastructural Location of the Periodate-Schiff Reactive Basement Membrane at the Dermoepidermal Junctions of Human Scalp and Monkey Gingiva. Ultrastruct. Res. **17,** 23—34. — 26. VORBRODT, A., KOPROWSKI, H.: (1969) Ruthenium Red-stained Coat of Normal and Simian Virus 40-Transformed Cells. J. nat. Cancer Inst. **43,** 1241—1248. — 27. WALLACH, D. F. H., EYLAR, E. H.: (1961) Sialic Acid in the Cellular Membranes of Ehrlich Ascites Carcinoma Cells. Biochem. Biophys. Acta (Amst.) **52,** 594—596. — 28. WETZEL, M. G., WETZEL, B. K., SPICER, S. S.: (1966) Ultrastructural Localization of Acid Mucosubstances in the Mouse Colon with Iron-containing Stains. J. Cell Biol. **30,** 299—317.

DIE ANWENDUNG DER PA-SILBERREAKTION FÜR ELEKTRONENMIKROSKOPISCHE UNTERSUCHUNGEN

O. CSUKA und J. SUGÁR

Die Spezifität der für Elektronenmikroskopie adaptierten PAS-Reaktion (Periodic acid-silver methenamine, PA-Silberreaktion) wurde in verschiedenen Organen untersucht (Nieren, Milchdrüsen, Schilddrüsen, Haut). Mit dieser Methode lassen sich nach Oxydation in Perjodsäure das Glykoprotein und das Sialomucin an den Zelloberflächen, in den Zytoplasmagranula (Lysosome, Sekretionsgranula) und in der Basalmembran spezifisch nachweisen. Nach Trypsinverdauung war die Färbung der Basalmembran und der Zelloberfläche weniger intensiv, während nach Sialidaseverdauung keine Abnahme der Färbungsintensität beobachet wurde. Die im Zytoplasma und in den Kernen ohne Oxydation in Perjodsäure vorkommende aspezifische Reaktion läßt sich durch Anwendung von -SH-Blockern (PCMB = p-Chlormerkuribenzoat, Monojodessigsäure) in hohem Maße vermindern. Durch Azetylieren und Blockieren der Aldehyd-Gruppe wird die spezifische Reaktion negativ und ein Teil der aspezifischen Reaktion aufgehoben.

ПРИМЕНЕНИЕ РЕАКЦИИ С ПЕРЙОДКИСЛЫМ СЕРЕБРОМ (PAS) ДЛЯ ЭЛЕКТРОННОМИКРОСКОПИЧЕСКОГО ИССЛЕДОВАНИЯ

О. ЧУКА и Я. ШУГАР

Специфичность адаптированной к микроскопии реакции с PAS (Periodic acid-silver methenamine), реакция с перйодкислым серебром была изучена в различных органах (почки, молочные железы, щитовидные железы, кожа). При таком методе после окисления четырехйодистой кислотой на клеточной поверхности, в зернышках цитоплазмы (в лизосомах, секреторных зернышках) и в базальной мембране можно специфически выявить гликопротеины и сиаломуцин. После переваривания трипсином базальная мембрана и клеточная поверхность окрашиваются менее интенсивно, в то время как после переваривания сиалидазой уменьшения окрашивания не наблюдается. В цитоплазме и в ядрах неспецифическую реакцию, наблюдаемую без окисления четырехйодистой кислотой, можно в существенной мере уменьшить применением — SH — блокаторов (ПХМБ = р-хлормеркурибензоат, монойодуксусная кислота). После ацетилирования и блокирования альдегидной группы специфическая реакция становится отрицательной и одна часть неспецифической реакции прекращается.

Orsolya CSUKA
Dr. János SUGÁR
Onkopathologiai Kutató Intézet, Budapest XII., Ráth György u. 5., Hungary

Acta Morphologica Acad. Sci. Hung. 19 (3), pp. 241—245, 1971

Institute of Forensic Medicine (Director: Prof. I. Gy. Fazekas), University Medical School, Szeged and Public Health Station (Director: J. Vetró), Szeged

HISTOCHEMICAL AND BIOCHEMICAL EXAMINATION OF β-GLUCURONIDASE ACTIVITY IN THE LIVER AND SERUM OF SEVERELY BURNED RATS

A. Basch, I. Gy. Fazekas, B. Rengei and L. Mindszenti

(Received November 11, 1970)

After causing 3rd degree burn over 20% of the body surface of rats, the activity of β-glucuronidase in their liver and serum was examined by histological and biochemical methods at stated intervals over 72 hours. It is suggested that the observed changes in activity of the enzyme were due to the 24-hour state of shock, associated with the burn, and should not be regarded as characteristic of hepatic injury due to burn.

Severe burns of the skin affect the entire organism. The liver has been observed to react by enlargement of its cells, fatty degeneration, turbid swelling, loss of glycogen, hydropic degeneration and sometimes necrosis [2, 14, 21]. Histological examination of the liver after a burn revealed hydropic degeneration in all cases. Baccino et al. [3, 4] observed an increased hydrolase activity following hydropic degeneration. It was shown by Nilius [20] and Pineda et al. [24, 25] that the activity of β-glucuronidase (one of the hydrolases) became more intensive in the serum in certain acute and chronic hepatopathies. The present study was undertaken to establish whether the changes in hepatic and β-glucuronidase activity were indicative of hepatic injury due to burns.

Material and method

Thirty-five male Wistar rats of 150 to 200 g body weight were divided into groups of five and superficially anaesthetized with ether. About 20% of the body surface (some 50 sq.cm of the skin) was then burnt (3rd degree), and the animals were decapitated 2, 6, 16, 24, 48 and 72 hours later. The serum was examined biochemically, the liver both biochemically and histochemically. The excised pieces of liver were frozen without delay with carbon dioxide snow according to Seligman et al. [27]; 12 μ cryostat sections were then incubated for 4½ hrs at 37°C in a solution of 6-bromo-2-naphthyl D glucuronide, pH 4.95. The preparations were stained with fast blue for 1 min. A dark (Prussian) blue or purple staining indicated the presence of β-glucuronidase, while a red or pink colour meant the decrease of its activity.

Immediately after decapitation, from the liver a 500 mg piece was excised, homogenized in a Potter-Elvehjem apparatus in the presence of an 8.5% ice cold sucrose solution and then centrifuged (800 r.p.m.) at 0°C for 30 min. The supernatant was divided into two parts. To one half, Triton X 100 in a dilution of 0.1% at a ratio of 1 : 10 was added, to achieve maximum solubility of the enzyme. After another centrifugation at 500 r.p.m. for 30 min., enzymatic activity was estimated photometrically by the method of Fishman et al. [15]. Values for the material treated with Triton X 100 indicate total enzymatic activity, those for the untreated supernatant show the activity of free enzyme. The same method was used for the determination of enzymatic activity in the serum in which only the activity of free enzyme was measured. The method is based on the fact that the β-glucuronidase contained in the test material releases

phenolphthalein from the substrate (phenolphthalein-glucuronide); it was then estimated colorimetrically in 10 mm cuvettes at 540 nm. Enzymatic activity is referred to protein: one unit means 1 μg phenolphthalein per 1 g protein, released after the incubation of 100 ml serum or 1 g tissue for an hour at 37°C from the 0.0025 M substrate buffered to pH 4.5 by acetate.

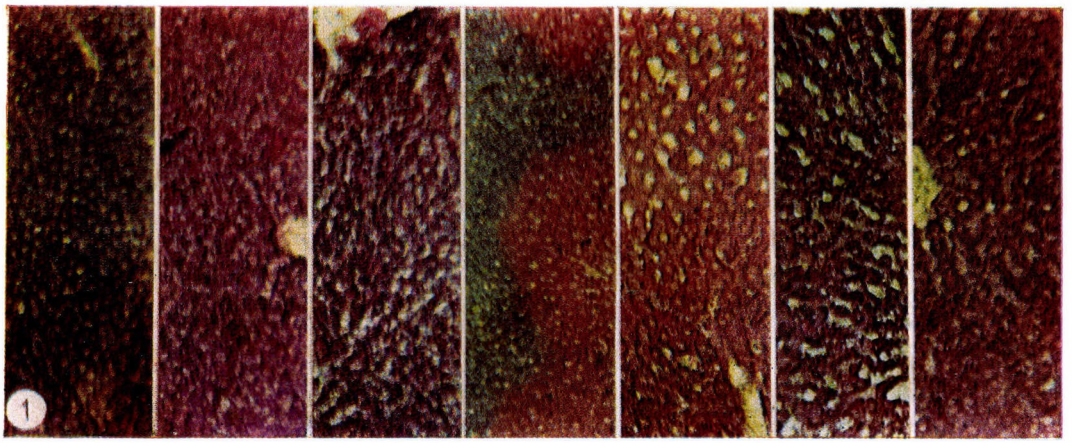

Fig. 1. Rat liver. Determination of β-glucuronidase by the method of SELIGMAN et al. *a* = control; *b* = enzymatic activity 2 hrs; *c* = 6 hrs; *d* = 16 hrs; *e* = 24 hrs; *f* = 48 hrs; *g* = 72 hrs. after the burn

Results

Results of the histochemical examinations are shown in Fig. 1. Fig. 1a presents the section of a control liver with a medium enzymatic activity. Figs 1b and 1c show strong activity 2 and 6 hrs after the burn. The pale blue and pink colour in Figs 1d and 1e, representing conditions 16 and 24 hrs after the

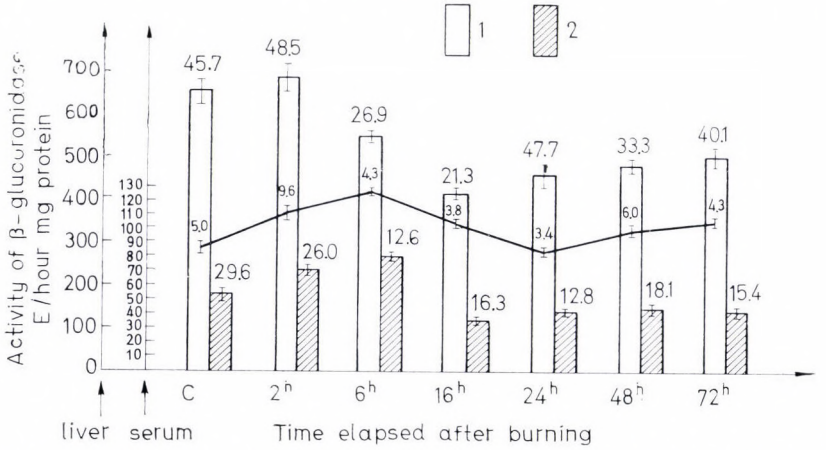

Fig. 2. Columnar diagrams indicate β-glucuronidase activities in the liver (total activity, free activity); the linear diagram shows changes in the activity of the same enzyme in the serum

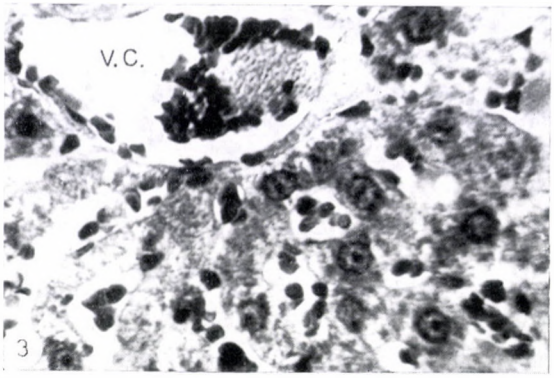

Fig. 3. Hydropic degeneration in rat liver. Central vein. Haematox.-eosin, ×400

burn, points to a decreased activity. It is increasing again at 48 and 72 hrs as shown in Figs 1f and 1g.

The activity of β-glucuronidase in liver and serum is shown in Fig. 2. Immediately after the burn in the liver there was a moderate rise of the activity; this elevation was followed by a decrease until the 16th hour, whereafter a renewed mild increase lasted until the end of the experiment (72 hrs). Activity of the free enzyme rose to a peak at 6 hrs when it decreased and remained constant until the 72nd hour. Though somewhat prolonged in time, enzymatic activity in the serum was similar to that of the free enzyme in the liver.

The haematocrit showed a rising tendency until 6 hrs whereafter the observed values began to fall gradually and reached the initial level after 24 hrs.

Discussion

DUTTON et al. [12] have shown that 55% of β-glucuronidase is contained in the lysosomes, 25% in the microsome and 10% in the nucleus. According to the present findings, activity in the liver cells begins to increase 2 hrs after the burn, a phenomenon that can be seen histochemically and followed quantitatively biochemically. In agreement with the data in literature, we have reached the conclusion that the observed increase was due to the lysosomal membranes having become permeable to the dye [5, 7, 16, 19], further by an actual increase in the amount of the enzyme [29]. The latter phenomenon is brought about by the cellular mechanism which transforms the prelysosomes into hydrolase containing lysosomes [10, 18, 29, 30, 31].

Up to 16 hrs after the burn there is a moderate outflow of β-glucuronidase from the liver cells, a phenomenon indicated by a reduction of the total enzymatic activity. The subsequent increase until the 72nd hour is indicative of re-

generation [9]. The trend of changes in free enzymatic activity was the same in the serum as in the liver which justifies the conclusion that, under certain conditions, a moderate amount of hydrolase may pass from intact cells into the systemic circulation.

The haemoconcentration indicated a state of shock lasting for 24 hrs; it was reversible in the majority of our cases [1, 23, 28]. It seems to follow from our observations that in state of shock induced by burn, blood flow is decelerated and tissue hypoxia develops [6, 13]. Thus, the permeability of cell membranes is increased; this would explain the changes in β-glucuronidase activity observed in our 72-hour experiments. The hydropic degeneration, found in the liver of burnt animals, is a further sign of hypoxia [8, 11]. Therefore, we do not regard the changes in β-glucuronidase activity as characteristic of hepatic damage caused by burns; the observed changes are only sequelae of the state of shock. That this is so seems to be confirmed by the fact that, for instance, shock elicited by poisoning [26] or other factors [17] also induces changes in β-glucuronidase activity.

REFERENCES

1. Arturson, G. (1961): Pathophysiological Aspects of the Burn Syndrome. Acta chir. scand. Suppl. 274, 109. — 2. Arturson, G., Wallenius, G. (1963): The Hepatocellular Origin of Circulating Enzymes. Acta. chir. scand. **126,** 34. — 3. Baccino, F. M., Rita, G. A., Dianzani, M. V. (1965): Further Experiments on the Action of CCl_4 Lysosomes in vitro. Enzymologia **29.** — 4. Baccino, F. M. (1969): Lysosomal Involvement in Liver Cell Vacuolation by Hypoxia. Brit. J. exp. Path. **150,** 150. — 5. Beaufay, H., De Duve, C. (1959): Enzymic Release of Bound Hydrolase. Biochem. J. **73,** 604. — 6. Berdjis, C. C., Vick, J. A. (1968): Endotoxin and Traumatic Shock. J. Amer. med. Ass. **204,** 191. — 7. Bitensky, L., Gahan, P. B. (1962): Reversible Activation of the Normal Cells. J. Biochem. **84,** 13P. — 8. Blair, O. M., Stenger, R. J., Hopkins, R. W., Simeone, F. A. (1968): Hepatocellular Ultrastructure in Dogs with Hypovolemic Shock. Lab. Invest. **18,** 172. — 9. Cambell, J. G., Lewy, G. A. (1950): Cytochemical Localization of Beta-glucuronidase. Nature (Lond). **166,** 783. — 10. De Duve, C., Wattiaux, R. (1966): Functions of Lysosomes. Ann. Rev. Physiol. **28,** 435. — 11. Dobson, E. L., Warner, G. F.: Cit. in M. Allgöver, J. Siegrist: Verbrennungen. Springer, Berlin—Göttingen—Heidelberg, 1957. — 12. Dutton, G. J., Pressman, B. C., Gianetto, R., Wattiaux, R., Appelman, F. (1955): Tissue Fractionation Studies. Biochem. J. **60,** 604. — 13. Evans, E. I. (1952): The Early Management of the Severely Burned Patient. Surg. Gynec. Obst. **94,** 273. — 14. Fazekas, I. Gy., Basch, A. (1969): Kísérletes égés okozta ultrastructuralis elváltozások patkánymájban. Morf. és Igazs. Orv. Szle. **9,** 294. — 15. Fishman, W. H., Springer, B., Brunetti, R. (1948): Application of an Improved Glucuronidase Assay Method to the Study of Human Blood β-Glucuronidase. J. biol. Chem. **173,** 449. — 16. Gahan, P. B. (1965): Reversible Activation of Lysosomes in Rat Liver. J. Histochem. Cytochem. **13,** 334. — 17. Janoff, A., Weissmann, G., Zweifach, B. W., Thomas, L. (1962): Pathogenesis of Experimental Shock. J. exp. Med. **116,** 451. — 18. Lapis, K. (1968): A lysosomák szerepe és jelentősége a pathológiában. Orv. Hetil. **109,** 785. — 19. Nelson, D. (1966): Hepatic Lysosome and Serum Enzyme Alteration in Rats Exposed to High Altitude. Amer. J. Phys. **211,** 651. — 20. Nilius, R. (1967): Die Serum β-Glucuronidase bei Lebererkrankungen. Med. Klin. **62,** 1082. — 21. Norden, G., Sternberg, T. (1962): Studies of the Liver Function in Experimental Burns. Acta Chir. Scand. **123,** 171. — 22. Periente, R. (1966): Les lysosomes. Sém. Hôp. Paris **12,** 1072. — 23. Peters, R. A. (1945): The Biochemical Lesions in Thermal Burn. Brit. med. Bull. **3,** 81. — 24. Pineda, E. P., Goldberg, J. A., Banks, B. M., Rutenburg, A. M. (1967): Serum β-Glucuronidase in Patients with Liver Disease. Clin. Res. **7,** 35. — 25. Pineda, E. P., Goldberg, J. A., Banks, B. M., Rutenburg, A. M. (1959): The Significance of Serum β-Glucuronidase Activity in Patients with Liver Disease. Gastroenterology **36,** 202. — 26. Rath, F. W.,

NILUS, R. (1967): Das histochemische und biochemische Verhalten der β-Glucuronidase bei Leberparenchymschädigung der Ratte durch eine einmalige Tetrachlorkohlenstoffgabe. Exp. Path. **1,** 195. — 27. SELIGMAN, A. M., TSON, K. C., RUTENBURG, S. H., COHEN, R. B. (1954): Histochemical Demonstration of β-D-Glucuronidase with a Synthetic Substrate. J. Histochem. Cytochem. **2**, 209. — 28. SCHUMER, W., SPERLING, R. (1968): Shock and its Effect on the Cell. J. Amer. med. Ass. **205,** 75. — 29. SHIBKO, S., PANGBORN, J., TAPPEL, A. L. (1965): Studies on the Release of Lysosomal Enzymes from Kidney Lysosomes. J. Cell Biol. **25,** 479. — 30. TÖRŐ, I. JR.: Az orvostudomány aktuális problémái. Medicina, Budapest 1962. — 31. WOLFF, K., SCHREINER, E. (1970): Epidermale Lysosomen. Arch. Derm. **101,** 276.

HISTOCHEMISCHE UND BIOCHEMISCHE UNTERSUCHUNG DER BETA-GLYKURONIDASE-AKTIVITÄT VON LEBER UND BLUTSERUM DER SCHWEREN BRENNVERLETZUNG AUSGESETZTEN RATTEN

A. BASCH, I. GY. FAZEKAS, B. RENGEI und L. MINDSZENTI

Verfasser haben die beta-Glykuronidase Enzymaktivität von Leber und Blutserum einer 25%igen Brennverletzung dritten Grades ausgesetzten Ratten in verschiedenen Zeitpunkten bis 72 Stunden mit histochemischen und biochemischen Methoden untersucht. Es konnte behauptet werden, daß in dem Verbrennungssyndrom ein cca. 24 Stunden lang dauernder Schockzustand die Ursache der Änderungen in der Enzymaktivität sei und darum sei diese für die Verbrennung folgende Leberschädigung nicht charakteristisch.

ГИСТОХИМИЧЕСКОЕ И БИОХИМИЧЕСКОЕ ИССЛЕДОВАНИЕ АКТИВНОСТИ β-ГЛЮКУРОНИДАЗЫ В ПЕЧЕНИ И СЫВОРОТКЕ КРОВИ КРЫС ПОСЛЕ ТЯЖЕЛОГО ОЖОГА

А. БАШ, И. ФАЗЕКАШ, Б. РЕНГЕИ и Л. МИНДСЕНТИ

В течение 72 часов авторы в различные сроки определяли гистологическими и биохимическими методами активность β-глюкуронидазы в печени и в сыворотке крови крыс после 25%-ого ожога третьей степени. Было установлено, что при синдроме ожога изменение активности глюкуронидазы вызывается приблизительно 24-часовым состоянием шока, и что это не является характерным для поражения печени от ожога.

Dr. András BASCH
Prof. Dr. I. Gyula FAZEKAS
Dr. Béla RENGEI
Dr. László MINDSZENTI

Szeged, Igazságügyi Orvostani Intézet, Hungary

Acta Morphologica Acad. Sci. Hung. 19 (3), pp. 247—257, 1971

Pathologisches Institut (Direktor: Prof. Dr. F. Bolck), Friedrich-Schiller Universität, Jena

STRUKTUR EMBRYONALER ZELLPOPULATIONEN IN DER LEBER UND PRIMÄRER MONOLAYER-KULTUR

G. Neupert

(Eingegangen am 5. Januar, 1971)

Die funktionell und strukturell verknüpften Endothel- und Epithelzellen der embryonalen tubulären Hühnchenleber bilden nach proteolytischer Dissoziation des Gewebes in primärer Monolayer-Kultur zwei voneinander getrennt liegende Populationen mit eigener Entwicklungstendenz. Das Wachstum der beiden Populationen in einer sich formierenden Monolayer ist neben physiologischen und nutritiven Faktoren des Kulturmilieus in erster Linie von der ausgesäten Zelldichte abhängig. Der histochemische Nachweis von Glykogen, Phosphorylase, UDPGTase, G-6-Pase und die Empfindlichkeit gegenüber Sauerstoffmangel in der Primärkultur sind Kriterien für die Bestimmung der Identität einer epithelial gewachsenen Parenchymzellpopulation und einer fibroblasten- und epithelähnlichen Population aus mesenchymalen Zellen.

Die Beziehung zwischen den Zellen eines Gewebes und den Populationen einer daraus hervorgegangenen Monolayer sind neben der ontogenetischen Differenzierung, dem Nährstoffangebot und der physiologischen Mikroumgebung, in der die Zelle lokalisiert ist, wesentliche Faktoren bei der Beurteilung der Struktur und Funktion von Zellen in vitro. Im allgemeinen finden die unspezialisierten Begleitzellen in vitro günstigere Bedingungen bei der Adaptation und zur Proliferation als die organtypischen Epithelzellen, so daß eine Verschiebung der ursprünglich vorliegenden Zellpopulationen zugunsten der Begleitzellen eintreten kann. Voraussetzung zur Bestimmung der Populationsstruktur und -dynamik ist die Abgrenzung und Identifikation der einzelnen Zelltypen vor und nach der Gewebsdisaggregation bis zur Formation einer primär geschlossenen Zell-Monolayer. Die von Katsutaet al. [8], Sandström [21] und Zuckerman et al. [34] an embryonalen Leberkulturen unternommenen Versuche, die Zelltypen allein nach ihrer Morphologie zu trennen, dürften auf Grund der Formvariabilität isolierter Zellen für eine Populationsstudie kaum ausreichen.

Wir versuchten, die Zellpopulationen in der Leber und der daraus hervorgegangenen Monolayer-Kultur nach vorausgegangener Identifikation der Zelltypen aus summarischen Angaben über differente Enzymmuster und der Empfindlichkeit gegenüber Sauerstoff strukturell zu erfassen.

Material und Methoden

Leberstückchen von Hühnchenembryonen 11—13 Tage inkubierter Eier wurden mit einer 0,15%igen Trypsinlösung (Difco 1 : 250) in Ca^{++}- und Mg^{++}-freier phosphatgepufferter Salzlösung in Einzelzellen disaggregiert. Die Zellen wuchsen als Monolayer auf Deckgläschen (24 × 26 mm) in Petrischalen und Mikrokammern mit 0,4% Lactalbuminhydrolysat (Difco) in Hanks-Lösung sowie einem Zusatz von 0,01% Glutamin und 10% Kälberserum. Die H-Ionenkonzentration des Mediums wurde mit $NaHCO_3$ auf pH 7,4—7,6 eingestellt und durch Begasung mit einem Luft/CO_2-Gemisch während der Kulturperiode konstant gehalten. In Petrischalen von 70 mm Durchmesser wurden in 10 ml Medium bei verschiedenen Versuchsserien 8×10^5 bis $1{,}2 \times 10^7$ Zellen suspendiert.

1. Phosphorylase nach TAKEUCHI und KURIAKI [29] modifizert nach KORSGAARD und WULFF [9].

2. Uridindiphosphatglucose: Glykogen-4-Glucosyltransferase (UDPGGTase) nach TAKEUCHI und GLENNER [30] modifizert durch SASSE [25].

Kontrolluntersuchungen erfolgten für jede Methode durch Inkubation ohne Substrat. Das durch die Gram-Reaktion sichtbar gemachte Glykogen wurde mit α- und β-Amylase nach der Methode von TAKEUCHI [31] verdaut.

3. Glucose-6-Phosphatase (G-6-Pase) nach WACHSTEIN und MEISEL [32].

Die Zellen wurden mit einer 0,02%igen EDTA-Lösung vom Glas abgelöst und in einer Fuchs—Rosenthal-Kammer gezählt.

Ergebnisse

Die embryonale Hühnchenleber unterscheidet sich durch ihren tubulären Bau deutlich von derjenigen erwachsener Hühner [7]. Sie besitzt das gleiche Bauprinzip wie die Leber der niederen Wirbeltiere, z. B. Myxiden [15]. In der Gesamtstruktur stellt die embryonale Hühnchenleber ein Netzwerk von anastomosierenden Leberzelltubuli mit dazwischenliegenden lagunaartig erweiterten Sinusoiden dar. 6—8 Parenchymzellen bilden im Querschnitt die dicht ineinandergesteckten kommunizierenden Epithelschläuche, die mantelförmig von Endothelzellen umgeben werden (Abb. 1b, c) [19]. Im Zentrum des Tubulus verläuft das Lumen des Gallenkanälchens [3, 19]. Das galleabführende System ist bei 11—13 Tage alten Hühnchen noch undifferenziert und wenig ausgebildet, so daß nur vereinzelt Gallengänge mit dem typischen prismatischen Epithel angeschnitten werden. Die verhältnismäßig kleine Population von Gallengangepithelzellen wurde bei der weiteren Betrachtung nicht berücksichtigt, da diese wenigen Zellen nach der Gewebsdisaggregation keine Chance haben, in Monolayer zu wachsen. Die zu- und abführenden Blutgefäße werden von einer aus 2—6 Zellagen bestehenden Bindegewebsscheide umgeben (Abb. 1e).

Bei regelmäßiger Ausbildung der Tubuli sind im Querschnitt 6—8 Parenchymzellen 2 Endothelen zugeordnet. Die kubischen Parenchymzellen sind durch eine basal absorbierende und apikal sezernierende Fläche im Tubulus polar ausgerichtet. Durch das funktionelle Zusammenwirken von Leberepithelzellen, die eine Population bilden, und der Zellpopulation aus dem mesenchymalen Apparat wird der gewebliche Aufbau der Leber bestimmt. Da nach anerkannter Vorstellung die Endothelzellen und Fibrozyten im frühen

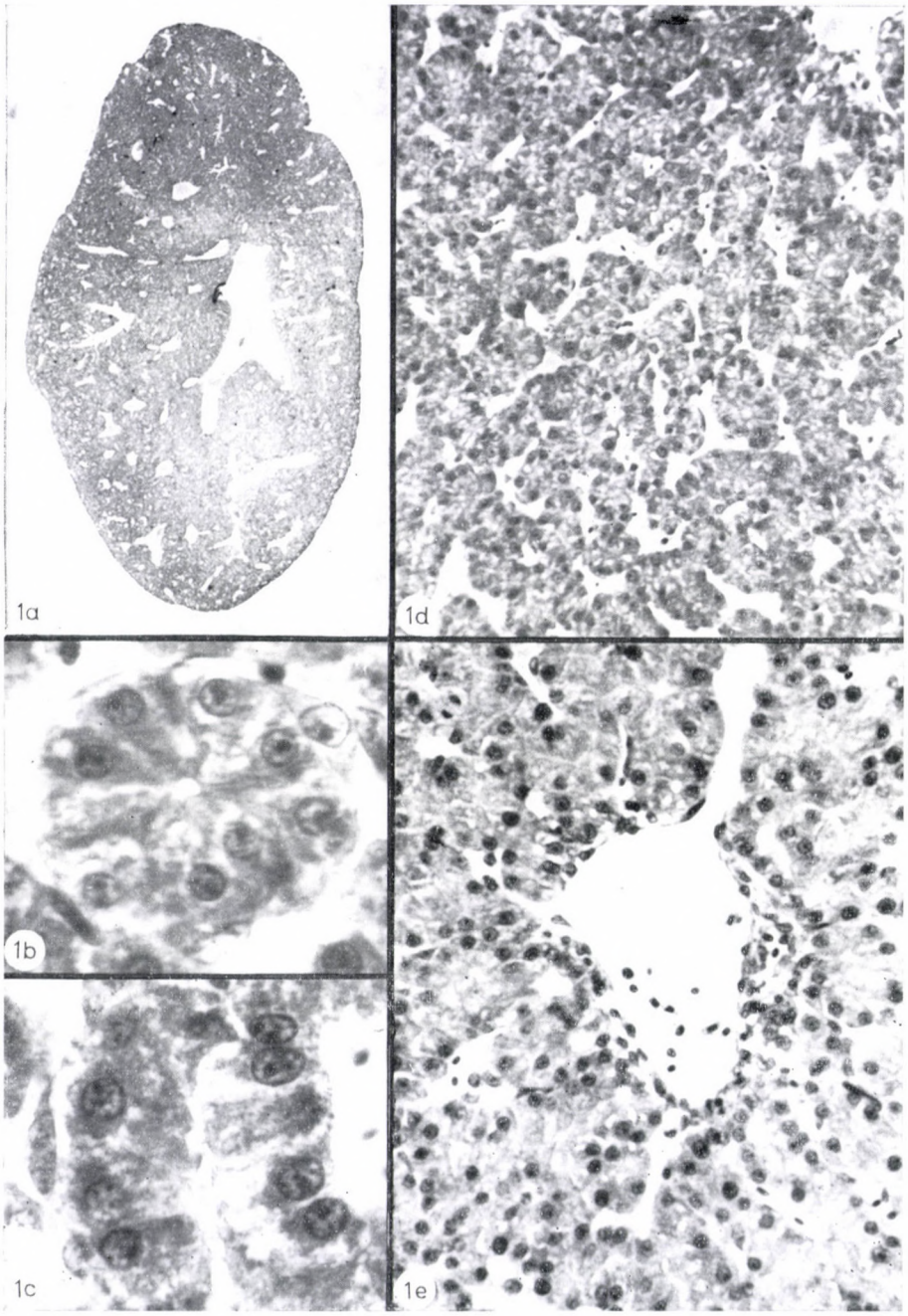

Abb. 1. Leber eines 13 Tage alten Hühnchenembryos (Carnoy, Paraffin, HE-Färbung). a) Querschnitt durch einen Leberlappen (Übersicht ×13); b) Lebertubulus quer, ×650; c) Lebertubulus längs, ×650; d) Leberparenchym, ×120; e) Blutgefäß der Leber, ×210

embryonalen Stadium gemeinsame Merkmale besitzen und morphologisch nicht trennbar sind, haben wir bei 11—13 Tage alten Hühnchenembryonen die beiden Zelltypen zu einer Population von Endothelzellen zusammengefaßt. Durch Auszählen an Stufenschnitten in verschiedenen Regionen versuchten wir die prozentuale Verteilung der beiden bestimmenden Zellpopulationen zu ermitteln. 80 $\pm$ 3% entfallen auf Parenchymzellen und 20 $\pm$ 3% wurden als Endothelzellen ermittelt. Die Identifikation der Zelltypen im Gewebe erfolgte hauptsächlich in HE und nach v. Gieson gefärbten Paraffinschnitten. Parallel dazu wurden die Parenchymzellen von den Sinusoid- und Bindegewebszellen durch den Nachweis von G-6-Pase, Phosphorylase, UDPGGTase und der Fähigkeit zur Glykogenspeicherung getrennt.

Unmittelbar nach Dissoziation des Lebergewebes setzen sich die einzelnen isolierten Zellen auf der Glasunterlage der Kulturgefäße fest und beginnen sich auszubreiten. Bei dichter Zellaussaat von 3×10^5 Zellen/cm^2 (oder $1{,}2 \times 10^7$ Zellen/Petrischale) ist die Voraussetzung geschaffen, daß sich ein Teil der isolierten Zellen bei der Sedimentation und Ausbreitung zu mehr oder weniger großen Arealen agglutinieren. Der prozentual kleine Anteil von endothel- und fibroblastähnlichen Zellen breitet sich am Rand oder in den Lücken der größeren Areale aus. Die Mitoseaktivität der Parenchymzellen von 2—4 Tage alten Kulturen entspricht dem in vivo-Verhältnis 9—13 Tage alter Hühnchenembryonen [10]. Die Verlaufsform des mitotischen Wachstums kann trotz konstanter Bedingungen um 0,2% variieren. Bei inhomogener Verteilung der Zellen während der Sedimentation stellen die dichter liegenden Areale Mitosezentren dar.

Die durch Zellteilung sich vergrößernden Kolonien von Parenchymzellen fusionieren durch mehrzellige Zellstränge miteinander, so daß nach 6—8 Tagen eine geschlossene Monolayer mit kleinen Lücken zusammengeschlossener fibroblastähnlicher Zellen entsteht (Abb. 2b, d). Vom 5. bis 8. Tag sinkt die Mitoserate bei den Parenchymzellen, bis die Mitoseaktivität zum Stillstand kommt. Die mitotische Wachstumsaktivität der mesodermalen Zellen steigt um das 3fache des Ausgangswertes (Abb. 3). Die Lücken und Randpartien der Parenchymzell-Monolayer werden criss and cross mit fibroblastähnlichen Zellen überwachsen. Nach der beschriebenen Methode und dichter Zellaussaat entspricht das Zahlenverhältnis der beiden Populationen bis zum 8. Tag dem in-vivo-Verhältnis.

Anders verhält es sich, wenn weniger als 5×10^4 Zellen/cm^2 (oder 2×10^6 Zellen/Petrischale) ausgesät werden. Die einzeln liegenden Zellen wandern, bevor sie ihren festen Standort in der sich formierenden Monolayer einnehmen, zu Nachbarzellen der gleichen Population, wo sie kleine Zellinseln von 20 bis maximal 100 Zellen bilden. Selbst in den ersten Kulturtagen wurden in der Parenchymzellpopulation sehr selten Mitosen beobachtet. Dagegen vermehren sich die endothel- und fibroblastenähnlichen Zellen rasch und bilden nach

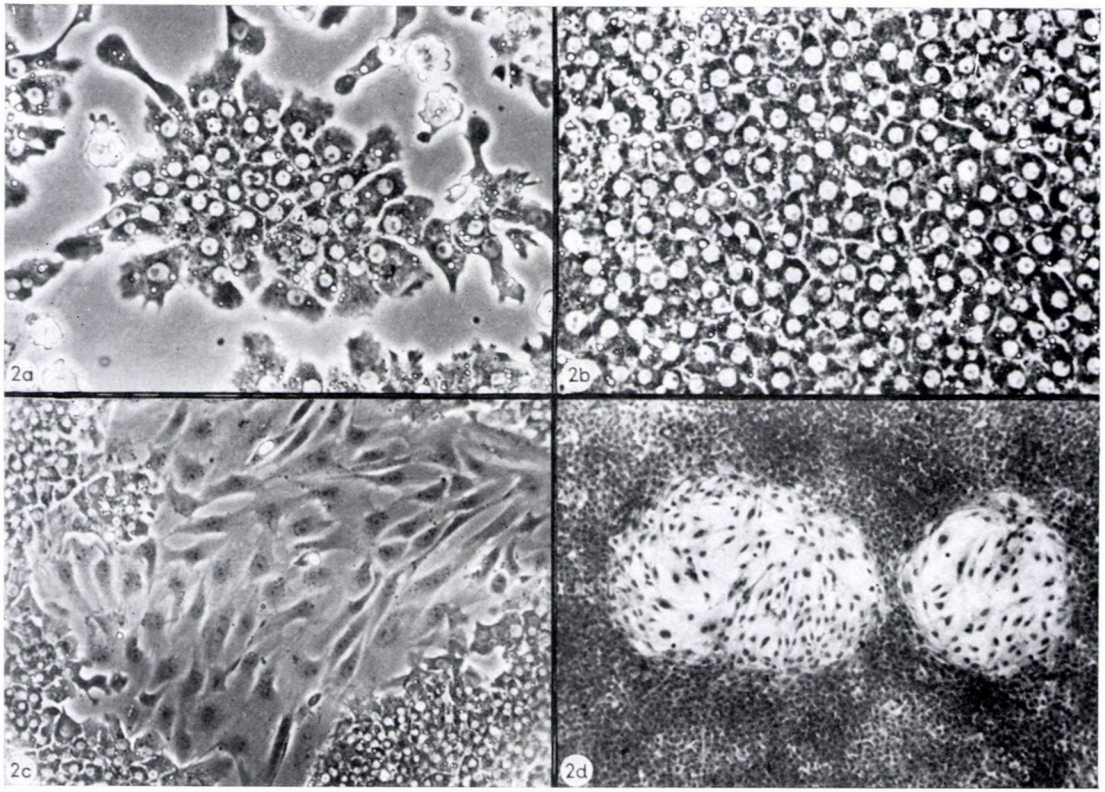

Abb. 2. Hühnchenleberzellen in Monolayer-Kultur (a, b und c — Phasenkontrast, d — May–Grünwald–Giemsa). a) Kolonie von Parenchymzellen, 24 Std. in Kultur, ×300. b) Geschlossene Monolayer von Parenchymzellen nach 6 Tagen in vitro (dichte Zellaussaat), ×320. c) Epithelähnliche Zellen zwischen Parenchymzellen bei wenig dichter Zellaussaat nach 4 Tagen Kultur, ×140. d) Eingeschlossene epithel- und fibroblastenähnliche Zellen in einer Parenchymzell-Monolayer nach 8 Tagen Kultur, ×90

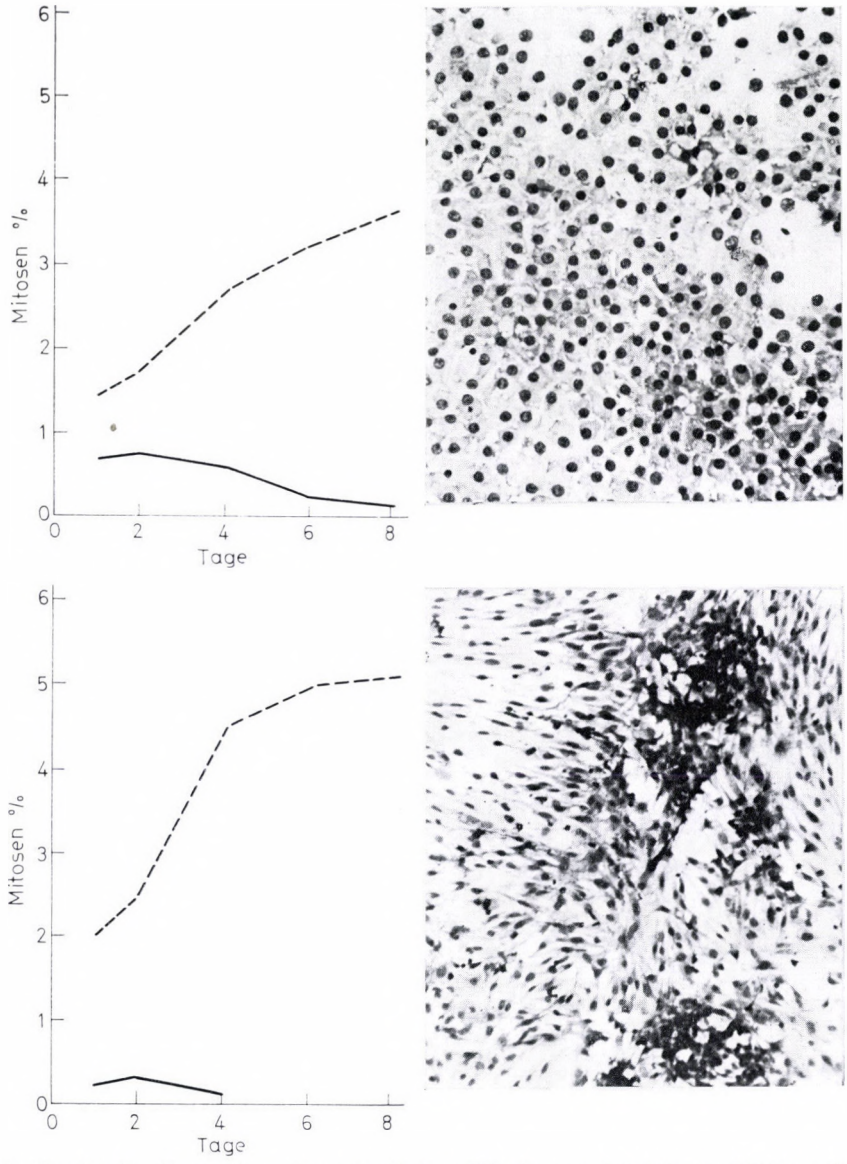

Abb. 3. Graphische Darstellung der mitotischen Wachstumsaktivität der Epithelzell-Population (ausgezogene Linie) und der Population aus fibroblastenähnlichen Zellen (unterbrochene Linie) einer Leberzell—Monolayer-Kultur nach unterschiedlicher Zellaussaat; oben: 3×10^5 Zellen/cm^2; unten: 5×10^4 Zellen/cm^2. Die dazugehörigen Mikrophotos zeigen nach 8 Tagen Kultur die typische Monolayer-Organisation. (Methylalkohol, May—Grünwald—Giemsa, oben $\times 250$, unten $\times 150$)

wenigen Tagen ein zusammenhängendes Retikulum, das die Parenchymzellinseln einschließt (Abb. 3 unten). Durch den Einfluß der zahlreichen Milieufaktoren können die in vivo bereits determinierten Fibrozyten und Endothelzellen

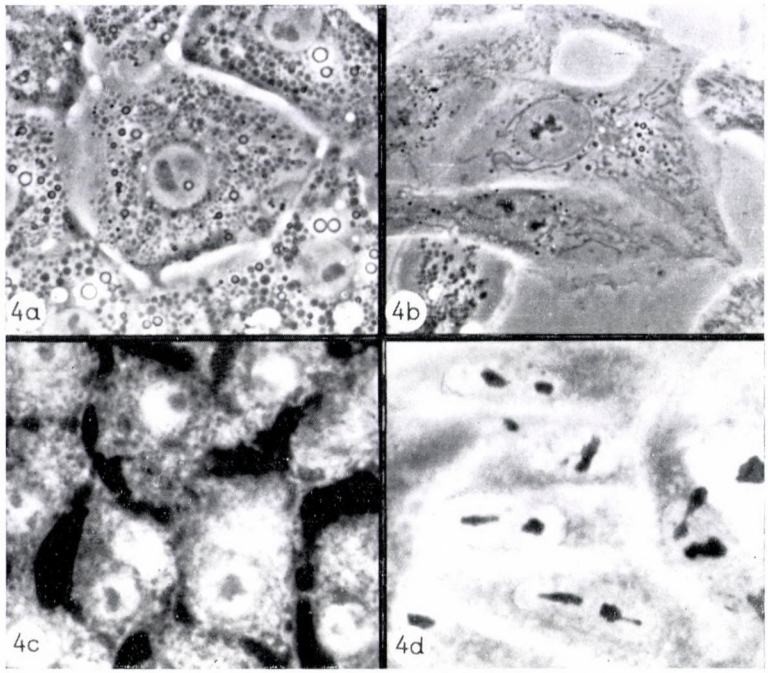

Abb. 4. Zellen aus einer Leberzellmonolayer (*a* und *b* Phasenkontrast, *c* und *d* PAS—Methylenblau). *a)* Parenchymzelle, ×960; *b)* Epithelähnliche Zelle aus der Population der Endothelzellen, ×960; *c)* Parenchymzellen 6 Tage in Kultur, ×900; *d)* Fibroblastenähnliche Zellen 6 Tage in Kultur, ×900

im Rahmen ihrer Entwicklungspotenzen wie Fibroblasten, fibroblastenähnliche oder epithelähnliche Zellen nach der Terminologie von FEDOROFF [4] wachsen.

Die flachen, polygonal gewachsenen Parenchymzellen sind dadurch ausgezeichnet, daß der Zellinhalt neben dem runden Kern von einer großen Anzahl runder bis ovaler Mitochondrien völlig ausgefüllt ist (Abb. 4a). An der Zellperipherie liegen grobgranulierte bis schollige diastasebeständige PAS-positive Reaktionsprodukte, die als Glykogen identifiziert wurden (Abb. 4c), und die in ihrer Form und Lage mit den Jodniederschlägen nach histochemischer Phosphorylase- und UDPGGTase-Reaktion identisch sind [16]. Bei 90% der Parenchymzellen ist die G-6-Pase mit unterschiedlicher Aktivität in Form von kleinen braunschwarzen Bleisulfidgranula im gesamten Zytoplasma sichtbar. In der Population der Endothelzellen wurden alle Fibroblasten — bis epithelähnlichen, sehr dünn auf der Unterlage ausgebreiteten Zellen — zusammengefaßt. Die Zellen besitzen einen oval-länglichen Kern mit 2 bis 3 Nukleoli umgeben mit unterschiedlich vielen filiformen Mitochondrien (Abb. 4b). Das Zytoplasma reagiert nach PAS- und Gomori-Reaktion (G-6-Pase) negativ. Die äußere Gestalt der fibroblasten- und epithelähnlichen Zellen ist sehr

variabel und wird unter anderem vom Zellkontakt zu Nachbarzellen und durch die Kultivierungszeit bestimmt. Ein weiteres Trennungsmerkmal ist kurz nach der Gewebsdisaggregation gegeben. Alle Parenchymzellen beantworten die hypoxische Milieubedingung mit starker Vakuolenbildung. Die fibroblasten- und epithelähnlichen Zellen bleiben vakuolenfrei.

Besprechung

Aus der frühen embryonalen Korrelation von entodermalem Epithel des Urdarmdaches und den indifferenten Bindegewebszellen des Mesenchyms entwickelt sich bei allen Wirbeltieren die funktionelle Verknüpfung von Sinus-Endothelzelle und Parenchymzelle, die ihren gestaltlichen Ausdruck am deutlichsten in der von Rössle [20] bezeichneten Gewebseinheit — dem Hepaton — findet. Die strukturelle Besonderheit der embryonalen Hühnchenleber liegt in der tubulären Anordnung der Epithelzellen, die mantelförmig von Endothelzellen umgeben werden. Abgesehen von besonderen Stoffwechselfunktionen (z. B. Lipoid- und Gallepigmentstoffwechsel) stellen die Sinus-Endothelzellen auf Grund ihrer spezifischen Permeabilität und Phagozytoseaktivität ein geeignetes Filter des kapillären Plexus dar, der auf den erhöhten Stoffaustausch der Parenchymzelle abgestimmt ist. Nach Isolierung und Dissoziation des Lebergewebes, wobei die Architektur der Gewebseinheit aufgelöst wird, beginnt in vitro die Adaptation an eine völlig neue Stoffwechselsituation. Die funktionsbedingte polare Ausrichtung der Parenchymzelle wird bedeutungslos und verschwindet bei der räumlichen Orientierung der Eizellen. Die isolierten, in Monolayer gewachsenen Zellen, die im gewissen Sinne als selbständige Mikroorganismen angesehen werden können [6], regulieren ihre Eigenbewegung und Wachstumsfähigkeit durch cell–cell contact [1] und ihre Adhäsion zur Unterlage [2]. Die Zell–Zell Wechselwirkung und das Zell–Medium-Verhältnis sind bestimmend für die Differenzierung der Zellen in vitro. Während Moscona [12, 13, 14] aus Suspensionen embryonaler tierischer Zellen (darunter Hühnchenleber) in rotation-mediated-aggregation-Kultur unter geeigneten Bedingungen organtypische Aggregate mit histotypischer Struktur züchten konnte, ist es in Leberzell-Monolayer-Kulturen noch nie zu einer Selfaggregation gekommen. Allgemein formieren sich in Monolayer-Kulturen Epithel- und Endothelzellen jeweils getrennt. Dafür sind wahrscheinlich quantitative Differenzen in der Adhäsion der verschiedenen Zelltypen verantwortlich [27, 28]. Eine morphogenetische Bewegung zu einem organisierten Zellverband, der dem typischen Charakter des Gewebes entsprechen würde, kommt nicht zustande.

Ob die fibroblastenähnlichen Zellen aus dem indifferenten endothelialen Syncytium in der Monolayer-Kultur einen Einfluß auf die spezifische Dif-

ferenzierung der Parenchymzellen haben, analog der von LE DOUARIN [11] gefundenen experimental gezeigten mesenchymalen Induktion während der frühen Embryogenese, konnte bisher in Kultur nicht geklärt werden.

Obwohl in primärer Monolayer-Kultur die Parenchymzellpopulation und die Population aus Zellen mesenchymaler Herkunft getrennt lagen, blieb das Zahlenverhältnis der Populationen bei dichter Zellaussaat gegenüber dem Gewebe bis zum 8. Tag annähernd gleich. Nach fortgesetzter Kultivierung ist es aufgrund eigener Beobachtungen und Darstellungen von SATO et al. [26] und ZUCKERMAN et al. [34] nicht zu verhindern, daß die fibroblastenähnlichen Zellen mesenchymalen Ursprungs schneller proliferieren und nach Subkultur über die organtypischen Zellen dominieren. Die Parenchymzellen während der Disaggregation des Gewebes von den retikuloendothelialen Zellen zu trennen und durch gezielt ausgewählte nutritive Zusätze zum Medium in der Adaptation zu begünstigen, wie es GARVEY [5] dargestellt hat, bringt nur Vorteile für die isolierten Kupfferschen Zellen [18] und nicht für die Parenchymzellen. Eine Reinkultur von primär angelegten Parenchymzellen herzustellen, war bisher trotz zahlreicher Versuche nicht möglich [8].

Während sich die entodermalen Epithelzellen in der Embryogenese aufgrund ihres Genoms nur zu voll funktionsfähigen Epithelzellen ausbilden, können sich die undifferenzierten Retikulumzellen zu Histiozyten, Fibrozyten, Sinusoid- und Gefäßendothelien sowie hämopoetischen Zellen umwandeln. Die Zellen des embryonalen Bindegewebes zeigen im Organ und in der Kultur eine große Variabilität [33].

SANDSTRÖM [21] trennte in embryonalen Hühnchenleberzell-Kulturen die Parenchymzellen von drei weiteren epithel- und fibroblastenähnlichen Zelltypen ab und demonstrierte kinematographisch, daß sich letztere ineinander, die Parenchymzellen jedoch nie in epithel- oder fibroblastenähnliche Zellen umwandeln können. In Kultur kann man mit Sicherheit nur die Parenchymzellen von einer Zellpopulation mesenchymalen Ursprungs trennen. Da in den kultivierten Leberparenchymzellen die wichtigsten Stoffwechselenzyme und -produkte bis 6 Tage nachweisbar sind [16, 17, 22, 23, 24], erscheint es berechtigt, mit Hilfe histochemischer Methoden die Parenchymzell-Population von der anderen Zellpopulation zu trennen.

LITERATUR

1. ABERCROMBIE, M., AMBROSE, E. J.: (1962) The Surface Properties of Cancer Cells. Cancer Res. **22**, 525—548. — 2. ABERCROMBIE, M.: (1965) The Locomotor Behaviour of Cells. In: Cells and Tissue in Culture, ed. E. N. Willmer, Academic Press, New York, Vol. I. pp. 177—202. — 3. ELIAS, H.: (1955) Origin and Early Development of the Liver in Various Vertebrates. Acta hepat. (Hamburg) **3**, 40—56. — 5. GARVEY, J. S.: (1961) Separation and in vitro Culture of Cells from Liver Tissue. Nature (Lond.) **191**, 972—974. — 4. FEDOROFF, S.: (1967) Proposed Usage of Animal Culture Terms. Exp. Cell Res. **46**, 642—648. — 6. GREEN, H., TODARO, G. J.: (1967) The Mammalian Cell as Differentiated Microorganism. Ann. Rev. Microbiol. **21**, 573—600. — 7. HICKEY, J. J., ELIAS, H.: (1954) The Structure of the Liver of Birds. 458—462. —

8. KATSUTA, H., TAKAOKA, T., SAITO, S.: (1957) Cultivation of Liver Cells from Chick Embryos in the Simplified Replicate Tissue Culture. Jap. J. exp. Med. **27,** 367—380. — 9. KORSGAARD, B., WULFF, H. R.: (1967) An Improved Method for the Histochemical Demonstration of Phosphorylase in Tissue Sections. Acta path. microbiol. scand. **70,** 236—240. — 10. KUSE, R.: (1962) Vergleichende Untersuchungen der mitotischen Wachstumsaktivität der Thorax- und Oberbauchorgane beim embryonalen und fetalen Hühnchen. Z. Zellforsch. **56,** 728—747. — 11. LE DOUARIN, N.: (1964) Étude expérimentale de l'organigenèse du tube digestif et du foie chez l'embryon de poulet. Bull. Biol. France Belgique **98,** 544—676. — 12. MOSCONA, A.: (1957) The Development in vitro of Chimeric Aggregates of Dissociated Embryonic Chick and Mouse Cells. Proc. Nat. Acad. Sci. (Wash.) **43,** 184. — 13. MOSCONA, A.: (1961) Rotation-mediated Histogenetic Aggregation of Dissociated Cells. Exp. Cell Res. **22,** 455—475. — 14. MOSCONA, A.: Recombination of Dissociated Cells and the Development of Cell Aggregates. In: Cells and Tissue in Culture, ed. E. N. Willmer, Academic Press, New York. Vol. I. pp. 489—529. — 15. MUGNAINI, E., HARBOE, S. B.: (1967) The Liver of Myxine Glutinosa: A True Tubular Gland. Z. Zellforsch. **78,** 341—369. — 16. NEUPERT, G.: (1969) Vergleichende histochemische Untersuchungen am Glykogenzyklus embryonaler Leberzellen in vivo und in vitro. Z. mikr.-anat. Forsch. **80,** 419—432. — 17. NEUPERT, G.: (1970) Darstellung und Lokalisation einiger Dehydrogenasen in primären Leberzell-Monolayer-Kulturen. Acta histochem. (Jena) **38,** 149—159. — 18. PISANO, J. C., FILKINS, J. P., DILUZIO, N. R.: (1968) Phagocytic and Metabolic Activities of Isolated Rat Kupffer Cells. Proc. Soc. exp. Biol. (N.Y.) **128,** 917—922. — 19. ROMANOFF, A. L.: The Avian Embryo. Macmillan, New York, p. 1305, 1960. — 20. RÖSSLE, R.: Entzündungen der Leber. In: Handbuch der speziellen pathologischen Anatomie und Histologie. Hrsg. O. Henke-Lubarsch. Springer, Berlin, Bd. V, pp. 243—505. — 21. SANDSTRÖM, B.: (1965) Studies on Cells from Liver Tissue Cultivated in vitro. Exp. Cell Res. **37,** 552—568. — 22. SANDSTRÖM, B.: (1966a) Observations on the Bile Secretion in Cultivated Liver Tissue. Acta Soc. Med. upsalien. **71,** 14—20. — 23. SANDSTRÖM, B.: (1966b) Some Observations on the Protein Synthesis in Cultivated Chicken Embryonic Liver. Acta Soc. Med. upsalien. **71,** 35—40. — 24. SANDSTRÖM, B.: (1966c) Cytochemistry of Foetal Chicken Liver Cultivated in vitro. Acta Soc. Med. upsalien. **71,** 65—82. — 25. SASSE, D.: (1966) Untersuchungen zur Nachweismethodik der Uridindiphosphoglucose-glykogentransferase. Histochemie **7,** 39—49. — 26. SATO, G., ZAROFF, L., MILLS, S. E.: (1960) Tissue Culture Populations and Their Relation to the Tissue of Origin. Proc. Nat. Acad. Sci. (Wash.) **46,** 963—972. — 27. STEINBERG, M. S.: (1963) Tissue Reconstruction by Dissociated Cells. Science **141,** 401—408. — 28. STEINBERG, M. S.: (1964) The Problem of Adhesive Selectivity in Cellular Interactions. In: Cellular Membranes in Development, ed. M. Locke, 22nd Symp. Soc. Study Development and Growth. Academic Press, New York, pp. 321—66. — 29. TAKEUCHI, T., KURIAKI, H.: (1955) Histochemical Detection of Phosphorylase in Animal Tissue. J. Histochem. Cytochem. **3,** 153—160. — 30. TAKEUCHI T., GLENNER, G. G.: (1960) Histochemical Demonstration of a Pathway for Polysaccharide Synthesis from Uridinediphosphoglucose. J. Histochem. Cytochem. **8,** 227—230. — 31. TAKEUCHI, T.: (1962) Histochemistry of Intracellular Polysaccharide Synthesis. Ann. histochem. **7,** 61—80. — 32. WACHSTEIN, M., MEISEL, E.: (1957) Histochemistry of Hepatic Phosphatases of a Physiological pH with Special Reference to the Demonstration of Bile Canaliculi. Amer. J. clin. Path. **27,** 13—27. — 33. WILLMER, E. N.: (1965) Morphological Problems of Cell Type, Shape and Identification. In: Cells and Tissue in Culture, ed. E. N. Willmer, Academic Press, New York. Vol. I, pp. 143—176. — 34. ZUCKERMAN, A. J., REES, K. R., INMAN, D. R., ROBB, I. A.: (1968) The Effects of Aflatoxins on Human Embryo Liver Cells in Culture. Brit. J. exp. Path. **49,** 33—39.

STRUCTURE OF EMBRYONAL CELL POPULATIONS OF THE LIVER AND OF PRIMARY MONOLAYER-CULTURE

G. NEUPERT

The functionally and structurally connected endothelial and epithelial cells of the embryonal tubular chicken liver appear after proteolytic dissociation of the tissue in primary monolayer culture as two separate populations with own tendencies of development. The growth of both populations depends besides physiological and nutritional factors first of all on the density of disseminated cells. The histochemical demonstration of glycogen, phosphorylase, UDPGGTase, G-6-Pase and the sensitivity to oxygen deficiency in primary culture are criteria of the determination of the identity of an epithelially grown parenchyme cell population and of fibroblast-like and epithelium-like population of mesenchymal cells.

СТРУКТУРА ЭМБРИОНАЛЬНЫХ КЛЕТОЧНЫХ ПОПУЛЯЦИЙ В ПЕЧЕНИ И В ПЕРВИЧНОЙ МОНОЛАЙЕРОВСКОЙ КУЛЬТУРЕ

Г. НЕЙПЕРТ

Функционально и структурно связанные эндотелиальные и эпителиальные клетки эмбриональной тубулярной печени цыплят образовывают после протеолитической диссоциации ткани в первичной монолайеровской культуре две различно расположенные популяции с собственной тенденцией развития. Рост обеих популяций в формирующейся монолайеровской культуре зависит, наряду с физиологическими и нутритивными факторами среды культуры, в первую очередь от густоты рассеивания клеток. Гистохимическое выявление гликогена, фосфорилазы, УДПГТ-азы, Г-6-Ф-азы и чувствительность в отношении недостатка в кислороде в первичной культуре являются критериями для определения тождественности эпителиально росшей популяции паренхиматозных клеток и фибробласто- и эпителиальноподобных популяций из мезенхимальных клеток.

Dr. G. Neupert, Pathologisches Institut der Friedrich-Schiller Universität, Jena, DDR

Acta Morphologica Acad. Sci. Hung. 19 (3), pp. 259—268, 1971

Institute of Anatomy, Histology and Embryology (Director: St. Krompecher), University Medical School, Debrecen

EFFECT OF POSTNATAL THYMECTOMY ON ENCHONDRAL OSSIFICATION

B. Mándi, Cs. Hadházy, A. Mándi and T. Glant

(Received February 20, 1971)

Thymectomy was performed in albino rats 36 to 48 hours after birth. The thymectomized rats and their controls were examined once every week for a period of six weeks following operation. Body length, the distance between shoulder and wrist, and between hip and ankle, as well as femur length were measured. In addition, the epiphyseal cartilages of long tubular bones were studied by histological methods.

Postnatal thymectomy resulted in the development of the characteristic wasting syndrome. The length of the body and limbs of thymectomized rats was significantly reduced as compared to their healthy littermates. The epiphyseal cartilage was remarkably narrower showing a thin zone of proliferating cartilage. The zone of calcifying cartilage was likewise reduced, containing fewer and thinner newly formed bone trabeculae than the controls. These features are indicative of severe disturbances in enchondral ossification and are responsible for the reduced growth of postnatally thymectomized rats.

Introduction

Thymic activity is one of the less known organ activities. This might be the cause that it has become the subject of innumerable immune biological, endocrinological, morphological and physiological investigations. Miller [25] reported that neonatal thymectomy in mice was followed by a characteristic syndrome termed wasting disease. The animals showed a retarded growth, their fur was scarce, their skin thin and wrinkled, and the amount of subcutaneous fat tissue was reduced. In wasted animals marked atrophy of the lymphatic system was observed, with a reduction in the number of small lymphocytes in the lymph nodes and peripheral blood, and diminution of the number of Malpighian corpuscules in the spleen. According to Miller [26], wasting disease is a progressive process as in two to four months following thymectomy more than 70% of the animals died.

By a single large dose of glucocorticoid injection administered to mice 24 hours after birth, Schlesinger and Mark [31] were able to induce symptoms similar to those of the wasting syndrome. Their observations were later confirmed by other authors [7, 10, 12, 30].

The marked difference in body length noted between postnatally thymectomized rats and their healthy littermates, has prompted us to study the relation between the thymus and bone development, the more so as it is known

that the skeletal system is of essential importance in the determination of the length of the body. We have therefore studied the effect of neonatal thymectomy on enchondral ossification which seemed the more interesting as hardly any attention has been paid to this aspect of the problem. In the literature available we have found only the work of BEREK et al. [2] dealing with histological changes of bone due to thymectomy.

Material and method

Thymectomy according to MILLER's method [25] was performed on a total of 108 Wistar albino rats 36 to 48 hours after birth. From the transsternal approach the thymus gland situated in the neck area, covered by a thin connective tissue capsule, was extirpated together with its retrosternal lobe. After careful control of haemorrhage the wound was closed. A similar operation — though without removal of the thymus — was performed on littermates of the rats subjected to thymectomy.

Two to four days following operation the majority of the operated animals died; of the survivors 18 thymectomized rats and the same number of controls were submitted to measurements and histological examination.

The animals were killed in groups of three in weekly intervals from the first to the sixth week following the surgical intervention.

After exsanguination, body length (from the tip of the nose to the tail base), the length of the upper limb (from the shoulder joint to the wrist) and that of the lower limb (from the hip joint to the ankle) were measured. Then the humerus, radius, femur and tibia, as well as the spleen were removed.

The bones were fixed and decalcified in Susa fluid, and the spleen in 4% formol. After fixation the specimens were embedded in paraffin, sectioned in the usual way and stained with haematoxylin-eosin, Azan, and Alcian blue-PAS reaction.

At the removal of the experimental material the surgical area was reopened and any tissue remnants suggestive of thymic origin were removed and examined histologically. In all instances such fragments proved to be fat tissue.

Results

Neonatal thymectomy induced characteristic symptoms of wasting disease in most of the experimental animals (Fig. 1). In the first postoperative week the average body length of thymectomized rats was 6.0 cm, whereas that of the control group was 7.4 cm. This difference, taking the control value as 100%, means a reduction of 18%. The controls continued to grow more rapidly, and by the sixth week their average body length was 14.5 cm, while that of thymectomized rats was only 11 cm, a difference of 23% (Fig. 2). The difference in growth was even more marked with the long bones. Mean femoral length of thymectomized rats, as compared to that of the controls, was 21% less in the first week, 27% less in the 4th, and 35% less in the 6th week following operation (Fig. 3).

The epiphyseal disks of long bones displayed practically identical changes and will therefore be described with respect to the structure of the proximal tibial epiphyseal cartilage disk, on the basis of HAM's [16] zonal division.



Fig. 1. Thymectomized (O) and control (C) rat 6 weeks after operation

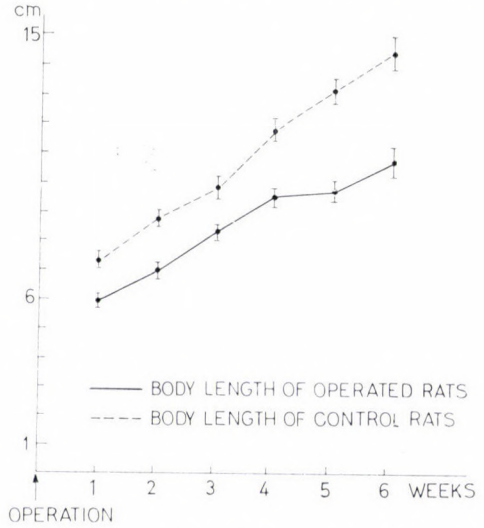

Fig. 2. Mean body length of thymectomized and control rats, including extreme values

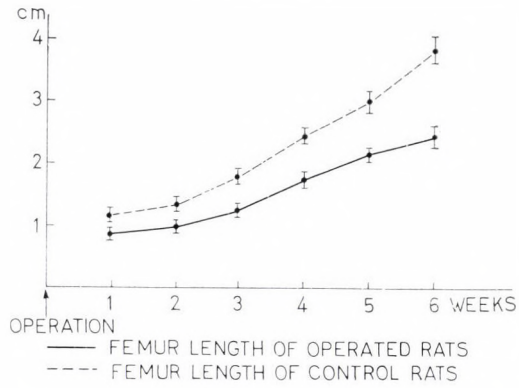

Fig. 3. Femur length in thymectomized and control rats, including extreme values

One-week stage. In the first week following operation there were no appreciable differences between thymectomized and control rats. The epiphyseal cartilage was undeveloped, the whole proximal epiphysis of the tibia consisting of a homogeneous cartilage mass. In the interior, along the vessels penetrating from the perichondrium, the cells were swollen, displaying a lively chondroclastic activity with a consequential medullary cavity formation. On the diaphyseal side of the cartilage mass, enchondral ossification was proceeding.

Two-week stage. At this time the epiphyseal cartilage disk was not yet developed in its whole extent. There was no difference in cartilage thickness between thymectomized and control rats. There were, however, some differences in the structure of the cartilage. In thymectomized rats (Fig. 5) the resting zone and the hypertrophic zone were much broader than in the controls (Fig. 4); the zone of proliferation was narrower and the zone of calcifying cartilage was hardly perceivable.

Three-week stage. The epiphyseal cartilage disks were fully developed, displaying their characteristic layers. The disks of thymectomized rats (Fig. 7) were thinner than those of the controls (Fig. 6). The zone of proliferating cartilage was narrow. The calcification zone was thin containing comparatively few ingrowing capillaries. The newly formed bone trabeculae of the metaphysis were rather thin (Fig. 12) and there was a slight osteoblastic activity.

Fig. 4. Epiphyseal cartilage disk of two-week-old control rat. Haematoxylin-eosin

Fig. 5. Epiphyseal cartilage disk of two-week-old thymectomized rat. The zones of resting and hypertrophic cartilage are broad, whereas the zones of proliferating and calcifying cartilage are narrow. Haematoxylin-eosin

Fig. 6. Epiphyseal cartilage disk of three-week-old control rat. Azan

Fig. 7. Epiphyseal cartilage of three-week-old thymectomized rat. The cartilage disk is thinner than that in the controls. The zones of proliferating and calcifying cartilage are thin. Haematoxylin-eosin

Fig. 8. Epiphyseal cartilage of four-week-old control rat. The cartilage disk shows a regular zonal distribution. Haematoxylin-eosin

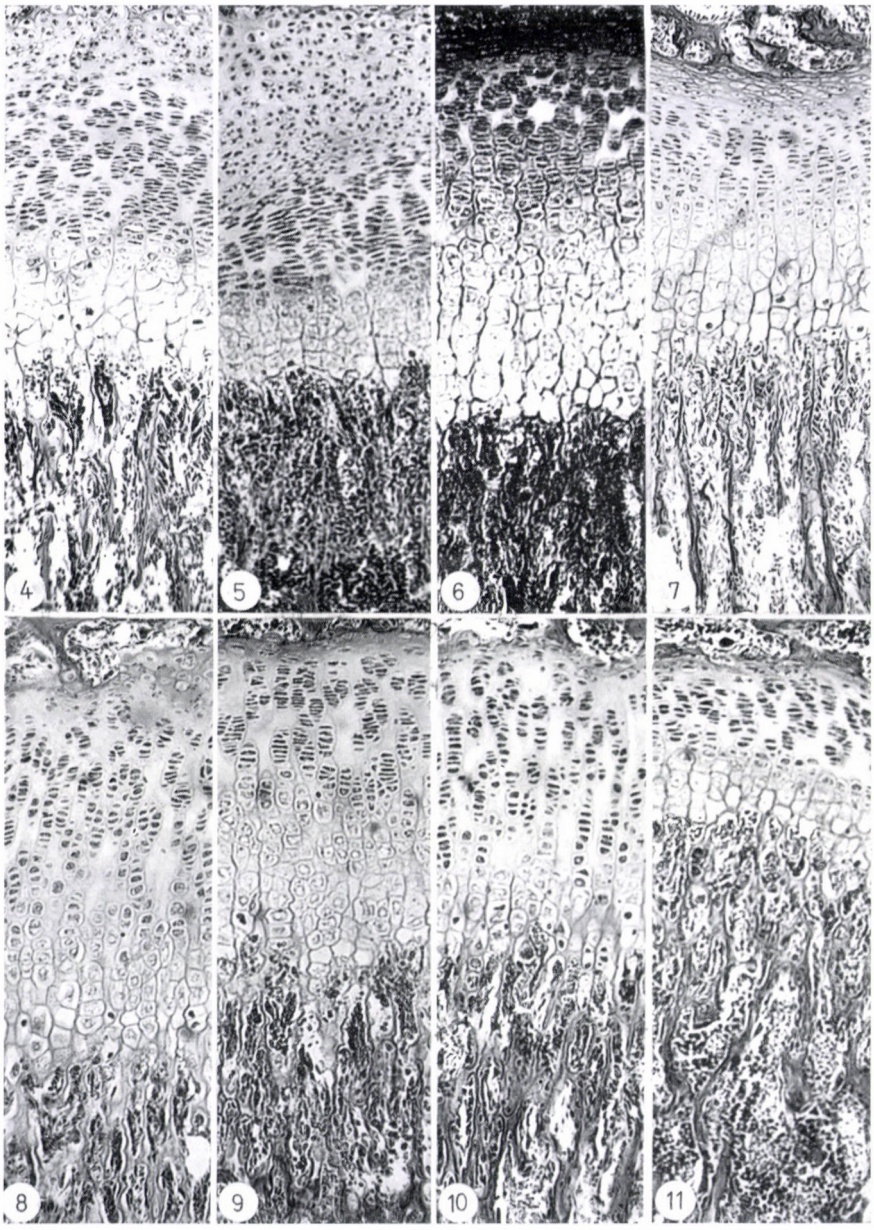

Fig. 9. Epiphyseal cartilage of four-week-old thymectomized rat. The cartilage disk is thinner than in the control. The zone of proliferating cartilage is thin and contains small scattered groups of cells. Haematoxylin-eosin

Fig. 10. Epiphyseal cartilage of five-week-old control rat. Haematoxylin-eosin

Fig. 11. Epiphyseal cartilage of five-week-old thymectomized rat. The cartilage disk is remarkably thinner than in the controls. The zones of proliferating and calcifying cartilage are narrow. Haematoxylin-eosin, Figs 4—11 show proximal tibial epiphyses. (Objective: Reichert Plan 10/0.25; eyepiece: Zeiss K 2.5)

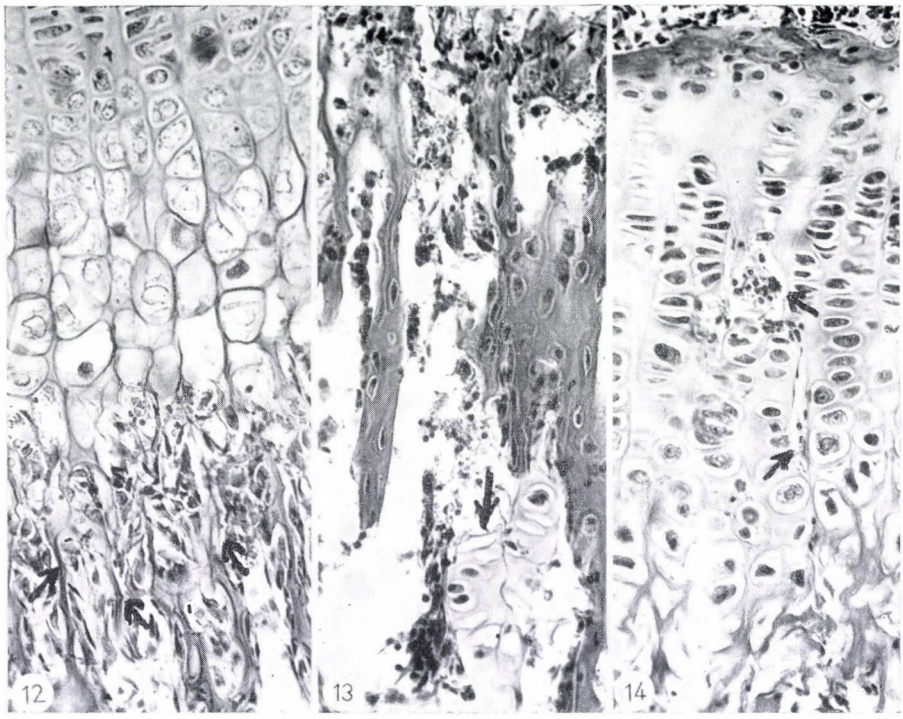

Fig. 12. Epiphyseal cartilage of three-week-old thymectomized rat. The zone of calcification is narrow with a thin young bone trabecula (↑) in the metaphyseal area. Haematoxylin-eosin
Fig. 13. Metaphysis of six-week-old thymectomized rat. Intact cartilage islets (↓) between newly formed bone trabeculae. Haematoxylin-eosin
Fig. 14. Epiphyseal cartilage of six-week-old thymectomized rat. A capillary passing from the calcification zone to the upper part of the zone of proliferation. Haematoxylin-eosin. Figs 12—14 show proximal tibial epiphyses (Objective: Reichert Plan 25/0.45; eyepiece: Zeiss K 2.5)

Four-week stage. As compared to the controls, the epiphyseal cartilage of thymectomized rats (Fig. 9) was even thinner than in the former stages, due almost exclusively to the narrowing of the zones of proliferation and calcification. The newly formed bone trabeculae were likewise thin.

Five-week stage. While the epiphyseal cartilage disks of the controls (Fig. 10) had a regular structure showing numerous cell divisions in the zone of proliferation and a lively bone building activity in the metaphyseal area, the epiphyseal cartilage of thymectomized rats was very thin (Fig. 11). The zone of proliferating cartilage usually consisted of 10—15 cell rows, whereas in the controls it consisted of 25 to 30. In the metaphyses of thymectomized rats there were fewer and thinner bone trabeculae than in the controls.

Six-week stage. The differences noted in earlier stages remained unchanged. In addition, signs of marked cartilage breakdown and disturbed bone building were noted, e.g. at a distance from the zone of calcification, in the lower part

of the metaphysis, islets consisting of intact cartilage cells were seen scattered among the bone trabeculae (Fig. 13). In one specimen, a thin capillary penetrating from the zone of calcification to that of proliferation was noted (Fig. 14).

In the spleen of thymectomized rats a reduction of Malpighian corpuscles and an increase in the number of reticulum cells were observed.

Discussion

The thymus gland is regarded above all as an organ performing immune biological and endocrine activity. MILLER [25, 26] laid special stress on its immunological importance, showing that thymectomy performed in the first 24 to 48 hours of life caused a marked reduction of the immune response to antigens. In consequence of this immune depression, allogenic and heterospecific transplants were retained longer by thymectomized animals than by the controls. On the contrary, if neonatal thymectomy was immediately followed by thymus implantation, the immune response was normal. From these experiments it appeared that the role of the thymus was of essential importance, particularly in the first postnatal days. On the other hand, numerous observations have indicated that the thymus may have an important immunological function in the adult organism, too [24, 27, 32]. According to some authors [3, 14] the thymus seems to have an essential role in the development of autoimmune diseases. Most probably, the immunological function of the thymus is related to the fact that this organ is one of the sites of production of immunologically competent cells [26]. The production of such cells seems to be considerable as in the newborn the mitotic thymus-lymphocyte index is 4 to 6 times higher than that of other lymphatic organs [17]. Thus in young age the thymus may be regarded as an essential site of production of lymphocytes of peripheral blood [23].

It is also supposed that the thymus is a true hormone-producing endocrine organ. According to TÖRŐ and OLÁH [33] the epithelial cells of the guinea pig are of a glandular character displaying a well developed ER system and Golgi apparatus. GOLDSTEIN et al. [15, 18, 19] isolated from the thymus a biologically active factor termed thymosin which, if given parenterally, caused a marked increase of lymphocytopoietic activity and depression of the symptoms of wasting disease in thymectomized animals. The consequences of neonatal thymectomy did not take place if thymic tissue placed in a small diffusion chamber was implanted in the experimental animal immediately after thymectomy [1, 22, 28]. COMSA [4] as well as FACHET et al. [8, 9] pointed to interesting functional interrelations between the thymus and other endocrine organs.

The pathogenesis of the wasting syndrome is by no means clear. Some authors regard it as an immunological catastrophe and emphasize the impor-

tance of different antigens [4, 29]. Others suppose endocrinological occurrences. In our experience, enchondral ossification also suffers severe damage in the syndrome. We have found that neonatal thymectomy caused a considerable reduction in thickness of the epiphyseal cartilage disks of long tubular bones, and marked changes in their structure. The most conspicuous changes were noted in the zones of proliferating and calcifying cartilage. The former was found to be very narrow with disorderly arranged cells, and the latter was sometimes so much reduced in width that in younger age groups it was hardly recognizable as a distinct layer. In the epiphyseal cartilages the newly formed bone trabeculae were considerably fewer and thinner in thymectomized rats than in the controls. The histological pattern indicated a disorder in the equilibrium of nearly all phases of normal bone development (cartilage formation — cartilage destruction — bone formation — bone destruction). The disturbances of cartilage formation and cartilage breakdown seem to be the primary consequences of thymectomy followed undoubtedly by disturbances of bone building and bone disintegration. A similar narrowing of the epiphyseal cartilage disk following neonatal thymectomy was observed in mice by FÖLDES et al. [13]. On the basis of X-ray studies these authors also concluded that thymectomy caused a reduction in the calcium content of bones.

From the present findings it was not possible to explain the cause and mechanism of the changes noted in ossification following thymectomy. Several hypotheses have been forwarded. It may be supposed that the thymus has a direct effect on ossification, producing a substance required for normal bone development and calcification. According to another hypothesis, disturbed ossification might be the consequence of the general hormonal dysfunction and metabolic changes caused by thymectomy. The explanation seems to be more difficult on the basis of the immune biological concept, all the more that cartilage, as regards immune response, is considered a passive tissue [5, 6]. We are more inclined to believe that the cachexia subsequent to thymectomy may be the primary cause of disturbances in bone development. Further studies are required to elucidate this complex problem.

REFERENCES

1. AISENBERG, A. C., WILKES, B.: (1965) Partial Immunological Restoration of Neonatally Thymectomized Rats with Thymus Containing Diffusion Chambers. Nature (Lond.) **205,** 716—717. — 2. BEREK, L., BÁNCS, Zs., SZERI, I., ANDERLIK, P., ASZÓDI, K.: (1968) Újszülött korban thymus irtott egerek csontelváltozásai. Kísérl. Orvostud. **20,** 240—243. — 3. BURNET, M.: (1969) Self and Not-self. Cambridge University Press, pp. 255—285. — 4. COMSA, J.: (1957) Effect of Thymectomy upon the Functional Condition of the Adrenal Cortex in Guinea Pigs. Nature (Lond.) **179,** 872—873. — 5. CRAIGMYLE, M. B. L.: (1958) An Autoradiographic and Histochemical Study of Long Term Cartilage Grafts in the Rabbit. J. Anat. **92,** 467—472. — 6. CRAIGMYLE, M. B. L.: (1958) Antigenicity and Survival of Cartilage Homografts. Nature (Lond.) **182,** 1248. — 7. CSABA, G., FISCHER, J.: (1966) Data Regarding the Mechanism of Wasting Disease in Chemically Thymectomized Rats. Acta biol. Acad. Sci. hung.

17, 75—88. 8. FACHET, J., VALLENT, K., PALKOVITS, M., ÁCS, ZS.: (1964) A thymus szerepe az experimentális hyperthyreosis okozta mellékvese functio változásában. Magy. Belorv. Arch. **17,** 98—105. — 9. FACHET, J., PALKOVITS, M., VALLENT, K.: (1965) Effect of Neonatal Thymectomy on Endocrine and Lymphatic Organs, Reticular Elements and Blood Count. Acta med. Acad. Sci. hung. **21,** 305—310. — 10. FACHET, J., PALKOVITS, M., VALLENT, K., STARK, E.: (1966) Effect of Single Glycocorticoid Injection on the First Day of Life in Rats. Acta endocr. (Kbh.) **51,** 71—76. — 11. FACHET, J., PALKOVITS, M., PETRÁNYI, G. JR.: (1966) Effect of a Single Neonatal Glycocorticoid Dose on the Lymphatic and Endocrine Organs and on the Transplantation Immunity of Rats. Acta morph. Acad. Sci. hung. **14,** 259—273. — 12. FACHET, J., STARK, E., VALLENT, K., PALKOVITS, M.: (1966) The Effect of Glycocorticoid Administered on First Day of Life on Survival, Body Weight, Lymphatic Organs and Blood Counts in the Rat. Acta physiol. Acad. Sci. hung. **29,** 374. — 13. FÖLDES, P., SZERI, I., BÁNOS, ZS., ANDERLIK, P.: (1967) Adatok az újszülöttkori thymectomiát követő "wasting syndrome" pathomechanizmusához. Orv. Hetil. **108,** 1021—1025. 14. GOLDSTEIN, G.: (1966) Thymitis and Myasthenia gravis. Lancet, II; 1164—1167. — 15. GOLDSTEIN, A. L., SLATER, F. D., WHITE, A.: (1966) Preparation, Assay, and Partial Purification of a Thymic Lymphocytopoietic Factor (Thymosin). Proc. Nat. Acad. Sci. (Wash.) **56,** 1010—1017. — 16. HAM, A. W.: (1953) Histology. 2nd edition. Lippincott, Philadelphia, Pp. 238—243. — 17. KINDRED, J. E.: (1942) Quantitative Study of Hemopoietic Organs of Young Adult Albino Rats. Amer. J. Anat. **71,** 207—243. — 18. KLEIN, J. J., GOLDSTEIN, A. L., WHITE, A.: (1965) Enhancement of in vivo Incorporation of Labeled Precursors into DNA and Total Protein of Mouse Lymph Nodes after Administration of Thymic Extracts. Proc. Nat. Acad. Sci. (Wash.) **53,** 812—817. — 19. KLEIN, J., J., GOLDSTEIN, A. L., WHITE, A.: (1966) Effects of the Thymus Lymphocytopoietic Factor. Ann. N. Y. Acad. Sci. **135,** 485—495. — 20. KROMPECHER, ST.: (1950) A csontfejlődés egyes kóros formái. Magy. Radiol. **3,** 15. — 21. KROMPECHER, ST.: (1958) Die enchondralen Ossificationsstörungen. Orthopädie, **5,** 87—97. — 22. LEVEY, R. H., TRAININ, N., LAW, L. W.: (1963) Evidence for Function of Thymic Tissue in Diffusion Chambers Implanted in Neonatally Thymectomized Mice. Preliminary Report. J. nat. Cancer Inst. **31,** 199—218. — 23. METCALF, D.: (1960) The Effect of Thymectomy on the Lymphoid Tissues of the Mouse. Brit. J. Haemat. **6,** 324—333. — 24. METCALF, D.: (1965) Delayed Effect of Thymectomy in Adult Life on Immunological Competence. Nature (Lond.) **208,** 1336. — 25. MILLER, J. F. A. P.: (1961) Immunological Function of the Thymus. Lancet **2,** 748—750. — 26. MILLER, J. F. A. P.: (1962) Role of Thymus in Transplantation Immunity. Ann. N.Y. Acad. Sci. **99,** 340—354. — 27. MILLER, J. F. A. P.: (1965) Effect of Thymectomy in Adult Mice on Immunological Responsiveness. Nature (Lond.) **208,** 1337—1338. — 28. Osoba, D., Miller, J. F. A. P.: (1964) The Lymphoid Tissues and Immune Responses of Neonatally Thymectomized Mice Bearing Thymus Tissue in Millipore Diffusion Chambers. J. exp. Med. **119,** 177—185. — 29. REED, N. J., JUTILA, J. W.: (1965) Wasting Disease Induced with Cortisol Acetate: Studies in Germ-free Mice. Science 150, 356—357. — 30. SCHAPIRO, S.: (1965) Neonatal Cortisol Administration: Effect on Growth, the Adrenal Gland and Pituitary—Adrenal Response to Stress. Proc. Soc. exp. Biol. (N.Y.) **120,** 771—774. — 31. SCHLESINGER, M., MARK, R.: (1964) Wasting Disease Induced in Young Mice by Administration of Cortisol Acetate. Science **143,** 965—967. — 32. TAYLOR, R. B.: (1965) Decay of Immunological Responsiveness after Thymectomy in Adult Life. Nature (Lond.) **208,** 1334—1335. — 33. TÖRŐ, I., OLÁH, I.: (1966) Electron Microscopic Study of Guinea-pig Thymus. Acta morph. Acad. Sci. hung. **14,** 275—290.

WIRKUNG DER POSTNATALEN THYMEKTOMIE AUF DIE ENCHONDRALE OSSIFIKATION

B. MÁNDI, CS. HADHÁZY, A. MÁNDI und T. GLANT

Die Thymektomie wurde an neugeborenen Albinoratten 36—48 Stunden nach der Geburt durchgeführt. Die thymektomierten und die Kontrolltiere wurden wöchentlich im Verlaufe von sechs Wochen nach der Operation untersucht. Es wurden die Körperlänge, die Entfernung zwischen Schulter und »Handwurzelgelenk« und von der Hüfte bis zum »Fußwurzelgelenk« sowie die Länge des Femurs bestimmt. Mittels histologischer Methoden wurden weiterhin die Knorpelepiphysen der Röhrenknochen untersucht.

Die postnatale Thymektomie verursacht ein charakteristisches Atrophiesyndrom. Die Körperlänge sowie die Länge der Extremitäten war im Vergleich zu den gesunden Tieren des gleichen Wurfes signifikant kleiner. Der Epiphysärknorpel war auffällig schmaler, die Proliferationszone der Knorpel war dünner. Die Verkalkungszone des Knorpels war ebenfalls

geringer und die neuen Knochentrabekeln waren dünner als bei den Kontrolltieren. Die charakteristischen Besonderheiten weisen auf schwere Störungen der enchondralen Ossifikation hin und sind für die Verringerung des Wachstums der Ratten verantwortlich, an denen nach der Geburt eine Thymektomie durchgeführt wurde.

ДЕЙСТВИЕ ПОСЛЕРОДОВОЙ ТИМЭКТОМИИ НА ЭНХОНДРАЛЬНОЕ ОКОСТЕНЕНИЕ

Б. МАНДИ, Ч. ХАДХАЗИ, А. МАНДИ и Т. ГЛАНТ

Тимэктомия была проведена на крысах-альбиносах через 36—48 часов после рождения. Тимэктомизированные и контрольные крысы исследовались еженедельно на протяжении шести недель после операции. Определялись длина тела, расстояние от плеча до лучезапястного и от тазобедренного до голеностопного суставов. Измерялась также длина бедренной кости. Затем гистологическими методами изучались хрящевые эпифизы трубчатых костей.

Послеродовая тимэктомия вызывает характерный синдром атрофии. Длина тела и конечностей у тимэктомизированных крыс была достоверно меньшая по сравнению со здоровыми животными. Эпифизарный хрящ был заметно уже, зона пролиферации хряща была тоньше. Зона обызвествления хряща была также уменьшена и новые костные трабекулы были тоньше, чем у контрольных животных. Эти характерные особенности указывают на тяжелые расстройства энхондрального окостенения и они ответственны за уменьшение роста крыс, которым после рождения была проведена тимэктомия.

Dr. Barnabás MÁNDI
Dr. Csaba HADHÁZY
Dr. András MÁNDI
Dr. Tibor GLANT

Anatómiai-, Szövet- és Fejlődéstani Intézet,
Debrecen, Hungary

Acta Morphologica Acad. Sci. Hung. 19 (3), pp. 269—281, 1971

Institute of Anatomy (Director: Dr. J. Szentágothai), Semmelweis University Medical School, Budapest

THE VENA PORTAE AS AN "INDEPENDENT" VENOUS SEGMENT

ITS MURAL STRUCTURE AND INNERVATION

G. Ungváry, Erzsébet Petrovics, Cs. Léránth and S. A. Naszály

(Received March 25, 1970)

The mural structure of the vena portae of guinea pigs was studied by connective and muscle tissue staining methods, the innervation by histochemical reactions [acetylcholinesterase (AChE) reaction, monoamino oxidase (MAO) reaction, as well as Champy's zinc iodine osmium (ZnIOs) method] and by electron microscopy. It has been demonstrated that the inner circular muscular layer of the vena portae had a longitudinal muscular coating, C-shaped in the middle part of the vascular segment and circular at the confluence and primary bifurcation.

Preterminal nerve bundles positive by the AChE test were found exclusively in the adventitia. The most marked MAO reaction occurred in the longitudinal muscular layers; at the junction of the adventitia and media there was a dense network of monoaminergic fibres. Fibres positive by the ZnIOs test occurred in all three layers of the vascular wall.

By electron microscopy, fibres covered by Schwann cell cytoplasm or free from Schwann cells could be detected in the adventitia, media and intima.

On the basis of its mural structure and peculiar innervation, the vena portae is considered an independent venous segment.

Modern methods have made it possible to determine cardiac output simultaneously with total hepatic flow and so to estimate the hepatic fraction of cardiac output. Myers (1950) found in man values ranging from 14 to 26%, as compared to the 20 to 25% reported by Reichman et al. (1958). Fischer et al. (1960) estimated the liver fraction at 11 to 40% (mean, 23%) in the dog; of this, 6% fell to the hepatic artery and 17% to the vena portae. Thus, the vena portae, which carries the venous blood from the abdominal viscera toward the liver and the ligation of which has a fatal outcome, is capable of transporting extremely large volumes of blood. In modern circulation physiology the measuring instrument is the electromagnetic flow meter. Its application to the individual vascular segments including the vena portae represents a mechanical, local stimulation, to which the vascular segment responds according to its properties. It is known that in the various forms of cirrhosis there is a marked hypertrophy especially of the longitudinal muscles of the wall of the vena portae. Köhn and Richter (1959) explain this by suggesting that the increased resistance produced inside the cirrhotic liver by the abnormal vascular system (portal hypertension) is overcome by the portal trunk by means of a working hypertrophy.

In a previous study (Ungváry and Faller, 1963) of injected-corroded preparations we often found at the origin and bifurcation of the vena portae

impressions, between which the trunk of the vena portae was located as a "venous segment".

It seemed therefore justified to study the functional anatomy of the portal venous trunk, the precise structure of its vascular wall and the possibilities of neural regulation of the vascular segment.

Materials and methods

Thirty guinea pigs were used. The vascular segment was removed, so that to its caudal end was continuous with the portal stump of the lienal and mesenteric veins while cranially the primary bifurcation remained in connection with the vascular trunk. Part of the material was fixed in 5% formaldehyde solution, at the levels shown in Fig. 1, embedded in celloidin-paraffin, and the sections were stained with haematoxylin-eosin, Azan, as well as by the Van Gieson and the Farkas–Mallory methods. The other methods employed were silver impregnation according to Gross and Schultze, Champy's zinc-iodide-osmium (ZnIOs) method, the Falck and Hillarp technique for the demonstration of catecholamines (CA), the monoamino oxidase (MAO) method of Glenner et al. and the acetylcholinesterase (AChE) reaction of Coupland and Holmes. The latter was carried out at different pHs, after preincubation for 30 minutes with 10^{-5} M Iso-OMPA.

In the third group the specimens were subjected to electron microscopic study. The material was fixed in paraformaldehyde solution, post-fixed in osmic acid and embedded in Durcupan. Ultrathin sections were cut on the LKB ultrotome, contrasted according to Reynolds, and examined in a TESLA BS 413 electron microscope.

Results

The methods suitable for the staining of muscle and connective tissue fibres revealed that the mural structure was variable in the guinea pig portal vein, in the trunk at the confluence of the lienal and mesenteric veins, at the site where the portal vein divides into the primary trunci, as well as in the primary trunci (Fig. 1). The circularly arranged muscle bundles of the media at the confluence of the lienal and common mesenteric veins and the division into primary trunci are surrounded circularly by longitudinal muscle bundles parallel to the axis of the portal vein in the inner part of the adventitia. These longitudinal bundles are absent in the ventral aspect of the middle segment of the portal vein nor are they visible in the primary trunci.

Of the neurohistochemical reactions AChE demonstrated only major preterminal nerve bundles, occurring invariably in the adventitia, in the connective tissue of the portal vein (Fig. 2).

Even the widest scale of variation of the method failed to detect the presence of AChE positive nerve fibres in the muscle. It is to be noted that we have found copious quantities of AChE positive fibres intrahepatically in the guinea pig.

Some of the fibres detaching themselves from major nerve bundles may be demonstrated by the ZnIOs reaction (Fig. 3). The fibres are in the adventitia

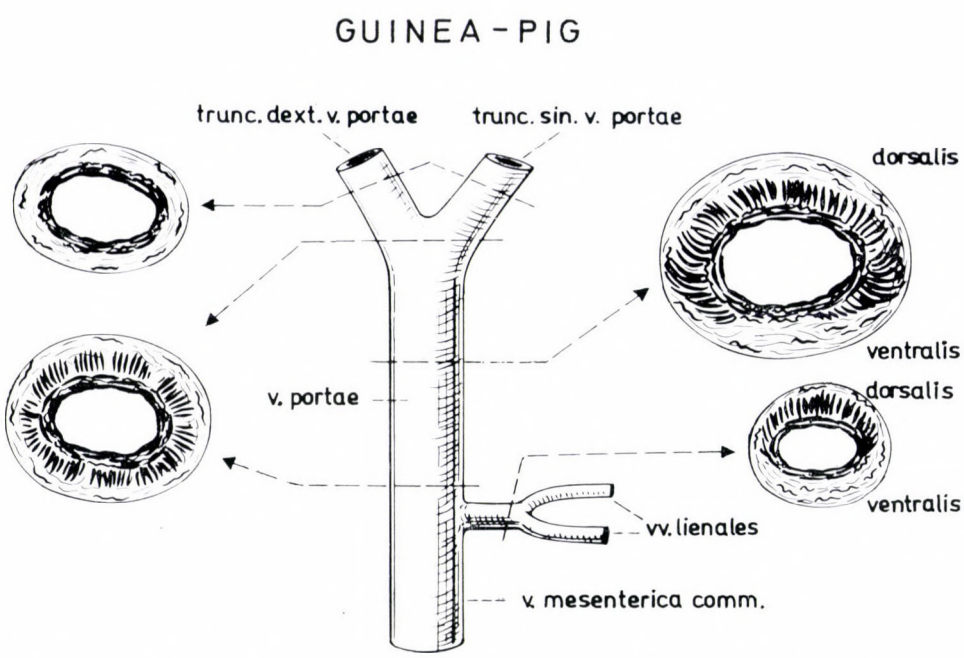

Fig. 1. Diagrammatic representation of the mural structure of the portal vein in the guinea pig

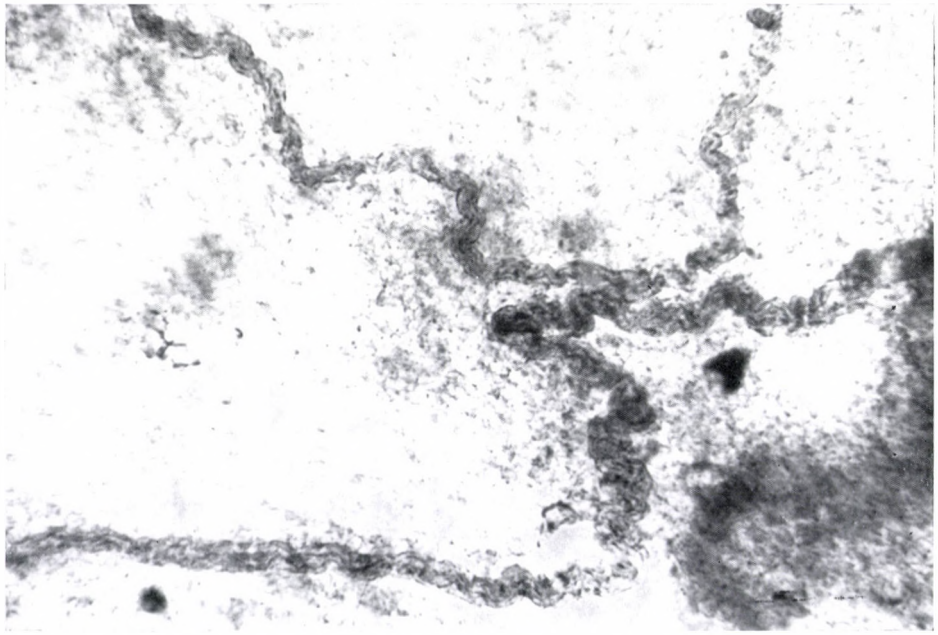

Fig. 2. Spread-out wall of portal vein. Note thick nerves running in the adventitial connective tissue. Coupland–Holmes' AChE reaction, six-hour incubation, 30 minutes of 10^{-5} M Iso-OMPA preincubation. ×180

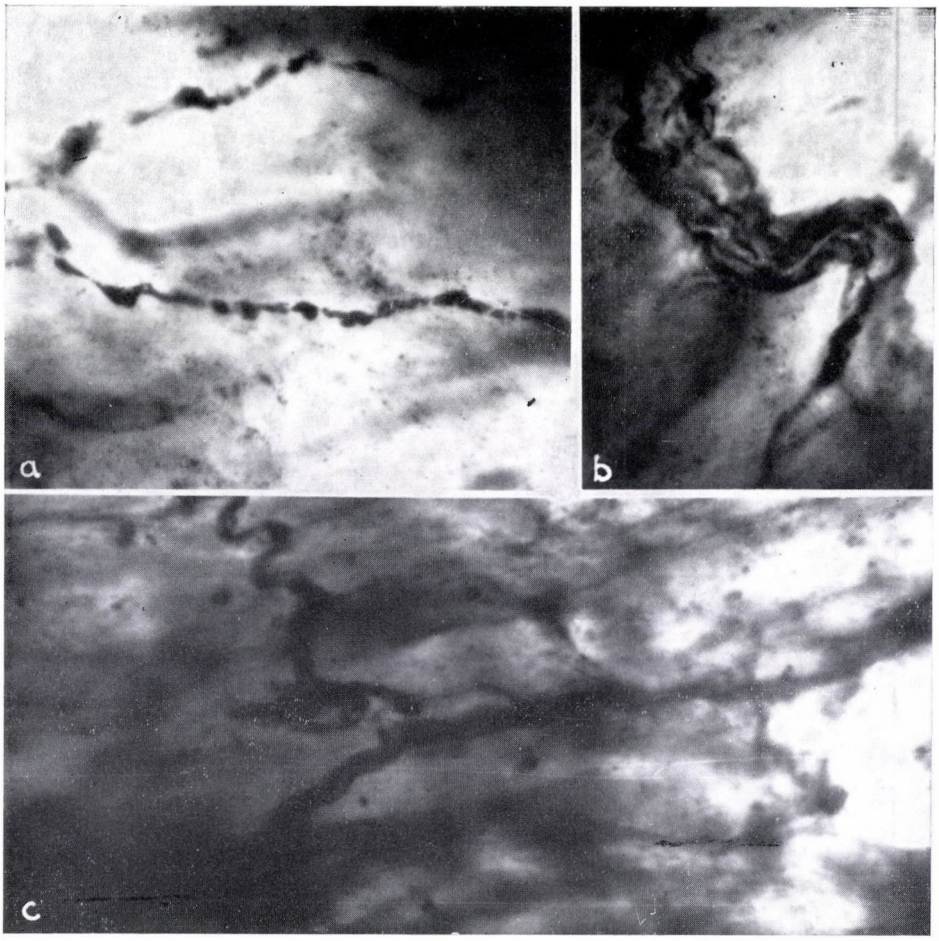

Figs 3a—c. Spread-out portal vein with ZnIOs positive nerves running in the adventitia. Champy's ZnIOs staining. Magnifications: a) ×800; b) ×500; c) ×180

(adventitial nerve plexus) and here only a few preterminal or terminal fibres emerge from them, running then on the longitudinal muscle bundles of the adventitia. Another part of the fibres run between the muscle bundles, or penetrate the media, almost reaching the intima (Fig. 4). A number of nerve fibres appears to be present at the bifurcation of the portal vein (Fig. 5).

The catecholamine reaction calls attention to a remarkably rich monoaminergic nervous network. The terminals showing specific fluorescence, particularly at the origin and division of the portal vein, are so densely situated as in the iris (Fig. 7). The sections cut at the portal vein division level show clearly that the monoaminergic fibres at the junction of adventitia and media lie close to the media and there are only a few "free" fibres in the space between the trunci (Fig. 8).



Fig. 4. Portal venous trunk. The nerve fibres penetrate between muscle bundles, showing at sites a "terminal-like" pattern (insert). Champy's ZnIOs staining. Magnification ×400, insert ×800

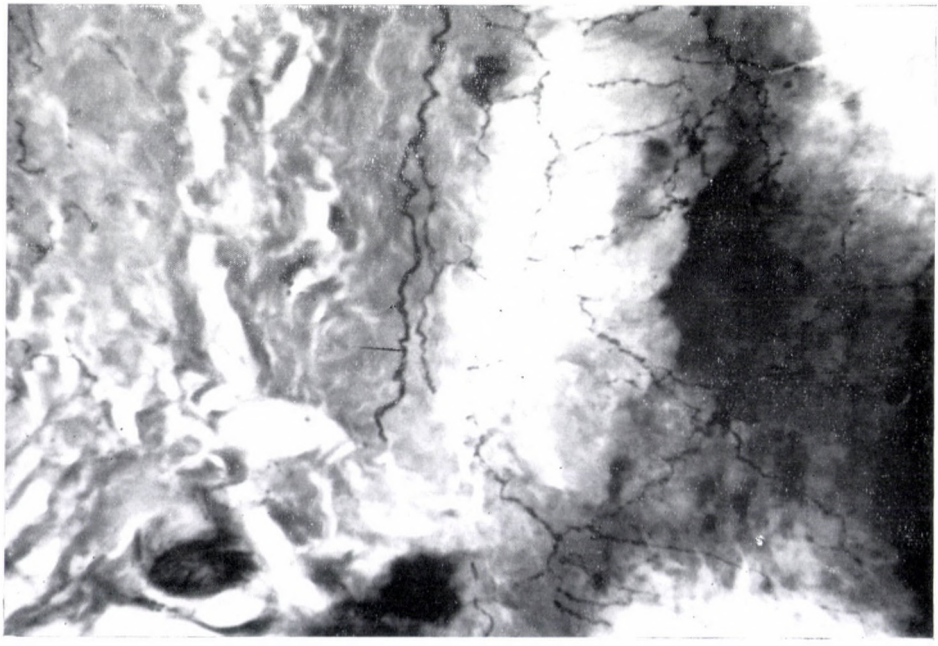

Fig. 5. First portal division: numerous ZnIOs positive fibres, some of them almost reaching the intima. Champy's ZnIOs staining. ×800

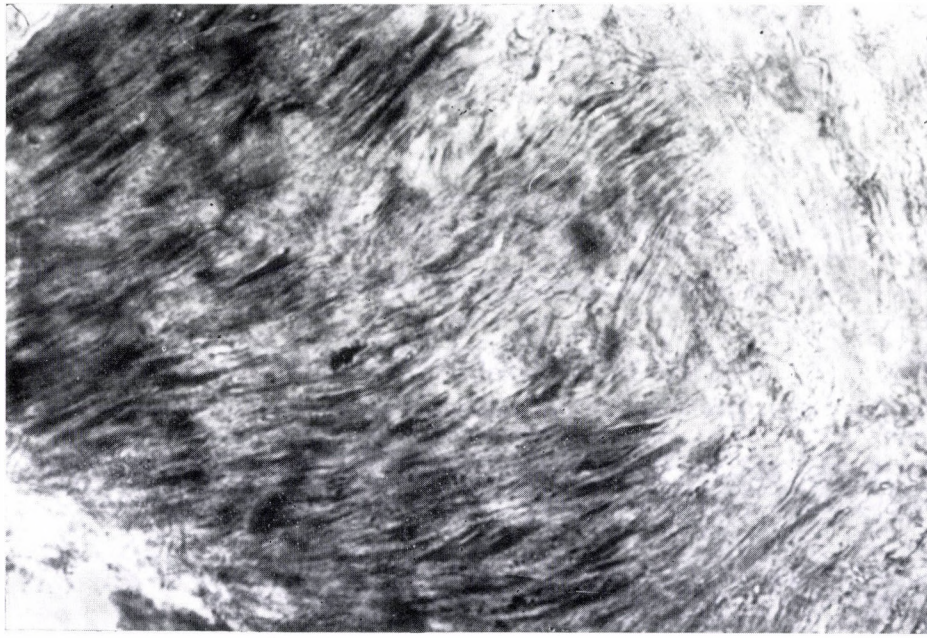

Fig. 6. Intensive extraneuronal MAO reaction of the muscular layer. The internal media is negative. MAO reaction of Glenner et al. ×400



Fig. 7. Spread-out portal vein with dense nervous monoaminergic network, showing intensive fluorescence by the Falck–Hillarp paraformaldehyde reaction. Magnification on the left side ×180, on the right side ×400

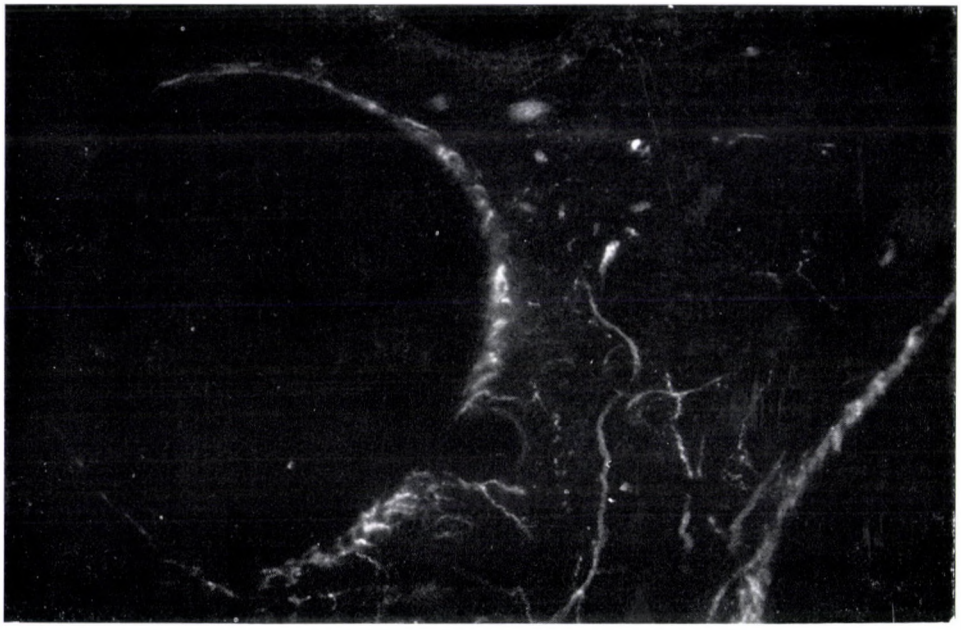

Fig. 8. The first intrahepatic division. At the junction of adventitia and media there are monoaminergic fibres showing intensive fluorescence. Between the two trunci there are "free" nerves, running onto the division from above. Falck–Hillarp reaction. ×300

The localization of MAO corresponds only within broader limits to that of the catecholamine containing nerve fibres. The enzyme reaction is intensive in the longitudinal muscle layer, while it is practically negative in the connective tissue, in the circular muscle layer of the adventitia and in the intima. The reaction shows no fibre-like localization, it is found extraneuronally (Fig. 6).

By electron microscopy, nerves could be demonstrated in all three layers of the portal venous trunk. In the adventitia (Fig. 9), there are several axons in a common Schwann cell, a few of them contain dense core vesicles.

In the media, in the interspace between muscle fibres inside the Schwann cell, partly without the Schwann cells, there are axons in intimate connection with smooth muscle cells (Fig. 10).

The last electron microscopic picture shows axons inside a Schwann cell in the intima, with a few axons already emerged from it (Fig. 11).

Discussion

The studies of the mural structure of the portal vein have thus revealed that at the site of origin of the portal vein (confluence of common mesenteric and lienal veins) and at the bifurcation into primary trunci, the vein has a complete internal circular and an external longitudinal muscular layer. This

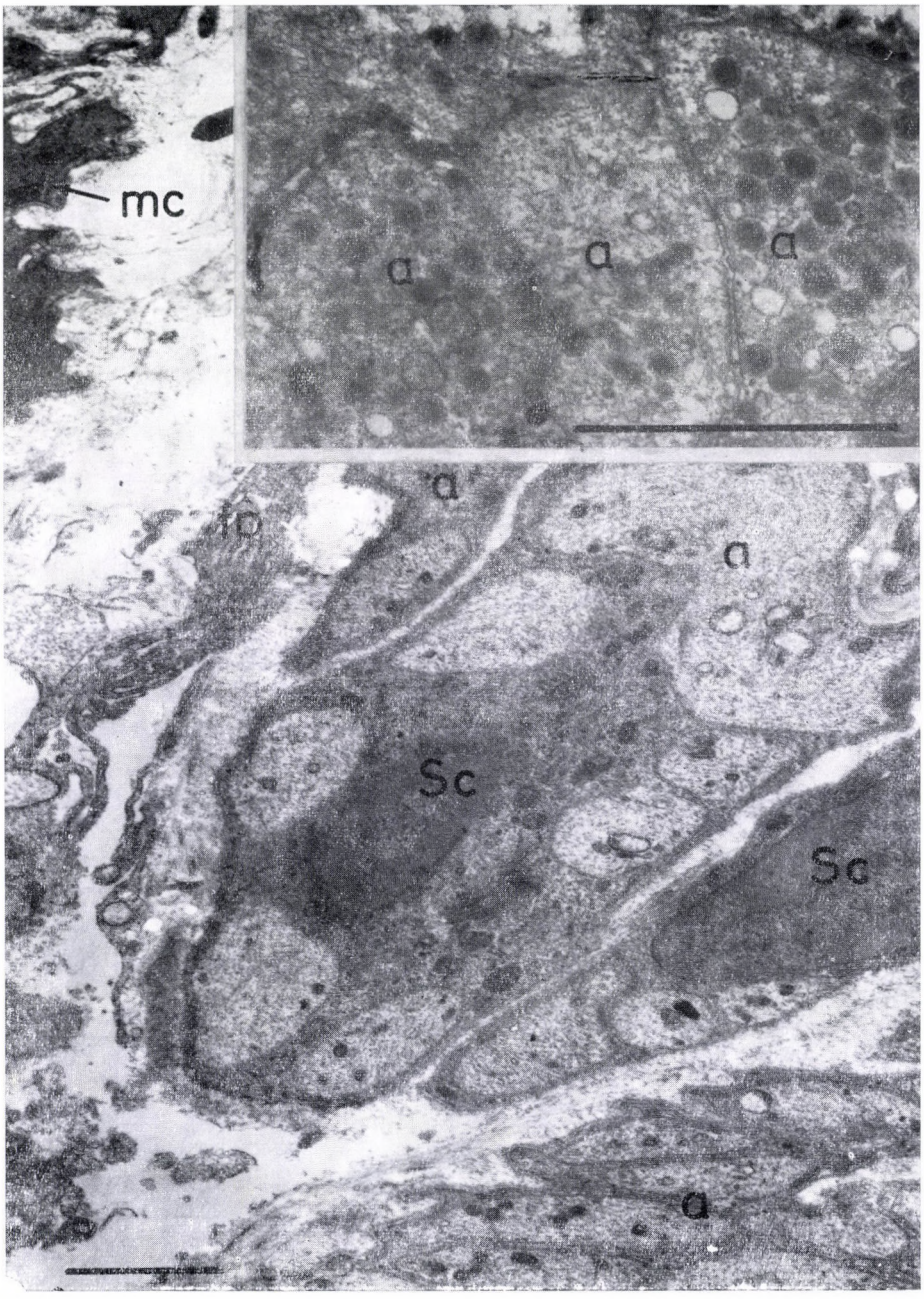

Fig. 9. Electron microscopic appearance of part of the adventitia. Numerous nerve fibres in the cytoplasm of the Schwann cell (Sc). In left upper corner, smooth muscle cell (mc). A fibrocytic process (fp) penetrates between the muscle cells and the fibre bundles. Scale, 1 μ. In the insert: dense core vesicle axons in the adventitia. Scale, 1 μ

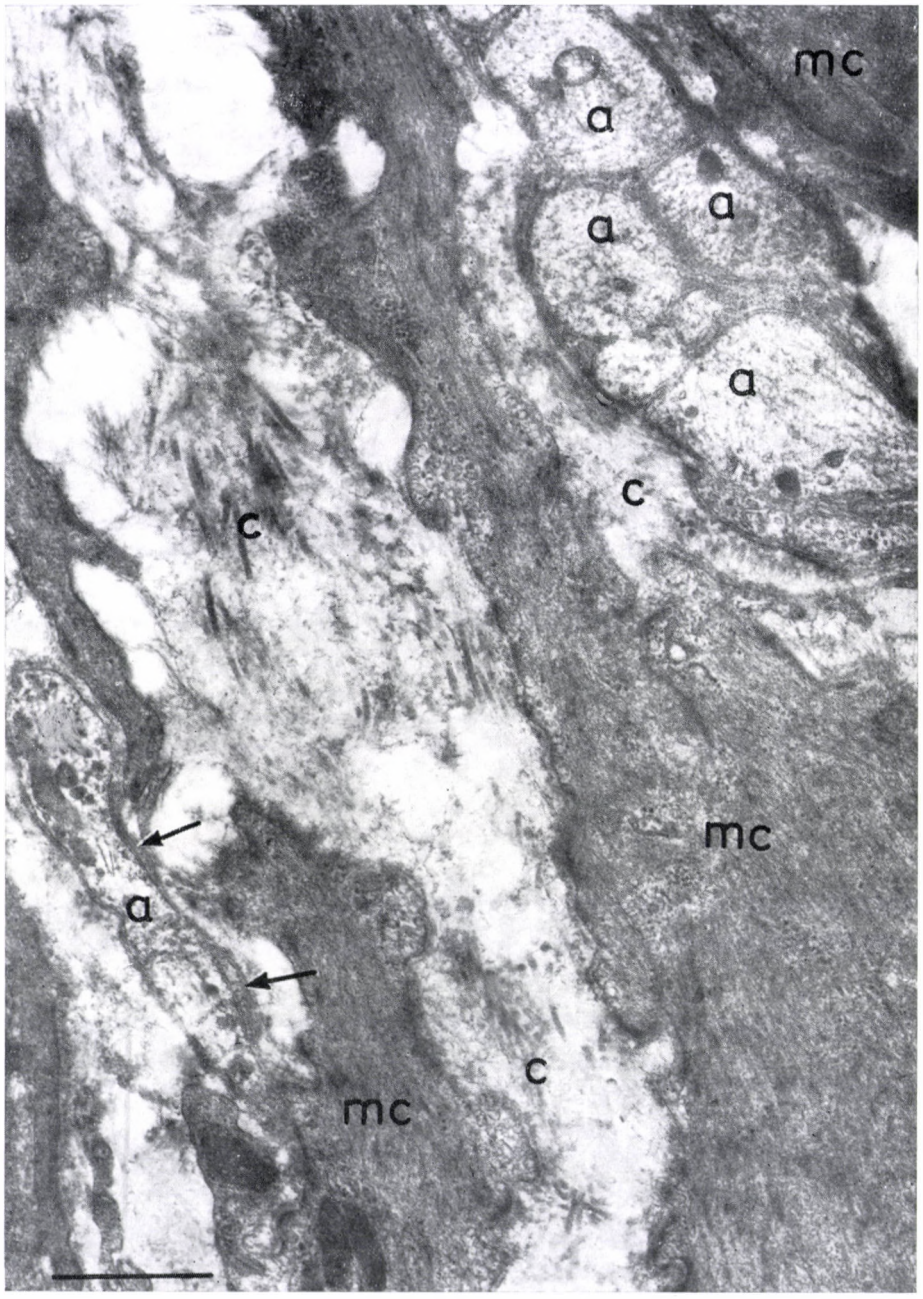

Fig. 10. Electron microscopic appearance of part of the media. The nerve fibres are in the collagen (c) between the smooth muscle cells. The axons (a) in the upper right corner are in no close contact with the smooth muscle cells (mc). In the left lower corner the axon terminal (a) contains numerous empty vesicles and is covered only at sites by Schwann cell processes (arrows). At this site is the axon nearest to the muscle cells (mc). Scale, 1 μ

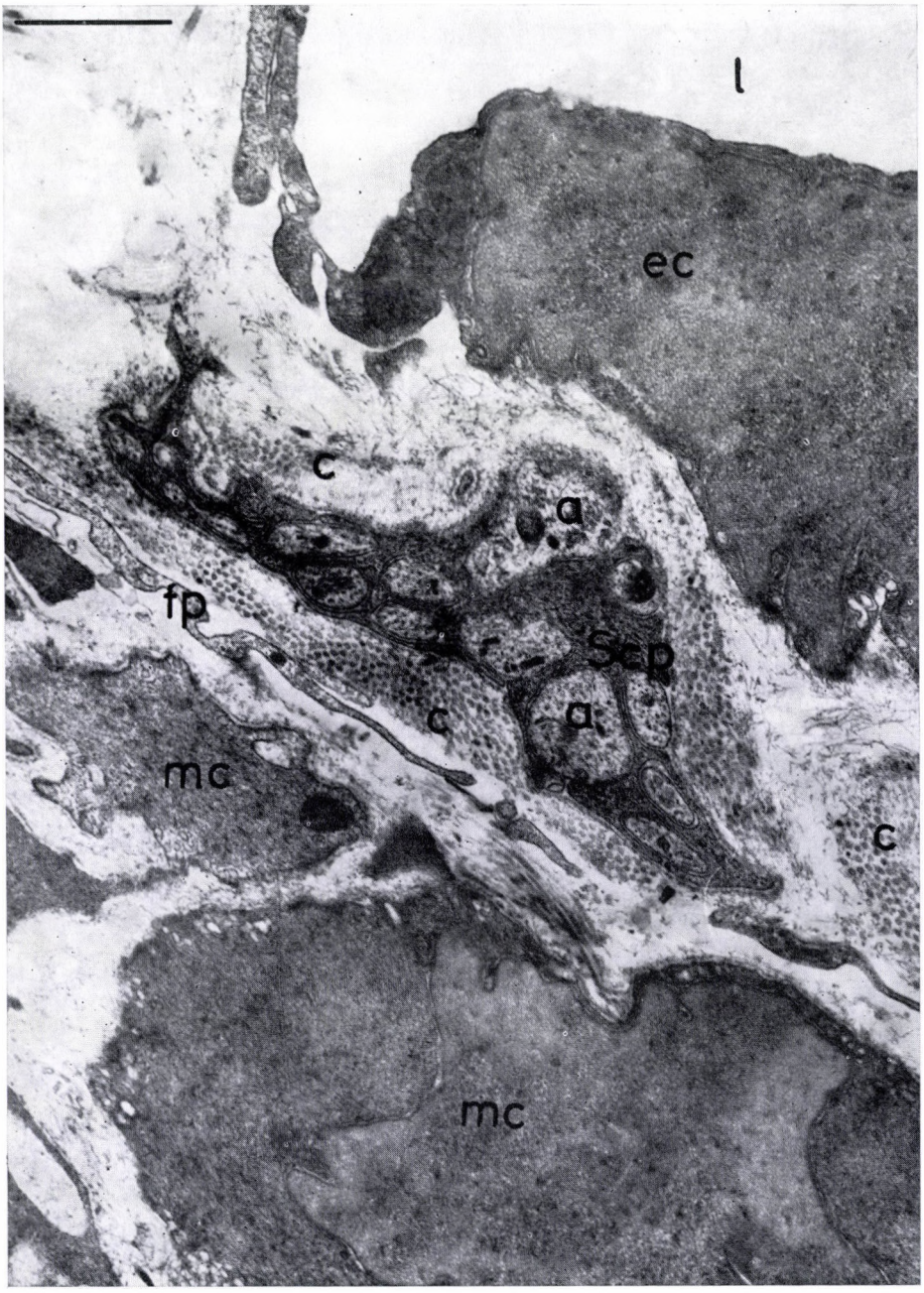

Fig. 11. Electron microscopic appearance of part of the intima. The axons (a) are in the collagen (c) under the endothelial cell (ec) lining the lumen (l). The axons covered by Schwann cell processes are separated from the muscle cells (mc) of the media by a fibrocytic process (fp). Scale, 1 μ

may be interpreted with some caution to indicate that the mural structure of the portal vein may make it capable of acting as a regulatory factor between the splanchnic and hepatic-portal vascular beds. This hypothesis is supported by the data according to which in portal hypertension the wall of the portal vein becomes thicker, independently of the splanchnic or intrahepatic blood vessels (KÖHN and RICHTER, 1959).

The innervation of the portal vein seems to be interesting. Although the innervation of veins was rather extensively discussed in earlier literature, there is scarce evidence concerning the portal vein.

A detailed paper on the innervation of the portal vein was published by MOOTZ (1965) who had employed the ZnIOs method, the AChE technique and Bodian's impregnation procedure. The results obtained by the two latter techniques are the same as ours. By CHAMPY's method MOOTZ failed to demonstrate the presence of nerves between muscle fibres, where we have found several nerve terminals.

Writing about innervation of the veins, ÁBRAHÁM (1969) stated that their innervation was practically the same as that of arteries. In the adventitia large nerve trunci are visible, which toward the media decrease in number, and are reduced in diameter. In the media the nerves approach the muscle cells and end there. The hypotheses put forward vary from author to author. BUSCH (1929) described an intercellular network between the smooth muscles, built up of unmyelinated fibres. According to STÖHR jr. (1932) there is a terminal reticulum in the muscularis of the vascular wall. HILLARP (1946) described between the muscle bundles thinner and thicker nerve bundles which ramify and anastomose; this is called the "nervous ground plexus". However, there is agreement among the majority of authors that nerve fibres would not penetrate deeper than the media. Our electron microscopic finding was therefore striking, but there is no doubt about the existence of an intimal innervation in the portal vein. In the splanchnic region only sympathetic nerves can be demonstrated by physiological methods (BRADLEY, 1963). We do not therefore consider surprising the masses of monoaminergic fibres which, however, occur exclusively at the junction of the adventitia and media. Intrahepatically, the monoaminergic terminals of the portal venous nerves are at the junction of the adventitia and the media too (UNGVÁRY and DONÁTH, 1969). The MAO reaction is localized essentially to the longitudinal muscle bundles, corresponding to the monoaminergic innervation. This is in agreement with the observation of RADYMSKA-WAWRZYNIAK (1968) who found in certain venous segments of different species the most intense MAO reaction essentially in the same layer. LUKAS and CECH (1966) found that also in the iris there was a gross parallelism between the adrenergic nerves and the distribution of MAO.

The nerve fibres of the media and intima (the existence of which is proved beyond doubt by the electron microscopic finding) cannot be demonstrated

either by the FALCK—HILLARP CA-specific reaction, or by the method of COUPLAND and HOLMES specific for AChE. These fibres could be demonstrated by light microscopy exclusively by the ZnIOs method of CHAMPY. This was unexpected, because according to HILLARP (1959) the CHAMPY technique would demonstrate the adrenergic fibres, while AKERT and SANDRI (1968) found the precipitate characteristic of the ZnIOs reaction in the synaptic vesicles of cholinergic junctions.

In 1963, BRAUER wrote that the portal vein itself was a collapsible reservoir, placed between two larger reservoirs, in which the pressure fluctuations were the function of changes in abdominal pressure correlated with the movements of the diaphragm.

In the light of recent data and our own results it seems that the portal vein, placed between the splanchnic and hepatic circulation systems, may be considered a venous segment of considerable independence. The functional significance and potentialities of its apparently "closed unit" mural structure are further enhanced by the peculiarities of innervation which to our best knowledge are not present in any other vein or in the more copiously innervated arteries.

REFERENCES

1. AKERT, K., SANDRI, C.: (1968) An Electron-microscopic Study of Zinc Iodide-osmium Impregnation of Neurons. I. Staining of Synaptic Vesicles at Cholinergic Junctions. Brain Res. **7,** 286—295. — 2. ÁBRAHÁM, A.: Microscopic Innervation of the Heart and Blood Vessels in Vertebrates Including Man. Akadémiai Kiadó, Budapest, 1969. — 3. BRADLEY, S. E.: (1963) The Circulation in the Liver. Gastroenterology, **44,** 403—409. — 4. BRAUER, R. W.: (1963) Liver Circulation and Function. Physiol. Rev. **43,** 127—213. — 5. BUSCH, E.: (1929) Studies on the Nerves of the Blood Vessels with Especial Reference to Periarterial Sympathectomy. Acta path. microbiol. scand. Suppl. **2,** 1—186. — 6. CHAMPY, CH.: (1913) Granules substances réduisant l'iodure d'osmium. J. Anat. (Paris) **49,** 323—343. — 7. COUPLAND, R. E., HOLMES, R. L.: (1957) The Use of Cholinesterase Techniques for the Demonstration of Peripheral Nervous Structures. Quart. J. micr. Sci. **98,** 327—330. — 8. FALCK, B., HILLARP, N. A., THIEME, G., THORP, A.: (1962) Fluorescence of Catecholamines and Related Compounds Condensed with Formaldehyde. J. Histochem. Cytochem. **10,** 348—354. — 9. FISCHER, A., TAKÁTS, L., MOLNÁR, G.: (1960) Parallele Bestimmung des arteriellen und portalen Kreislaufs der Leber. Acta med. Acad. Sci. hung. **16,** 61—74. — 10. GLENNER, G., BURTNER, H. J., BROWN, G. W.: (1957) The Histochemical Demonstration of Monoamine Oxidase Activity by Tetrazolium Salts. J. Histochem. Cytochem. **5,** 591—600. — 11. HILLARP, N. A.: (1946) Structure of the Synapse and the Peripheral Innervation Apparatus of the Autonomic Nervous System. Acta anat. (Basel) **4,** Suppl. 1—153. — 12. HILLARP, N. A.: (1959) On the Histochemical Demonstration of Adrenergic Nerves with the Osmic Acid–sodium Iodide Technique. Acta anat. (Basel) **38,** 379—384. — 13. KISZELY, GY., BARKA, T.: Gyakorlati mikrotechnika és hisztokémia. Medicina, Budapest, 1958. — 14. KÖHN, K., RICHTER, M.: (1959) Gefäßveränderungen im extrahepatischen Pfortaderstromgebiet bei Leberzirrhosen. Acta hepato-splenol. **6,** 29—39. — 15. LUKAS, Z., CECH, S.: (1966) Adrenergic Nerve Fibers and Their Relation to Monoamine Oxidase Distribution in Ocular Tissues. Acta histochem. (Jena) **25,** 133—140. — 16. MOOTZ, W. O.: (1965) Lichtmikroskopische Untersuchungen zur Innervation der Pfortader der weißen Ratte. Z. mikr.-anat. Forsch. **73,** 462—505. — 17. MYERS, J. D.: (1950) The Hepatic Blood Flow in Laennec's Cirrhosis with an Estimate of the Relative Contributions from Portal Vein and Hepatic Artery. J. clin. Invest. **29,** 836—837. — 18. RADYMSKA-WAWRZYNIAK, K.: (1968) The Histochemical Activity of Monoamine Oxidase and Cholinesterase in Arterial and Venous Walls. Various Circulation Regions in Domestic Animals. Folia histochem. cytochem. **6,** 49—64. — 19. REICHMAN, S., DAVIS, W. D., STORAASLI, J. P., GORLIN, R.: (1958) Measurement of Hepatic Blood Flow by Indicator Dilution Technique. J. clin. Invest. **37,** 1848—1856. — 20.

Stöhr, Ph., Jr.: (1932) Mikroskopische Studien zur Innervation des Magen-Darm-Kanales. II. Z. Zellforsch. **16,** 123—197. — 21. Ungváry, Gy., Faller, J.: (1963) Die portobiliären Leberläppchen und das Glisson-System. Acta morph. Acad. Sci. hung. **12/2,** 189—200. — 22. Ungváry, G., Donáth, T.: (1969) On the Monoaminergic Innervation of the Liver. Acta anat. (Basel) **72,** 446—459.

DIE V. PORTAE ALS »SELBSTÄNDIGES« VENENSEGMENT
(Untersuchung der Wandstruktur und der Innervation)

G. UNGVÁRY, E. PETROVICS, CS. LÉRÁNTH und S. A. NASZÁLY

Die Wandstruktur der Pfortader von Meerschweinchen wurde mittels Färbung des Binde- und Muskelgewebes, ihre Innervation mit Hilfe von histochemischen Reaktionen [Azetylcholinesterase-Reaktion (AChE), Monoaminooxydase (MAO) Reaktion, Zinkjodosmium (ZnJOs) Verfahren nach Champy], ferner elektronenmikroskopisch untersucht und festgestellt, daß die innere zirkuläre Muskelschicht der Pfortader im mittleren Teil des Gefäßabschnitts in C-Form, bei ihrem Zusammenfluß und bei ihrer Abzweigung erster Ordnung zirkulär von einer längsgerichteten Muskelschicht umgeben ist.

AChE-positive präterminale Nervenbündel wurden nur in der Adventitia gefunden. Die intensivste MAO-Reaktion wurde in den längsgerichteten Muskelschichten erhalten. An der Grenze der Adventitia und Media finden sich monoaminerge Fasern, die ein dichtes Netzwerk bilden. ZnJOs-positive Fasern, sind in allen drei Schichten der Gefäßwand zugegen.

Im Elektronenmikroskop wurden sowohl in der Adventitia wie auch in der Media und der Intima mit Schwannschem Zellplasma bedeckte oder von Schwannschen Zellen freie Fasern nachgewiesen.

Aufgrund der Wandstruktur und der eigenartigen Innervation wird angenommen, daß die Pfortader ein selbständiges Venensegment darstellt.

ВОРОТНАЯ ВЕНА — „САМОСТОЯТЕЛЬНЫЙ" ВЕННЫЙ СЕГМЕНТ (ИЗУЧЕНИЕ СТРУКТУРЫ СОСУДИСТОЙ СТЕНКИ И ИННЕРВАЦИИ)

Д. УНГВАРИ, Е. ПЕТРОВИЧ, Ч. ЛЕРАНТ и Ш. А. НАСАЙ

Структура сосудистой стенки воротной вены морской свинки была изучена методами окрашивания соединительной и мышечной тканей, а ее иннервация — при помощи гистологических реакций (реакция с ацетилхолинэстеразой (АХЭ) с моноаминооксидазой (МАО), с цинкйодосмием (ZnJOs) по методу Champy), а также в электронном микроскопе. Было установлено, что внутренний кругообразный мышечный слой в средней части участка воротной вены окружен продольным мышечным слоем, в форме С, а у места ее слияния и у места ее разветвления первого порядка — кругообразно.

Ацетилхолинестеразо-положительные претерминальные нервные пучки были обнаружены только в адвентиции. Наиболее сильная реакция на МАО была получена в продольных мышечных слоях. На границе адвентиции и медии присутствуют моноаминергные волокна, образующие густую сеть. ZnJOs-положительные волокна обнаруживаются во всех трех слоях сосудистой стенки.

При помощи электронного микроскопа как в адвентиции, так и в среднем слое и в интиме, равным образом были выявлены волокна, покрытые плазмой Шванновских клеток, или волокна без Шванновских клеток.

На основе стркуры сосудистой стенки и своеобразной иннервации полагается, что воротная вена представляет собой самостоятельный венозный сегмент.

Dr. György Ungváry
Dr. Erzsébet Petrovics
Dr. Csaba Léránth
Dr. S. Attila Naszály

Anatómiai Intézet,
Budapest IX., Tűzoltó u. 58., Hungary

Acta Morphologica Acad. Sci. Hung. 19 (3), pp. 283—300, 1971

Institute of Histology and Embryology (Head: Prof. I. TÖRŐ), Semmelweis University Medical School, Budapest

ELECTRONMICROSCOPICAL CHANGES DUE TO HISTAMINE IN THE SKIN OF THE RAT

I. TÖRŐ and I. OLÁH

(Received May 27, 1971)

The endothelium of the histamine-rubbed skin behaves like the reticuloendothelial system. It stores colloidal carbon by means of endocytosis. A new endothelial lining replaces the site of the decaying endothelial cells in consequence of the flattening of the adjoining endothelial cells. At that point the basement membrane undergoes decay and a new one develops. The carbon granules arrive into the tissue partly through the intercellular gaps and partly through the endothelial cells. First, the pericytes take up the carbon from the endothelial cells with the help of endocytosis and detach from the vascular wall. The pericytes migrate and transform into tissue macrophages, later they disintegrate and the carbon passes into the tissue spaces by means of exocytosis. The granules are then taken up by another macrophage and carried farther. The cells performing endocytosis are rich in ribosomes and a lively membrane-flow is observable in them.

The present electron microscopic studies have supported the previous light microscopic findings, disclosing the details of the mechanism of the reaction caused by histamine. Histamine as tissue hormone mobilizes the reserve cells of the reticuloendothelial system and provokes the mechanism of a local sterile inflammation by the transformation and mobilization of the cells. In the endocytosis three variations of the vacuoles can be found; they display the different mechanisms of endocytosis.

Endocytosis is considered one of the most characteristic functions of the cells belonging to the reticuloendothelial (RE) system. This specific cell function manifests itself in the capacity of taking up foreign substances circulating in the blood by phagocytosis as well as storing them for a certain period and digesting them later. Especially well known is this capacity of those RE cells of the liver which line the sinusoids of this largest gland and enable it to depurate the blood in a few minutes by filtering out the foreign substances. Besides phagocytosis, the RE cells have further mechanisms for the uptake of different substances, such as simple pinocytosis [11] and vermiform phagopinocytosis [27].

Our experiments [25] have shown that colloidal carbon or silver particles taken up by the Kupffer cells may be evacuated in two directions. 1) They may reach the circulating blood with cells detached from the vascular wall; or 2) they may appear, in a short time, in the periportal interstices of the liver. Challenging questions are why only the endothelium lining the liver's sinusoids possesses this capacity lacking in the endothelium of most other blood vessels. In the case of skin injuries it can be observed that after the intravenous administration of colloidal carbon the skin bordering the wound turns black as

the endothelium of the blood vessels and capillaries of this skin area is storing, like the RES, the carbon taken up by the cells. Consequently, the endothelium of the capillaries and postcapillary veins of the skin are capable of endocytosis under certain circumstances. This tissue reaction may be due to substances released by the injured tissues.

JANCSÓ [13] observed that, after administering India ink intravenously to the rat, the histamine rubbed skin becomes black. Our light-microscopic studies showed that also in this case, in the same manner as in the liver, the carbon granules appear in the cells of the subcutaneous connective tissue. Since the light microscope failed to clarify convincingly the mechanism taking place [22, 23, 24], we have studied the process electron microscopically and shall now present the results obtained.

Materials and methods

In the experiments white rats weighing 130—150 g were used. The abdominal wall of the animals was depilated on the previous day and in ether anaesthesia its skin was painted with a 5% histamine solution and 1 ml of tenfold diluted fine granulated India ink was injected into the vein of the tail. The substances taken from the liver and from the blackened skin area were fixed for two hours in 4.5% buffered glutaraldehyde. Buffered rinsing was followed by 1% osmium tetroxide postfixation and subsequently the dehydrated material was embedded in Araldite, slices were cut with a Reichert OMN-2 apparatus or with a microtome, and studied under a JEM 6 C electron microscope.

Results

In the blood vessels, erythrocytes, sometimes leucocytes were found, usually surrounded by an inhomogeneous medium. At those sites where the vascular wall stored carbon in large quantities, thrombocytes were assembled (Fig. 1). At the points where the thrombocytes were attached to the surface the external coat covering the endothelium and the cell membrane were remarkably thickened.

Endothelium

On the surface of the endothelial cells, numerous microvilli can be found which protrude into the lumen as irregularly placed, shorter or longer cytoplasmic processes. The endothelium is usually protruding into the lumen

Fig. 1. In the lumen, side by side, attached to the vascular wall thrombocytes (Th). Under them two endothelial cells (En). The one endothelial cell under the thrombocytes is darker, the other lighter. The two endotheliel cells are connected with interlocked cell borders (Cj). In the endothelium adjoining the thrombocytes, many ribosomes are seen. The basal surface of the cell is rough, with microvilli on it. Desmosome (D) between two endothelial cells. The basement membrane (Bm) is loose and in certain places it disappears and there the extensions of the adjoining endothelial cells are visible. In the endothelium, carbon-containing phagosome (Ph). On the basement membrane of the cell, pinocytotic invaginations (Pv). Under the endothelium a pericyte (Pe) transformed into macrophage-containing phagosomes filled with India ink; on its abluminal surface a basement membrane is seen. In this pericyte many thick-walled pinocytotic vacuoles and around them a detached vesicle, representing exocytosis (Ec) appears ×21,000. The inset: India ink-filled phagosome in the endothelial cell, rising into the lumen of the vein and separated from the lumen by a thin cytoplasmic structure

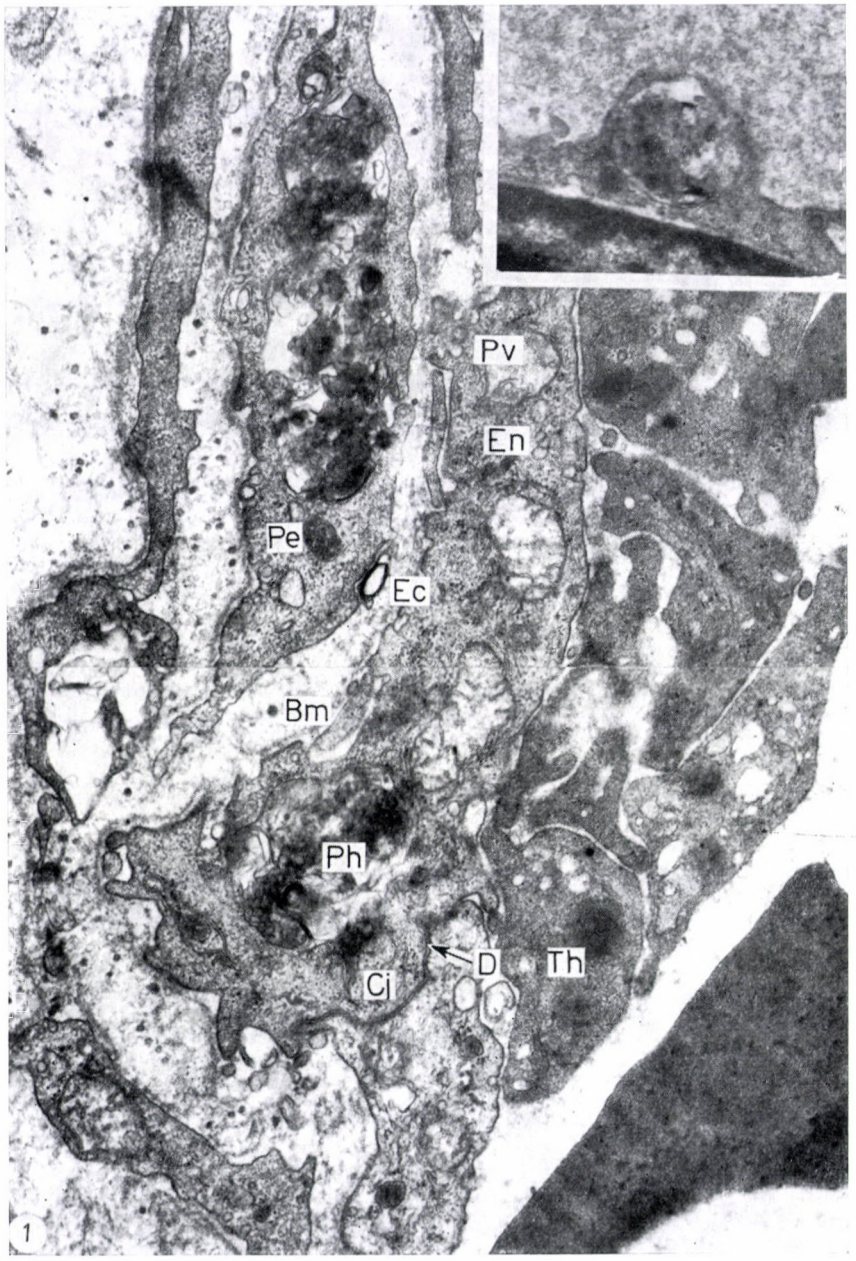
Pv
En
Pe
Ec
Bm
Ph
D
Th
Cj
1

showing here and there protuberances. The swelling is caused chiefly by empty or India ink filled phagosomes resulting from vigorous phagocytosis. Where phagosomes filled with India ink are found, the luminar wall of the swollen vacuoles becomes thin (inset), and numerous empty, dilated cisterns can be seen causing the swelling and a spongy structure of the endothelium (Fig. 2). The vacuoles communicate and they may later fuse form ing large cavities. Numerous pinocytotic vacuoles can be found on the luminar surface of the endothelium, though pinocytotic vacuoles can be seen also on the basal part of the endothelial cells. The endothelium is usually filled with such vacuoles which have, already at their formation (i.e. at the engulfment of the cell-membrane), electron dense granules attached to their outer surface; thus they can be characterized as thorny vacuoles. So-called coated vacuoles can also be found (Fig. 3), with an evenly thick wall which generally appears homogeneous. In the case of larger vacuoles of the same type, however, an electron dense stripe runs along the middle-line of the thick wall; this stripe is lacking at that place where the vacuole seems to open.

Consequently, three types of pinocytotic vacuole can be distinguished in the endothelium, viz. 1) the common pinocytotic vacuole having a thin wall and increasing more and more in size in the cytoplasm; 2) the thorny vacuole showing a gradual enlargement towards the centre of the cell; 3) the lined vacuole of unknown origin. The thorny vacuoles often open into enlarged pinocytotic vacuoles, though two thorny vacuoles may communicate with each other. The phagosomes in the endothelium filled with India ink may grow large and within them stored carbon, numerous membrane-like formations as well as their debris can be seen (Fig. 4). The smaller carbon granules are surrounded by an electron-dense cover. The content of the phagosomes is differing as to its quantity and structure. The endothelial cells which contain more phagosomes filled with India ink are richer in ribosomes and consequently much darker. In the endothelium, little endoplasmic reticulum can be observed. The desmosomes of the endothelial cells are distinct (Fig. 1), though the intercellular spaces are often dilated (Fig. 5), where well-characterized gaps can be found.

At sites where the endothelium contains numerous phagosomes and vacuoles, the basement membrane is loose and basal processes of the endothelial cells protrude through it (Fig. 6). At the sites of membrane defects,

Fig. 2. Protruding, riddle-like transformed endothelium (En), under it a disintegrating basement membrane (Bm) and layers of flattened cell lamelles, on their abluminal surface with basement membrane. ×15,500

Fig. 3. Endothelium (En) with smooth and thorny vacuoles, phagosomes (Ph). In several places a fusion of vacuoles is visible (arrows), sometimes like a string of pearls. The figure reminds of pinophagocytosis vermiformis (double arrow). On the endothelium's abluminal surface microvilli and exocytotic vacuoles. In the pericyte (Pe) under the endothelium a large phagosome as well as numerous pinocytotic vacuoles. ×2000

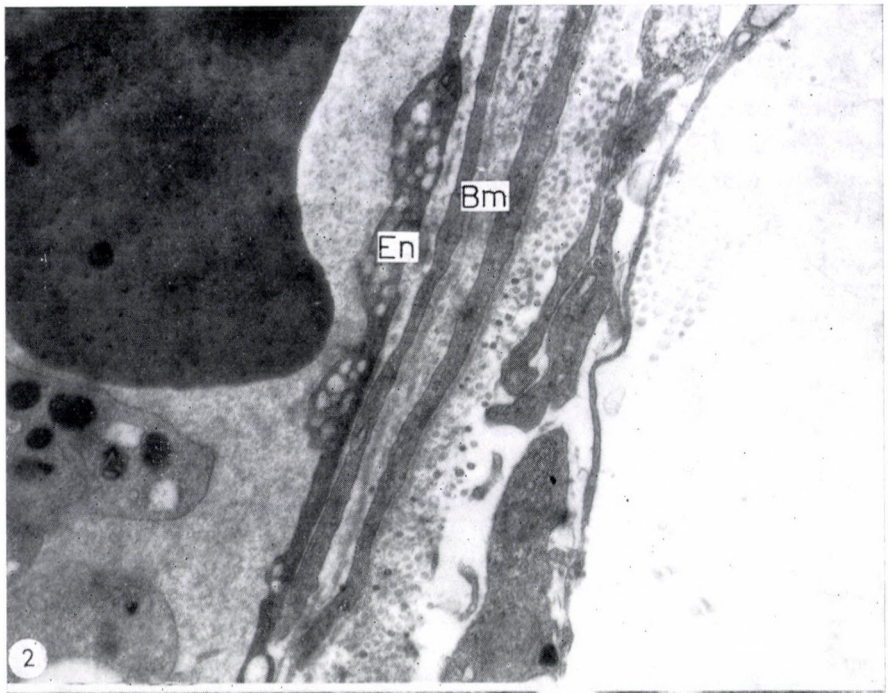
Bm
En
2

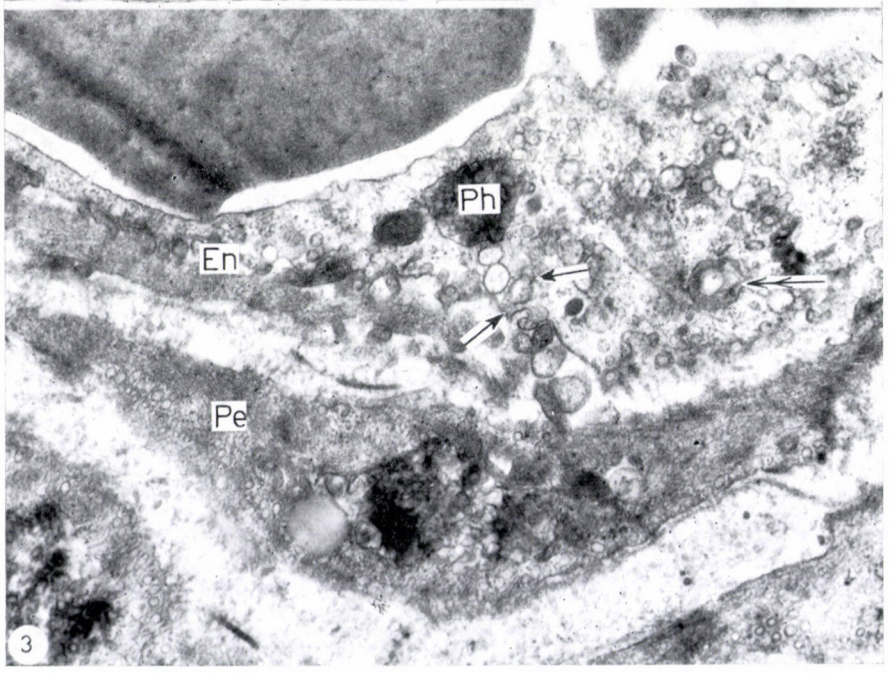
Ph
En
Pe
3

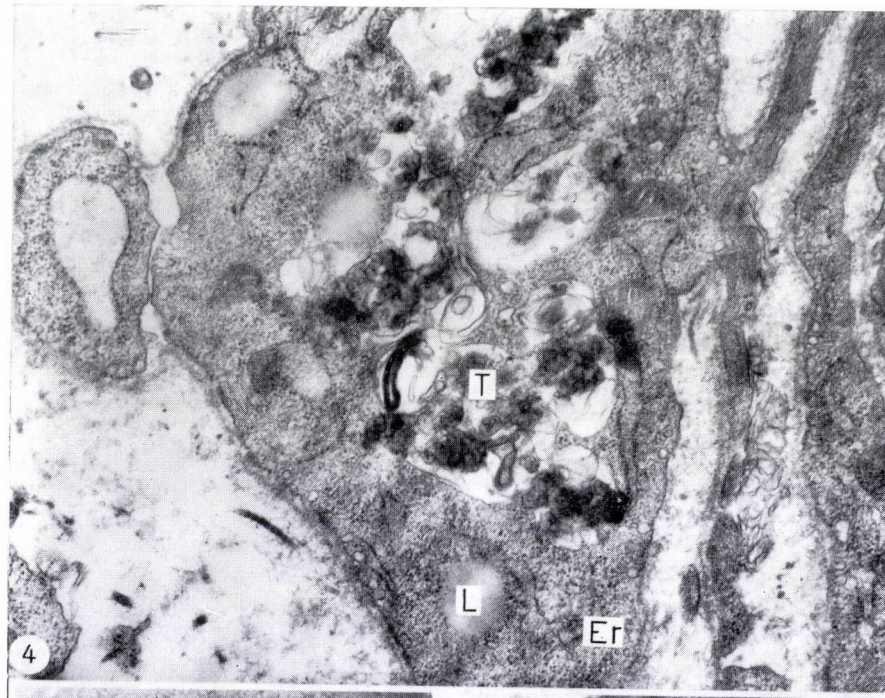
T
L
Er
4


En
En
5

collagen fibres appear. The membrane is incomplete also beneath the swollen endothelium having a sponge-like structure (Fig. 2). Here, similarly as on the luminar surface, the endothelium sends microvilli towards the pericytes and the spreading out of a new endothelium can be observed beneath the old one (Fig. 6). At certain points of the disintegrated basement membrane, the new endothelium is closely connected to the old one forming desmosomes with it (Fig. 8a). This new endothelial layer can be found at numerous places beneath the old endothelium. Under this secondary endothelial layer, a basement membrane is also found, moreover, the carbon-storing pericytes situated here have a more expressed basement membrane. In this way, the flattened endothelial cells show, at several places, a multilayered structure.

The new endothelium appearing under the generating old one is separated from the latter by an electron dense substance and under the new endothelial layer a new basement membrane develops.

Pericytes

After having stored more or less carbon within the phagosomes of the endothelium, the pericytes detach from the blood-vessel wall and appear in a rounded form (Figs 7a, b) having contracted their elongated bodies. As a consequence, the venous wall remains bare, being composed only by the endothelium and the basement membrane. The pinocytotic vacuoles of the pericytes too can be classified into three groups. There are enlarged vacuoles in the cell. The thorny vacuoles are more developed. We can find also the fusion of the thorny and the smooth vacuoles like in the endothelium (Figs 1 and 3). The pericytes detached from the vascular wall and the macrophages situated farther from the blood vessel are distinguishable only by their localization, the pericytes, like the macrophages, having numerous long processes as well as undulating membranes. Some of these tissue macrophages contain well-developed endoplasmic reticulum thus bearing resemblance to plasma cells (Fig. 9a). Owing to the dilated cisterns of the endoplasmic reticulum, their cell body shows a spongy structure (Fig. 9b). The macrophages also contain large phagosomes filled with carbon (Fig. 10). In both the pericytes and the macrophages, there are some homogeneous lipid droplets (Fig. 4). Some macrophages contain bodies of lamellar structure; between their concentrically arranged lamellae carbon granules can be observed (Fig. 10). This points to the phagosomal origin of these bodies.

Certain pericytes show a fine microfilamentar structure besides the large phagosomes containing India ink.

←

Fig. 4. Tissue macrophage containing phagosomes filled with Indian ink (T). Around the carbon granules an unoriented lamellar structure. Lipoids (L) sorrounded by ribosomes and dilated rough endoplasmic reticulum (Er) with granularly structured content. ×21,000

Fig. 5. Dilated intercellular space between two adjoining endothelial cells (arrows). Under the gap the flattened extension of the adjoining endothelial cell redoubles the endothelial layer (En) and closes the gap. ×11,400

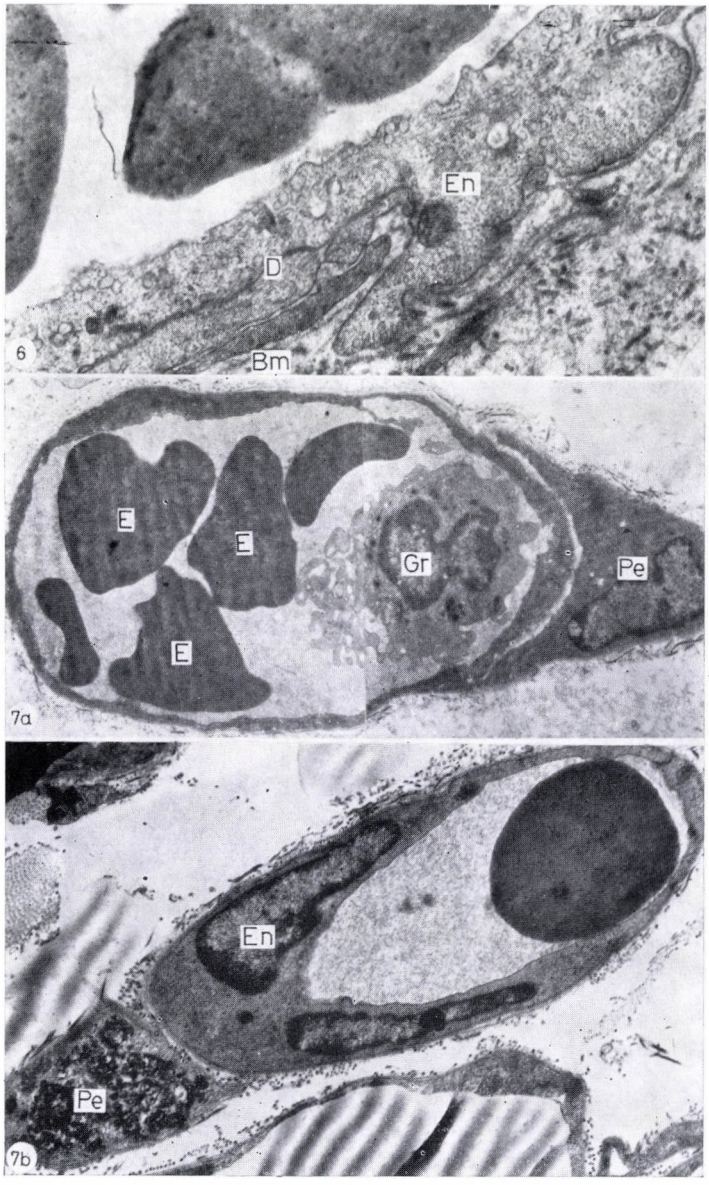

Fig. 6. At the site of the loosened basement membrane (Bm) extended endothelial cell (En), the endothelium seems to be in two or even in three layers. In the endothelium, fine fibrils. Occluding between the old and the new endothelium (D). ×19,000

Fig. 7a. A pericyte detaching from the vein-wall, contracting its body leaves the vascular wall bare. In the lumen, extended young leucocyte figures (Gr) and erythrocytes (E). ×13,000

Fig. 7b. The detaching pericyte (Pe) contains confluent phagosomes filled with carbon. En = endothelium. ×6,800

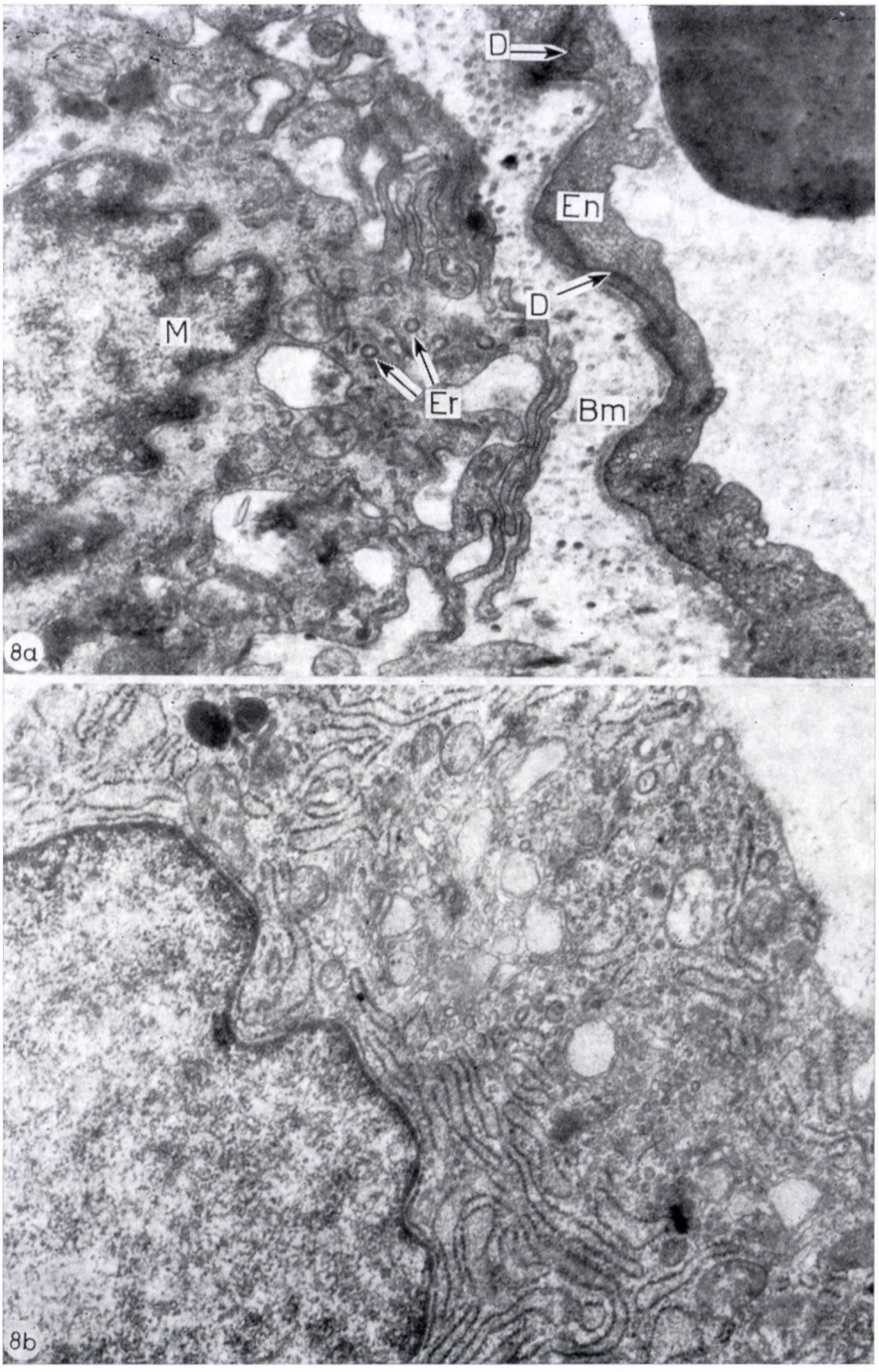

Fig. 8a. Desmosome between old and new endothelium (En). Here and there loosened basal membrane (Bm). Tissue macrophage (M) with numerous undulating membranes. India ink containing phagosomes and rough-surfaced endoplasmic reticulum (Er). ×8,000
Fig. 8b. Plasma cell containing rough-surfaced endoplasmic reticulum. ×18,200

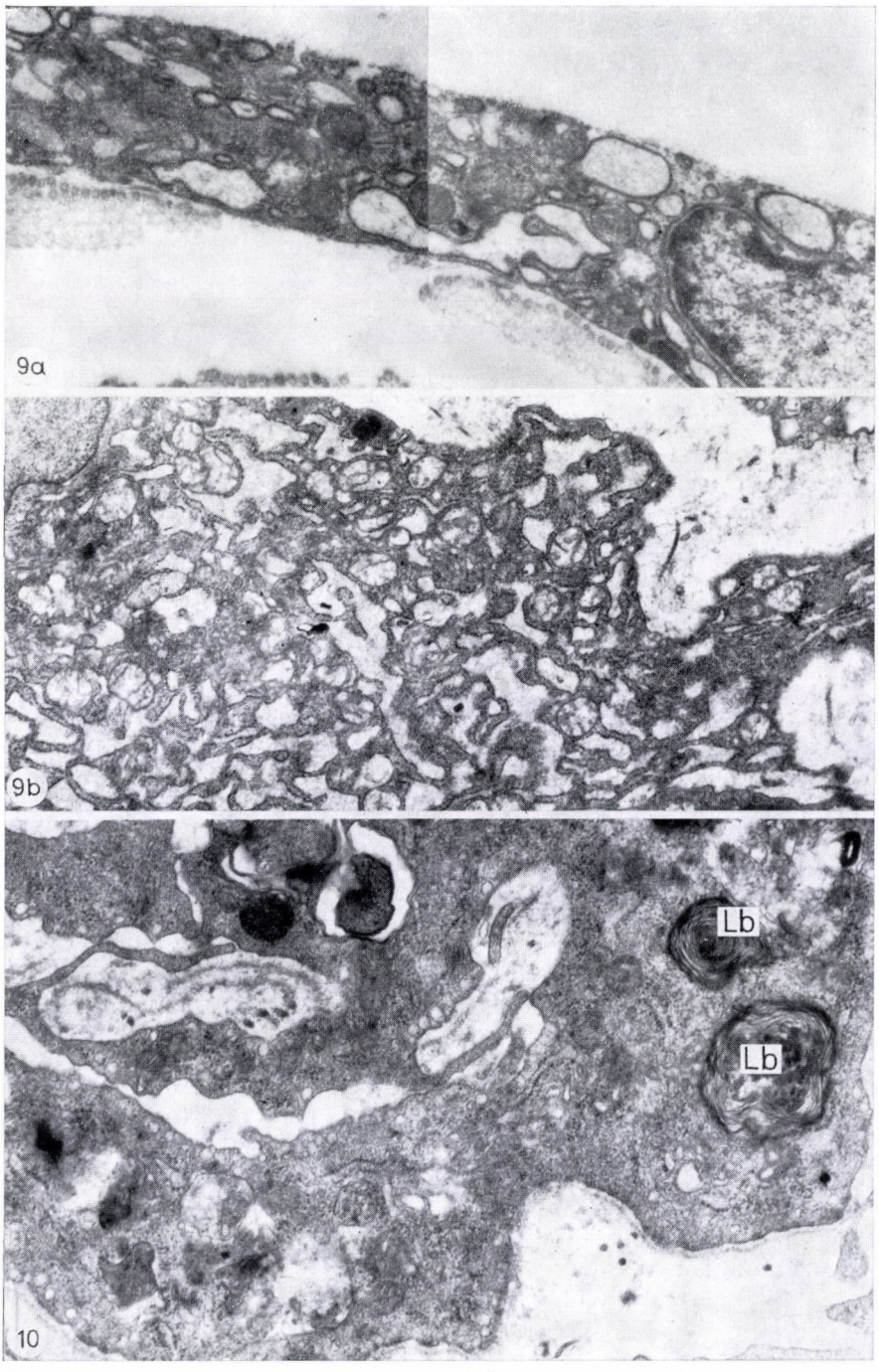

Fig. 9a Flattened tissue macrophage with dilated, rough-surfaced endoplasmic reticulum and coated vesiculum. ×13,000

Fig. 9b. Dilated endoplasmic reticulum, lending the cell a spongy structure. ×7,800

Fig. 10. Lamellar (Lb) bodies deriving from lysosomes, encysting and isolating the carbon granules in their interior. ×17,500

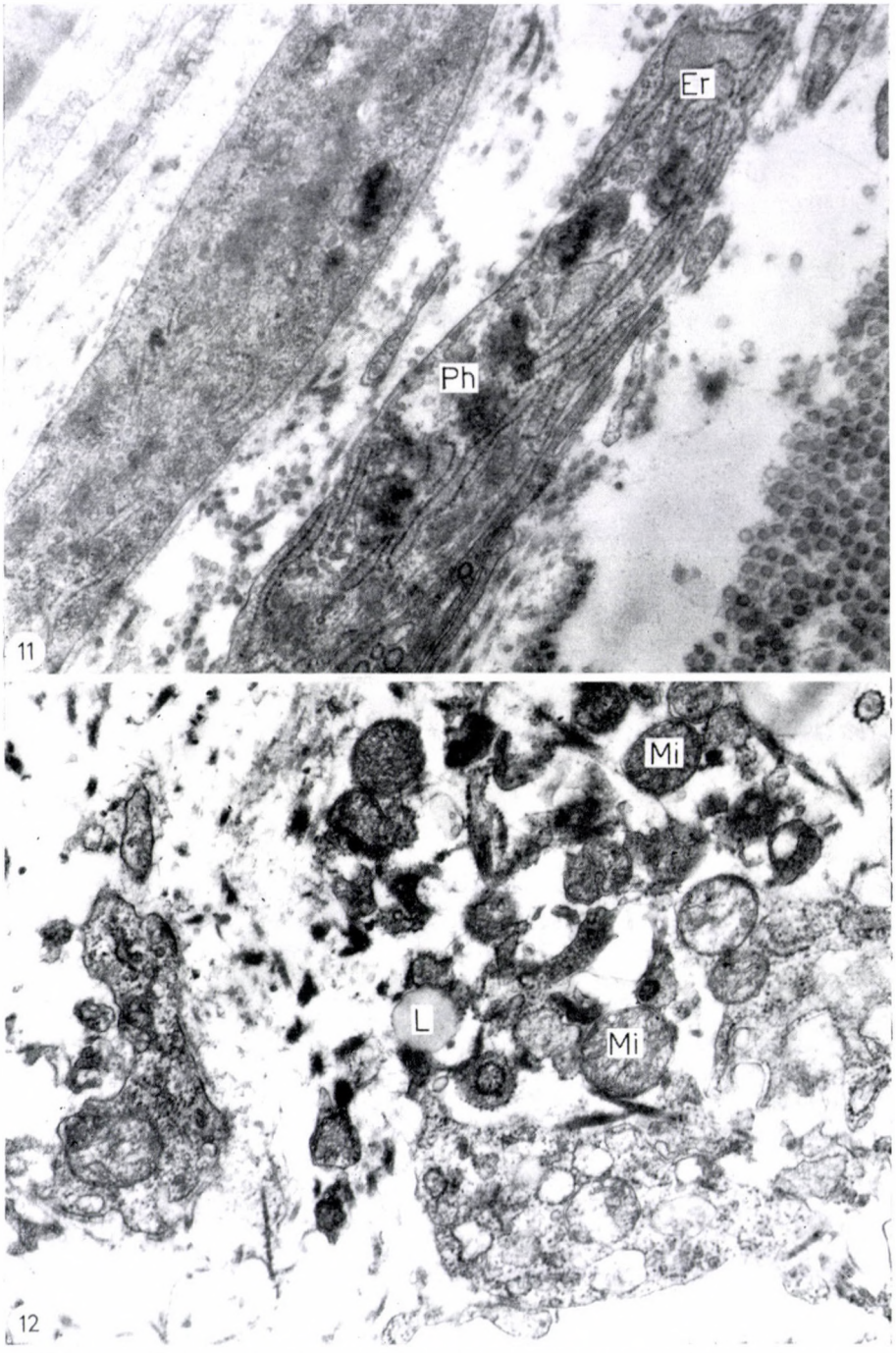

Fig. 11. Flattened tissue macrophages. In the interior of one macrophage, carbon-containing phagolysosomes and rough-surfaced parallel oriented endoplasmic reticulum with electron dense content. ×19,200

Fig. 12. The cell organelles escaped from disintegrated macrophages are phagocyted later by other macrophages. ×19,200

Macrophages

The macrophages are lying in a stratified structure and between the layers collagen fibrils can be seen. In the flattened cells both agranular and granular endoplasmic reticulum containing electron-dense substance is found, with lamellae arranged parallel to the cell surface (Fig. 11). The number of ribosomes and polysomes increases parallel with the number of phagosomes. The macrophages filled with carbon show degeneration. The numerous lipid droplets and mitochondria seen extracellularly originate from the disintegrated cells (Fig. 12), as also the few carbon granules of similar localization.

Discussion

A certain kind of vascular endothelium belongs to the reticuloendothelial system, lining the sinusoids of the liver and of the spleen. When different colloidal materials such as colloidal dyes, carbon, metals (e.g. silver, gold, iron, mercury sulphate, lead), thorium dioxide sol, etc. [1, 2, 6, 13, 16, 18, 24, 26] enter the circulation, these endothelial cells clear the blood from the foreign material. The endothelium of the blood vessels of other organs (e.g. muscles, skin) does not show phagocytosis, only pinocytosis. The endothelium of the liver sinusoids has been studied most thoroughly since its cells exert a conspicuous storing activity. It is not known why this activity is remarkable just in the liver and spleen and our knowledge is deficient also with regard to its regulatory control. According to Omosi [16] and Törő [24], the character of the reticuloendothelial system depends on that organ in which it is localized. If we examine the endothelium of a liver sinusoid directly after having administered India ink intravenously into it, in the intima cells we find carbon granules and if we follow their fate [13, 25], the carbon appears extra-sinusoidally in the Disse space and in the interstices of the periportal connective tissue where it accumulates forming rough clumps. The carbon as an undigestible material remains for several months in the cells and then sowly leaves the organ with the wandering cells, and passes into the circulation. The carbon can leave the liver in another manner too, when the Kupffer cells detach from the vascular wall and the circulation washes them away. This means that the carbon granules can arrive in other organs, chiefly in the lungs, through the circulation. The endothelium of the liver was examined by Parks [20] and Wisse [30]; among others Parks examined the sinusoid endothelium electron microscopically and found its structure to differ from that of the vascular endothelium. According to Wisse, the sinusoid endothelium of the liver is perforated at sites as a sieve and through its pores the lumen of the sinusoid communicates with the Disse space. On the other hand, the microvilli of the liver cells protrude into

the Disse space, they spread through the pores of the sieve even into the lumen of the sinusoid, or the processes of the Kupffer cells reach the microvilli of the parenchymal cells. Another characteristic of the sinusoid wall is that it is devoid of basement membrane and thus the substances may easily reach into the perisinusoidal space and the interstice. The capillaries of the skin and the subcutaneous connective tissue as well as the postcapillary veins have no sinusoid structure, and there is generally a basement membrane instead of the Disse space.

The passing of the substances through the lamellated barrier is not easily understood. Their permeability manifests itself only under certain effects. After the intravenous administration of India ink a blackening can be observed around the injuries caused by the shaving of the rat's abdominal skin. JANCSÓ found that, after having administered carbon intravenously, tightening of a grooved forceps resulted in persisting traces on the skin. This shows that some compounds, released by injured tissues, may enable the vascular endothelium to take up foreign colloidal substances. These observations then turned the interest in the first line to histamine (JANCSÓ [13]). The endothelium of the capillaries and of the postcapillary veins in the histamine rubbed skin region is capable of fixing India ink by increased endocytosis. Under the influence of histamine the endothelial cells became swollen, activated, they took up the carbon in phagosomes and showed increased pinocytosis. At the initial stage of pinocytosis, granules line up at the invagination of the cell membrane and the thus developing vesicle detaches as a thorny vacuole. After swelling more and more, the thorny vacuoles may expand to cisterns. In the sinusoid endothelium of the liver, WISSE too found thorny vacuoles. In the endothelial cells smooth vacuoles can be found originating probably from the endoplasmic reticulum and they, too, may expand further. The fusion of the two types of vacuole is necessary for the development of lysophagosomes [10, 21]. The development of lysosomes [5, 8, 9] was followed in tissue cultures where the phagolysosomes originate from the fusion of phagosomes and vesicles (primary lysosomes) developed in the Golgi apparatus, and the primary lysosomes release their enzymes into the phagosomes. The dilated vacuoles often fill the cytoplasm or the largest part of it. As a result of the swelling and vacuolization of the cells, the desmosomes open up and the intracellular gaps dilate, sometimes to a great extent.

Through the dilated intercellular passages in the endothelium the lumen of the vein communicates freely with the subendothelial tissue spaces, thus it may be supposed that the carbon granules can pass through the venous wall without having previously entered the cytoplasm of the endothelial cells. The endothelial cells contain numerous large clumps of India ink in phagosomes and with their help the carbon granules arrive into the perivascular connective tissue. The cytological effect of histamine starts here as an endocytotic wave,

spreading soon from the endothelium to the lower layers, first to the pericytes. They contract, draw back their bodies filled with India ink from around the vein and after rounding off, leave the veins bare. DUNN [4] injected carbon in the vas efferens of a dog's lymph node and studied with the electron microscope the carbon granules passing through the sinus endothelium. Also here the carbon granules passed by endocytosis into the endothelial cells, although the basement membrane is missing there.

Under the influence of histamine, at places the basement membrane becomes loose, disintegrates and disappears, especially where the endothelium shows a cribriform structure. Here under the old endothelium new flat cells appear — sometimes in several layers — tightly attached to the old one. The new layer corresponds to the flattened processes of the old, adjoining endothelial cells, and stretching under the effect of histamine a new endothelial layer develops below the old endothelium. Most probably the old endothelium becomes detached.

Parallel with the loosening of the basement membrane, the basal border of the endothelial cells is mobilized, microvilli develop on it, the cells become elongated and a double layer of endothelial cells develops. At the points which show the greatest change, thrombocytes accumulate in the lumen. These cells certainly play some part in the mechanism of endocytosis. Under the new endothelial layer a new basement membrane develops. According to VRACKO [29], the thickening of the basement membrane points to a decay or regeneration of the cells. In the regenerating capillary a secondary basement membrane develops giving support to the regenerating cells.

It may be supposed that the phenomenon appearing as pinocytosis at the basal part of the endothelial cells is identical with exocytosis, considering that several indentations with thorny membranes can be seen. During the period of investigation (20 hours) the carbon granules are already in large phagosomes and thus it would be necessary to examine also the initial period of the phenomenon. MILLS [15] found on the cell membrane of isolated Kupffer cells that the period of the dense cup-like invaginations was the initial period of the thorny vacuoles.

The thorny vacuoles develop from the detached cell membranes, while the smooth-walled vacuoles originate most probably from the endoplasmic reticulum. The Golgi apparatus being not sharply expressed, their Golgi-origin cannot be proved. Some carbon granules under the endothelium may be situated intercellularly, accordingly they arrive there by the fusion of the vacuoles with the cell membrane and later by their opening. This phenomenon can be observed on the basal and luminar surface equally. The carbon granules are incorporated in the pericytes and these after rounding off migrate farther transforming into tissue macrophages. These cells which only partly originate from the pericytes, containing large India ink-filled phagosomes as well,

develop the same vacuoles as the endothelium, and even in a more expressed form. The coated vacuoles in the macrophages remind strongly of the phagopinocytosis vermiformis [22, 27], being the sign of increased phagocytosis, a phenomenon described by us and later examined by others as micropinocytosis. This refers to the fact that this storage mechanism is not a characteristic feature of the Kupffer cells or of the lymphoid reticulum cells. In these cells the ergastoplasm increases intensely, chiefly in the form of rough surfaced endoplasmic reticulum. Polyribosomes can also be found. All these indicate an intense synthetic cellular activity which is most certainly in connection with enzyme production. The fact that in this case pinocytosis was not provoked by Indian ink permits the supposition that some kind of material plays a part here, necessary for the cell's metabolism. FRIEDRICH [7] found that after the removal of part of the RES, the remaining reticuloendothelial organs were storing more vigorously. A certain regulatory substance must be supposed in this cellular function. According to JEUNET [12] the serum contains a factor which plays this regulatory role [3, 18, 28], though the tissue fluid may contain it too and it may be supposed that the increasing pinocytosis serves just its uptake [11]. This is indicated by the fact that during prolonged storage the substance may become exhausted and storage may cease [12]. It is supposed that the thrombocytes take part in the production of the substance in question.

From the phagosomes filled with carbon clumps, lamellar bodies develop and encyst their undigestible contents. Many tissue macrophages containing carbon-filled phagosomes degenerate and disintegrate if they cannot get rid of the carbon; the phagosomes can stay for a long time in the cells as residual bodies and kill the cells. The thus expelled carbon granules are taken up by macrophages developed from histiocytes. They transport the granules migrating further and drawing more and more cells into the process. Histamine, apart from increasing endocytotis, starts also an increased cell mobilization, whereupon the tissue macrophages, situated farther from the storing blood vessel, take part in the clearing action. Under the effect of histamine, cell mobilization and transformation, endocytotic, and klasmacytotic processes, degeneration and regeneration equally play a part in the tissue reactions.

Histamine is constantly regulating the cell and tissue processes according to its liberated quantity. A sterile tissue inflammation may start under the effect of a quantity of histamine (cell disintegration). For the removal of foreign substances from the circulation, several cells may transform to assume the character of the reticuloendothelial system. Besides the endothelial cells, the thrombocytes, histiocytes, macrophages play a part in this process, and perhaps even the plasma cells originating from histiocyte.

The reticuloendothelial system has an active and an inactive part. From the latter so much is activated as is adequate for the intensity of the reaction elicited by the stimulus of the foreign substance to be removed.

The reticuloendothelial system is a dynamical one and cannot be circumscribed sharply. The endocytosis, influenced by the external coat, its structure and its electric charge, and also by the quality and structure of the stored substance, starts a plasma-membrane flow which leads to vacuolization and the formation of lysosomes. The plasma flow does not mean only the engulfment of the cell membrane but also the flow of the endoplasmic reticulum. In connection with this occurs the development of new cytomembranes, e.g. in the differentiation of plasma cells or in the development of lamellar bodies. The transport of the engulfed substance is hindered by the flattening of the cells, the lamellar adhesion of the flattened cells and by the new basement membrane at the site of the degenerated old ones. The membrane flow serves equally the pinocytosis and phagocytosis. It seems certain that histamine is not the only tissue hormone able to activate the resting part of the reticuloendothelial system but it also takes part in the control of the reticuloendothelial system's function.

Those factors which start the endocytosis on the cell membrane, start also the membrane flow which, by developing the endocytotic vacuoles, draws the foreign substance into the cell. The engulfment of the cell membrane, together with the reorganized endoplasmic reticulum, develops phagosomes, i.e. lysosomes. Parallel with these processes new cell membranes develop, isolating the foreign substances. The increased phagocytosis is followed by increased pinocytosis being in connection with the synthesis occurring in the cell, the synthesis of new lysosomal enzymes.

REFERENCES

1. Benecerаff, B. M., Sebestyén, M. B., Cooper, N. S.: (1959) The Clearance of Antigen Antibody Complexes from the Blood by the Reticuloendothelial System. J. Immunol. **82,** 131—137. — 2. Benecerаff, B. M., Bioni, G., Halpern, B. N., Stiffel, C.: (1957) Phagocytosis of Heat-denatured Human Serum Albumin Labelled with S^{131} and its Use as a Means of Investigating Level Blood Flow. Brit. J. exp. Path. **38,** 35—48. — 3. Cohn, Z.: The Maturation of the Mononuclear Phagocyte. Tissue Culture Ass. P. 41. 1968. — 4. Dunn, R., Bark, M. V., Ward, P. W.: (1958) Ultrastructural Evidence for the Lymph Node Venous Transport of Carbon Particles. J. Ultrastruct. Res. **30,** 170 and 249. — 5. deDuve, C.: In: Subcellar Particles. ed. Hayachi T. Ronald Press, New York. P. 128. — 6. Easton, Th. W.: (1952) The Role of Macrophage Movements in the Transport and Elimination of Intravenous Thorium Dioxide in Mice. Amer. J. Anat. **90,** 1—28. — 7. Friedrich, R.: (1967) Zur Strahlenschädigung des reticuloendothelialen Systems bei thymektomierten Mäusen. Strahlentherapie, **133,** 63—67. — 8. Gordon, A. H., Jaques, P.: Labelled Proteins. in: Tracer Studies. ed.: Donato L., H. G. Serchis. J. Brussels Euratom 2950 d. f, e. P. 27. — 9. Gordon, G. B., Miller, L. R., Bensch, K. G.: (1965) Studies on the Intracellular Digestive Processes in Mammalian Tissue Culture Cells. J. Cell Biol. **25,** 41—55. — 10. Hers, H. G., F. van Hoof: In: Lysosomes in Biology and Pathology. (ed. Dingle J. T. and Fell H. B. North Holland Publishing Co., Amsterdam. **2,** 1969. — 11. Holter, H.: (1959) Pynocytosis. Int. Rev. Cytol. **8,** 481—504. — 12. Jeunet, F. S., Shoemaker, W. J., Good, R. A.: (1967) Isolated Double Perfusion of the Liver in the Study of the Reticulo-endothelial System. Nature (Lond.) **215,** 61—62. — 13. Jancsó, N.: Speicherung. Akademischer Verlag, Budapest, 1955. — 14. Matter, A., Orci, L., Forymann, W. G., Rouiller, Ch.: (1968) Stereological Analysis of the Fine Structure of the Micropinocytosis Vermiformis in Kupffer Cells of the Rat. J. Ultrastruct. Res. **23,** 272—279. —

15. MILLS, D. M., ZUCKER, D., FRANKLIN: (1969) Electron Microscopic Study of Isolated Kupffer Cells. Amer. J. Path. **54,** 147—166. — 16. OMOSI, J.: (1954) Cytological Studies on the Reticulo Endothelial System. Acta med. biol. Jap. **2,** 439—456. — 17. ORCI, L., PICTET, R., ROUILLER, CH.: (1967) Image ultrastructurelle de pinocytose dans la cellule de Kupffer du foie de rat. J. Microscopie, **6,** 413—418. — 18. PARKS, H. E.: (1956) A Morphological Study of Phagocytosis by Endothelial Phagocytes Lining the Hepatic Sinusoids of the Mouse. Anat. Rec. **125,** 1—16. — 19. PARKS, H. E.: Observations on Early Stages of Phagocytosis of Colloidal Particles by Hepatic Phagocytes of the Mouse. Conference on Electron Microscopy, 1956. 2—7. — 20. PARKS, H. E.: The Hepatic Sinusodial Endothelial Cell and Its Histological Relationships. Conference on Electron Microscopy, 1956. — 21. PERKINS, W. D.: (1970) Macrophage. Anat. Rec. **166,** 361. — 22. RÖHLICH, P., TÖRŐ, I.: Uptake of Chylomicron Particles by Reticular Cells of Mesenterial Lymph Nodes of the Rat. Third Europ. Reg. Conf. on Electron Microscopy. Publ. House of the Czechoslovak Academy of Sciences, Prague, 1964. — 23. SEAMAN, A., MURRAY, S. M.: (1957) Observations on the Reticuloendothelial Elements of the Liver and Spleen of the Rat Following Injections of Gelatine-stabilized Gold Chloride. Acta Haemat. **17,** 42—50. — 24. TÖRŐ, I.: (1942) Histologische Untersuchungen über die Beziehungen zwischen reticuloendothelialem System und Histaminwirkung. Z. mikr.-anat. Forsch. **52,** 552—571. — 25. TÖRŐ, I.: (1943) Zur Frage der Funktion des Leberreticuloendothels. Z. mikr.-anat. Forsch. **54,** 333—351. — 26. TÖRŐ, I.: (1948) Die humorale Regulierung der Speicherung in der Leber. Acta anat. hung. **5,** 311—342. — 27. TÖRŐ, I., RÖHLICH, P.: (1962) Ultrastructure of Early Phagocytic Stages in Sinus Endothelial and Kupffer Cells of the Liver. Exp. Cell. Res. **26,** 601—603. — 28. TULLIS, J. L., SURGENOR, D. M.: (1956) Phagocytosis-promoting Factor of Plasma and Serum. Ann. N. Y. Acad. Sci. 386—390. — 29. VRACKO, R., BENDITT, E. P.: (1970) Capillary Basal Lamina Thickening. J. Cell Biol. **47,** 281—285. — 30. WISSE, E.: (1970) An electron Microscopic Study of the Fenestrated Endothelial Lining of Rat Liver Sinusoid. J. Ultrastruct. Res. **31,** 125—150.

ELEKTRONENMIKROSKOPISCHE VERÄNDERUNGEN VERURSACHT DURCH HISTAMIN IN DER HAUT VON RATTEN

I. TÖRŐ und I. OLÁH

Das Endothelium der Haut benimmt sich bei Histamineinreibung so wie das Retikuloendothelialsystem. Es speichert mittels der Endozytose kolloidale Kohle. Anstelle der absterbenden Endothelialzellen ist als Ergebnis der Verflachung der angeschlossenen Endothelialzellen eine Linierung sichtbar. An dieser Stelle geht die Basalmembrane zugrunde und es entsteht eine neue. Die Kohlenkörner dringen ins Gewebe teils durch die interzellularen Spalten, teils durch die Endothelialzellen. Zuerst wird die Kohle von den Endothelialzellen durch die Perizyten übernommen, welche sich von der Gefäßwand ablösen, später gehen sie zugrunde und die Kohle gelangt in die Gewebsspalten mittels Exozytose. Die Granula werden dann von anderen Makrophagen aufgenommen und weitertransportiert. Die der Endozytose unterworfenen Zellen sind reich an Ribosomen und in ihnen ist eine belebte Membranströmung zu beobachten.

Die neusten Untersuchungen mittels des Elektronenmikroskops bewiesen die Richtigkeit der früher mit Hilfe des optischen Mikroskops gemachten Feststellungen und klärten die Details des Mechanismus der durch Histamin verursachten Reaktion. Histamin, als Gewebshormon mobilisiert die Reservezellen des Retikuloendothelialsystems und verursacht eine sterile Entzündung bei der Veränderung und der Mobilisierung der Zellen. Bei der Endozytose können drei Varianten von Vakuolen festgestellt werden, was auf den verschiedenen Mechanismus der Exozytose hinweist.

ЭЛЕКТРОННОМИКРОСКОПИЧЕСКИЕ ИЗМЕНЕНИЯ, ВЫЗЫВАЕМЫЕ ГИСТАМИНОМ В КОЖЕ КРЫС

И. ТЁРЁ и И. ОЛАХ

Эндотелий кожи при втирании гистамина ведет себя как ретикулоэндотелиальная система. Он накопляет при помощи эндоцитоза коллоидальный уголь. На месте погибающих эндотелиальных клеток в результате уплощения прилегающих эндотелиальных клеток видна линейность. На этом месте базальная мембрана погибает и развивается новая. Зернышки угля проникают в ткань частично через межклеточные щели и отчасти через

эндотелиальные клетки. Первыми уголь от эндотелиальных клеток перенимают перициты и отслаиваются от сосудистой стенки. Перициты превращаются в макрофаги ткани и затем они разрушаются и уголь проникает при помощи экзоцитоза в щели ткани. Зернышки затем поглощаются другими макрофагами и переправляются. Эндоцитозные клетки богаты рибосомами, в них наблюдается оживленное мембранное течение.

Настоящие исследования при помощи электронного микроскопа подтвердили установления, сделанные перед этим при помощи оптического микроскопа, освещая детали механизма вызываемой гистамином реакции. Гистамин, как тканевой гормон, мобилизует запасные клетки ретикулоэндотелиальной системы и вызывает механизм стерильного воспаления при превращении и мобилизации клеток. При эндоцитозе могут быть обнаружены три варианты вакуолей, что показывает различный механизм эндоцитоза.

Dr. Imre Törő } Szövet-Fejlődéstani Intézet,
Dr. Imre Oláh } Budapest IX., Tűzoltó u. 58., Hungary

Acta Morphologica Acad. Sci. Hung. 19 (3), pp. 301—311, 1971

National Institute of Traumatology (Director: Dr. Gy. Szántó), Budapest

THE SUBMICROSCOPIC STRUCTURE OF CONNECTIVE TISSUE IN A CASE OF HUNTER'S SYNDROME

I. POLARISATION MICROSCOPIC EXAMINATIONS

L. Józsa

(Received February 7, 1970)

The submicroscopic structure of the connective tissues from a patient with Hunter's syndrome killed in an accident has been studied by polarisation microscopic methods. By the Rivanol and toluidine blue precipitation techniques the femoral bone, femoral cartilage, bronchial cartilage, mitral valve and skin were tested for acid mucopolysaccharide content and state of dissociation in the matrix. By aniline-Canada and acetylated aniline-Canada covering, the collagen structures, by the phenol binding reaction the collagen protein-mucopolysaccharide bonds were analysed.

These procedures revealed an increased mucopolysaccharide content of the connective tissues, as a result of an increase of some fractions present also normally and not due to a deposition of chondroitin sulphate B and heparan sulphate characteristic of Hunter's syndrome. In Hunter's syndrome the collagen composition is different from the normal, in the collagen structures the number of free hydroxyl groups (oxyamino acids) increases, as related to the peptide bonds. The collagen-mucopolysaccharide bonds are significantly different from these in the normal collagen structures.

On the basis of the results, it is assumed that the changes in the composition of the matrix and the pathological collagen structures represent one of the causes of the ossification disturbance observable in mucopolysaccharidosis.

The group of mucopolysaccharidoses increases day by day with newly discovered entities (Józsa, 1969). To date, there are at least 15 independent pathological conditions known, comprised previously under the heading gargoylism. The first disease of this kind was described in 1917 by Hunter and this condition is according to the present classification the Hunter syndrome or mucopolysaccharidosis II. Brante (1952) recognized that gargoylism was a disorder of mucopolysaccharide storage, with changes in the bones, liver, kidneys, brain and eyes as the leading symptoms. The submicroscopic and histochemical changes of the brain, nerves, liver and spleen are the best known; while less is known about the changes in bones, cartilages and connective tissue (Anderson 1962, Bona et al. 1966, Bona et al. 1967, Rask 1963). As it has been shown earlier (Józsa and Szabó 1969), the disturbance in hyaluronidase production is of great importance in mucopolysaccharidosis, preceding by far the appearance of clinical symptoms. The enzymopathy is genetically determined and is demonstrable not only in the patient, but also in the gene-carrier relatives. In addition to the disturbance in hyaluronidase production, several other enzymes are usually defective or show a low activity (Anderson 1962, Bona et al. 1966, Bona et al. 1967).

The increased production of mucopolysaccharides and the deficiency or defective activity of the lytic enzyme system lead are damaging not only the ground substance of connective tissue, but also the fibre system. These changes are still unclear and their elucidation is rendered difficult by the fact that mucopolysaccharidosis or its model could not yet be induced in animals.

Materials and methods

The individual studied was an oligophrenic male, aged 32 years, a social care case. He died at our Institute 4 hours after a tram accident. At necropsy, multiple bone injuries and destruction of brain tissue were found. The 125 cm disproportionate dwarf exhibited postmortem evidence of osseous and organic changes characteristic of Hunter's syndrome. The urine obtained from the cadaver contained mucopolysaccharide at a concentration of 147 mg/l, of which 36 mg/l was heparan sulphate and 111 mg/l chondroitin sulphate B. The diagnosis of Hunter's syndrome was supported by radiological, postmortem and histological evidence and by the urinary mucopolysaccharide finding.

Specimens of femoral head cartilage, femoral bone, rib cartilage, rib bone, parietal bone, tracheal and bronchial cartilage and mitral valve were subjected to histological study. Bones were decalcified with acid, then cryostat serial sections were cut from every organ. In addition to the routine staining methods, for polarisation microscopy the following methods were used:

1. Covering with Canada balsam;
2. Covering with 50% aniline-Canada;
3. After acetylation (with pyridine control), covering with 50% aniline-Canada;
4. Rivanol test (Romhányi 1962);
5. Toluidine blue precipitation staining in the pH range of 2.4 to 7.4, according to Romhányi;
6. Serial covering with 1 to 10% phenol-xylol.

Birefringence was determined partly by a commercial compensator, partly by a home made one, checked and declared suitable by the Institute of Pathology, University Medical School of Pécs. Tissues from a healthy male of similar age, killed in an accident, were used as controls.

The histochemical, biochemical and electron microscopic, electron microscopic histochemical findings will be described in another paper.

Results

The Rivanol test gives an anisotropic reaction in a proportion corresponding to the acid components of the ground substance and allows conclusions concerning the quantity of acid mucopolysaccharide components as well as the number of acid (sulphate) groups. According to the Rivanol test in every cartilage examined the acid components were present at a higher relative concentration than in the normal control. The increased Rivanol anisotropism of the skin, heart valve and bone ground substance indicated an increase of acid mucopolysaccharides (Table 1).

The Rivanol test allows but a rough estimate of the relative concentrations of the acid components, while toluidine blue anisotropic staining supplies information also as to the quality and state of dissociation of the mucopolysaccharide molecules. According to the results of toluidine blue anisotropic

staining in the pH range of 2.4 to 7.4 the number of the sulphate radicals of the matrix was increased in every tissue. The increase of acid mucopolysaccharide content was especially marked in the femoral and costal bone, as well as in the heart valve. Mucopolysaccharide concentration was increased also in the respiratory tract cartilage, femoral head and costal cartilage, but the difference between the Hunter syndrome patient and the normal control was not so conspicuous as it was in the case of the bone matrix and the heart valve (Figs 1—9).

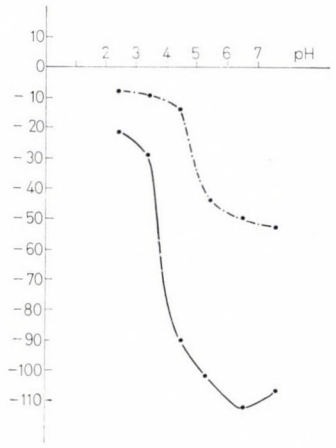

Fig. 1. Toluidine blue precipitation reaction. Femoral bone matrix. (Broken line: control. Solid line: Hunter's syndrome)

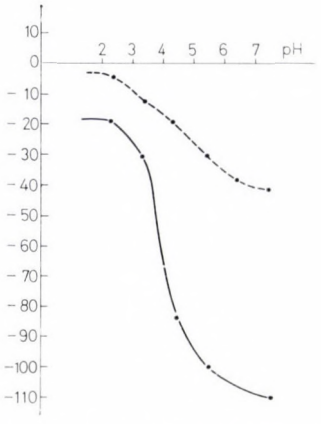

Fig. 2. Toluidine blue precipitation reaction. Costal bone matrix. (Broken line: control. Solid line: Hunter's syndrome)

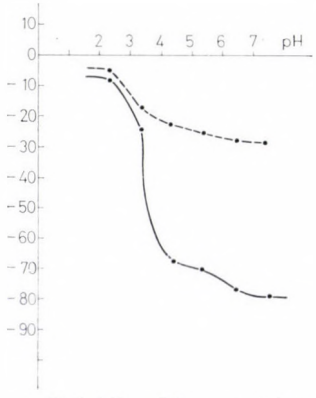

Fig. 3. Toluidine blue precipitation reaction. Parietal bone matrix. (Broken line: control. Solid line: Hunter's syndrome)

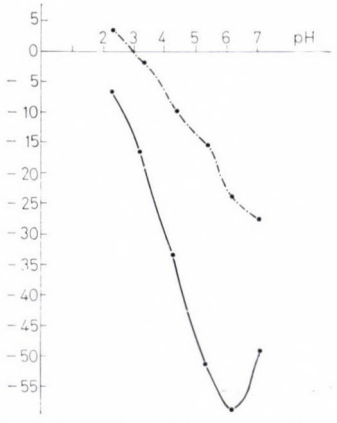

Fig. 4. Toluidine blue precipitation reaction. Bicuspid valve. (Broken line: control. Solid line: Hunter's syndrome)

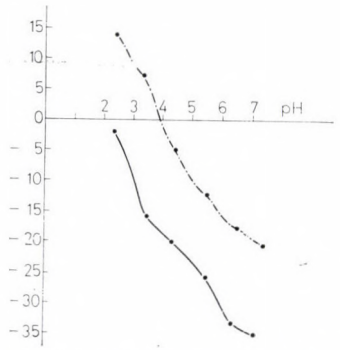

Fig. 5. Toluidine blue precipitation reaction. Skin of abdominal wall. (Broken line: control. Solid line: Hunter's syndrome)

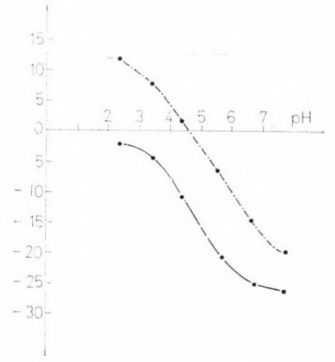

Fig. 6. Toluidine blue precipitation reaction. Bronchial cartilage. (Broken line: control. Solid line: Hunter's syndrome)

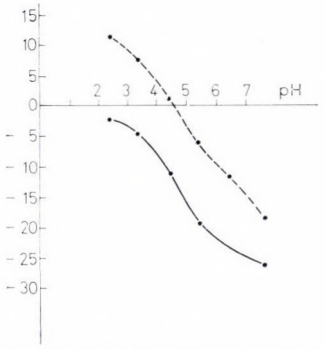

Fig. 7. Toluidine blue precipitation reaction. Tracheal cartilage. (Broken line: control. Solid line: Hunter's syndrome)

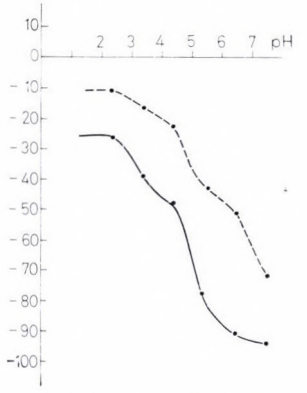

Fig. 8. Toluidine blue precipitation reaction. Femoral head cartilage. (Broken line: control. Solid line: Hunter's syndrome)

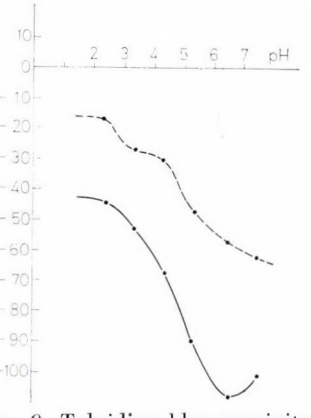

Fig. 9. Toluidine blue precipitation reaction. Costal cartilage. (Broken line: control. Solid line: Hunter's syndrome)

Table 1

Increase of acid mucopolysaccharides following of the increased Rivanol anisotropism

		Phenol-Canada	Aniline-Canada	Acetylated aniline-Canada	Rivanol
Bronchus	Hunter	−29.2	+ 9.4	−13.2	−17.3
	Control	−51.0	+ 6.5	+20.1	− 6.8
Trachea	Hunter	−24.0	+10.2	−11.7	−19.2
	Control	−63.2	+ 5.9	+16.3	− 8.0
Femoral cartilage	Hunter	−26.3	+13.8	−9.7	−16.5
	Control	−67.1	+12.0	−24.1	−10.5
Femoral bone	Hunter	−20.5	+18.7	−14.3	−13.8
	Control	−62.3	+16.5	−25.2	−10.2
Costal cartilage	Hunter	−12.5	+16.5	−10.8	−18.0
	Control	−51.0	+12.2	−18.1	− 7.9
Costal bone	Hunter	−17.5	+15.2	−12.7	−15.1
	Control	−47.9	+13.0	−22.7	−10.3

These findings showed that the deposition of mucopolysaccharides is not restricted to the parenchymal organs as it was suggested earlier, but is demonstrable in the mesenchymal tissues, too. The leading symptoms of Hunter's syndrome were thought to be an increase in heparan sulphate and chondroitin sulphate B. According to data in the literature (MEYER et al. 1959), these fractions are in fact deposited in the liver, kidney and brain, but not only these two fractions are overproduced (JÓZSA 1968). In the ground substance of cartilage and bone there is neither heparan sulphate nor chondroitin sulphate B, yet the mucopolysaccharide content of the matrix is increased. According to our histochemical and microchemical investigations, the case was not one of the appearance or increase in the matrix of cartilage and bone of the fractions characteristic of Hunter's syndrome, i.e. chondroitin sulphate B and heparan sulphate, but of an increase of chondroitin sulphate A and keratosulphate, thus of fractions present also normally.

The mucopolysaccharides accumulating in cartilage and bone matrix were linked to protein in an unusual fashion, but we have been unable to approach the different type of linkage by polarisation microscopy. The disturbance of the mucopolysaccharide-protein complex was indicated by the fact that the protein bond was alkali resistant and that the degree of toluidine blue anisotropism did not change following treatment with proteolytic agents (pepsin, trypsin, papain).

The aniline and the phenol binding reactions permit insight into the quality of the collagen-polysaccharide bond. The role played by chondroitin sulphate in the formation of collagen fibres is known (NÉMETH-CSÓKA 1960).

Table 2

Toluidine blue anisotropic precipitation reaction

		pH 2.4	pH 3.4	pH 4.4	pH 5.4	pH 6.4	pH 7.4
Trachea	Hunter	− 2.7	− 4.8	−11.0	− 19.2	− 24.0	− 26.3
	Control	+11.0	+ 7.3	+ 1.0	− 5.4	− 12.3	− 19.1
Bronchus	Hunter	− 3.8	− 5.6	−12.0	− 19.7	− 26.0	− 27.5
	Control	+ 9.1	+ 4.8	+ 0.5	− 5.0	− 14.0	− 16.2
Skin	Hunter	− 2.5	−17.2	−21.0	− 26.6	− 34.2	− 36.1
	Control	+13.9	+ 6.1	− 5.4	− 12.7	− 19.0	− 21.3
Mitral valve	Hunter	− 6.8	−17.5	−33.9	− 51.0	− 60.3	− 55.0
	Control	+ 2.9	− 0.5	− 9.0	− 14.8	− 24.0	− 36.2
Femoral cartilage	Hunter	−27.0	−39.8	−48.5	− 79.0	− 92.2	− 96.5
	Control	−11.0	−17.2	−23.0	− 44.1	− 52.2	− 73.0
Costal cartilage	Hunter	−44.0	−53.5	−67.9	− 90.0	−109.0	−101.0
	Control	−16.3	−27.0	−30.3	− 47.0	− 56.5	− 62.0
Femoral bone	Hunter	−21.0	−29.5	−90.4	−103.0	−112.0	−108.3
	Control	− 6.7	− 9.2	−13.5	− 14.1	− 50.2	− 73.0
Costal bone	Hunter	−19.5	−30.0	−84.0	−103.5	−112.0	−110.0
	Control	− 3.3	−12.0	−19.6	− 30.0	− 39.6	− 42.0
Parietal bone	Hunter	− 6.8	−24.0	−67.0	− 70.5	− 76.3	− 79.0
	Control	− 5.0	−17.2	−23.0	− 26.2	− 28.5	− 29.9

The process of collagen fibre formation, the chemical and submicroscopic structure may vary in diseases (VERZÁR 1963, VISZLÓY and KASZA 1967) and experimentally induced pathological conditions (NÉMETH–CSÓKA and VISZLÓY 1960, MARTIN et al. 1961). We have no data concerning the submicroscopic and chemical structure of the collagen fibre system of patients with gargoylism. With aniline cover a positive distance difference was found in every tissue examined, suggesting that there were no gross structural changes on the collagen fibres. The negative change in birefringence following acetylation indicates the quantity of -OH groups related to peptide bonds. In our case the change in birefringence following acetylation was more marked in the tissues of the Hunter syndrome patient than in the controls, from which it may be concluded that in the main collagen chain the number of hydroxyl groups per peptide bonds was higher than in the normal collagen structures.

Since not only the acid mucopolysaccharide ground substance, but also the chemical structure of the collagen protein were different from the normal, it seemed interesting to study the salt-like bonds between collagen protein and

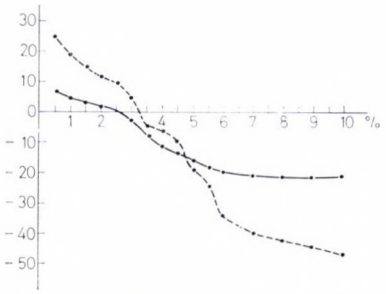

Fig. 10. Phenol binding reaction. Abdominal skin. (Broken line: control. Solid line: Hunter's syndrome)

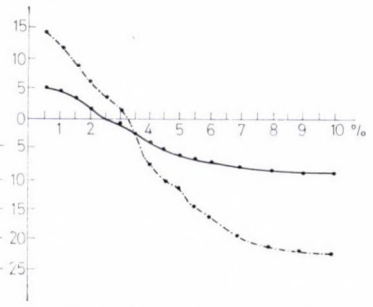

Fig. 11. Phenol binding reaction. Mitral valve. (Broken line: control. Solid line: Hunter's syndrome)

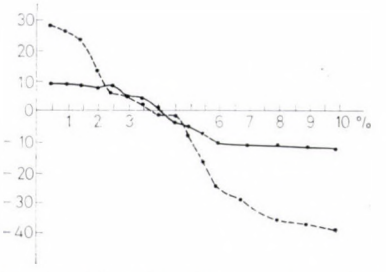

Fig. 12. Phenol binding reaction. Costal bone matrix. (Broken line: control. Solid line: Hunter's syndrome)

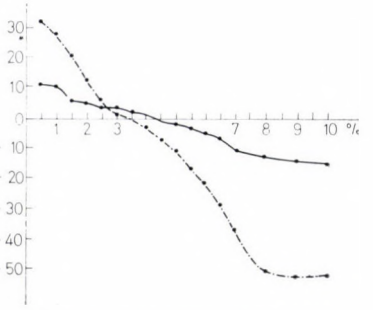

Fig. 13. Phenol binding reaction. Femoral bone matrix. (Broken line: control. Solid line: Hunter's snydrome)

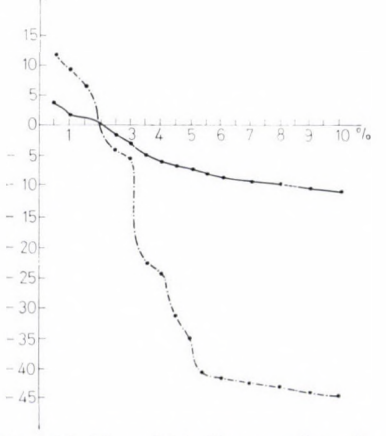

Fig. 14. Phenol binding reaction. Costal cartilage. (Broken line: control. Solid line: Hunter's syndrome)

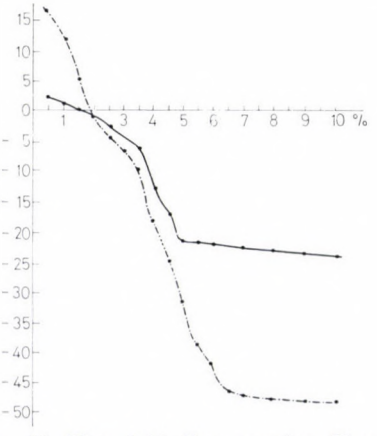

Fig. 15. Phenol binding reaction. Femoral head cartilage. (Broken line: control. Solid line: Hunter's syndrome)

Table 3

Phenol binding

Organ	Phenol per cent	0.5	1.0	1.5	2.0	2.5	3.0	3.5
Bronchus	Hunter	+ 2.1	+ 0.5	0.0	0.0	— 2.3	— 5.7	—12.0
	Control	+13.8	+10.5	+ 5.4	0.0	— 5.2	—13.0	—18.6
Trachea	Hunter	+ 2.9	+ 0.5	0.0	— 0.05	— 1.8	— 2.7	— 8.0
	Control	+14.0	+11.2	+ 6.4	0.0	— 4.5	—11.0	—16.0
Femoral cartilage	Hunter	+ 1.8	+ 0.7	0.0	— 0.05	— 2.4	— 2.8	— 6.3
	Control	+17.2	+12.0	+ 5.3	0.0	— 3.6	— 6.2	— 9.5
Femoral bone	Hunter	+11.3	+10.8	+ 6.5	+ 6.0	+ 4.7	+ 3.0	+ 2.1
	Control	+33.0	+28.0	—27.0	+21.5	+15.0	+ 5.5	+ 1.0
Costal cartilage	Hunter	+ 3.8	+ 1.7	+ 0.5	0.0	— 2.7	— 3.5	— 5.6
	Control	+12.1	+10.0	+ 6.5	0.0	— 4.2	— 5.2	—22.0
Costal bone	Hunter	+10.2	+ 9.6	+ 9.0	+ 8.4	+ 6.3	+ 5.5	+ 3.2
	Control	+29.0	+26.2	+24.0	+23.0	+10.7	+ 8.0	+ 5.0
Skin bone	Hunter	+ 3.8	+ 2.7	+ 1.2	+ 0.5	0.0	— 1.5	— 3.7
	Control	+13.0	+10.0	+ 8.0	+ 6.0	+ 5.0	+ 2.5	— 2.0
Heart valve	Hunter	+ 5.0	+ 3.8	+ 2.7	+ 1.2	+ 0.5	0.0	— 2.1
	Control	+14.0	+12.0	+ 8.6	+ 6.0	+ 3.0	+ 1.5	— 2.0

mucopolysaccharide. Ebner's phenol reaction is suitable for use in such investigations, because the higher the number of the acid side radicals of the mucopolysaccharide, the less phenol is bound by the tissue tested. The collagen structures of the tissues tested were not uniform, inasmuch as the phenol

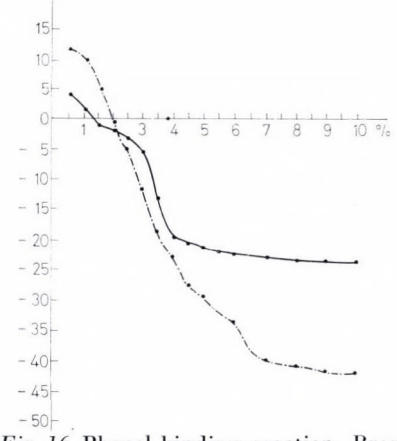

Fig. 16. Phenol binding reaction. Bronchial cartilage. (Broken line. control. Solid line: Hunter's syndrome)

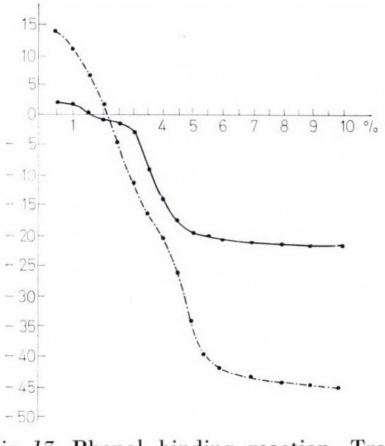

Fig. 17. Phenol binding reaction. Tracheal cartilage. (Broken line: control. Solid line: Hunter's syndrome)

reaction

.0	4.5	5.0	5.5	6.0	6 5	7.0	7.5	8.0	10.0
—19.3	—20.7	—21.0	—21.2	—21.5	—22.0	—22.2	—22.6	—23.0	—23.4
—22.3	—27.5	—29.0	—32.0	—33.5	—40.0	—40.2	—40.8	—41.0	—43.3
—14.0	—17.2	—19.0	—19.2	—20.0	—20.3	—20.5	—20.5	—20.5	—21.0
—19.5	—26.0	—34.0	—39.0	—42.0	—43.0	—42.7	—43.0	—44.0	—46.0
—13.4	—17.5	—21.5	—21.5	—21.6	—22.0	—22.2	—22.5	—22.8	—23.0
—17.2	—24.5	—21.0	—38.2	—42.6	—46.0	—47.0	—47.2	—47.8	—48.0
+ 1.0	0.0	— 2.5	— 2.9	— 8.0	—11.0	—11.5	—12.0	—11.0	—12.0
0.0	— 3.0	— 7.0	—10.0	—17.0	—21.0	—29.0	—36.0	—44.0	—51.0
— 6.3	— 6.7	— 7.2	— 7.8	— 8.5	— 8.5	— 9.0	— 9.5	—10.0	—11.0
—24.0	—32.5	—34.0	—41.3	—42.0	—42.6	—43.5	—43.5	—44.0	—44.5
+ 1.5	0.0	— 3.9	— 5.0	— 8.3	—11.0	—11.0	—11.5	—11.5	—12.0
+ 2.0	0.0	— 2.0	— 8.0	—17.0	—24.0	—29.0	—31.0	—35.0	—39.0
— 6.3	— 7.0	— 8.5	— 9.5	—10.0	—10.5	—10.5	—10.5	—11.0	—11.0
— 3.0	— 5.0	— 9.5	—12.0	—18.0	—19.5	—20.0	—21.0	—21.5	—23.5
— 3.7	— 5.0	— 6.3	— 7.0	— 7.5	— 7.9	— 8.2	— 8.4	— 8.8	— 9.0
— 7.4	— 9.4	—11.5	—14.0	—16.3	—18.0	—19.0	—20.0	—21.0	—22.0

binding capacity was markedly reduced in skin, heart valve, rib cartilage, rib and femoral bone matrix, while its reduction in the other tissues was found to be less marked (Figs 10 to 17, Table 3).

The methods of connective tissue staining showed no substantial differences in the connective tissues, or the differences found were comparable (PAS reaction) to data in the literature, therefore no details are presented here.

Conclusions

In a case of Hunter's syndrome an increase in mucopolysaccharides could be demonstrated not only in the internal organs, but also in the connective tissues. In every tissue tested the acid mucopolysaccharide content of the matrix was increased, but the degree of accumulation varied from tissue to tissue. The Rivanol reaction and also toluidine blue anisotropic staining revealed a most marked increase of mucopolysaccharides in the heart valves, and the femoral and costal bone matrix. There was a moderate increase of mucopolysaccharides in parietal bone, femoral cartilage and respiratory tract cartilage.

According to the acetylated aniline reaction, the chemical structure of the fibrogenic collagen protein was so changed that in the collagen structures the number of free hydroxyl groups (those disappearing on acetylation) increased, as related to the peptide bonds. This suggests that the collagen of gargoylism patients contains more oxyamino acids (serine, threonine, hydroxyproline) than the normal collagen.

It is explained partly by the change in the composition of the matrix and partly by the difference from the normal of the amino acid composition of the collagen protein that in the supportive tissues of patients with Hunter's syndrome the mucopolysaccharide-collagen bonds are differing from the normal.

REFERENCES

1. ANDERSON, C. E., CRANE, J. T., HARPER, H. A., HUNTER, T. W.: (1962) Morquio's Disease and Dysplasia Epiphysealis Multiplex. (Study of Epiphyseal Cartilage in Seven Cases.) J. Bone J. Surg. **44A**, 295—306. — 2. BONA, C., STANESCU, V., STREJA, D., IONESCU, V.: (1966) Histochemical and Histoenzymological Study of Tibial Growing Cartilage in Hurler's Syndrome. Acta histochem. (Jena) **23,** 231—248. — 3. BONA, C., STANESCU, V., STREJA, D.: (1967) Differential Regional Distribution of Mucopolysaccharides in the Human Epiphyseal Cartilage Matrix in Normal and Pathologic Conditions. Virchows Arch. path. Anat. **342,** 274—281. — 4. BRANTE, G.: (1952) Gargoylism — a Mucopolysaccharidosis. Scand. J. clin. Lab. Invest. **4,** 43—46. — 5. HUNTER, C.: (1917) A Rare Disease in Two Brothers. Proc. roy. Soc. Med. **10,** 104—109. — 6. JÓZSA, L.: (1968) A mucopolysaccharidosisok laboratoriumi és kórbonctani diagnosztikája. Orvosképzés **43,** 386—399. — 7. JÓZSA, L., SZABÓ, L.: (1969) Urinary Hyaluronidase Activity in Mucopolysaccharidosis. Acta paediat. Acad. Sci. hung. **10,** 73—78. — 8. JÓZSA, L.: Mucopolysaccharidosis. in: Orvosi Lexikon. Ed.: S. Hollán. Vol. II. Akadémiai Kiadó, Budapest, 1969. — 9. MARTIN, G. R., GROSS, I., PIEZ, K., LEWIS, M. S.: (1961) On the Intramolecular Crosslinking of Collagen in Lathyric Rats. Biochim. biophys. Acta (Amst.) **53,** 599—601. — 10. MEYER, K., HOFFMAN, P., LINKER, A., GRUMBACH, M. M., SAMPSON, P.: (1959) Sulfated Mucopolysaccharides of Urine and Organs in Gargoylism (Hurler's Syndrome). II. Additional Studies. Proc. Soc. exp. Biol. (N. Y.) **102,** 587—590. — 11. NÉMETH-CSÓKA, M., VISZLÓY, K.: (1960) Kísérletes osteolathyrismusos elváltozások polarizációs optikai vizsgálata. Rheum. Baln. Allerg. (Budapest) **1,** 65—73. — 12. NÉMETH-CSÓKA, M.: (1960) Untersuchung über die Kollagenfasern. I. Über die submikroskopische Struktur der in vitro präzipitierten Kollagenfasern und die stabilisierende Rolle der saueren Mukopolysacchariden. Acta histochem. (Jena) **9,** 282—290. — 13. RASK, M. R.: (1963) Morquio-Brailsford Osteochondrodystrophy and osteogenesis imperfecta. J. Bone J. Surg. **45A,** 561—570. — 14. ROMHÁNYI, GY.: (1958) Submicroscopic Structure of Elastic Fibres, as Observed in the Polarisation Microscope. Nature (Lond.) **182,** 929. — 15. ROMHÁNYI, GY.: (1962) A polarizációs mikroszkópia szerepe a submikroszkópos szerkezetkutatásban. Morph. Ig. Orv. Szle **2,** 161—179. — 16. VERZÁR, F.: (1963) Molekulare Veränderungen des Kollagens beim Altern und bei Erkrankungen. Schweiz. med. Wschr. **93,** 1036—1038. — 17. VISZLÓY, K., NÉMETH-CSÓKA, M.: (1961) Histochemische und polarisationsmikroskopische Untersuchungen über die submikroskopischen Strukturbedingungen der Anilinreaktion der kollagenen Fasern. Acta morph. Acad. Sci. hung. **11,** 31—39. — 18. VISZLÓY, K., KASZA, GY.: (1967) Polarisation Tests in Connection with a Case of Osteogenesis Imperfecta Congenita. Morph. Ig. Orv. Szle. **7,** 46—50.

UNTERSUCHUNG DER SUBMIKROSKOPISCHEN STRUKTUR DES STÜTZGEWEBES BEI KRANKEN MIT HUNTER-SYNDROM

I. Untersuchung mit Hilfe des Polarisationsmikroskops

L. JÓZSA

Verfasser untersuchte mittels polarisationsmikroskopischer Methoden die submikroskopische Struktur der Stützgewebe eines infolge eines Unfalles ums Leben gekommenen an Hunter-Syndrom leidenden Kranken. Verfasser untersuchte mit anisotropen Präzipitationsmethoden mit Rivanol und Toluidinblau den Gehalt saurer Mukopolysaccharide in der Grundsubstanz der Stützgewebe (Femurknochen und -Knorpel, Rippenknochen und Rippenknorpel, Os parietale, Tracheaknorpel, Bronchusknorpel, Mitralklappe und Haut), sowie den Dissoziationszustand. Mit Hilfe von Anilin-Canada und azetyliertem Anilin-Canada untersuchte er die Kollagenstruktur, mittels der Phenolbindungsreaktion — die Bindungen zwischen Kollageneiweißen und Mukopolysacchariden.

Verfasser stellte fest, daß bei Hunter-Syndrom der Mukopolysaccharidgehalt der Stützgewebe erhöht ist. Diese Erscheinung ist die Folge der Vermehrung der im Stützgewebe auch in der Norm vorhandenen Fraktionen und nicht der Ablagerung des für die Huntersche Krankheit bezeichnenden Chondroitinsulfats B, sowie des Heparansulfates. Die Zusammensetzung des Kollagens beim Hunterschen Syndrom unterscheidet sich von der normalen Zusammensetzung, die Zahl der freien Hydroxylradikale (Oxyaminosäuren) in den Kollagenstrukturen erhöht sich im Vergleich zu den Peptidbindungen. Es kann auch nachgewiesen werden, daß sich die Kollagen-Mukopolysaccharidbindungen wesentlich von denjenigen der normalen Kollagenstruktur unterscheiden. Aufgrund dieser Untersuchungsergebnisse nimmt der Verfasser an, daß die Grundsubstanz veränderter Zusammensetzung sowie die pathologischen Kollagenstrukturen gemeinsam einen der Gründe der Verknöcherungsstörungen bei den Erkrankungen der Mukopolysaccharidanhäufung darstellen.

ИЗУЧЕНИЕ СУБМИКРОСКОПИЧЕСКОЙ СТРУКТУРЫ ОПОРНОЙ ТКАНИ У БОЛЬНЫХ СИНДРОМОМ ХУНТЕРА

I. Поляризационно-микроскопические исследования

Л. ЙОЖА

При помощи поляризационного микроскопа была изучена субмикроскопическая структура опорных тканей больного синдромом Хунтера, умершего вследствие несчастного случая. Техника анизотропной преципитации риванолем и толуидиновой синькой служила для выявления содержания кислых мукополисахаридов в основном веществе опорной ткани (бедренной кости, хряща бедренной кости, ребра, хряща ребра, теменной кости, хряща трахеи, хряща бронхов, митрального клапана сердца и кожи), а также ее диссоциационного состояния. Методом покрытия анилин-канадой и ацетилированной анилин-канадой были изучены коллагеновые структуры, а реакцией связывания фенола — мукополисахаридные связи коллагеновых белков.

Было установлено, что при синдроме Хунтера в опорной ткани повышается содержание мукополисахаридов. Это явление вызывается увеличением фракций, присутствующих в опорной ткани и в условиях нормы, а не отложением хондроитинсульфата В и гепарансульфата, характерного для болезни Хунтера. При синдроме Хунтера состав коллагена отличается от нормы, в коллагеновых структурах число свободных гидроксильных радикалов (оксиаминокислот) повышается по сравнению с пептидными связями. Выявляемо и то, что коллагено-мукополисахаридные связи существенно отличаются от связей нормальных коллагеновых структур. На основе этих результатов автором полагается, что основное вещество измененного состава и патологические коллагеновые структуры совместно являются одной причиной расстройств окостенения, наблюдаемых при заболеваниях от накопления мукополисахаридов.

Dr. László Józsa, Országos Traumatológiai Intézet,
Budapest VIII., Mező Imre út 17., Hungary

Acta Morphologica Acad. Sci. Hung. 19 (3), pp. 313—322, 1971

"V. Babes" Institute of Pathology and Medical Genetics (Director: Prof. Dr. I. Moraru), Bucharest

ULTRASTRUCTURAL DATA IN A CASE OF DUBIN—JOHNSON SYNDROME

C. Cotutiu,* I. Moraru and Violeta Ionescu

(Received June 2, 1971)

In a case of Dubin—Johnson syndrome the ultrastructural lesions have been studied on hepatic needle biopsy material.

The observed changes agreed with those described in literature.

From the localisation of acid phosphatase and ATPase it has been concluded that the characteristic pigment is of lysosomal origin and might represent an enzymatic defect of the lysosomes.

Dubin and Johnson [4] and Sprinz and Nelson [11] described in 1954 a form of jaundice characterized in the first place by accumulation in the liver cells of non-biliary pigment. Subsequent investigations revealed the familial, congenital character of the disease [1], its ultrastructural morphology [2] and characteristic disturbances.

The nature of the pigment and the relationship between the bile excretion disturbances and pigment accumulation have not been clarified [2, 6].

By investigating the present case** and using ultrastructural-histo-enzymologic methods, we have attempted to contribute new data concerning the nature of the pigment and the excretion disturbance.

Material and method

Liver tissue fragments were obtained by biopsy. Part of the fragments (for structural preparations) were fixed in 3% glutaraldehyde buffered to pH 7.4 with cacodylate at 4°C for 2 hours, postfixed in OsO_4S-collidine, dehydrated in alcohol and embedded in Epon or Araldite M. The other part (for histochemical preparations) was fixed in glutaraldehyde for 6 hours, buffered with cacodylate at pH 7.4 and sectioned with a freezing microtome (40—50 μ). The sections were tested for acid phosphatase (Barka—Andersson) and ATPase (Wachstein—Meisel), postfixed in OsO_4, dehydrated and embedded in Epon or Araldite.

The ultrathin sections obtained with an L.K.B. II microtome and contrasted with uranyl acetate and lead citrate (Reinolds), were examined in a Zeiss Oberkochen EM 9A and SEM_{3-2} electron microscope at direct magnifications of 1700 to 40,000.

* Electron Microscopy Laboratory, "V. Babes" Institute of Pathology and Medical Genetics.

** Admitted to the 2nd Medical Department (Director : Prof. I. Galea) of "Brincovenesc Hospital, Bucharest, Romania

Results

The thin sections stained with toluidine blue revealed the hepatic cords with maintained architectonics. The liver cells exhibited sharply outlined, round, clear vacuoles, of variable size, loaded with pigment especially peribiliarly. No periportal inflammatory changes or cholestasis were noted.

The ultrastructural alterations consisted in the presence of pigment, mitochondrial changes, modification of the endoplasmic reticulum and of the vascular pole of the liver cell.

a) *Pigment* was prevalently localized in the peribiliary zones of the liver cell, appearing in the form of accumulations of osmiophilic granular material containing sometimes less osmiophilic vacuolar areas. Within the same cell, forms of transition were often noted from dense, strongly osmiophilic pigment to clearer, multivacuolar zones. The pigmentary material was frequently surrounded by a single, fine, continuous or discontinuous membrane; in other instances no such membrane could be observed.

The form of these accumulations varied; round or oval structures, irregular, budded or polymorphous forms (Figs 1, 2) occurred.

b) The *mitochondria* exhibited characteristic aspects, visible especially in certain projections. In the matrix of several mitochondria, regular, parallel filamentous structures could be seen. The more evident these structures were and the more they invaded the matrix, the more reduced were the cristae and larger the mitochondria. One or several neighbouring mitochondria were often affected. This type of alteration described by JEZEQUEL [7] as crystalloid fibrous myelinic dystrophy has no precise significance and has been observed also in other hepatic lesions or even in the absence of any lesions [10].

In our case we noted giant mitochondria with a particularly evident crystalloid aspect, almost entirely replacing the mitochondrial matrix and cristae (Fig. 3).

c) The *endoplasmic reticulum* presented the most evident alterations, consisting in a substantial reduction of the rough reticulum and the appearance of dilated cisterns in the smooth reticulum. In many cells the rough reticulum appeared only around the mitochondria, while the remaining cytoplasm contained vacuoles, sacci and cisterns in the smooth reticulum. Here and there, smoothly dilated cisterns could be seen, containing some electron-opaque granules, which might be interpreted as forms of transition from rough to smooth reticulum.

Among these smooth structures the cytoplasm was loaded with glycogen in the form of large, polyhedral electron-opaque granules. The more smooth vacuolar-cisternal structures there were, the richer was the amount of glycogen (Figs 2, 3).

d) The *vascular pole* of the liver cell was often bare after the disappearance of microvilli; a fine, granular material could be seen in Disse's space. The endo-

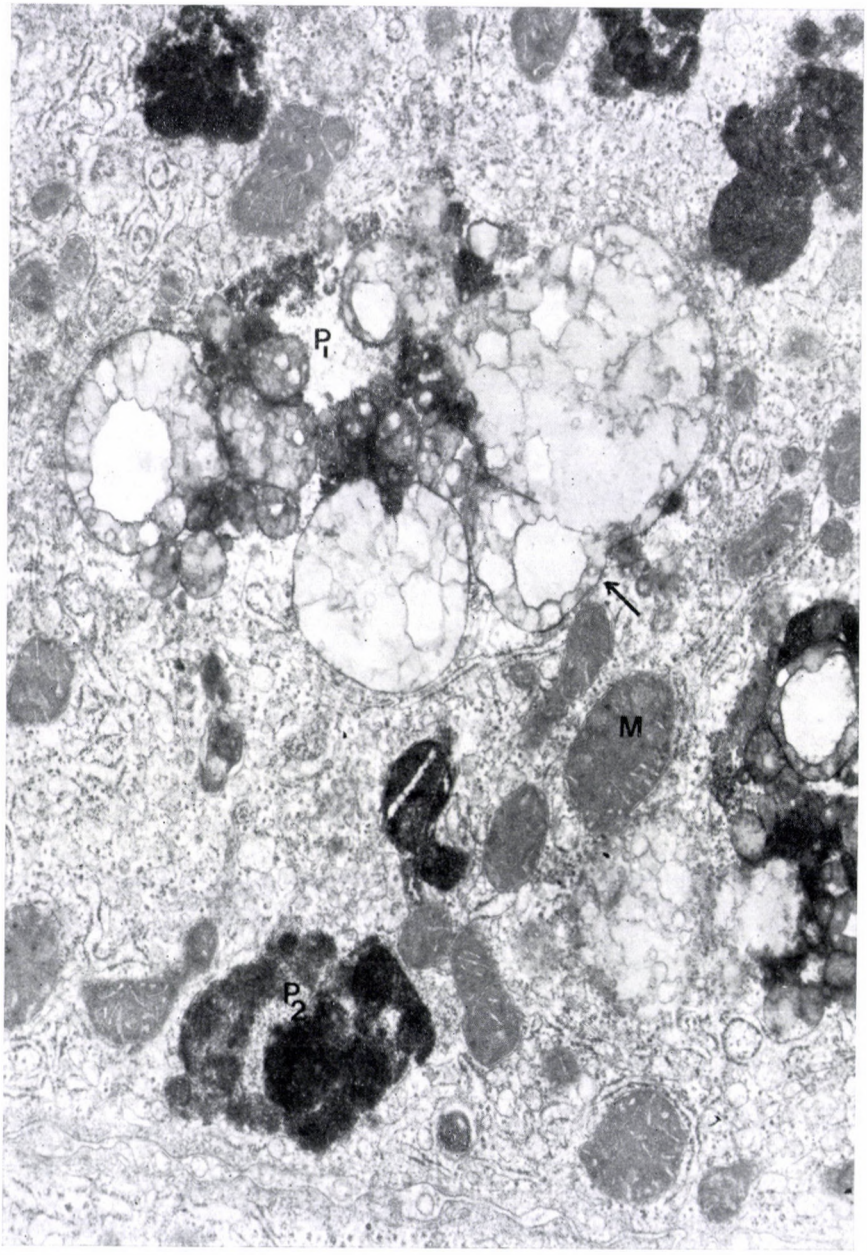

Fig. 1. Dubin—Johnson pigment of the compact, homogeneous type and of the heterogeneous type, surrounded by a single membrane (arrow). ×24,000

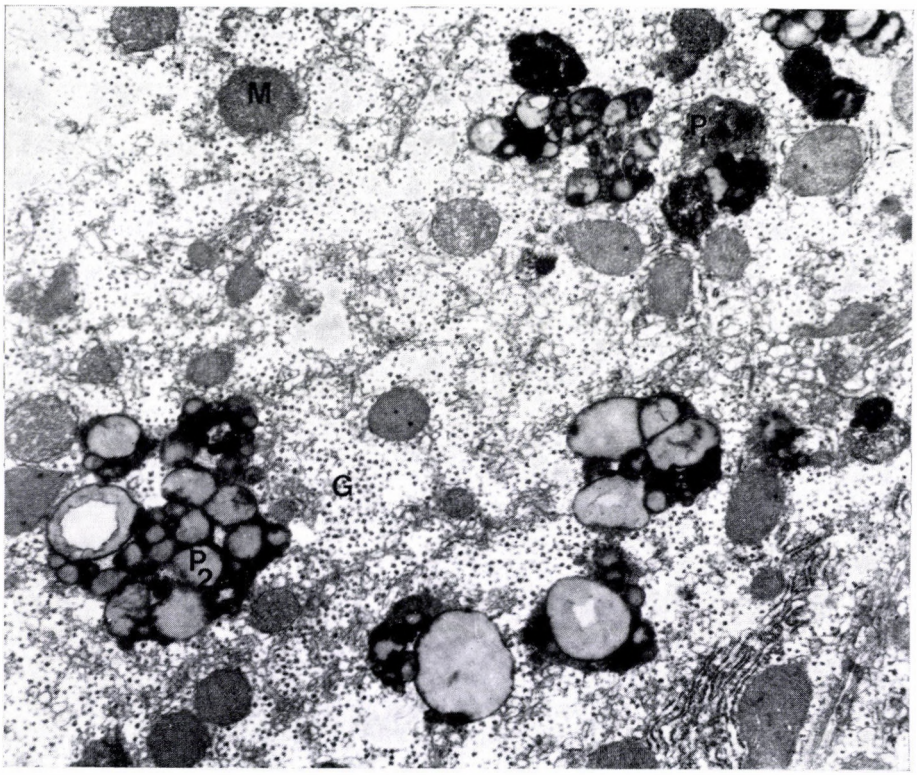

Fig. 2. The same aspect of pigment, with diminution of the rough endoplasmic reticulum, the presence of glycogen and dilatation of the smooth reticulum. × 12,000. M — mitochondrium; G — glycogen; P_1 — heterogeneous pigment; P_2 — dense pigment

thelial and Kupffer cells exhibited no evident alteration or pigment accumulation [12].

At the biliary pole the microvilli had disappeared and the bile ducts were empty.

e) *Enzyme* ATPase gave a positive, granular reaction along the liver cell membranes, strongly accentuated at the level of the bile canalicules (Fig. 5). The reaction was likewise positive in the Kupffer cell membrane (Fig. 4), but negative in the sinusoidal cells.

Acid phosphatase gave a positive reaction in the cytosomal structures, sometimes in onion peel form. The intensity of the reaction was heterogeneous in the pigmentary structures (Fig. 6). The smaller and denser ones gave a relatively homogeneous reaction, whereas the polymorphous structures contained only zones giving a positive reaction. At some sites, in the vicinity of the larger pigmentary structures, smaller intensely positive cytosomes were observed, sometimes sticking to them.

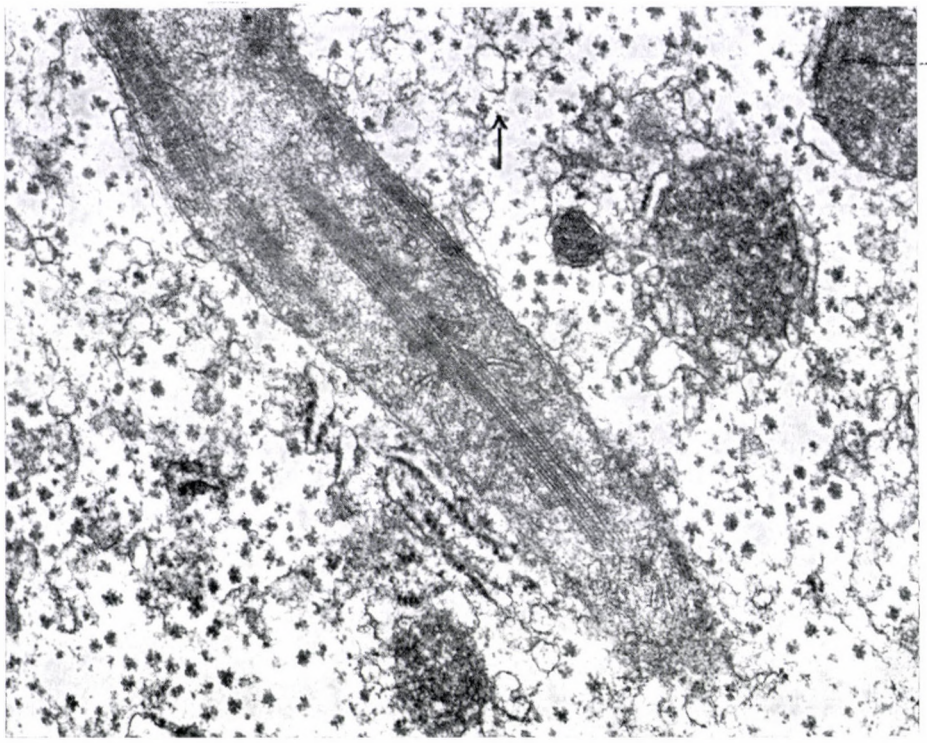

Fig. 3. Giant mitochondria with crystalloid inclusions; glycogen and dilated smooth reticulum (arrow). ×36,000

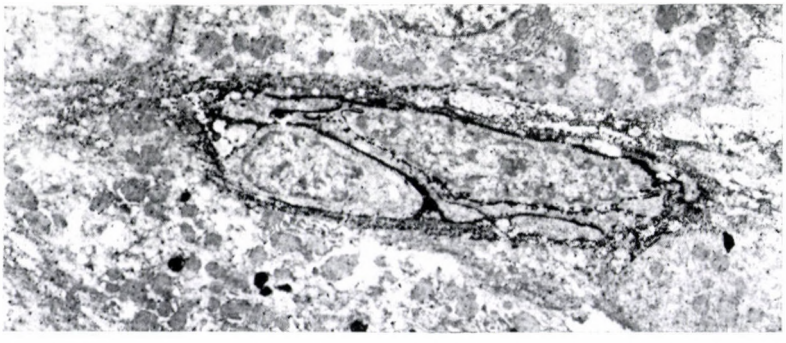

Fig. 4. ATPase in Kupffer cell; intensely positive cell membrane. ×4,000

In some instances, the reaction appeared to be positive within a vacuole delimited by a membrane that contained besides pigment also glycogen and organelle residues (Fig. 7).

A large number of intensely reacting cytosomes were found in the Kupffer cells (Fig. 8).

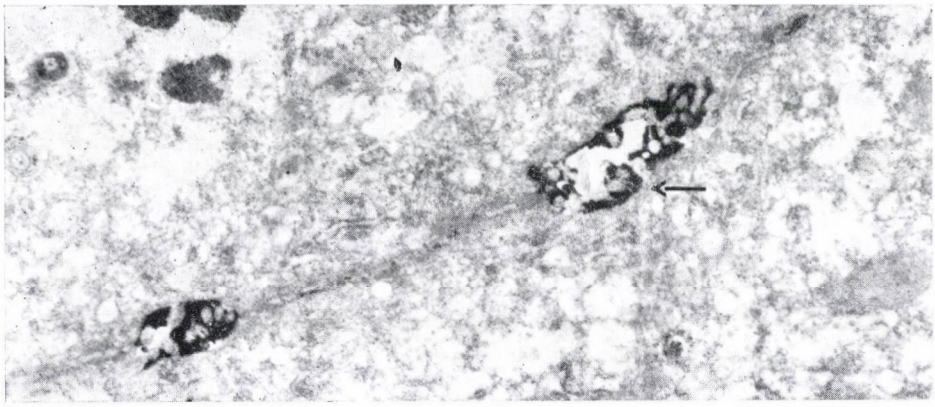

Fig. 5. ATPase in liver cell. Positive reaction in the microvilli of the bile ducts (arrow) and slightly positive reaction in the cell membrane. ×12,000

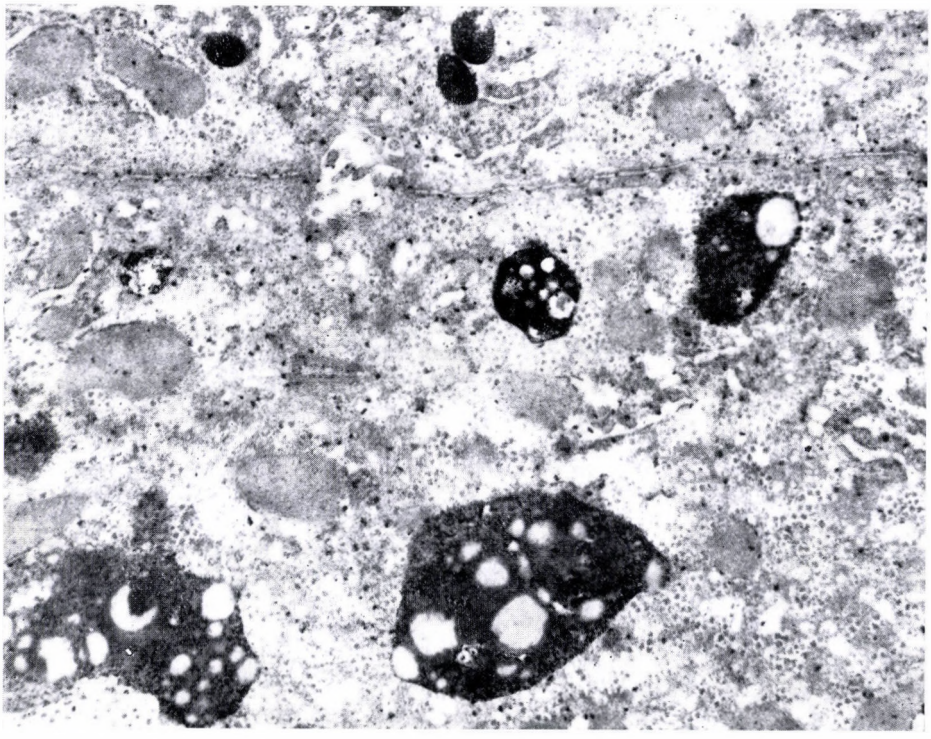

Fig. 6. Acid phosphatase in liver cell. Positive reaction in the peribiliary dense bodies (cytosomes) and pigmentary structures. ×12,000

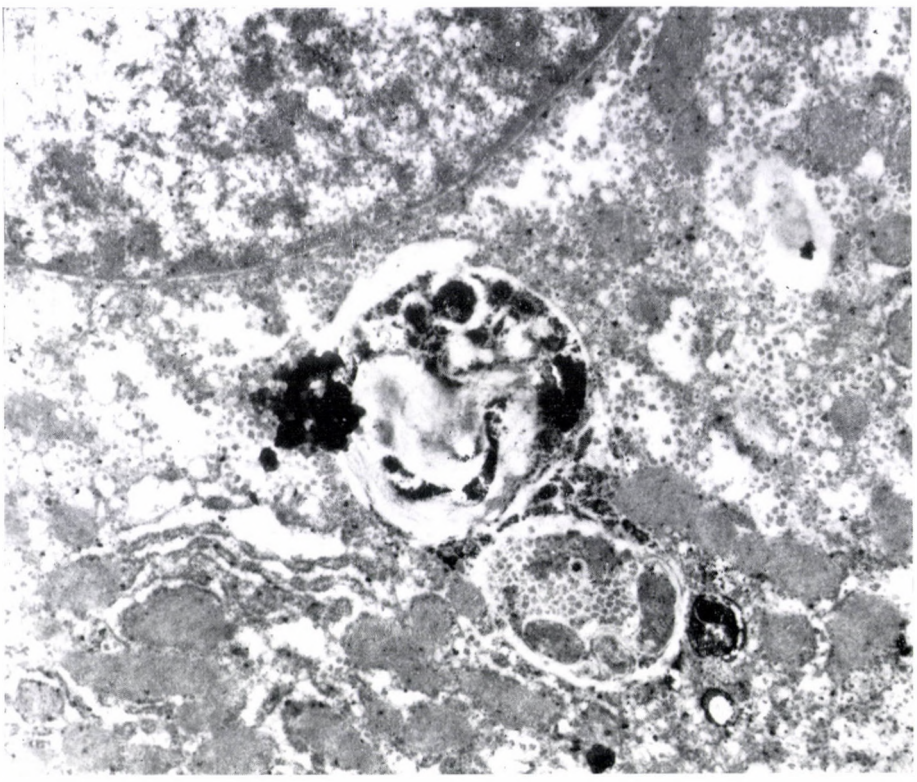

Fig. 7. Acid phosphatase in liver cell. Autophagous vacuoles with cytoplasmic content and positive reaction. ×12,000

Discussion

The ultrastructural aspect of the pigment in our case was indicative of its lipofuscin nature.

The data in literature are contradictory: most workers consider pigment of lipofuscin type on the basis of a series of tinctorial and histochemical properties. However, other authors suggest its melanin nature [6, 13]. Our findings were contradicting the latter assumption, as no elements were observed in favour of melanization (matrices preceding the deposition of pigment). Although the structures varied in size, form and condensation, it is assumed that there was a single type of pigment in different stages of organization.

The presence of acid phosphatase in the pigmentary structures lends support to their lysosomal origin, in agreement with previous findings [3, 5, 8]. Some of the structures observed raise the question of the existence of autophagy in their mechanism of formation. Variations in the intensity of the reaction, from the dense pigment to the heterogeneous type, plead in favour of periodical

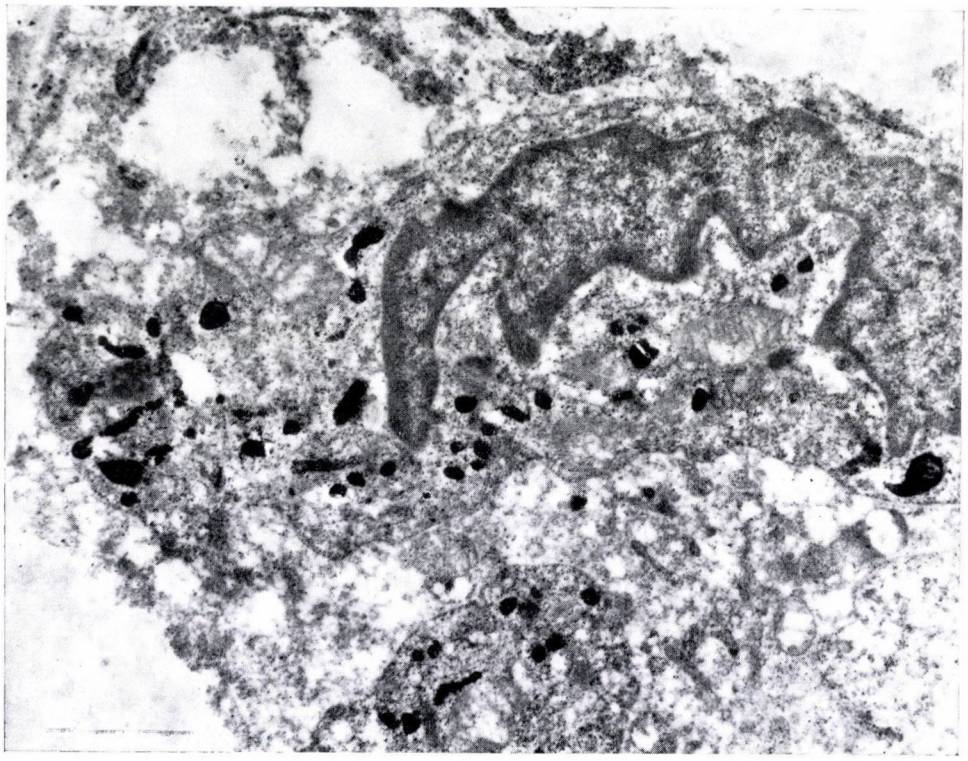

Fig. 8. Acid phosphatase in Kupffer cell. Numerous cytosomes with positive reaction. No pigment is present, ×12,000

accumulations of material in the cytosomes, with a progressive decrease of their lytic capacity.

In Dubin—Johnson syndrome, conjugation of the bile takes place normally [6, 9], but its excretion is deficient. The positivity of the ATPase reaction at the biliary pole of the liver cell shows that, at least from this point of view, the transmembranous transfer of bile is unaffected.

The changes observed at the vascular pole of the liver cell are more difficult to interpret. The existence of an artefact arising during fixation cannot be excluded, but if we bear in mind the good preservation of the structures even an artefact might reflect an increased fragility at this level [6]. These changes might be connected with icteric episodes due to regurgitation of unexcreted bile.

Ultrastructural and histochemical investigations have demonstrated that lipofuscin corresponds to the residual bodies of the lysosomal system. The presence of acid phosphatase in the developing structures of the pigmentary type, and its absence in the large polymorphous pigmentary structures suggest

the existence of an insufficiency of the lysosomal lytic capacity. It is difficult to establish the origin of the material accumulated intralysosomally and the relationship with the bile excretion deficit. For this purpose, ultrastructural investigations should be carried out on other lysosomal enzymes.

Our incomplete knowledge of all the metabolic links in the process of bile formation and excretion under physiological conditions make it difficult to offer a full interpretation of the disturbances observed in Dubin—Johnson syndrome. The familial character of the disease pleads for a genetic enzymatic defect, associated probably with the excretion of bile.

Conclusions

The changes observed have lent support to the diagnosis of Dubin—Johnson syndrome.

The pigment accumulated in this syndrome appears to be of lipofuscin nature and cytosomal in origin.

The disturbance incriminated appears to be at the level of excretion of the liver cell.

The genetic character of the disease is obvious but the intimate substrate of the disturbance still remains to be demonstrated.

REFERENCES

1. Brisbois, P.: (1960) Données de la littérature concernant l'étude clinique, biologique et anatomique de la maladie de Dubin—Johnson. Rév. Méd. (Paris) **35,** 63—74. — 2. Cussac, Y. et al.: (1966) Modifications ultrastructurelles des hépatocytes dans un cas d'ictère chronique idiopathique du type Dubin—Johnson. Ann. Anat. path. **11,** 38—54. — 3. De Duve, C.: Lysosomes, a New Group of Cytoplasmic Particles. In: "Subcellular Particles" New York, pp. 128—159, 1959. — 4. Dubin, J. N., Johnson, F. B.: (1954) Chronic Idiopathic Jaundice with Unidentified Pigment in Liver. Amer. J. Med. **33,** 155—198. — 5. Essner, E., Novikoff, A. B.: (1960) Human Hepatocellular Pigments and Lysosomes. J. Ultrastruct. Res. **3,** 374—391. — 6. Ganter, P., Simard, C., Perrau, H., Joubeau, F.: (1965) Le pigment hépatique de la maladie de Dubin—Johnson. A propos de l'étude histochemique d'une observation. Ann. Anat. path. **8,** 541—570. — 7. Jezequel, A. M.: (1959) Dégénérescence myélinique des mitochondries du foie humain dans un épithélioma du choledoque et un ictère viral. J. Ultrastruct. Res. **3,** 210—215. — 8. Novikoff, A. B., Essner, E.: (1960) The Liver Cell. Some New Approaches to its Study. Amer. J. Med. **29,** 102—131. — 9. Pages, A., Boldet, P.: (1969) Le syndrome de Dubin—Johnson. Ann. Anat. path. **14,** 77—106. — 10. Rouiller, Ch., Simon, G.: (1962) Contribution de la microscopie électronique au progrès de nos connaissances en cytologie et en histopathologie hépatique. Rev. int. Hépat. **12,** 167—205. — 11. Sprinz, H., Nelson, R. S.: (1954) Persistent Nonhemolytic Hyperbilirubinemia Associated with Lipochrome-like Pigment in Liver Cells. Ann. intern. Med. **41,** 962. — 12. Toker, C., Trevino, N.: (1965) Hepatic Ultrastructure in Chronic Idiopathic Jaundice. Arch. Path. **5,** 453—460. — 13. Wegmann, R., Rangier, M., Eteve, J., Charbonnier, A., Caroli, B.: (1960) Mélanose hépato-splénique avec ictère chronique à bilirubine direct: maladie de Dubin—Johnson. Étude chimique et biologique de la maladie. Étude histochimique, clinique et spectrographique du pigment. Sém. hôp. Paris, **36,** 1761—1790.

VERÄNDERUNGEN DER ULTRASTRUKTUR IN EINEM FALL VON DUBIN—JOHNSON SYNDROM

C. COTUTIU, I. MORARU und VIOLETA IONESCU

Verfasser untersuchten die Veränderungen der Ultrastruktur beim Dubin—Johnson Syndrom an mittels Nadelbiopsie aus der Leber gewonnenem Material.

Die festgestellten Veränderungen stimmen mit den in der Literatur beschriebenen überein.

Aus der Lokalisation der sauren Phosphatase und ATPase wurde festgestellt, daß das charakteristische Pigment lysosomaler Herkunft ist und einen enzymatischen Defekt der Lysosomen darstellt.

ИЗМЕНЕНИЯ УЛЬТРАСТРУКТУРЫ В СЛУЧАЕ СИНДРОМА ДУБИНА—ДЖОНСОНА

К. КОТУТИУ, И. МОРАРУ и В. ИОНЕСКУ

Авторы исследовали изменения ультраструктуры в случаях синдрома Дубина—Джонсона на материале, полученного при помощи игловой биопсии из печени.

Установленные изменения совпадают с таковыми, описанными в литературе.

По локализации кислой фосфатазы и АТФ-азы было установлено, что характерный пигмент лизосомального происхождения и является выражением ферментативного дефекта лизосом.

Coriolan COTUTIU, Electron Microscopy Laboratory, "V. Babes" Institute of Path. and Med. Genetics, Bucharest, Romania

Ion MORARU, Violeta IONESCU } "V. Babes" Institute of Path. and Med. Genetics, Bucharest, Romania

RECENSIO

T. Donáth: Anatomical Dictionary with nomenclatures and explanatory notes

Publishing House of the Hungarian Academy of Sciences, Budapest, 1969,

pp. 634, price: 190,00 Ft

The bulk of the words of the medical terminology consists of anatomical terms and of expressions formed of them. This terminology has been widening with the development of anatomical science. The nomenclatures accepted by official bodies aim at drawing a line between limited possibilities and necessity. The first official Nomina Anatomica was constructed in Basel in 1895 and this Basel Nomenclature (BNA) was the only official and usual anatomical terminology until 1935, when it was replaced in part by the Jena Nomenclature (JNA). In 1955, the Paris modification (PNA) based on the Basel Nomenclature has become the official Nomina Anatomica, supplemented with the minor modifications of New York and Wiesbaden.

In addition to the official variants of the Nomina Anatomica used simultaneously by different generations, nomenclatures adapted to the national language are in use in the French, English and other language territories. A dictionary explaining the correspondence between the different names as well as the meaning of the anatomical terms seemed useful in order to avoid confusion and errors.

The first and somewhat rudimentary dictionary of T. Donáth and a co-author was published in 1952; it defined anatomical terms as an aid to interested medical students. This dictionary has gradually widened and became independent during the successive editions. The true ancestor of the present edition is the explanatory dictionary edited in Hungarian in 1959 by the Publishing House of the Hungarian Academy of Sciences, soon followed by the editions in German (1960), and Russian (1961).

The present edition consists of three chapters and an Appendix. In the first chapter (pp. 15—315) the Basel, Jena and Paris Nomenclatures are compared. The terms for the same concept are printed in three columns according to the three nomenclatures. The chapter begins with the survey of general anatomical names, which have become numerous in the PNA. These are not new expressions but nouns and appositions frequently used in the special expressions. The general part contains the indication of planes, directions as well as of the parts of the body.

In the special part the comparison of the nomenclatures is grouped according to organ systems and organs. The names follow the course of the normal anatomical description of each organ. In these cases the expression for the same concept in the second and third column begins at the level of the last line of the preceding column. This make-up spaces the otherwise condensed pages.

The first chapter includes the comparative nomenclature of the regions and ends with the list of the new expressions accepted in Paris.

The second chapter (pp. 319—517), the explanatory dictionary, contains 2500 entries in alphabetical order with grammatical references and their explanations and the expressions derived from them. The key-words are set in bold face, the related expressions in italics. In addition to the terms included in the official nomenclature, those common in morphology are treated. Authors' names are ranged in if they are used for a concept in clinical practice.

The third chapter contains biographical data of 500 scientists and the concepts named after them.

Finally, an important part of the dictionary is the Appendix: here the three nomenclatures are listed in alphabetical order, with different settings and with reference to the respective page number.

The translation of the dictionary is the excellent work of Mrs. Karvinszky, the language reader was G.N.C. Crawford, of the Anatomical Department of Oxford University.

As to the redaction of this well-compiled dictionary, there are only two remarks to be observed. Orientation among the anatomical names arranged according to organs in the first

chapter would be easier if they would follow in alphabetical order. The methodical chapter is not restricted to the explanation of anatomical names but includes histological and embryological concepts, the choice of which seems to be accidental. On the other hand, the explanation of several anatomical concepts used especially by clinicians and not figuring in the official nomenclatures has been omitted; they ought to have found their place in the explanatory chapter.

The aim of dictionaries has changed in recent times. The prevailing functional approach in the instruction of anatomy does not require a mass of names. Thus, this dictionary will meet above all scientific requirements, and will be a useful guide especially for those teaching anatomy, research workers in the field of morphology, authors of text-books and monographs.

T. TÖMBÖL

INDEX

Morphologia Normalis et Experimentalis

Balázs, M.: Liver Injury Induced by Alpha-naphthyl-isothiocyanate 213

Csuka, O.—Sugár, J.: Electron Microscopic Studies on the Specificity of the PA-silver Reaction 233

Basch, A.—Fazekas, I. Gy.—Rengei, B.—Mindszenti, L.: Histochemical and Biochemical Examination of Glucuronidase Activity in the Liver and Serum of Severely Burned Rats 241

Neupert, G.: Struktur embryonaler Zellpopulationen in der Leber und primärer Monolayer-Kultur 247

Mándi, B.—Hadházy, Cs.—Mándi, A.—Glant, T.: Effect of Postnatal Thymectomy on Enchondral Ossification 259

Ungváry, G.—Petrovics, E.—Léránth, Cs.—Naszály, S. A.: The Vena portae as an "Independent" Venous Segment. Its Mural Structure and Innervation 269

Törő, I.—Oláh, I.: Electronmicroscopical Changes Due to Histamine in the Skin of the Rat 283

Pathologia

Józsa, L.: The Submicroscopic Structure of Connective Tissue in a Case of Hunter's Syndrome 301

Cotutiu, C.—Moraru, I.—Ionescu, V.: Ultrastructural Data in a Case of Dubin—Johnson Syndrome 313

Recensio 323

Gerichtliche Medizin
für Juristen, Kriminalisten, Studierende der Rechtswissenschaften und Medizin

Von Dr. med. GERHARD DIETZ, Berlin
5., überarbeitete Auflage
1970. 286 Seiten mit 64 Abbildungen
Leinen 16,50 M

Die "Gerichtliche Medizin" von Dr. G. Dietz ist in einer auch dem Nichtmediziner verständlichen Darstellung gehalten. So bietet sie nicht nur für die Studierenden der Humanmedizin und der Stomatologie, sondern auch für Jurastudenten, Kriminalisten und Angehörige der Kriminalpolizei eine geeignete Grundkonzeption dieses interessanten und oft erregenden medizinischen Fachgebietes. In der 5. Auflage wurden neue strafrechtliche Bestimmungen eingearbeitet, das Kapitel über "Tragzeitgutachten" erweitert und einige der gebräuchlichsten Häufigkeitstabellen aufgenommen.

Bestellungen an den Buchhandel erbeten

JOHANN AMBROSIUS BARTH LEIPZIG

Printed in Hungary

A kiadásért felel az Akadémiai Kiadó igazgatója — Műszaki szerkesztő: Várhelyi Tamás

A kézirat nyomdába érkezett: 1971. XI. 5. — Terjedelem: 10 (A/5) ív, 51 ábra (1 szines)

72.72640 Akadémiai Nyomda, Budapest — Felelős vezető: Bernát György

The Acta Morphologica publish papers on experimental medical subjects in English French, German and Russian.

The Acta Morphologica appear in parts of varying size, making up volumes.

Manuscripts should be addressed to:

Acta Morphologica, Budapest IX., Tűzoltó u. 58.

Correspondence with the editors and publishers should be sent to the same address.

The rate of subscription is $ 16.00 per volume.

Orders may be placed with "Kultúra" Foreign Trade Company for Books and Newspapers (Budapest I., Fő utca 32. Account No. 43-790-057-181) or with representatives abroad.

Les Acta Morphologica paraissent en français, allemand, anglais et russe et publient des travaux du domaine des sciences médicales expérimentales.

Les Acta Morphologica sont publiés sous forme de fascicules qui seront réunis en volumes.

On est prié d'envoyer les manuscrits destinés à la rédaction à l'adresse suivante:

Acta Morphologica, Budapest IX., Tűzoltó u. 58.

Toute correspondance doit être envoyée à cette même adresse.

Le prix de l'abonnement est de $ 16.00 par volume.

On peut s'abonner à l'Entreprise du Commerce Extérieur de Livres et Journaux «Kultúra» (Budapest I., Fő utca 32. Compte-courant № 43-790-057-181) ou à l'étranger chez tous les représentants ou dépositaires.

«Acta Morphologica» публикуют трактаты из области экспериментальных медицинских наук на русском, немецком, английском и французском языках.

«Acta Morphologica» выходят отдельными выпусками разного объема. Несколько выпусков составляют один том.

Предназначенные для публикации авторские рукописи следует направлять по адресу:

Acta Morphologica, Budapest IX., Tűzoltó u. 58.

По этому же адресу направлять всякую корреспонденцию для редакции и администрации. Подписная цена — $ 16.00 за том.

Заказы принимает предприятие по внешней торговле книг и газет «Kultúra» (Budapest I., Fő utca 32. Текущий счет № 43-790-057-181) или его заграничные представительства и уполномоченные.

Reviews of the Hungarian Academy of Sciences are obtainable at the following addresses:

ALBANIA

Drejtorija Qëndrone e Përhapjes dhe Propagandimit të Librit
Kruga Konferenca e Pazes
Tirana

AUSTRALIA

A. Keesing
Box 4886, GPO
Sydney

AUSTRIA

GLOBUS
Höchstädtplatz 3
A — 1200 Wien XX

BELGIUM

Office International de Librairie
30, Avenue Marnix
Bruxelles 5
Du Monde Entier
5, Place St. Jean
Bruxelles

BULGARIA

HEMUS
11 pl Slaveikov
Sofia

CANADA

Pannonia Books
2, Spadina Road
Toronto 4, Ont.

CHINA

Waiwen Shudian
Peking
P. O. B. 88

CZECHOSLOVAKIA

Artia
Ve Směčkách 30
Praha 2
Poštovní Novinová Služba
Dovoz tisku
Vinohradská 46
Praha 2
Mad'arská Kultura
Václavské nám. 2
Praha 1
SLOVART A. G.
Gorkého
Bratislava

DENMARK

Ejnar Munksgaard
Nörregade 6
Copenhagen

FINLAND

Akateeminen Kirjakauppa
Keskuskatu 2
Helsinki

FRANCE

Office International de Documentation de Librairie
48 rue Gay-Lussac
Paris 5

GERMAN DEMOCRATIC REPUBLIC

Deutscher Buch-Export und Import
Leninstraße 16
Leipzig 701
Zeitungsvertriebsam.
Fruchtstraße 3—4
1004 Berlin

GERMAN FEDERAL REPUBLIC

Kunst und Wissen
Erich Bieber
Postfach 46
7 Stuttgart S.

GREAT BRITAIN

Blackwell's Periodicals
Oxenford House
Magdalen Street
Oxford
Collet's Subscription Import Department
Dennington Estate
Wellingborough, Northants.
Robert Maxwell and Co. Ltd.
4 — 5 Fitzroy Square
London W. 1

HOLLAND

Swetz and Zeitlinger
Keizersgracht 471—487
Amsterdam C.
Martinus Nijhof
Lange Voorhout 9
The Hague

INDIA

Hind Book House
66 Babar Road
New Delhi 1

ITALY

Santo Vanasia
Via M. Macchi 71
Milano
Libreria Commissionaria Sansoni
Via La Marmora 45
Firenze
Techna
Via Cesi 16.
40135 Bologna

JAPAN

Kinokuniya Book-Store Co. Ltd.
826 Tsunohazu 1-chome
Shinjuku-ku
Tokyo
Maruzen and Co. Ltd.
P. O. Box 605
Tokyo-Central

KOREA

Chulpanmul
Phenjan

NORWAY

Tanum-Cammermeyer
Karl Johansgt 41 — 43
Oslo 1

POLAND

RUCH
ul. Wronia 23
Warszawa

ROUMANIA

Cartimex
Str. Aristide Briand 14—18
Bucureşti

SOVIET UNION

Mezhdunarodnaya Kniga
Moscow G—200

SWEDEN

Almquist and Wiksel
Gamla Brogatan 26
S—101 20 Stockholm

USA

F. W. Faxon Co. Inc.
15 Southwest Park
Westwood Mass. 02090
Stechert Hafner Inc.
31. East 10th Street
New York, N. Y. 10003

VIETNAM

Xunhasaba
19, Tran Quoc Toan
Hanoi

YUGOSLAVIA

Forum
Vojvode Mišića bro
Novi Sad
Jugoslovenska Knjiga
Terazije 27
Beograd

3. IV. 1972

Index: 26.017

Acta Morphologica

Academiae Scientiarum Hungaricae

ADIUVANTIBUS

J. BALÓ, P. ENDES, K. FARKAS, L. HARANGHY,
B. KELLNER, I. KÖRNYEY, I. KROMPECHER,
GY. ROMHÁNYI, E. SOMOGYI, J. SZENTÁGOTHAI

REDIGIT

I. TÖRŐ

TOMUS XIX * FASCICULUS 4

Akadémiai Kiadó Budapest

1971

ACTA MORPHOLOGICA

A MAGYAR TUDOMÁNYOS AKADÉMIA ORVOSTUDOMÁNYI KÖZLEMÉNYEI

SZERKESZTŐSÉG ÉS KIADÓHIVATAL: BUDAPEST V., ALKOTMÁNY U. 21.

Technikai szerkesztő:
Dr. Somogyi Endre

Az Acta Morphologica német, angol, francia és orosz nyelven közöl értekezéseket a kísérletes orvostudomány tárgyköréből.

Az Acta Morphologica változó terjedelmű füzetekben jelenik meg. Több füzet alkot egy kötetet.

A közlésre szánt kéziratok a következő címre küldendők:

Acta Morphologica, Budapest IX., Tűzoltó u. 58.

Ugyanerre a címre küldendő minden szerkesztőségi és kiadóhivatali levelezés.

Megrendelhető a belföld számára az Akadémiai Kiadónál (Budapest V., Alkotmány utca 21. Bankszámla 05-915-111-46), a külföld számára pedig a „Kultúra" Könyv- és Hírlap Külkereskedelmi Vállalatnál (Budapest I., Fő utca 32. Bankszámla: 43-790-057-181) vagy annak külföldi képviseleteinél és bizományosainál.

Die Acta Morphologica veröffentlichen Abhandlungen aus dem Bereiche der experimental-medizinischen Wissenschaften in deutscher, englischer, französischer und russischer Sprache.

Die Acta Morphologica erscheinen in Heften wechselnden Umfanges. Mehrere Hefte bilden einen Band.

Die zur Veröffentlichung bestimmten Manuskripte sind an die folgende Adresse zu senden:

Acta Morphologica, Budapest IX., Tűzoltó u. 58.

An die gleiche Anschrift ist auch jede für die Schriftleitung und den Verlag bestimmte Korrespondenz zu richten. Abonnementspreis pro Band: $ 16,00.

Bestellbar bei dem Buch- und Zeitungs-Außenhandels-Unternehmen »Kultúra« (Budapest I., Fő utca 32. Bankkonto Nr. 43-790-057-181) oder bei seinen Auslandsvertretungen und Kommissionären.

Acta Morphologica Acad. Sci. Hung. 19 (4), pp. 325–334 1971

Institute of Anatomy, Histology and Embryology (Director: Prof. B. FLERKÓ), University Medical School, Pécs

THE PROJECTION OF THE RETINAL QUADRANTS ON THE OPTIC CENTRES IN THE FROG

A TERMINAL DEGENERATION STUDY

GY. LÁZÁR

(Received March 15, 1971)

The Fink and Heimer technique was employed to study the projection of the retinal quadrants upon the optic centres after focal retinal lesions in the frog. On the side contralateral to the lesions the following projections were found.

In the lateral geniculate body and in the nucleus of Bellonci the nasal and ventral retinal quadrants project on the anterior half of these neuropil areas. The ventral quadrant fibres terminate dorsal to the nasal fibres. The temporal and dorsal retinal quadrants project on the posterior half of these structures, and the temporal fibres terminate more dorsally than the dorsal fibres.

In the pretectal area, fibres originating from the nasal and the ventral quadrants terminate in the dorsal half, and the temporal and dorsal fibres in the ventral half of the neuropil.

In the optic tectum the nasal quadrant fibres terminate in the posteromedial, the ventral fibres in the anteromedial, the temporal fibres in the anterolateral and the dorsal fibres in the posterolateral part of the tectum.

The temporal quadrant of the retina gives rise also to an ipsilateral projection into the lateral geniculate body, the nucleus of Bellonci and the pretectal area.

Using silver technique on normal material, STRÖER [35] was able to show an ordered quadrantic projection of the retina upon the optic tectum in lower vertebrates. The positions of scotomata evoked in the visual field with focal lesions of the tectum referred also to an ordered retino-tectal projection in frogs [33]. With the aid of the electrophysiological mapping technique GAZE [13], MATURANA et al. [27] and JACOBSON [20] have shown a well-organized point-to-point retinal projection into the contralateral optic tectum. In the lateral geniculate body of the frog MUNTZ's physiological studies [30] revealed a similar organization in the termination of optic fibres. A detailed analysis with the aid of modern degeneration techniques of the projection of retinal quadrants in the frog has not been reported. In the present investigation the terminal degeneration technique has been applied for studying the retinotopic projection of optic fibres on the diencephalic optic centres and the optic tectum.

Material and methods

The experiments were made on 82 adult frogs (Rana esculenta). With the aid of a glass insulated platinum electrode small electrolytic lesions were placed in the retina under the dissecting microscope. The electrode was positive to earth and a current of 3 mA was passed for 10 sec. Most of the lesions were placed close to the peripheral margin of the dorsal, nasal, ventral and temporal quadrants, and a few others at the border between two quadrants.

Usually, 1 to 4 penetrations were made to destroy a sufficiently large field of the retina. Following the operation the animals were kept alive for 6 to 8 days in the summer, and 9 to 12 days in the winter, then they were anaesthetized and perfused with physiological saline and 10% formalin through the aorta. The brain and one half of the skull together with the operated eye were removed and stored in 10% formalin for a fortnight. Brains were embedded in 25% gelatine solution and frozen sections 20 μ thick were prepared in the coronal, horizontal and sagittal planes. Degenerated terminals were shown with the FINK and HEIMER [11] technique.

The sites of degenerated terminals were plotted in drawings made from serial sections in the coronal plane of the diencephalon and mesencephalon. Sites of the retinal lesions were checked under the stereoscopic microscope. The cornea and iris were removed, and a cross-mark applied into the eye-piece and centred on the optic disc, was superimposed on the retina. In the standard position used in these experiments, the horizontal line of the cross-mark touched the upper rim of the tympanic membrane and crossed the middle part of the optic disc. The sites of lesions indicated by opacities in the retina were determined with reference to the cross-mark and plotted in a circle representing the retina. The size of the lesions varied from 0.7 to 3.5 mm in diameter.

Results

Projections on the lateral geniculate body and the nucleus of Bellonci

In the oral part of the diencephalon, two well-defined neuropil areas one of them in the lateral geniculate body (LGB) and the other in the nucleus of Bellonci (NB), receive both contralateral and ipsilateral optic fibres [26, 31]. In the neuropil spotty degeneration appears after focal retinal lesions close to the optic tract. The distribution of degeneration is different in the caudal and oral parts of the contralateral LGB. In the caudal part, circumscribed lesions of the retina evoked triangular fields of degenerated terminals in coronal sections (Fig. 1). More orally the pattern of degeneration was not as regular. Usually a larger spot of maximal density of granules could be seen surrounded by smaller patches of scattered granules indicative of degenerated terminals. In the NB the general distribution of degeneration was similar to that found in the LGB.

The localization of the degeneration following lesions in the different retinal quadrants is shown schematically in Fig. 4 in four representative cases. A lesion in the nasal quadrant caused degeneration in the most oral part of the LGB. The degeneration after a ventral quadrant lesion occupied also the oral half of the neuropil but dorsal to the projection of the nasal quadrant. At their border the two fields partially overlapped. Both fields extended as far caudally as the middle part of the neuropil area, and from their initial laterodorsal position they tended to shift ventrally and medially. Lesions in the temporal and dorsal quadrants brought about degeneration in the caudal half of the LGB. The temporal quadrant projected somewhat oral to the dorsal quadrant, and in the middle third of this neuropil structure the terminations of the temporal fibres were at the same level as those of the nasal and ventral fibres. A little more caudally the two triangular areas occupied by the degen-



Fig. 1. Degeneration in the neuropil area of the lateral geniculate body following a small oval lesion made in the upper part of the temporal retinal quadrant of the contralateral eye. The granules indicating degenerated optic fibre terminals occupy a triangular area. The medial margin of the optic tract is shown by broken lines

Fig. 2. Degenerated optic fibre terminals in the neuropil area of the lateral geniculate body after a large peripheral lesion made in the temporal retinal quadrant of the ipsilateral eye. The medial border of the LGB is to the right. Silver granules are present in the dorsomedial circumference of the neuropil area (arrows)

Fig. 3. Degenerated optic fibre terminals in the caudomedial part of the optic tectum after a lesion made in the nasal retinal quadrant of the contralateral eye. The large pigmented spot indicates the surface of the tectum. St.z.: stratum zonale; 9, 8, 7, 6, 5, 4,: tectal layers. The horizontal bar indicating magnification applies to all three photograms

erated terminals of temporal and dorsal fibres partially overlapped and both areas were located somewhat ventral to their initial position. At the most caudal level the area for the degenerated temporal fibres was in the middle part of the neuropil of the LGB, and the degenerated dorsal fibre terminals filled up the posterior pole.

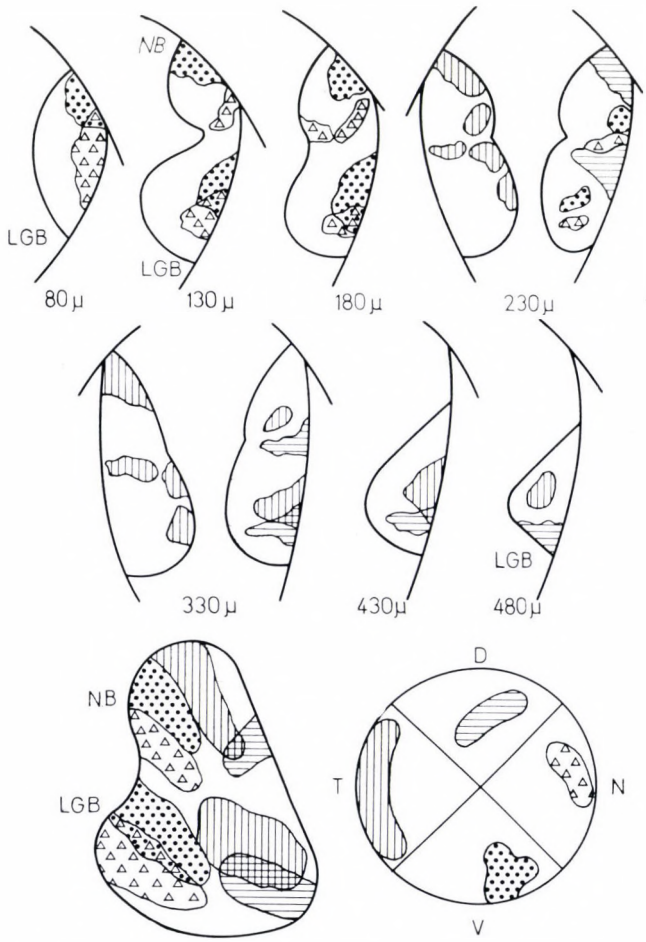

Fig. 4. Schematic representation of the projection of the four retinal quadrants on the lateral geniculate body and the nucleus of Bellonci. The two upper rows of drawings were made from a serial section of the diencephalon. Single drawings show the contralateral side, in the paired drawings the left side is ipsilateral to the lesion. The distance of individual sections from the anterior pole of the LGB is given in microns below the drawings. Patterned areas indicate the localization of degenerated fibres of different origin according to the scheme of the right lower drawing, which shows the position and extension of the retinal lesions. N, V, T, D: nasal, ventral, temporal and dorsal quadrants of the retina. The left lower drawing is a side view of the neuropil areas of the nucleus of Bellonci (NB), and the lateral geniculate body (LGB) with a lateral projection of the areas of degeneration

In the NB a similar order of projection was found. The sequence of the representation of the quadrants was the same as in the LGB, but a considerable number of granules was found in the medial part of the nucleus.

Temporal quadrant lesions result in ipsilateral degeneration as well. The degenerated granules are fewer and are distributed more thinly than on the contralateral side (Fig. 2). This degeneration occupies the dorsomedial circumference of the middle third of the LGB (Fig. 4). In contrast to the contralateral degeneration, the ipsilateral fibres terminate dorsally and medially, both in the LGB and NB. The orocaudal extension of the ipsilateral projection measuring about 200 μ in length, does not reach the caudal pole.

Projections on the pretectal neuropil area

The pretectal neuropil occupies a cylindrical area in front of the tectum (Fig. 5). Fibres originating in the contralateral nasal and ventral quadrants terminate in the dorsal half, while the temporal and dorsal quadrant fibres in the ventral half, of that structure. Within this arrangement, the nasal and dorsal fibres terminate medially and orally to the ventral and temporal fibres

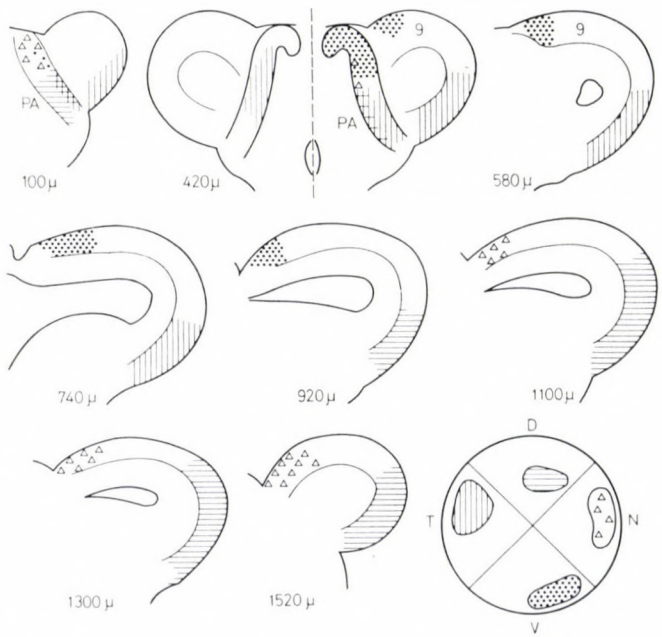

Fig. 5. Schematic representation of the projection of the four retinal quadrants on the contralateral pretectal area (PA) and the optic tectum. The left side of the second drawing is ipsilateral to the lesion. The distances of the individual sections from the anterior pole of the tectum are given in microns under the respective drawings. Patterned areas show the sites of degeneration. In the circle representing the retina (right lower corner) the positions and extensions of the retinal lesions are shown with the appropiate patterning. 9: the 9th layer of the optic tectum

which occupy a lateral and caudal position. This latter separation of fibre terminals is not clearly demarcated, as the fibres originating in adjacent quadrants (nasal-ventral and temporal-dorsal) extensively intermingle in the dorsal and ventral half, respectively, of the pretectal neuropil.

After temporal lesions degeneration can be found also on the ipsilateral side. The ipsilateral optic fibres cover an area which occupies a caudal position in the middle third of the pretectal neuropil.

Projections on the optic tectum

Focal lesions in the retina evoke degeneration in well-defined areas of the contralateral optic tectum. Peripheral retinal lesions result in degeneration in the lateral or medial edge of the tectum; the more the lesion approaches the optic disc, the wider the degenerated zone in the tectum. If a whole quadrant is destroyed, the zone of degeneration covers half of the tectal circumference in the coronal plane. The border of degeneration is always sharp and well-defined in layers 9 and 8, which are the receiving zones for optic fibres in the tectum (Fig. 3). The distribution of degeneration in these layers has already been described in detail [26].

The projection of the four retinal quadrants upon the optic tectum is shown in Fig. 5. Fibres of ventral and nasal quadrant origin travel in the medial division of the optic tract and invade the medial half of the tectum. Ventral quadrant fibres terminate in the anterior part, nasal fibres in the posterior part of this tectal area. In both cases represented, the lesions in the retina are relatively small and situated close to the peripheral margin. Accordingly, a narrow zone of degeneration is plotted at the anteromedial and posteromedial edge of the tectum. Fibres of temporal and dorsal quadrant origin reach the lateral half of the tectum through the lateral division, and temporal fibres terminate orally to dorsal fibres. In the cases shown in Fig. 5, the temporal lesion is large and the dorsal lesion is positioned towards the optic disc. This is why degenerated dorsal fibre terminals are filling almost the entire posterolateral part, and temporal fibre terminations are distributed in a comparatively large field in the anterolateral part of the tectum. Unlike in the diencephalic centres, overlapping areas of adjacent projections cannot be shown in the tectum.

A retinotopically organized projection on the nucleus of the basal optic root could not be established from the present material.

Discussion

The present findings on the contralateral retino-geniculate projection are similar to those made by MUNTZ [30] with electrophysiological methods. He succeeded in showing that the nasal visual field was projected caudal to

the temporal field on the lateral geniculate body. With the Fink—Heimer technique we could distinctly localize the projections of the four retinal quadrants onto the LGB and the NB. Following focal lesions placed into the peripheral part of the retina, degenerated granules appeared in the lateral part of these nuclei. In a few cases of larger and more central lesions, the degeneration was found more medially. This suggests that the periphery of the retina projects mainly on the lateral part of these nuclei, and their medial part is occupied by the centre of the retina. An ordered retino-pretectal projection on the pretectal neuropil area has not been described in the literature. In our material a fairly good separation could be seen between the site of terminations of fibres coming from the nasal-ventral and temporal-dorsal halves of the retina. They terminate in the dorsal and the ventral part, respectively, of this neuropil area, but within this separation the projections of adjacent quadrants overlap extensively.

Like in mammals, the ipsilateral fibres to these three diencephalic optic structures originate in the temporal retina, but only a smaller part of the temporal fibres remains uncrossed in the frog. In the mammalian LGB the pattern of termination of ipsilateral fibres is more complicated than in the frog, though the tendency of ipsilateral fibres to terminate medially to contralateral fibres seems to be a common feature. The ipsilateral optic fibres occupy the medial part of the dorsal nucleus of the LGB in the rat [18] and the rabbit [15]. In higher mammals, such as the cat [12, 25, 29, 34] the ipsilateral fibres terminating in lamina A_1 occupy a central position surrounded by contralateral fibres in the LGB. In animals in which the fibres of the two eyes terminate in alternating layers of the LGB, the ipsilateral fibres tend to accumulate in the more medial layers [7, 23, 36]. There seems to be only a single curious exception, Trichosurus vulpecula, in which the ipsilateral fibres project lateral to the contralateral fibres [17].

The functional significance of the direct optic fibres is unknown in the frog. In fishes and birds, which have panoramic vision without a binocular visual field, direct retinal fibres could not be shown in the ipsilateral diencephalic centres [6, 8, 9]. During phylogenesis, the ipsilateral fibres appear first in amphibia [21, 26, 31] and reptiles [1, 2, 5, 22], and the nasal fields partially overlap in these animals [14]. It seems that the presence of ipsilateral retino-diencephalic fibres is somehow associated with the development of binocular vision.

The retino-tectal projection found in the present study is exactly the same as that obtained in electrophysiological mapping experiments [13, 20, 27]. The apparent discrepancies are purely artificial and a consequence of representation. In physiological experiments the eye is usually divided by a dorsoventral line into nasal and temporal halves. Here two oblique lines, both at 45° to the dorsoventral line, cut the eye into four quadrants. Hence the present

map is rotated by 45° with relation to electrophysiological maps. In terms of fibre distribution in the optic tract, the eye can be divided into a dorsotemporal and a nasoventral half. Fibres of dorsotemporal origin travel in the lateral division, and those of nasoventral origin in the medial division of the optic tract. This line of separation runs in the orocaudal direction, the other line which divides the eye into nasodorsal and temporoventral halves, runs in the mediolateral direction on the tectum.

The retino-tectal projection is strikingly the same in the different vertebrate classes [16, 19, 28, 32]. In lower mammals including rodents, where the retino-tectal fibres are wholly crossed, or the number of uncrossed temporal fibres is negligibly small, the pattern of projection is identical with that found in the frog [3, 4, 15, 24]. In higher mammals the retino-collicular projection shows basically the same pattern, however, with the increasing number of ipsilateral temporal fibres and the bilateral representation of the fovea centralis, the identical points of the visual field are projected on the same collicular place [10, 12, 25].

REFERENCES

1. Armstrong, J. A.: (1950) An Experimental Study of the Visual Pathways in a Reptile *(Lacerta vivipara)*. J. Anat. **84,** 146—167. — 2. Armstrong J. A.: (1951) An Experimental Study of the Visual Pathways in a Snake *(Natrix natrix)*. J. Anat. **85,** 275—288. — 3. Bodian, D.: (1937) An Experimental Study of the Optic Tracts and Retinal Projection of the Virginia Opossum. J. comp. Neurol. **66,** 113—144. — 4. Brouwer, B., Zeeman, W. P. C.: (1925) Experimental Anatomical Investigations Concerning the Projection of the Retina on the Primary Optic Centers in Apes. J. Neurol. Psychopath. **6,** 1—10. — 5. Burus, A. H., Goodman, D. C.: (1967) Retinofugal Projections of *Caiman sklerops*. Exp. Neurol. **18,** 105—115. — 6. Campbell, C. B. G., Ebbesson, S. O. E.: (1971) The Optic System of a Teleost: *Holocentrus* Re-examined. Brain, Behav. Evol. (in press). — 7. Campos-Ortega, J. A., Glees, P.: (1967) The Subcortical Distribution of Optic Fibers in *Saimiri sciureus* (Squirrel monkey). J. comp. Neurol. **131,** 131—142. — 8. Cowan, W. M., Adamson, L., Powell, T. P. S.: (1961) An Experimental Study of the Avian Visual System. J. Anat. **95,** 545—563. — 9. Ebbesson, S. O. E.: (1968) Retinal Projections in Two Teleost Fishes (*Opsanus tau* and *Gymnothorax funebris*). An Experimental Study with Silver Impregnation Methods. Brain, Behav. Evol. **1,** 134—154. — 10. Feldon, S., Feldon, P., Kruger, L.: (1970) Topography of the Retinal Projection upon the Superior Colliculus of the Cat. Vision Res. **10,** 135—143. — 11. Fink, R. P., Heimer, L.: (1967) Two Methods for Selective Impregnation of Degenerating Axons and their Synaptic Endings in the Central Nervous System. Brain Res. **4,** 369—374. — 12. Garey, L. J., Powell, T. P. S.: (1968) The Projection of the Retina in the cat. J. Anat. **102,** 189—223. — 13. Gaze, R. M.: (1958) The Representation of the Retina on the Optic Lobe of the Frog. Quart. J. exp. Physiol. **43,** 209—214. — 14. Gaze, R. M., Jacobson, M.: (1962) The Projection of the Binocular Visual Field on the Optic Tecta of the Frog. Quart. J. exp. Physiol. **44,** 273—280. — 15. Giolli, R., Guthrie, Mary D.: (1969) The Primary Optic Projections in the Rabbit. An Experimental Degeneration Study. J. comp. Neurol. **136,** 99—126. — 16. Hamdi, F., A., Whiterbridge, D.: (1954) The Representation of the Retina on the Optic Tectum of the Pigeon. Quart. J. exp. Physiol. **39,** 111—119. — 17. Hayhow, W. R.: (1967) The Lateral Geniculate Nucleus of the Marsupial Phalanger *Trichosurus vulpecula*. An Experimental Study of Cytoarchitecture in Relation to the Intranuclear Optic Nerve Projection Fields. J. comp. Neurol. **131,** 571—604. — 18. Hayhow, W. R., Sefton, A., Webb, C.: (1962) Primary Optic Centers of the Rat in Relation to the Terminal Distribution of the Crossed and Uncrossed Optic Nerve Fibers. J. comp. Neurol. **118,** 295—321. — 19. Heric, T. M., Kruger, L.: (1965) Organization of the Visual Projections upon the Optic Tectum of a Reptile *(Alligator mississippiensis)*. J. comp. Neurol. **124,** 101—111. — 20. Jacobson, M.: (1962): The Representation of the Retina on the Optic Tectum of the Frog. Correlation between

Retinotectal Magnification Factor and Retinal Ganglion Cell Count. Quart. J. exp. Physio. **47,** 170—178. — 21. KNAPP, H., SCALIA, F., RISS, W.: (1965) The Optic Tracts of *Rana pipiens.* Acta neurol. scand. **41,** 325—355. — 22. KOSAREVA, A. A.: (1967) Projection of Optic Fibers to Visual Centers in a Turtle *(Emys orbicularis).* J. comp. Neurol. **130,** 263—276.— 23. LAEMLE, L. K., NOBACK, C. R.: (1970) The Visual Pathways of the Lorisid Lemurs (*Nycticebus coucang* and *Galago crassicaudatus*). J. comp. Neurol. **138,** 19—61. — 24. LASHLEY, K. S.: (1934) The Mechanism of Vision. VII. The Projection of the Retina upon the Primary Optic Centers in the Rat. J. comp. Neurol. **59,** 341—375. — 25. LATIES, A. M., SPRAGUE, J. M.: (1966) The Projection of Optic Fibers to the Visual Centers in the Cat. J. comp. Neurol. **127,** 35—70. — 26. LÁZÁR, GY., SZÉKELY, GY.: (1969) Distribution of Optic Terminals in the Different Optic Centres of the Frog. Brain Res. **16,** 1—14. — 27. MATURANA, H. R., LETTVIN, J. Y., MCCULLOCH, W. S., PITTS, W. H.: (1960) Anatomy and Physiology of Vision in the Frog *(Rana pipiens).* J. gen. Physiol. **43,** 129—176. — 28. MCGILL, J. J., POWELL, T. P. S., COWAN, W. M.: (1966) The Retinal Representation upon the Optic Tectum and Isthmo-optic Nucleus in the Pigeon. J. Anat. **100,** 5—33. — 29. MOORE, R. Y., KARAPAS, F., FRENKEL, M.: (1964) Lateral Geniculate Projection from Discrete Retinal Lesions in Cat. Anat. Rec. **148,** 390. — 30. MUNTZ, W. R. A.: (1962) Microelectrode Recordings from the Diencephalon of the Frog *(Rana pipiens)* and a Blue-sensitive System. J. Neurophysiol. **25,** 699—711. — 31. SCALIA, F., KNAPP H., HALPERN, M., RISS, W.: (1968) New Observations on the Retinal Projection in the Frog. Brain, Behav. Evol. **1,** 324—353. — 32. SCHWASSMANN, H. O., KRUGER, L.: (1965) Organization of the Visual Projections upon the Optic Tectum of Some Fresh Water Fish. J. comp. Neurol. **124,** 113—126. — 33. SPERRY, R. W.: (1944) Optic Nerve Regeneration with Return of Vision in Anurans. J. Neurophysiol. **7,** 57—70. — 34. STONE, J., HANSEN, S. M.: (1966) The Projection of the Cat's Retina on the Lateral Geniculate Nucleus. J. comp. Neurol. **126,** 601—624. — 35. STRÖER, W. F. H.: (1940) Zur vergleichenden Anatomie des primären optischen Systems bei Wirbeltieren. Z. Anat. Entw.-Gesch. **110,** 301—321. — 36. TIGGES, M., TIGGES, J.: (1970) The Retinofugal Fibers and their Terminal Nuclei in *Galago crassicaudatu*, (Primates). J. comp. Neurol. **138,** 87—102.

DIE PROJEKTION DER NETZHAUTQUADRANTEN IN DEN OPTISCHEN ZENTREN DES FROSCHES. UNTERSUCHUNG DER TERMINALEN DEGENERATION

GY. LÁZÁR

Verfasser untersuchte nach fokalen Retinaläsionen mittels der Methode von Fink und Heimer die Projektion der Retinaquadranten in den optischen Zentren am Frosch. Auf der der Netzhaut entgegengesetzten Seite wurden folgende Projektionen festgestellt.

Im Corpus geniculatum laterale und im Nucleus Bellonci werden die nasalen und ventralen Netzhautquadranten auf die vordere Hälfte der Neuropilen projiziert. Die Fasern des ventralen Quadranten enden dorsal von den nasalen Fasern. Die temporalen und dorsalen Netzhautquadranten werden auf den hinteren Teil der Neuropilen projiziert und die temporalen Fasern enden dorsal.

Auf dem prätectalen Gebiet enden die von dem nasalen und dem dorsalen Quadranten kommenden Fasern im dorsalen Teil der Neuropile, die temporalen und dorsalen Fasern dagegen im ventralen Teil.

Im Tectum opticum enden die nasalen Fasern posteromedial, die ventralen Fasern anteromedial; die temporalen Fasern anterolateral und die dorsalen Fasern posterolateral.

Der temporale Quadrant der Netzhaut besitzt auch eine Projektion auf die eigene Seite, auf das Corpus geniculatum laterale, den Nucleus Bellonci und auf das prätectale Gebiet.

ПРОЕКЦИЯ КВАДРАНТОВ СЕТЧАТОЙ ОБОЛОЧКИ ЛЯГУШКИ НА ЗРИТЕЛЬНЫЕ ЦЕНТРЫ. ИССЛЕДОВАНИЕ КОНЦЕВОГО ПЕРЕРОЖДЕНИЯ

Д. ЛАЗАР

Автор исследовал после очаговых поражений сетчатой оболочки по методу Финка и Хеймера проекцию квадрантов сетчатки в зрительных центрах лягушки. На стороне, противоположной сетчатой оболочке были установлены следующие проекции.

В боковом коленчатом теле и в ядре Беллончи назальные и вентральные квадранты сетчатой оболчки проецируются на переднюю часть нейропилов. Волокна вентрального квадранта оканчиваются дорсально от таковых назального квадранта. Височные и дорсальные квадранты проецируются на заднюю часть нейропилов и височные волокна оканчиваются дорсально.

В претектальной области волокна, идущие от носового и от дорсального квадрантов оканчиваются в дорсальной части нейропилов. Височные и дорсальные волокна же оканчиваются в вентральной части.

В области зрительной покрышки назальные волокна оканчиваются постеромедиально, вентральные волокна — антромедиально; височные волокна оканчиваются антролатерально, а дорсальные волокна — постеролатерально.

Височный квадрант сетчатой оболочки имеет и проекцию на своей же стороне на боковое коленчатое тело, на ядро Беллончи и на претектальную область.

Dr. Gyula LÁZÁR: Anatómiai Intézet, Pécs, Hungary

Acta Morphologica Acad. Sci. Hung. 19 (4), pp. 335—347, 1971

2nd Institute of Pathology (Director: Prof. H. JELLINEK), Semmelweis University School of Medicine, and Research Institute for Animal Breeding (Head: J. KESERÜ), Budapest

ABSORPTION OF COLOSTRUM IN THE RAT AND THE CAT

A COMPARATIVE ELECTRON MICROSCOPIC STUDY

B. VERESS and K. BAINTNER, JR.

(Received April 6, 1971)

Structures related to protein absorption have been studied in ileal epithelial cells of rats and cats. Cells of embryos and newborn lactated animals alike contained a system of tubules and vesicles (TVS) localized in the apical part of the cytoplasm. The limiting membranes of the TVS showed a particular structure, consisting of a 56 Å thick unit membrane, and an 80 Å thick granular internal lining layer, thus representing a transitory type between exo- and endoplasmic membrane systems. The tubules had outlets to the intermicrovillous gaps and also communicated with the supranuclearly localized large vacuole (SNV) which obviously served for storing the absorbed proteins. In the rat cells, the latter structure retained its vacuole nature throughout; its contents consisted partly of eccentrically aggregated granular material, partly of filamentous structures. In contrast, in the cat cells the vacuole represented a body containing homogeneous electron dense substance, the so-called central drop. With the progress of protein absorption, the central drop filled almost the entire cytoplasm, compressing thereby the elements of the TVS.

Under the given conditions, no morphological difference was detected between the TVS of the rat and the cat, animals known for selective and nonselective absorption of proteins, respectively. It appears that selectivity takes effect not so much at the uptake as at the cellular passage or transfer of the absorbed proteins.

The majority of newborn mammals receive passive immunity through the colostrum (Table 1). Intestinal absorption of antibodies takes place in the ileum in undigested macromolecular form [5].

In the rat, after the first week of life exclusively immunoglobulins are absorbed [20]. No similar selection has been noted in ungulates and carnivores, which absorb also proteins other than immunoglobulins [1, 2, 4, 5, 28]. The morphological study of the absorption process has been centered on three main aspects, (1) the manner in which the colostral proteins enter the intestinal epithelial cells; (2) the fate of the proteins during their passage across these cells; and (3) the manner of the exit of proteins into the intercellular space of the villous stroma. The special structures arising in the cells during the entry and passage of absorbed proteins have been analysed mainly in the rat intestine [8, 12, 15, 21, 22, 23, 33]. Absorption from the intestine of the pig was studied in the jejunum [26, 31] but, since proteins are absorbed in the middle and lower segments of the small intestine [2, 12], these findings were not fully conclusive as to protein absorption in general.

The present studies were carried out on ileal epithelial cells from cats and rats, with the principal aim to clarify (1) whether the intake of protein

by the cells takes place by means of a specialized structure or simply by pinocytosis; and (2) whether there is a difference between the two species which would account for the selective absorption in the rat.

Table 1

Routes of passive immune transfer (after BRAMBELL[5])

Species	Prenatal	Postnatal
Ox, sheep, goat, pig and horse	—	+++ (Gut)
Dog and cat	+	+++ (Gut)
Rat and mouse	+ (Yolk sac)	++ (Gut)
Rabbit and guinea pig	+++ (Yolk sac)	--
Man and rhesus	+++ (Syncytiotrophoblast)	—

Materials and methods

Specimens of ileal epithelium from 15- and 21-day-old rat embryos, newborn non-lactated rats, lactated 4- and 14-day-old rats as well as from cat embryos, non-lactated newborn cats and cats killed 5 and 25 hours after the first sucking have been examined. Rectangular blocks of 1 cu.mm volume were excised from the intestine and fixed first in a 2% glutaraldehyde solution of pH 7.1 in cacodylate buffer at +4°C for 3 hours, then washed in the buffer solution for 18 hours and fixed again in a 1% solution of OsO_4. After dehydration in ethanol, the blocks were embedded in Durcupan ACM. Sections were cut with a LKB III ultrotome and stained with uranyl acetate and lead hydroxide. Electron micrographs were made on Gewaert 23D50 slides in a JEM 6C Electron Microscope, in the 1st Central Electron Microscopy Laboratory of Semmelweis University Medical School. Also 0.5—1 μ thick sections were cut with a Porter-Blum microtome and stained with toluidine blue.

To follow up the individual phases of absorption, a 50 mm long portion of the ileum of a non-lactated 1-hour-old cat was ligated at both ends with the afferent mesenterium left intact and goat colostrum was injected into the isolated segment. Blocks cut from the intestinal mucosa 15, 30 and 60 minutes after administration were processed as described above.

Results

In both species, epithelial cells were examined exclusively in the upper and median thirds of the intestinal villi. As in previous studies [32] the morphological characteristics of absorption had been found to be lacking in the basal third of the villi, viz. in the not fully matured cells of the crypts of Lieberkühn.

A. Rat (selective absorption of antibodies)

In the ileal epithelial cells of the 15-day-old rat embryo, the microvilli had already developed. The cytoplasmic membrane consisted of two components, a 96 Å thick unit membrane and a 20—40 Å thick "fuzzy coat", covering the former. The intercellular space was 100 Å wide, with frequently digit-

ating neighbouring cells. In places the intercellular space was broadened. The terminal web, typical of the epithelial cell of adults, was lacking, its place having been occupied by compressed tubules and vesicles of 230—300 Å thickness. The walls of the latter structures were formed by a 52—60 Å thick unit membrane, the internal surface of which was covered by a 70—90 Å thick granular filamentous layer, particularly conspicuous in the slightly distended ductules (Figs 1, 4). Supranuclearly ribosomes, partly free and partly forming a rosette-like pattern, as well as ergastoplasmic ducts and mitochondria were seen.

In epithelial cells of the 21-day-old embryos and non-lactated newborn rats, the tubules and vesicles formed distended empty ducts in the apical area. Immediately above the nucleus, a so-called supranuclear vacuole surrounded by a unit membrane was seen; it contained a medium electron dense substance and glycogen. Adjacent to the vacuole there were smaller vesicles of similar content (Fig. 2).

In the epithelial cells of the lactated 4- and 14-day-old rats the apical tubules and vesicles were greatly distended, their ductules forming a coherent cavernous system (Figs 3, 5) which, like in the embryonic cells, was surrounded by a 52—60 Å thick unit membrane. The internal surface of that membrane was covered by a 70—90 Å thick granular filamentous layer, resembling the external coat. This tubulo-vesicular system (TVS) communicated directly with the intestinal lumen, in that the tubuli had their outlets at the base of the microvilli, opening into the bottom of the intermicrovillous gaps (Fig. 6). On the other hand, the deeply situated tubules and vesicles communicated with the vacuole which filled almost the entire supranuclear space (Fig. 7). The vesicles contained electron dense, aggregated clumps. At some sites the vesicles were seen to communicate directly with the contents of the supranuclear vacuole (SNV) (Fig. 8). The limiting membranes of the SNV and TVS differed in that the SNV had no granular layer along its internal surface and resembled, therefore, the endoplasmic membrane systems in both structure and width (50—60 Å). The contents of the vacuole consisted of two elements (Figs 3, 7): (1) clumps of material composed of 25—30 Å diameter particles, part of which aggregated peripherally, closely along the wall, and part within the vacuole, chiefly in eccentric position; (2) a net-like, medium electron dense substance seen in the interspaces between the dense aggregates. After sucking, neither glycogen clumps nor the low electron dense granular substance seen in 21-day embryos could be demonstrated in the SNV.

In those cells in which the SNV reached maximum size and its contents were electron lucent, the tubules and vesicles appeared compressed to their original width (350—400 Å). In such instances, a direct communication between the tubules and the intermicrovillous gap or the SNV was infrequent (Figs 16, 18).

B. Cat (nonselective absorption)

In the epithelial cells of the cat embryo (Fig. 10) and of the non-lactated newborn cat (Fig. 9), 330—400 Å wide tubuli and vesicles were present beneath the microvilli. The 52—60 Å thick unit membrane was lined by a 30—40 Å thick granular filamentous layer. Some cells of the newborn cat contained distended vesicles. Supranuclearly there was a large vesicle which contained a loose substance of net-like structure. The limiting membrane of the vacuole was 55—60 Å thick and had no lining.

Four hours after sucking, the constituent elements of the TVS distended to 5—7-fold of their original volume (Fig. 11). They contained 40 Å thick clumps, which filled the deeper situated tubules and vesicles almost completely (Fig. 12). The contents of the latter structures and of the large central vacuole were much more electron dense than those of the superficial ductuli of the apical region, owing perhaps to a greater concentration (Fig. 11).

Twenty-four hours after the first sucking the epithelial cells of the cat were filled by a single large electron dense body which, on the basis of its light microscopic appearance, was termed "central droplet" [32]. Beneath this droplet was situated the nucleus of the cell, tightly squeezed against the basement membrane (Figs 15, 17). With maximum droplet size, there was a compression of the TVS elements to the analogy of that seen in the rat cell, the average width of the ductules having been 370 Å (Figs 19, 20).

In the isolated can ileum, a loose granular structure, with density and clump size corresponding to that of the colostrum, was seen in the TVS elements 15 minutes after the administration; the absorbed colostrum was seen in the TVS and central droplet in a more condensed and more electron dense form (Fig. 14).

→

Fig. 1. Ileal epithelial cell from 15-day-old rat embryo. Note tubules and vesicles (arrow) beneath the microvilli and the many free RNA-clumps and ergastoplasmic ductules in the supranuclear cytoplasm. Mv, microvilli; N, nucleus. ×4,500

Fig. 2. Ileal epithelial cell from 21-day-old rat embryo. Note distension of certain elements of the tubulo-vesicular system (Ts) and the supranuclear vacuole (Sv) which contains glycogen (Gl) and medium electron dense granular substance. N, nucleus; M, mitochondria. ×9,700

Fig. 3. Ileal epithelial cell from 4-day old suckled rat. Beneath the distended TVS (arrow) the cytoplasm is filled by a large SNV (Sv). The SNV contains aggregated granular substance and filaments. Mc, Goblet cell. ×2,400

Fig. 4. Ileal epithelial cell from 15-day-old rat embryo. The elements of the TVS are 230—300 Å wide. The tubules are surrounded by a 52—60 Å thick unit membrane which is lined by a more electron dense granular 70—90 Å thick internal layer (arrow). ×36,800

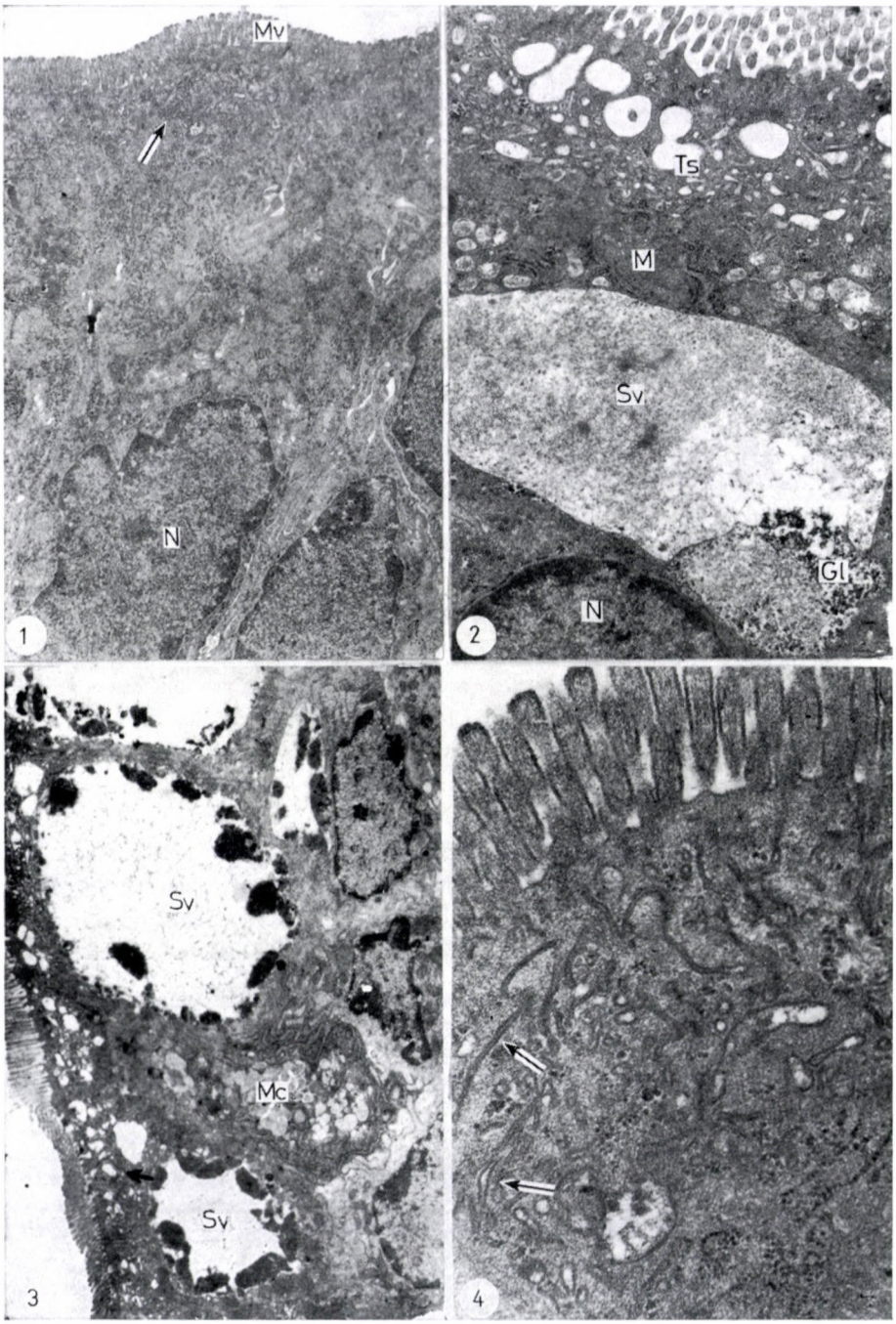
Mv
N
1
Ts
M
Sv
Gl
N
2
Sv
Mc
Sv
3
4

Discussion

It is known from the studies of COMLINE et al. [9, 10] and HILL and HARDY [19] that the ileal cells of certain newborn mammals contain specific structures. In the ileal epithelial cells of calves, homogeneous eosinophilic droplets are seen in the first three days of extrauterine life, which tend to disappear along with the absorption of colostrum. COMLINE et al. [9, 10, 11] believed these structures to be related to globulin absorption. BRAMBELL [5] reviewed the literary data stating that newborn rats, kids, lambs, dogs and kitten were able to absorb from their intestine protein molecules in undigested form. This was verified by immunomorphological methods by PAYNE and MARSH [28] and later by LECCE [24]. The studies performed by LECCE [24] by means of metabolic inhibitors indicated absorption to be an energy requiring active transport process.

The morphological dissimilarity of the ileal epithelial cells of newborn and adult animals has been clarified electronmicroscopically during the last decade. In the course of these examinations an attempt was made to answer the first question posed in the introduction of this paper, viz. how the incorporation of immunoglobulin by the cell is taking place. In the mouse and the rat, CLARK [8] found the vesicular membranes of the apical cytoplams to communicate with the cytoplasmic membrane and demonstrated absorbed protein and clumps of colloidal gold and iron in the vesicles. On this basis, he concluded that the cell engulfed the protein by pinocytosis and this then was concentrated in the SNV. The colloidal iron and gold clumps did not leave the cells, while the gamma globulin passed out of them to enter the lymph circulation, as noted also by others [14, 28]. Based on rat experiments, KRAEHENBUHL et al. [21, 22, 23] explained the intestinal absorption of protein by pinocytosis. RUBIN [29] arrived at the same conclusion from experiments on dogs.

In contrast, GRANEY [15] and WISSIG and GRANEY [33] stated that protein uptake occurred through a specialized membrane system rather than by pinocytosis. Examining the intestinal epithelial cells of the newborn nonlactated rat they found an apically situated system of tubules and vesicles with

→

Figs 5—8. Details of ileal epithelial cell from 4-day-old rat.

Fig. 5. The tubules and vesicles had distended to 1—2000 Å width. The arrow points to the communication between tubule and intestinal lumen. Sv, supranuclear vacuole; M, mitochondria. ×9,800

Fig. 6. The tubular limiting membrane of the TVS is continuous with the cytoplasmic membrane (arrow). ×34,500

Fig. 7. Direct communication (arrow) between SNV and a larger vesicle (V) of the TVS. ×33,400

Fig. 8. Communication (arrow) between the granular contents of the SNV and of a vesicle of the TVS. ×16,200

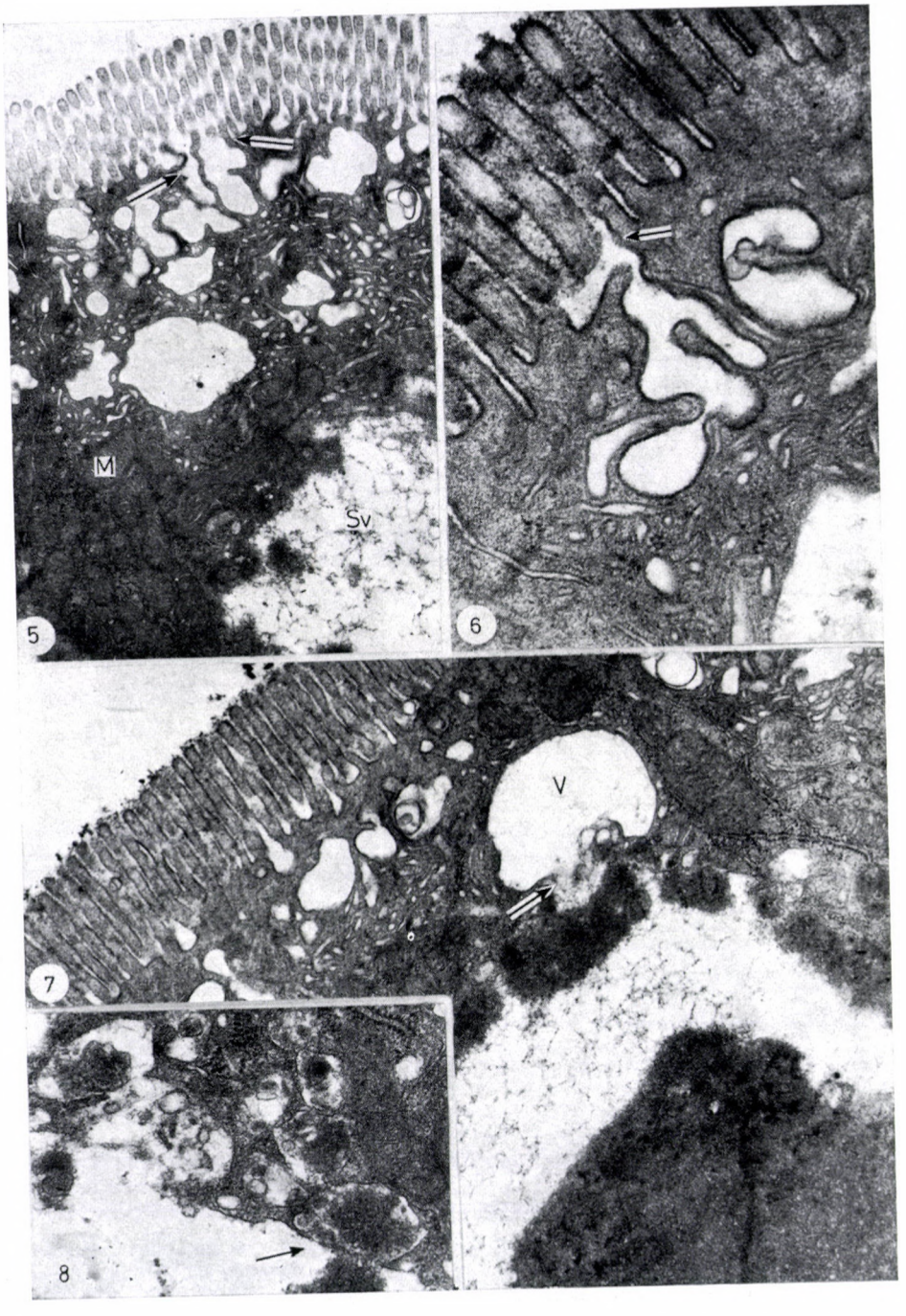
M
Sv
5
6
V
7
8

flat lumina which distended after lactation and appeared to communicate with both the intestinal lumen and the SNV. Consistent conclusions were drawn by CORNELL and PADYKULA [12]; they demonstrated by enzyme histochemical methods strong acid phosphatase and nonspecific esterase activities in the TVS and SNV, termed by them superficial vacuoles and dense droplets, respectively. On this basis, they regarded these structures as "phagolysosomes". Furthermore, they demonstrated in the SNV also thiamine-pyrophosphatase, interpreted by them as suggestive of the structure's relationship with the Golgi apparatus.

The present findings, too, are in support of the existence of a system specialized for protein uptake. Previous light microscopic examinations [32] disclosed that a vesicular system had been present prior to lactation which filled up with a basophilic substance in the course of colostrum absorption. Electron microscopic studies of intestinal epithelium from rat and cat embryos have shown these vesicles to be unrelated to pinocytosis, as (i) elements of the TVS were demonstrable in a compressed state already in the embryonic cells. Immediately before birth as well as in the newborn nonlactated animals, part of the tubules had distended as if in preparation for the intake of colostrum from the intestinal lumen. The SNV, which stores the protein taken up by the cell, was also present prior to the first sucking. On the other hand, (ii) the fact that the limiting membranes of the tubules and vesicles represented a transitory type between the various membrane systems is also in support of the existence of a preformed system. The thickness of the unit membrane of the TVS corresponds to that of the endoplasmic membranes, whereas its structure (coat + unit membrane) to that of the exoplasmic membranes [30]. The limiting membranes of the SNV or central drop resemble the Golgi membranes in both structure and thickness thus, in agreement with CORNELL and PADYKULA [12] we, too, believe the former membranes to derive from the Golgi

→

Fig. 9. Detail of ileal epithelial cell from newborn nonlactated cat. Most tubules and vesicles (arrow) between the microvilli and the large vacuole are flat (350 Å thick). ×15,300

Fig. 10. Detail of ileal epithelium from cat embryo. Above the nucleus there is a large vacuole (arrow). Toluidine blue, ×650

Fig. 11. Detail of ileal epithelial cell from 4-hour-old suckled cat. The distended tubuli of the TVS open into the intermicrovillous space (arrow). The granular contents of the tubules are less electron dense in the superficial structures and more electron dense in the deeper situated ones. ×17,100

Fig. 12. Detail of ileal epithelial cell from 4-hour-old suckled cat. The limiting membrane of the elements of the TVS is 50—60 Å thick; along its internal surface there is a 70—90 Å thick granular layer (arrow). ×40,000

Fig. 13. Epithelial cell from isolated ileal portion of a baby cat 15 minutes after the administration of goat colostrum. Clumps of colostrum (C) are seen in the intestinal lumen and the distended apical tubules and vesicles contain a granular substance of similar density. ×16,000

Fig. 14. Epithelial cell from isolated ileal portion of a baby cat. 60 minutes after the administration of goat colostrum, the contents of the vacuole are electron lucent. Communication between a tubule and the intestinal lumen (arrow) is well visible. ×19,400

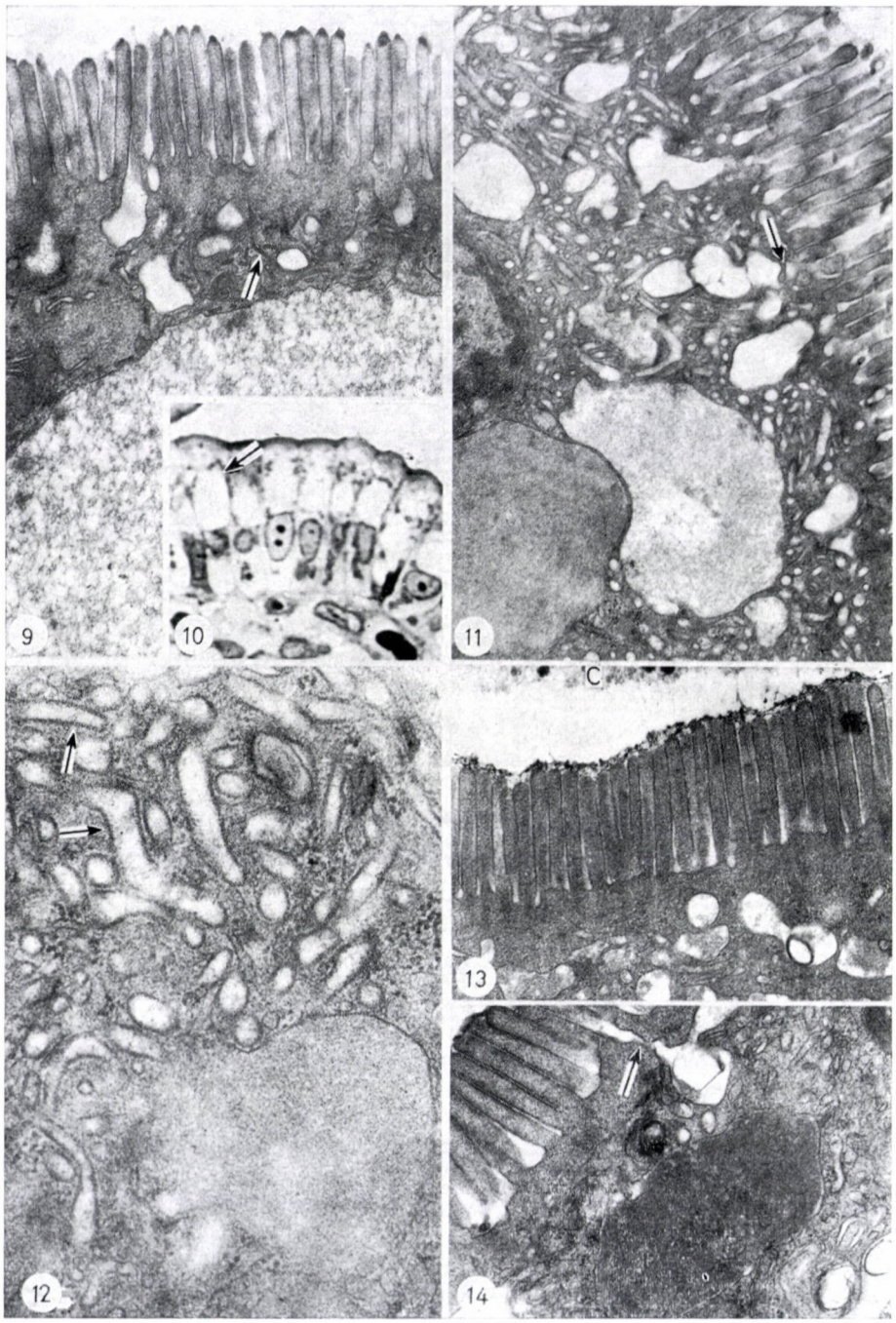
9
10
11
12
C
13
14

apparatus. (iii) In addition to the above evidences of the existence of a TVS, literary data on the rate of absorption also suggest the presence of a preformed system. It is known that while at birth the serum antibody level of the newborn rat amounts to one sixteenth of the maternal level, it reaches the latter on the second or third postnatal day [7]. Also, antibodies absorbed from the colostrum are demonstrable in the blood of the baby rat within 30 minutes after sucking [8].

As to the second question posed in the introduction, viz. whether there is a morphologically demonstrable difference between the selective and non-selective absorption types, the following may be stated. The light microscopic structure of the intestinal epithelial cells of the two groups was different. Cells from the selective rat and the mouse contained a SNV within which there was an eosinophilic body in eccentric position [2, 3, 12]. In contrast, in the ileal cells of non-selective animals, the absorbed protein appeared in the form of a homogeneous central droplet [1, 9, 19, 25, 32]. Electronmicroscopically, the morphology of protein incorporation showed no fundamental difference in the two groups, whereas the sites of accumulation of the incorporated proteins were dissimilar, consistently with the light microscopic findings. In the rat cells, the SNV was inhomogeneous, showing eccentric and peripheral aggregations of a substance, with electron lucent filamentous structures in the interspaces. In the cat cells, in contrast, the entire central droplet was filled by a uniformly distributed substance, corresponding in shape and density to the clumps of colostrum. As to the rat and mouse, selectivity is generally believed to take effect not so much at the intake as at the transfer of proteins [12] by the intestinal epithelial cells. BRAMBELL et al. [7] thought the selectivity to be related to certain receptors which, by linking with proteins of appropriate configuration, prevent their being hydrolysed. According to BRAMBELL [6] and MORRIS [27], this binding takes place at the periphery of the SNV, under involvement of the limiting membrane. Enzyme histochemical examinations suggested these configurations to represent phagolysosomes [12, 13], while the biochemical examinations by BAINTNER and JUHÁSZ [1] showed that in the intestinal epithelial cells of the suckled newborn rat acid proteolytic activity was negligible and the alkaline activity seemed to be related to the pancreas.

→

Fig. 15. Detail of ileal cell from 25-hour-old suckled cat. Above the nucleus there is a homogeneous electron dense structure. Ic, intercellular space; SC, stromal cell. ×5,500

Fig. 16. Ileal epithelium from 14-day-old suckled rat. Above the nucleus there are vacuoles with inclusion bodies and above the vacuoles there are small vesicles. Toluidine blue, ×580

Fig. 17. Ileum of 24-hour-old suckled cat. The epithelial cells are filled by large protein droplets (P). Mc, goblet cell. Toluidine blue, ×750

Fig. 18. Detail of ileal cell from 14-day-old rat. The elements of the TVS are 400 Å wide. Sv, supranuclear vacuole. × 21,600

Figs. 19—20. Detail of ileal cell from 24-hour-old suckled cat. The elements of the TVS, situated above the central drop (C), are 370 Å wide. (Fig. 19, ×18,000; Fig. 20, ×30,000)


15

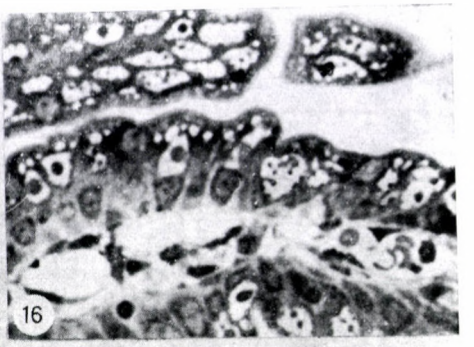
16

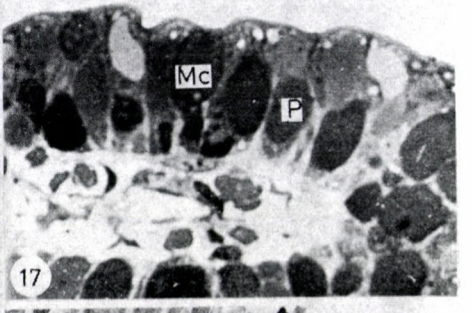
Mc
P
17


Sv
18


C
19


C
20

GRAVES [16] reported on the blocking of colostrum absorption by previous feeding of milk. Our observations may in part account for this finding. At the stage when the central drop of enterocytes was almost entirely filled by colostral proteins, the TVS appeared to be inactive. We suppose that beyond a given degree of saturation, the SNV or the central drop may mechanically compress the TVS, inhibiting thereby the uptake of further protein.

*

Acknowledgements. We are indebted to Miss K. GYÖKÖSSY, Miss GY. TÓTH and Mrs. K. KOTTÁSZ for technical assistance.

REFERENCES

1. BAINTNER, K. JR., JUHÁSZ, S.: (1971) Acta physiol. Acad. Sci. Hung. **40,** 179. — 2. BAINTNER, K. JR., VERESS, B.: (1967a) Magy. Állatorv. Lapja **22,** 97. — 3. BAINTNER, K. JR., VERESS, B.: (1967b) Nature (Lond.) **215,** 774. — 4. BAINTNER, K. JR., VERESS, B.: (1970) Experientia (Basel) **15,** 54. — 5. BRAMBELL, F. W. R.: (1958) Biol. Rev. (Cambridge) **33,** 488. — 6. BRAMBELL, F. W. R.: (1966) Lancet, **2,** 1087. — 7. BRAMBELL, F. W. R., HALLIDAY, R., MORRIS, I. G.: (1958) Proc. roy. Soc. Ser. B. **149,** 1. — 8. CLARK, S. L. JR.: (1959) Biophys. biochem. Cytol. **5,** 41. — 9. COMLINE, R. S.: (1951) Nature (Lond.) **168,** 84. — 10. COMLINE, R. S., ROBERTS, H. E., TITCHEN, D. A.: (1951) Nature (Lond.) **167,** 561. — 11. COMLINE, R. S., POMEROY, R. W., TITCHEN, D. A.: (1953) J. Physiol. biochem. Cytol. **122,** 6 P. — 12. CORNELL, R., PADYKULA, H. A.: (1965) Anat. Rec. **151,** 339. — 13. CORNELL, R., PADYKULA, H. A.: (1969) Amer. J. Anat. **125,** 291. — 14. DEUTSCH, H. F., SMITH, W. R.: (1957) Amer. J. Physiol. **191,** 271. — 15. GRANEY, D. O.: (1968) Amer. J. Anat. **123,** 227. — 16. GRAVES, H. J.: (1963) Immunology **91,** 251. — 17. HALLIDAY, R.: (1955a) Proc. roy. Soc. Ser. B, **143,** 408. — 18. HALLIDAY, R.: (1955b) Proc. Roy. Soc. Ser. B, **144,** 427. — 19. HILL, K. J., HARDY, W. S.: (1956) Nature (Lond.) **178,** 1353. — 20. JORDAN, S. M., MORGAN, E. H.: (1968) Aust. J. exp. Biol. med. Sci. **46,** 465. — 21. KRAEHENBUHL, J.-P., GLOOR, E., BLANC, B.: (1966) Z. Zellforsch. **70,** 209. — 22. KRAEHENBUHL, J.-P.: (1967) Z. Zellforsch. **76,** 170. — 23. KRAEHENBUHL, J.-P., CAMPICHE, M. A.: (1969) J. Cell Biol. **42,** 345. — 24. LECCE, J. G.: (1966) J. Physiol. biochem. Cytol. **184,** 594. — 25. LECCE, J. G., MATRONE, G., MORGAN, D. O.: (1961) J. Nutr. **73,** 158. — 26. MATTISSON, A. G. M., KARLSSON, B. W.: (1966) Ark. Zool. **18,** 575. — 27. MORRIS, I. G.: (1964) Proc. Roy. Soc. Ser. B. **160,** 276. — 28. PAYNE, L. C., MARSH, C.: (1962) Fed. Proc. **21,** 909. — 29. RUBIN, C. D.: (1966) Gastroenterology, **50,** 65. — 30. RÖHLICH, P.: (1968) Magy. Tud. Akad. Biol. Oszt. Közl. **11,** 151. — 31. SIBALIN, M., BJÖRKMAN, N.: (1966) Exp. Cell Res. **44,** 165. — 32. VERESS, B., BAINTNER, K. JR.: (1970) Acta morph. Acad. Sci. hung. **18,** 237. — 33. WISSIG, S., GRANEY, D. O.: (1968) J. Cell Biol. **39,** 564.

RESORPTION DES KOLOSTRUMS BEI RATTEN UND KATZEN. VERGLEICHENDE ELEKTRONENMIKROSKOPISCHE UNTERSUCHUNG

B. VERESS und K. BAINTNER Jun.

Verfasser untersuchen mit der Eiweißresorption zusammenhängende Strukturen in den Epithelialzellen des Ileums von jungen Ratten und Kätzchen. Die Epithelialzellen des Darmes von Embryonen und neugeborenen Tieren enthalten gleicherweise im apikalen Teil des Zytoplasmas ein Tubular-vesikularsystem (TVS). Die das TVS abgrenzende Membrane besitzt eine charakteristische Struktur, insofern sie aus einer »unit membrane« von 56 Å Dicke und einer 80 Å dicken Schicht besteht und somit einen Übergangstyp zwischen den exo- und endoplasmatischen Membransystemen darstellt. Die Tubuli münden in den Spalten zwischen den Mikrozotten und kommunizieren miteinander sowie mit der supranuklear befindlichen großen Vakuole (SNV). Die SNV dienen wahrscheinlich zur Deponierung der aufgenommenen Eiweiße. In den Epithelialzellen des Rattendarmes besitzen die SNV immer

den Charakter von Vakuolen; der Inhalt besteht zum Teil aus exzentrisch aggregiertem Stoff, zum Teil aus faserigen Strukturen. In den Epithelialzellen des Darmes junger Katzen dagegen, bilden die Vakuolen einen sog. zentralen Tropfen, welcher aus homogenem Stoff besteht. Mit dem Fortschritt der Eiweißresorption füllt der zentrale Tropfen fast das ganze Zytoplasma aus und drückt gleichzeitig die Elemente des TVS zusammen.

Unter den gegenwärtigen Bedingungen fanden wir keinen Unterschied zwischen den TVS der Eiweiß selektiv resorbierenden Ratten und der nicht selektiv resorbierenden Katzen. Anscheinend wird die Selektierung der Eiweiße nicht so sehr bei ihrer Aufnahme in die Darmepithelzellen, wie bei ihrem Transit durch die Zellen verwirklicht.

ВСАСЫВАНИЕ МОЛОЗИВА У КРЫС И У КОШЕК. СРАВНИТЕЛЬНОЕ ЭЛЕКТРОННОМИКРОСКОПИЧЕСКОЕ ИССЛЕДОВАНИЕ

Б. ВЕРЕШ и К. БАИНТНЕР мл.

Авторы исследовали связанные со всасыванием белка структуры в эпителиальных клетках тощей кишки молодых крыс и котят. Эпителиальные клетки зародышей и новорожденных животных содержат в одинаковой степени в апикальной части цитоплазмы тубулярно-везикулярную систему (ТВС). Отграничивающая ТВС перепонка обладает характерной структурой, поскольку она состоит из «единой перепонки» толщиной в 56 Å и из слоя толщиной в 80 Å и таким образом представляет переходную форму между экзо- и эндоплазматическими мембранными системами. Канальцы оканчиваются в щелях между микроворсинками и сообщаются между собой, а также с надядерно расположенными большими вакуолями (НБВ). НБВ, вероятно, служат депонированию принятых белков. В эпителиальных клетках кишки крыс НБВ всегда носят характер вакуолей; содержание состоит отчасти из эксцентрически агрегированного вещества, отчасти же из волокнистых структур. В эпителиальных клетках кишки котят же вакуоли образовывают так наз. центральную каплю, состоящую из гомогенного вещества. С развитием всасывания белков центральная капля заполняет почти всю цитоплазму и одновременно с этим сжимает элементы ТВС.

При данных условиях авторы не нашли разницы между ТВС избирательно всасывающих белок крыс и неизбирательно всасывающих белок кошек. Очевидно селекция белков осуществляется не столько при их поступлении в эпителиальные клетки кишки, как при их прохождении через них.

Dr. Béla VERESS, II. Kórbonctani Intézet,
Budapest IX., Üllői út 93, Hungary
Dr. Károly BAINTNER, Állattenyésztési Kutató Intézet,
Budapest II., Kitaibel P. u. 4, Hungary

Acta Morphologica Acad. Sci. Hung. 19 (4), pp. 349—362, 1971

Institute of Forensic Medicine (Director: Prof. Dr. E. Somogyi) and Fourth Department of Surgery (Director: Prof. Dr. J. Kudász), Semmelweis University Medical School, Budapest

EFFECT OF IMMUNOSUPPRESSIVE AGENTS ON THE TISSUE REACTION AROUND THE PACEMAKER ELECTRODE

E. Somogyi, T. Varga, P. Sótonyi, F. Solti, Z. Szabó, F. Rényi-Vámos, I. Földes, and S. Várkonyi

(Received July 1, 1971)

The effect of anti-lymphocytic serum (ALS), prednisone and 6-mercaptopurine was investigated on the tissue reaction induced by the implantation of pacemaker electrodes in dogs. Under the effect of ALS the perifocal infiltration as well as the consecutive cicatrization markedly diminished. After prednisone treatment, the formation of connective tissue fibres was slightly repressed and changes of degenerative character appeared in the fibroblasts. Upon the influence of 6-mercaptopurine there was no considerable change. The direct mechanical damage was identical in all the cases. The morphological alterations may serve as a basis for the favourable clinical effect of the immunosuppressive agents.

Prolonged electric stimulation of the heart is applied more and more frequently in the early stage of cardiac infarction as well as in the after-treatment of heart operations. Apart from benefits, the method may lead to some complications. The threshold of cardiac response increases for several days after the implantation, then after 1—2 weeks it becomes constant [14, 17]. Nevertheless, it may happen that the threshold reaches such a high level that the electric power of the apparatus becomes insufficient to induce a stimulus. This is the so-called exit-block. In these cases necrosis, sterile inflammation, then scarring are observed around the electrode [3, 7, 13, 19]. Obviously, a close relationship may be assumed between the raised threshold and the extent of the inflammatory reaction around the electrode. We have reported previously on the alterations appearing after the implantation of pacemaker electrodes of different types [25, 28, 30]; the aim of the present study was to investigate the influence of drugs on the tissue reaction.

Material and methods

The investigations were carried out on 20 mongrel dogs of 10—15 kg body weight belonging to both sexes. Under hexobarbitalether-NO_2 anaesthesia, left thoracotomy was performed, the pericardium was opened and a flat electrode of the Elema—Schönander 567 type was fixed to the surface of the left ventricle. Stimulation was carried out by means of Schönander—Elema 139 apparatus working at constant frequency. The successful stimulation was controlled by ECG.

Five animals served as untreated controls and were bled on the 3rd, 5th, 6th, 8th and 10th days, respectively, following the operation.

Six dogs were treated with 0.4 ml/kg ALS (Human) intramuscularly every second day on four occasions before the operation and on the day of electrode implantation with 1 ml/kg. The animals were killed on the 3rd, 4th, 6th and 8th days and two of them on the 10th day subsequent to the operation.

Another group of six animals received four times 25 mg prednisone intravenously once before, and every day after the operation. They were killed two by two on the 4th, 7th and 9th days.

Three of the animals received 1 mg/kg of 6-mercaptopurine on the day of implantation and then daily subsequent to the intervention; they were killed on the 1st, 3rd and 4th days. During suppuration they could not have survived longer.

Blood counts and body temperature were recorded before and after the treatments. Specimens obtained from the heart were studied. For electronmicroscopy the material was fixed in formaline buffered according to Holt, then in 1% OsO_4, then dehydrated and embedded into Araldite. The ultrathin sections were stained with uranyl-acetate and lead citrate and studied by a Hitachi type HU 10 electronmicroscope.

Results

Control group

On the 3rd day after the implantation, profound necrosis and inflammation were found under the electrode and in the environment of the suture. In the uppermost layer of the change the pericardium was thickened with a great amount of fibrin and numerous cell-ghosts in it. The inflammatory reaction spread into the surrounding musculature between the muscle fibres (Figs 1 and 2). Round cells with an intensely pyroninophilic cytoplasm were dispersed in the granulation tissue. On the 5th day, fibroblasts appeared and there was a great amount of freshly synthetized collagen between the muscle fibres (Fig. 3). Giant cellst of foreign body character were observed on the 10th day. The muscles displayed necrosis and discoid degeneration in the environment of the suture and the electrode, with oedema predominating in the marginal regions. In some places sarcolysis could be seen whereas elsewhere only pearl-strings of vacuoles appeared (Figs 1 and 2). Signs of regeneration occurred in the marginal muscle fibres on the 8th and 10th days (Fig. 3).

Electronmicroscopically, the above cells of inflammatory as well as macrophage type were found, under the electrode in the central region of the change, together with fibrin deposition (Fig. 4). The muscle fibres are degenerated, the sarcolemma is disrupted or has disappeared, the mitochondria are damaged (Figs 5 and 6). The myofilaments have lost their contact with the intercalar discs (Fig. 7). Further from the centre the sarcolemma is separated from the muscle fibres, the mitochondria are swollen and lipid granules accumulate in the vicinity of the sarcotubular system (Fig. 8). Phagocytosis of the destroyed muscle fibres was observed at later stages (Fig. 9). The collagen displaying a regular cross striation appeared on the 5th and 6th days. Fibroblasts and fibrocytes of intact structure as well as newly formed capillaries

are seen in great numbers in the granulation tissue (Figs 10 and 11). A crystal-like substance showing a regular lattice structure was found in the wall of the capillaries in two animals in both the operated and the intact muscle areas (Fig. 12).



Fig. 1. Necrosis of heart muscles, sterile inflammatory infiltration appearing three days after electrode implantation. Half-thin section, toluidine-blue staining



Fig. 2. The infiltration propagates between the intact muscle fibres. Myocytolysis at the border of the necrosis. Hematoxylin-eosin

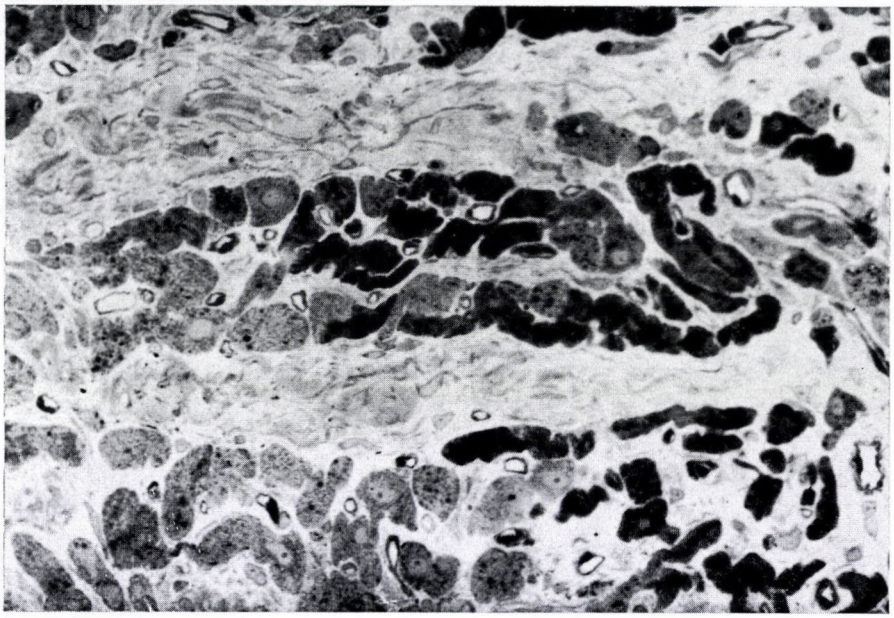

Fig. 3. Large amount of collagen and signs of regeneration of muscle fibres 10 days after electrode implantation. Half-thin section, toluidine-blue staining

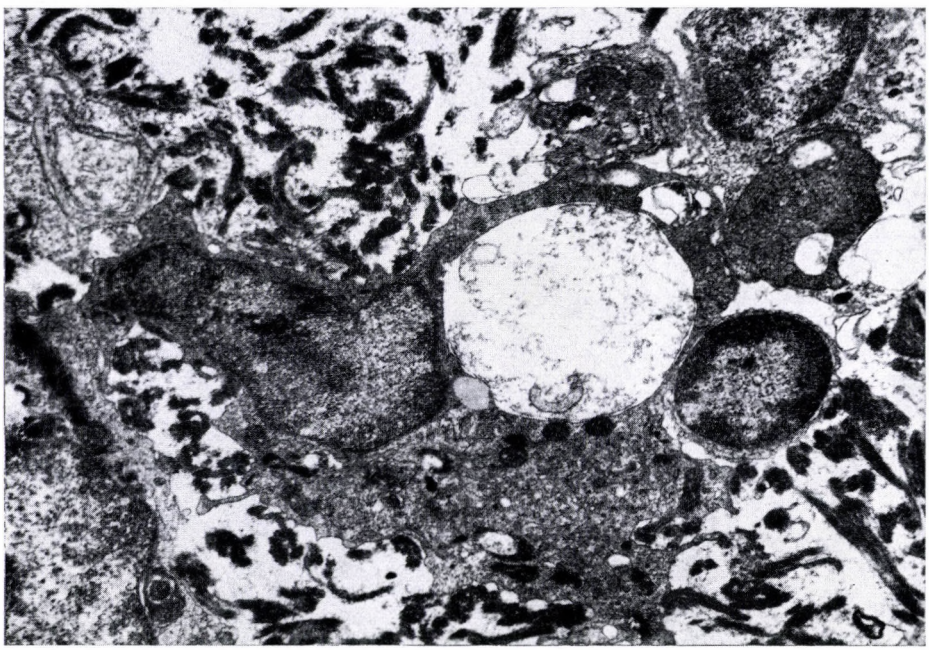

Fig. 4. Inflammatory elements of regular structure under the electrode, deposition of fibrin. (×7800)

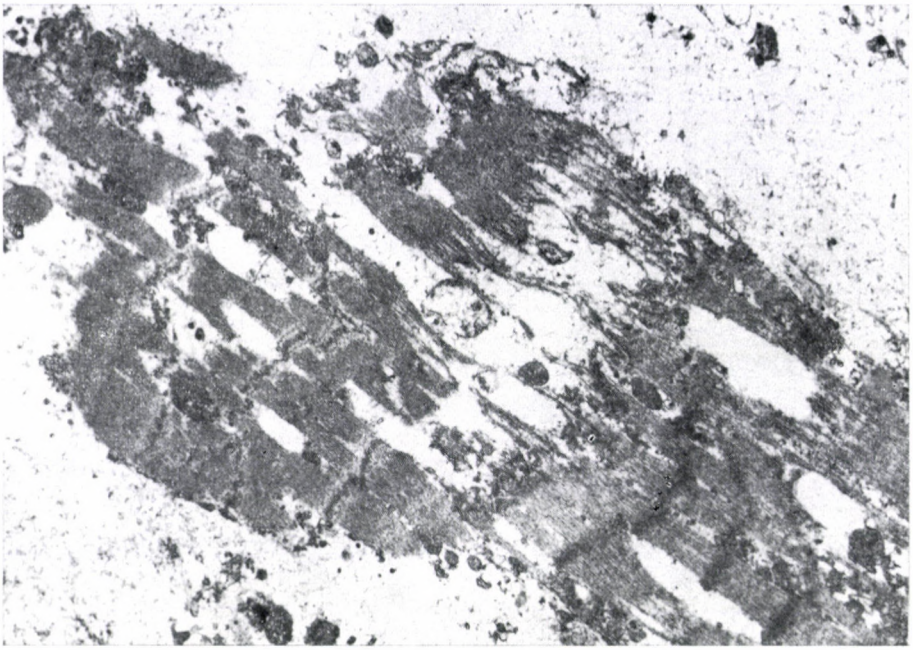

Fig. 5. The muscle fibres are damaged in the area of necrosis, the myofilaments are fragmented (×7800)



Fig. 6. The outer and internal membranes of mitochondria are fragmented in the necrotic areas, a dense substance is accumulating in the mitochondrial matrix. (×22,800)

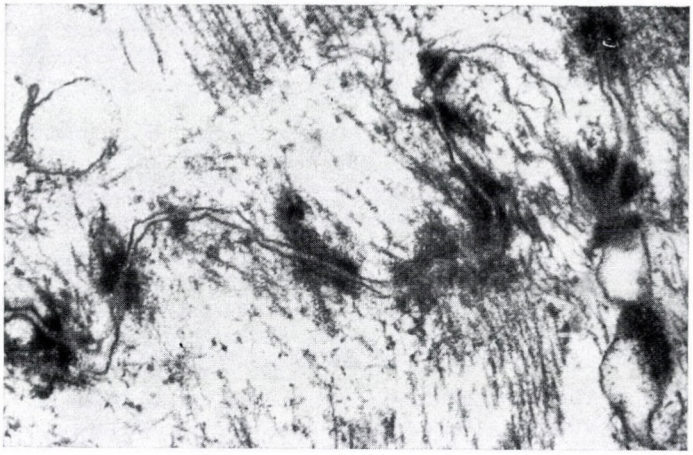

Fig. 7. The myofilaments have lost their contact with the intercalar disc displaying a comparatively intact structure. (×39,600)

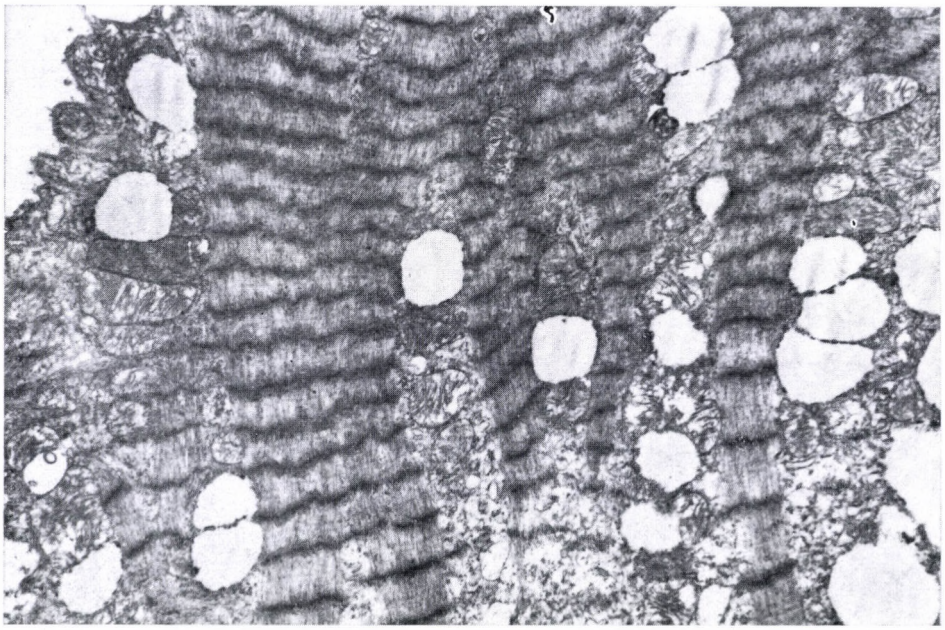

Fig. 8. The myofilaments are intact at some distance from the electrode, the mitochondria are swollen, lipid granules have accumulated in their environment. (×7800)

ALS-treated group

The changes occurring under the electrode were of the same character as in the control group. In spite of a 30% decrease in the peripheral lymphocyte count, lymphocytes as well as round cells with pyroninophilic cytoplasm were found in the infiltrations. A conspicuous light-microscopic difference was that the inflammatory reaction was of lesser extent, localized to the environment of the damaged area and did not spread over to the surrounding musculature (Fig. 13). Thus, the above signs of a secondary lesion are absent in the surround-

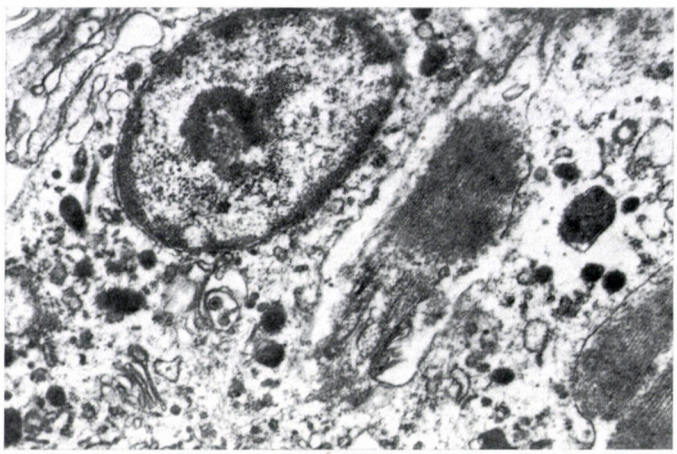

Fig. 9. A membrane limited muscle fibre phagocyted by a macrophage. (×18,000)

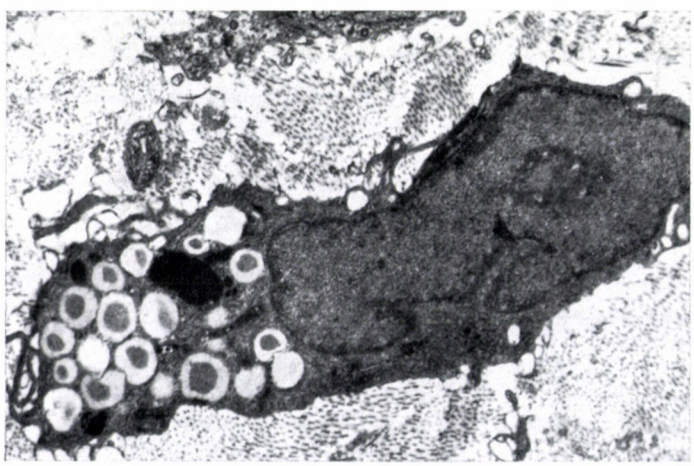

Fig. 10. Large amount of collagen and intact fibroblasts in the granulations tissue. (×12,000)

ing musculature. Electronmicroscopy revealed practically the same picture as in the controls, the difference in the secondary lesion was also observed. The crystal-like substance in the wall of capillaries was seen in 2 animals

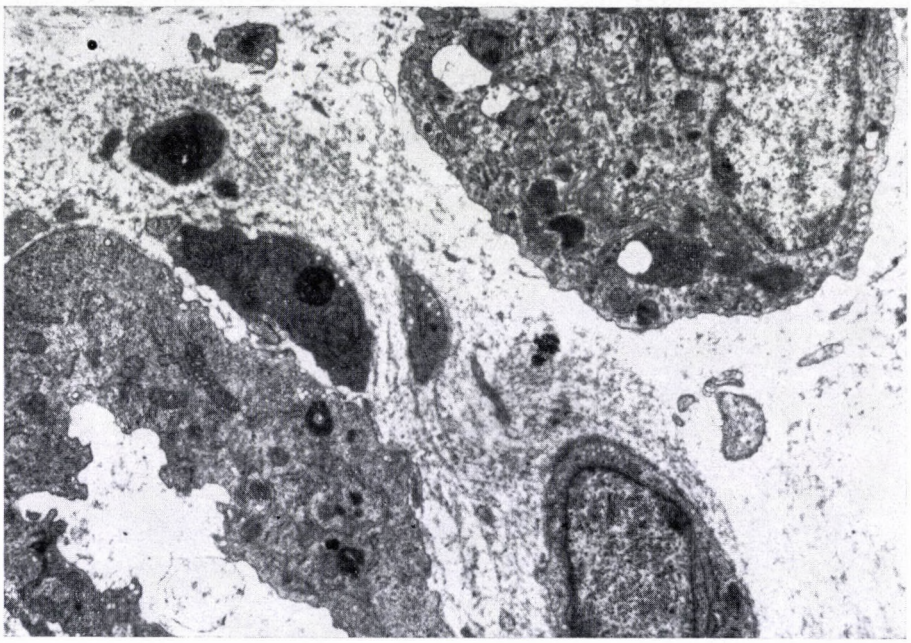

Fig. 11. Newly formed capillary, pericytes and connective tissue elements. (×7800)

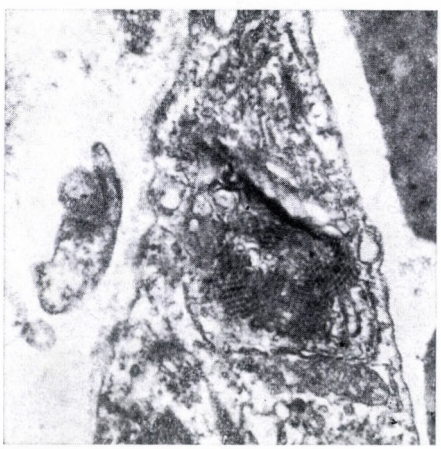

Fig. 12. Crystal-like substance in capillary wall. (×33,000)

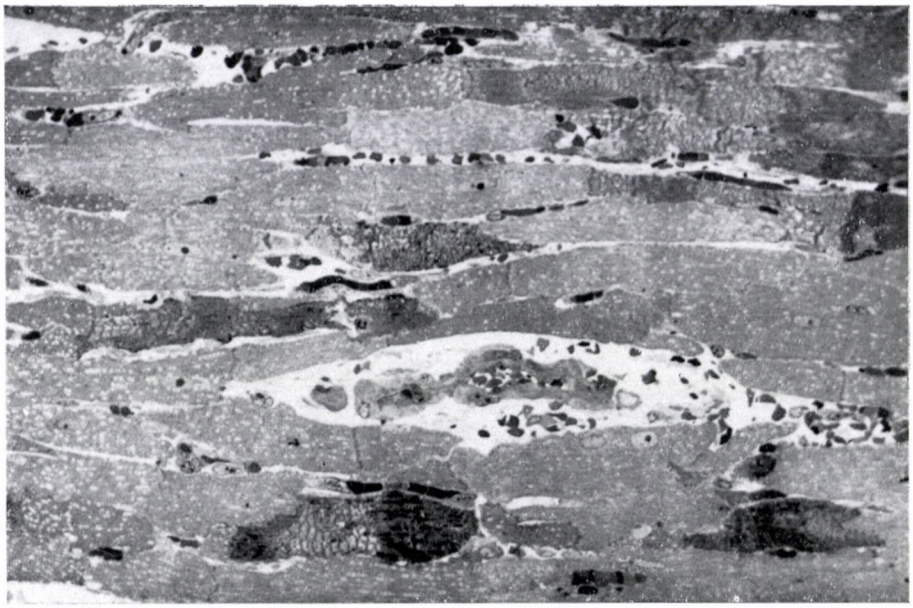

Fig. 13. In animals treated with ALS, hardly any inflammatory infiltration between the necrotizing muscle fibres. Toluidine-blue staining, half-thin section

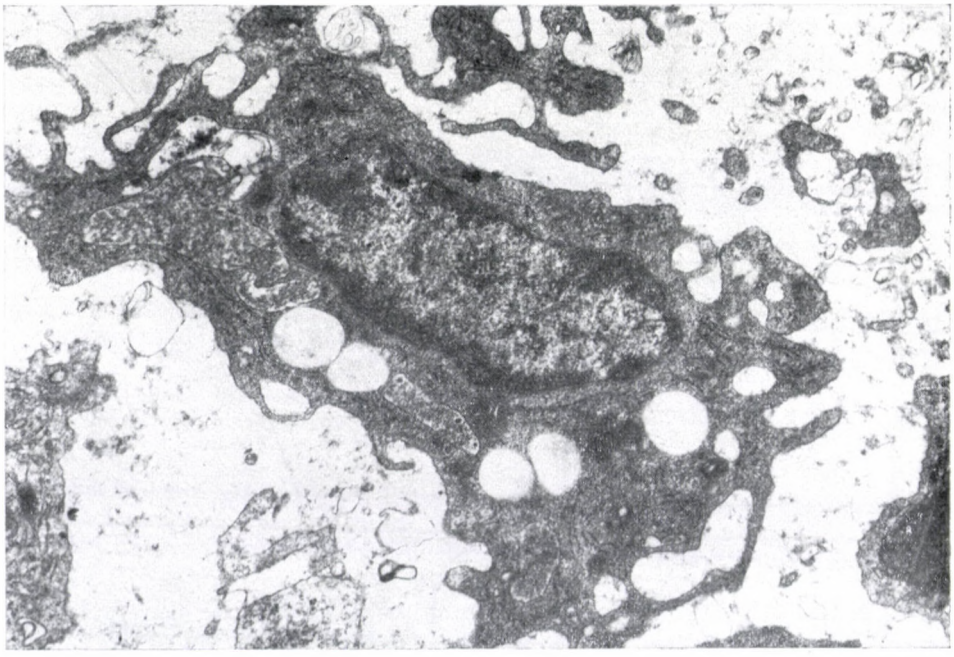

Fig. 14. A substance with regular periodicity in the cytoplasm of a histiocyte. (×12,000)

of this group, too. It occurred only in this group that a substance of 230 Å periodicity had accumulated in the cytoplasm of histiocytes, around which sometimes even a membrane was observed (Figs 14 and 15).

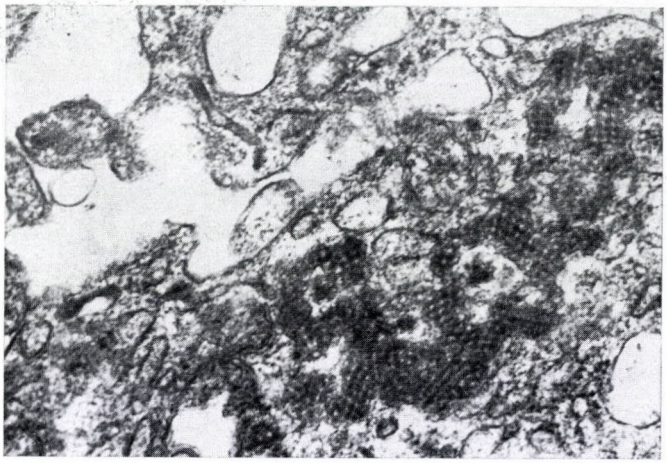

Fig. 15. The periodicity is of about 230 Å; it is surrounded by a membrane. (×48,000)



Fig. 16. Prednisone-treated animal. Scarce fibril formation in the infiltration on the 9th day in di-Adreson-treated animal. Van-Gieson's stain

Prednisone-treated group

On the 4th day of treatment the animals showed the same picture as the controls. Nevertheless, the fibroblasts and fibrocytes produced less collagen fibres than in the controls. The lysosomes in the cytoplasm of fibroblasts are

larger and more frequent than usually and the endoplasmic reticulum was enlarged and empty (Fig. 17). Crystals in the capillary walls occurred in one animal of this group.

6-mercaptopurine-treated group

Both light electron microscopy revealed the same picture as in the controls. The occurrence of capillary crystals was observed in one animal.

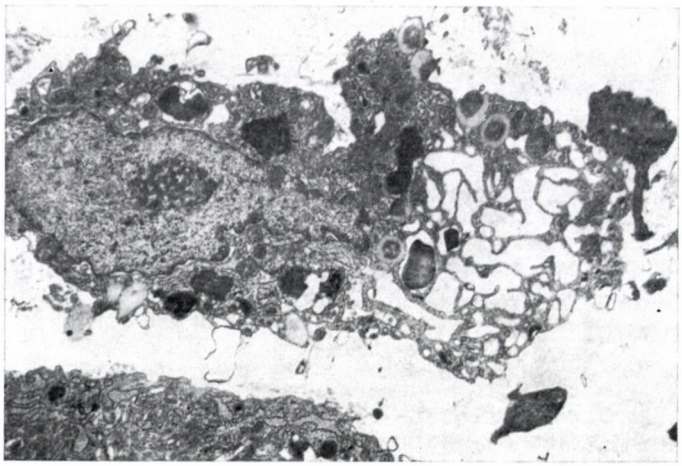

Fig. 17. Collagen is hardly to be found between the cells, the fibroblasts contain many lysosomal elements, the endoplasmic reticulum is enlarged. (×6 000)

Discussion

The tissue reaction to pacemaker electrode implantation has been studied by several authors [3, 7, 13, 19] who reported on progressive fibrosis as well as muscular destruction. In previous studies we have observed in detail the changes around the different pacemaker electrodes [25, 28, 30]. The present control group displayed lesions essentially corresponding to those. In all cases in the mechanically damaged areas a discoid degeneration of the muscle fibres surrounded by a diffuse, sterile inflammatory reaction was observed. Oedema and hypoxic lesions, i.e. fibrillolysis, oedema and lipid degeneration of the musculature were predominant in the perifocal regions. In the development of such changes, first of all the mechanical effect may have some significance. The process of degeneration is similar to those occurring under the effect of other myocardial lesions [4, 8, 9, 15, 21, 27].

Few experiments have been carried out to test the effect of drugs on the tissue reaction induced by pacemaker implantation and on the changes

of the stimulus threshold. PRESTON et al. [26] observed a decrease of the threshold after prednisolone treatment, and an increase after aldosterone treatment. According to KÜBLER and SOWTON [18], the threshold increases by about 40% in patients with a pacemaker under the influence of beta blockers. MOWRY et al. [24] as well as JUDGE et al. [17] observed the disappearance of the exit-block as a result of steroid therapy. We have shown previously that in the rat heart ALS decreased significantly the extent of the necrosis induced by coronary ligature [10]. This was the reason why we have investigated the effect of immunosuppressive agents.

The degenerative lesions observed in the region of mechanical injury even in the control group came into being in every case. Subsequent to the ALS treatment, the peripheral lymphocyte number count decreased, the perifocal infiltration was reduced and accordingly the secondary lesions of the musculature and the consecutive cicatrization were slighter. On prednisone treatment the necrosis as well as the surrounding inflammation were of the same extent as in the controls; collagen formation was, however, prolonged and less intense and degenerative lesions were observed in the fibroblasts. There was no considerable difference after 6-mercaptopurine treatment as compared with the controls.

The exact mode of action of ALS is not known, only that it inhibits both the afferent and the efferent sides of the immunological reaction [5, 7, 21, 32]. It has been revealed by immunofluorescent investigations that the serum does not penetrate into the follicles, thus it most probably does not influence the immunological memory [6]. The therapeutic observations agree with this statement in that the most intense effect can be achieved by a previous administration of the antigenic stimulus [16, 29]. The serum used in our experiments proved to be effective *in vitro* and its effect *in vivo* was evidenced by the decrease in the peripheral lymphocyte count. In spite of this fact, intact lymphocytes and round cells with pyroninophilic cytoplasm were observed in the inflammatory tissue. Thus, first of all the decreased responsiveness following the blocking of the immunological apparatus might be responsible for the diminution of the infiltration. However, one cannot deny the possibility of an autoantigenic inhibition similar to the post-cardiotomy syndrome.

Upon the influence of glycocorticoids the amount of oedema fluid markedly decreased in the first phase of inflammation and so did later its hydroxyproline and hexoseamine content. Biochemical investigations revealed a decreased activity of the Krebs cycle [20]. The incorporation of sulphurous amino acids and the synthesis of chondroitin-sulphate decreases [31]. Morphological studies showed a restriction of collagen formation [23]. Their membrane-stabilizing effect is also well known on the lysosomes [33]. We could demonstrate a restriction of collagen formation and a degeneration of fibroblasts after the implantation of pacemakers under the effect of glycocorticoids. These observations

can well be explained by those of the quoted authors and may represent a morphological basis of the advantageous clinical effect.

A crystal-like substance showing regular periodicity was found in the capillary walls of six animals belonging to all of the groups. In the literature at our disposal we have not found any description of capillary crystals localized in the heart muscle. As the accumulation of a substance of similar structure has been observed in a number of animal species, mainly in the retinal capillaries of dogs [2], we do not attribute any special pathological significance to it.

However, the crystal-like substances of the cytoplasm of histiocytes observed in the ALS-treated group had arisen most probably in another way. BESSIS [1] reported similar structures in the antigen forming plasma cells. Recently, a crystal-like substance was found in human wire-loop lesions, displaying the same periodicity and interpreted by the authors as a precipitated antigen-antibody complex [12]. Since this substance of characteristic structure was found only in the ALS-treated group, we assume that protein or lipoprotein molecules formed in a similar manner have played role a in this case, too.

Our observations revealed some morphological data concerning the inhibitory effect of immunosuppressive agents on sterile inflammatory changes, on the basis of which the favourable clinical results of treatment of exit-block can well be interpreted.

REFERENCES

1. BESSIS, M. C.: (1964) Lab. Invest. **10,** 1040. — 2. BLOODWORTH, J. M. B., MOLITOR, D. L.: (1965) Invest. Ophthal. **4,** 285. — 3. CHARDACK, W. M., GAGE, A. A., FREDERICO, A. J., SCHIMERT, O., GREATBATCH, W.: (1965) Surgery **58,** 915. — 4. DAVID, H., HECHT, A.: (1963) Z. ges. inn. Med. **18,** 351. — 5. DEUMAN, A. M., ZIFF, M.: (1965) Fed. Proc. **24,** 305. — 6. DEUMAN, A. M., FRENKEL, E. P.: (1968) Immunology, **14,** 107. — 7. DEUMAN, A. M., FRENKEL, E. P.: (1968) Immunology **14,** 115. — 8. DIEZEL, P. B., FRIESE, G.: (1963) Z. Kreisl.-Forsch. **52,** 1. — 9. DUSEK, J., RONA, G., KOHN, D. S.: (1971) Amer. J. Path. **62,** 321. — 10. FÖLDES, I., VÁRKONYI, S., SOLTI, F., KÓCZÉ, A.: (1970) Experientia (Basel) **26,** 741. — 11. GRENDAHL, H., SCHAANING, G. G.: (1970) Acta med. scand. **187,** 75. — 12. GRISHMAN, E., CHURG, J.: (1971) Arch. Path. **91,** 156. — 13. HAUPT, G. J., MYERS, R. N., PERILL, C. V., BIRKHEAD, N. C.: (1963) Surg. Gynec. Obstet., **117,** 484. — 14. MCHENRY, M. N., WELTON, C. G., HOPKINS, D. M., SMELOFF, E. A.: (1968) Circulation **38,** 330. — 15. HERDSOM, P. B., SOMMERS, H. M., JENNINGS, R. B.: (1965) Amer. J. Path. **46,** 367. — 16. JEEJEEBHOY, H., STARZL, T., TRAEGER, J.: Uses of Anti-lymphocyte-serum in Transplantation and other Fields. In: Round Table in Human-anti-lymphocyte Serum. Merieux, Lyon 1967. — 17. JUDGE, R. D., PRESTON, T. A., LUCCHESI, B. R., BOWERS, L. D.: (1966) Amer. J. Cardiol. **18,** 83. — 18. KÜBLER, W., SOWTON, E.: (1970) Lancet **2,** 67. — 19. LAGERGREN, H., DAGLGREN, H., WORDENSTRAM, H.: (1966) Acta chir. scand. **132,** 696. — 20. LANGGARD, H., HVIDBERG, E., SZPORNY, L.: (1964) Acta rheum. scand. **10,** 281. — 21. LAWRENCE, J. S., BARNET, E. W., CRODOCK, C. G.: (1968) Transplantation **6,** 70. — 22. MALLORY, G. K., WHITE, P. D., SALCEDO-SAGAR, J.: (1939) Amer. Heart J., **18,** 647. — 23. MCMINE, R. M. H.: Tissue Repair. Academic Press, New York, 1969. — 24. MOWRY, F. M., JUDGE, R. D., PRESTON, T. A., MORRIS, J. D.: (1965) Circulation **32,** Suppl. 157. — 25. NEMES, A., SOMOGYI, E., SÓTONYI, P., SZABÓ, Z., VARGA, T.: (1969) Bruns' Beitr. klin. Chir. **217,** 277. — 26. PRESTON, T. A., FLETCHNER, R. D., LUCCHESI, B. R., JUDGE, R. D.: (1967) Amer. Heart J., **74,** 235. — 27. SCHLESINGER, M. J., REINER, L.:

(1955) Amer. J. Path. **31,** 443. — 28. SOMOGYI, E., SÓTONYI, P., NEMES, A., VARGA, T., SZABÓ, Z.: (1968) Morph. Ig. Orv. Szle, **8,** 161. — 29. STARZL, T., MARCHIORO, T. L., PORTER, K. A., IWASAKI, Y., CERILLI, G. J.: (1967) Surgery, Gynec. Obstet. **124,** 301. — 30. SZABÓ, Z., SOMOGYI, E., NEMES, A., SÓTONYI, P., VARGA, T.: (1968) Morph. Ig. Orv. Szle, **8,** 169. — 31. SZIGETI, M., EZER, E., SZPORNY, L., FEKETE, G.: (1965) Steroids **5,** 729. — 32. TURK, J. L., WILLOUGHBY, P. A., STEVENS, J. E.: (1968) Immunology, **14,** 683. — 33. WEISSMANN, G.: The Effects of Steroids and Drugs on Lysosomes. In: Lysosomes. Ed. Dingle, J. T., and Fell, H. B. North Holland Publ. Co., Amsterdam 1969.

WIRKUNG IMMUNOSUPPRESSIVER MEDIKAMENTE AUF DIE GEWEBSREAKTION IN UMGEBUNG DER PACEMAKERELEKTRODEN

E. SOMOGYI, T. VARGA, P. SÓTONYI, F. SOLTI, Z. SZABÓ, F. RÉNYI–VÁMOS, I. FÖLDES und S. VÁRKONYI

Verfasser untersuchten die Wirkung von antilymphozytärem Serum, Diadreson und Leopurin auf die in der Umgebung von Pacemakerelektroden entstehende Gewebsreaktion an Hunden. Sie stellten fest, daß auf Wirkung der LS-Therapie sowohl die perifokale Entzündung, wie auch die Narbenbildung geringer werden. Nach Diadresonbehandlung trat die Bildung von Bindegewebsfasern etwas in den Hintergrund und in den Fibroblasten waren degenerative Erscheinungen bemerkbar. Nach Gabe von Leopurin war keine bewertbare Veränderung feststellbar. Die direkte mechanische Schädigung war in allen Fällen die gleiche. Diese morphologischen Veränderungen können die Grundlage der günstigen Wirkung der immunosuppressiven Medikamente darstellen.

ДЕЙСТВИЕ ИММУНОСУПРЕССИВНЫХ МЕДИКАМЕНТОВ НА ТКАНЕВУЮ РЕАКЦИЮ ВОКРУГ ЭЛЕКТРОД ЭЛЕКТРОСТИМУЛЯТОРА

Э. ШОМОДИ, Т. ВАРГА, П. ШОТОНИ, Ф. ШОЛЬТИ, З. САБО, Ф. РЕНИ-ВАМОШ, И. ФЁЛЬДЕШ и Ш. ВАРКОНИ

Авторы исследовали на собаках действие антилимфоцитарной сыворотки, диадрезона и леопурина на тканевую реакцию, возникающую вокруг электрод электростимулятора. Они наблюдали, что как перифокальное воспаление, так и рубцевание уменьшаются под влиянием терапии ЛС. После дачи диадрезона образование соединительнотканных волокон немного отступило на задний план и на фибробластах наблюдались дегенеративные изменения. После дачи леопурина не было оцениваемого изменения. Прямое механическое повреждение было во всех случаях одинаковым. Эти морфологические изменения могут быть основой благоприятного клинического действия иммуносупрессивных медикаментов.

Dr. Endre SOMOGYI
Dr. Tibor VARGA
Dr. Péter SÓTONYI
Igazságügyi Orvostani Intézet,
Budapest IX. Üllői út 93., Hungary

Dr. Ferenc SOLTI
Dr. Zoltán SZABÓ
Dr. Ferenc RÉNYI-VÁMOS
Dr. István FÖLDES
Dr. Sándor VÁRKONYI
IV.Sebészeti Klinika,
Budapest XII, Városmajor u. 68, Hungary

Acta Morphologica Acad. Sci. Hung. 19 (4), pp. 363—376, 1971

Institute of Forensic Medicine (Director: Prof. Dr. E. Somogyi), Semmelweis University Medical School, Budapest, Hungary

FUNCTIONAL AND MORPHOLOGICAL CHANGES OF THE LIVER INDUCED BY ELECTRIC SHOCK

E. Somogyi and T. Varga

(Received July 6, 1971)

After total-body electric shock the blood sugar and serum protein level of rabbits shows a marked, momentary decrease and there are alterations in the qualitative composition as well as in the enzymatic properties of the serum proteins. Serial biopsies revealed an acute vacuolar degeneration of the liver cells. Both the morphological and the chemical alterations are of reversible character and most probably they are induced by the oxidative disorder produced by the electric current.

During electric shock not only alterations of local character arise but also generalized ones involving the internal organs. It is known from clinical observations that repeated electric shocks are followed by changes in the serum protein and a temporary decrease in the blood sugar level [33]. It has been reported by Kaplan [19] that the serum bilirubin level is always, whereas the blood sugar value often, increased. Sirensky [44] observed liver function tests indicating hepatic lesions after electric accidents. Károly [20] reported on a temporary, aspecific disturbance of liver function in four cases of electric shock. Kirillov and Korotchkina [21] found a 10—50% increase of the blood sugar level immediately after electroshock treatment. Schofield et al. [37] observed a vacuolisation in the liver of experimental animals killed by electric current and similar observations were made by Kuhn et al. [25]. The electronmicroscopic studies of these authors revealed unit-membrane limited vacuoles containing a homogeneous substance of very low electron density, different from glycogen. The limiting membrane of the vacuoles displayed a positive ATPase reaction. On this basis the vacuoles have been interpreted as of pinocytotic origin and some role has been attributed in their formation to the effect of the electric current and the hypoxia.

In our previous investigations, the changes brought about by electric current in the epithelium, the connective tissue and the skeletal as well as heart muscle have been studied in detail [32, 41, 42, 43]. The present experiments were aimed at investigating the alterations of the serum protein level, the blood sugar value and the morphology of the liver, occurring after total-body electric shock.

Material and methods

Ten rabbits of both sexes and of 3—5 kg body weight were used. The electric shock was 220 V AC and of 10 sec duration, applied on the two sides of the abdomen by means of metal electrodes. Immediately after the shock then at different points of time from 10 min till 52 days, blood samples were taken from the ear-vein for blood sugar and serum protein determination. Blood sugar was estimated by the orthotoluidine reaction spectrophotometrically [6]. Immune and agar electrophoresis, starch-ge lelectrophoresis, quantitative protein determination, testing of beta-naphthyl and indoxylesterase as well as of RNase were performed in the sera [4]. Liver biopsy was carried out immediately after the electric shock, then at different points of time between 5 min and 20 days, in superficial ether anesthesia. Liver specimens of three untreated animals obtained by biopsy as well as their blood samples taken before the electric shock served as controls. The liver tissue was fixed in formalin buffered according to HOLT and postfixed in 1% OsO_4, dehydrated in ethanol and embedded into Araldite. Ultrathin sections were contrasted with uranyl acetate and lead citrate, and investigated by a Hitachi HU 10 electronmicroscope. Routine histological stainings and diastase digestion were also carried out on part of the material. Four animals received 2 ml/kg Ferrlecit (Nattermann, Köln) intravenously 15 min before the electric shock and the biopsy material was investigated by the Prussian blue reaction to demonstrate the presence of iron [5].

Results

Mean blood sugar was 141.3 $\pm$ 16.6 mg per 100 ml before the electric shock. The values formed a sinus curve in the first one and half hour after the treatment and by the 3rd hour returned to the control value. Thereupon a slow decrease began, reaching the minimum by the 3rd to 10th day. The change was strongly significant ($p < 0.001$). Then the blood sugar level increased again after the 10th day and although it did not reach the average of the controls, there was no significant difference as compared with it. On the 48th day the original value was restored (Fig. 1).

The amount of serum protein was 5.90 $\pm$ 0.15 g per 100 ml in the controls. In the samples taken on the 3rd day a marked decrease (4.62 $\pm$ 0.20 g) was observed, whereas on the 21st day it was practically identical with the control value (5.84 $\pm$ 0.14 g). The decrease was significant as compared to both the control value and that of the 21st day ($p < 0.01$) (Fig. 2).

Immunoelectrophoresis showed no alteration during the first three days. A decrease of $alpha_1$-globulins and a change of mobility of beta-globulins could be observed on the 6th day. This change persisted till the 48th day and the original pattern appeared again on the 52nd day. Agar electrophoresis revealed a relative decrease of about 45% of the albumin fraction and a 5—10% increase of IgG on the 6th and 21st days. Beta-naphthyl and indoxyl esterase activity decreased immediately after the electric shock. RNase activity of serumalbumin decreased by about 66% to the 21st day. The alterations of the enzyme activities were of a reversible character; on the 52nd day normal values were obtained both qualitatively and quantitatively.

The biopsy revealed that in half-thin sections made immediately after the electric shock the cytoplasm of the liver cells hardly stained with toluidine-

blue. A granular substance of blue staining (Fig. 3) should be found only in the vicinity of the nucleus and cell membrane as well as dispersedly in the cytoplasm. The light microscopic picture was unchanged till the third day;

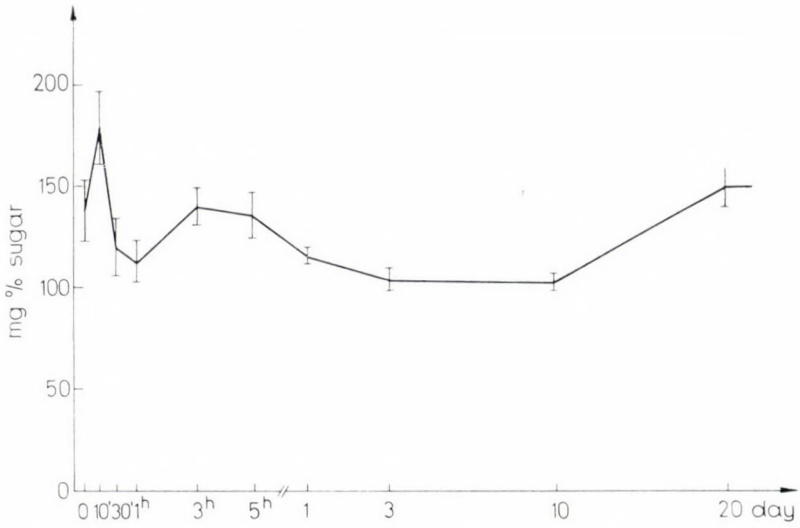

Fig. 1. Blood sugar level

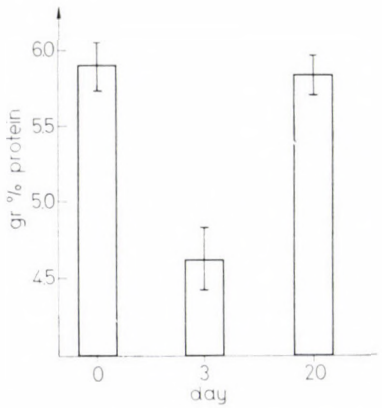

Fig. 2. Serum protein level

the normal structure was restored step by step by the seventh and tenth days. Regeneration started at the periphery of the acini. The empty areas of the cytoplasm displayed a homogeneous, intense PAS-positivity disappearing after diastase digestion (Fig. 4).

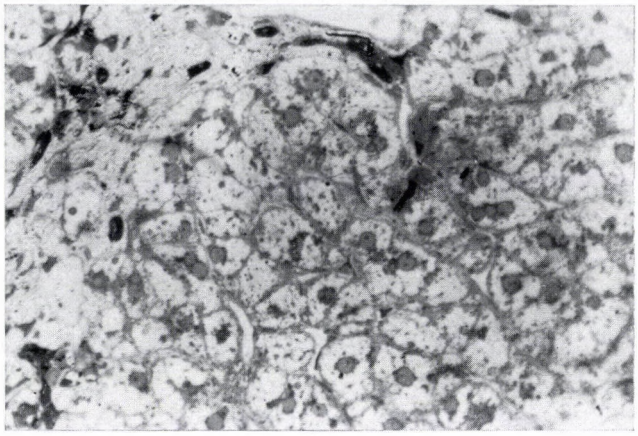

Fig. 3. Half-thin section, toluidine-blue staining. The majority of liver cells is filled with unstained vacuoles

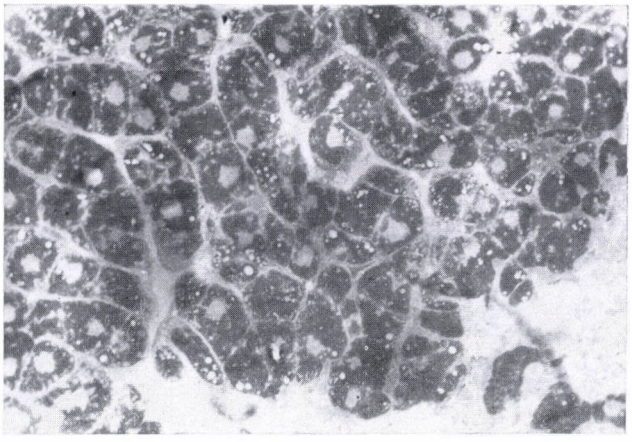

Fig. 4. Intensive PAS-reaction in the vacuoles

In the electron micrographs the most conspicuous phenomenon was the paucity of cells in organelles. The largest part of the cytoplasm was filled by a homogeneous substance of low electron density, containing some compact, scattered granules resembling the rosette-like arrangement of glycogen granules, as well as several membrane-limited vacuoles (Fig. 5). The picture 10 min after electric shock was identical with the above described one, only the amount of the compact granules decreased and by 20 min (Fig. 6) they disappeared. One hour after the shock the structure of the cytoplasm was similar containing no glycogen. The nucleoplasm precipitated in the form of rough

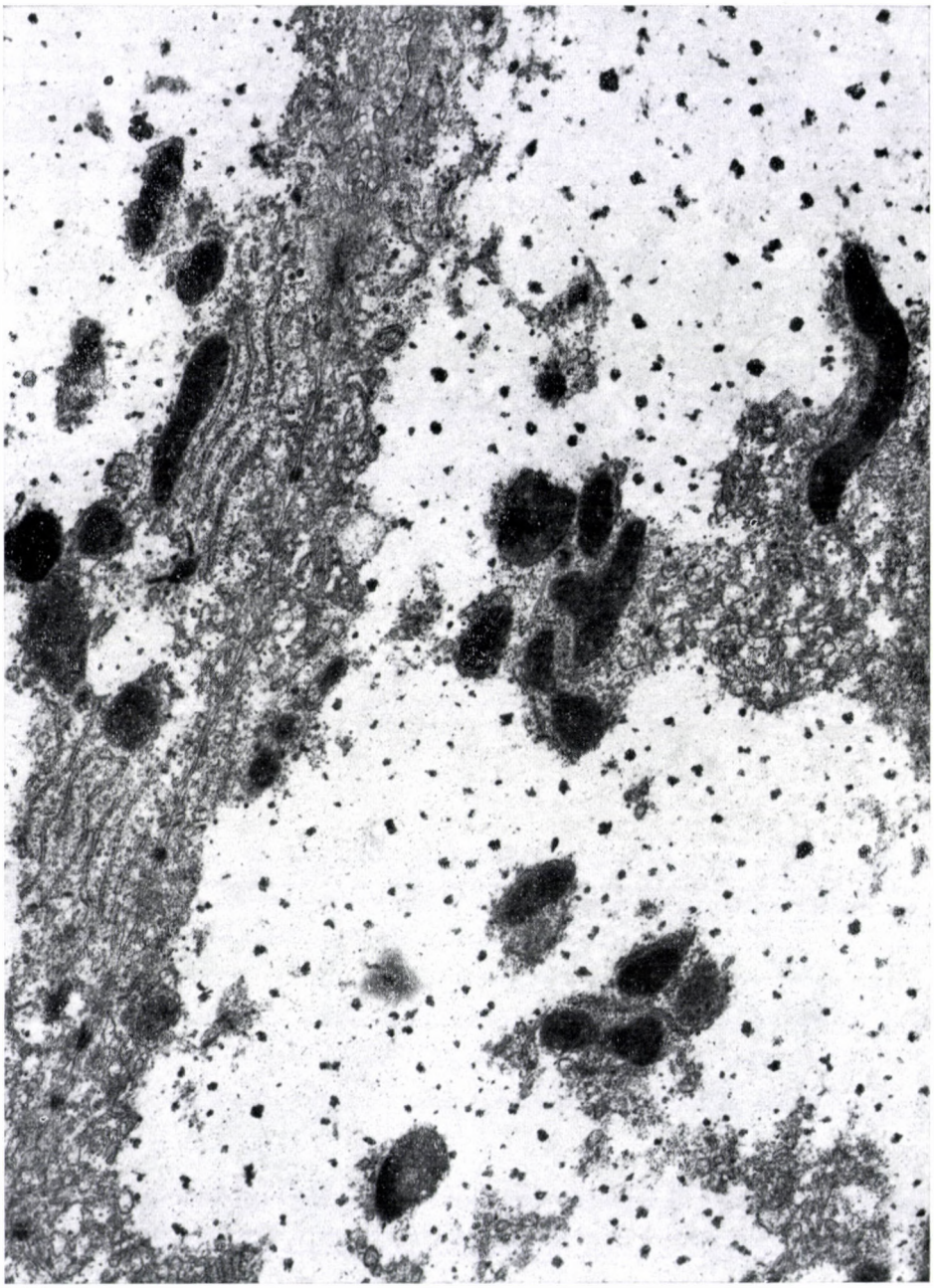

Fig. 5. In the cytoplasm a homogeneous substance of very low density, containing compact granules resembling glycogen. The mitochondria are slightly shrunken, their matrix is dark, other cell organelles are intact. (×21,000, Hitachi HU 10)

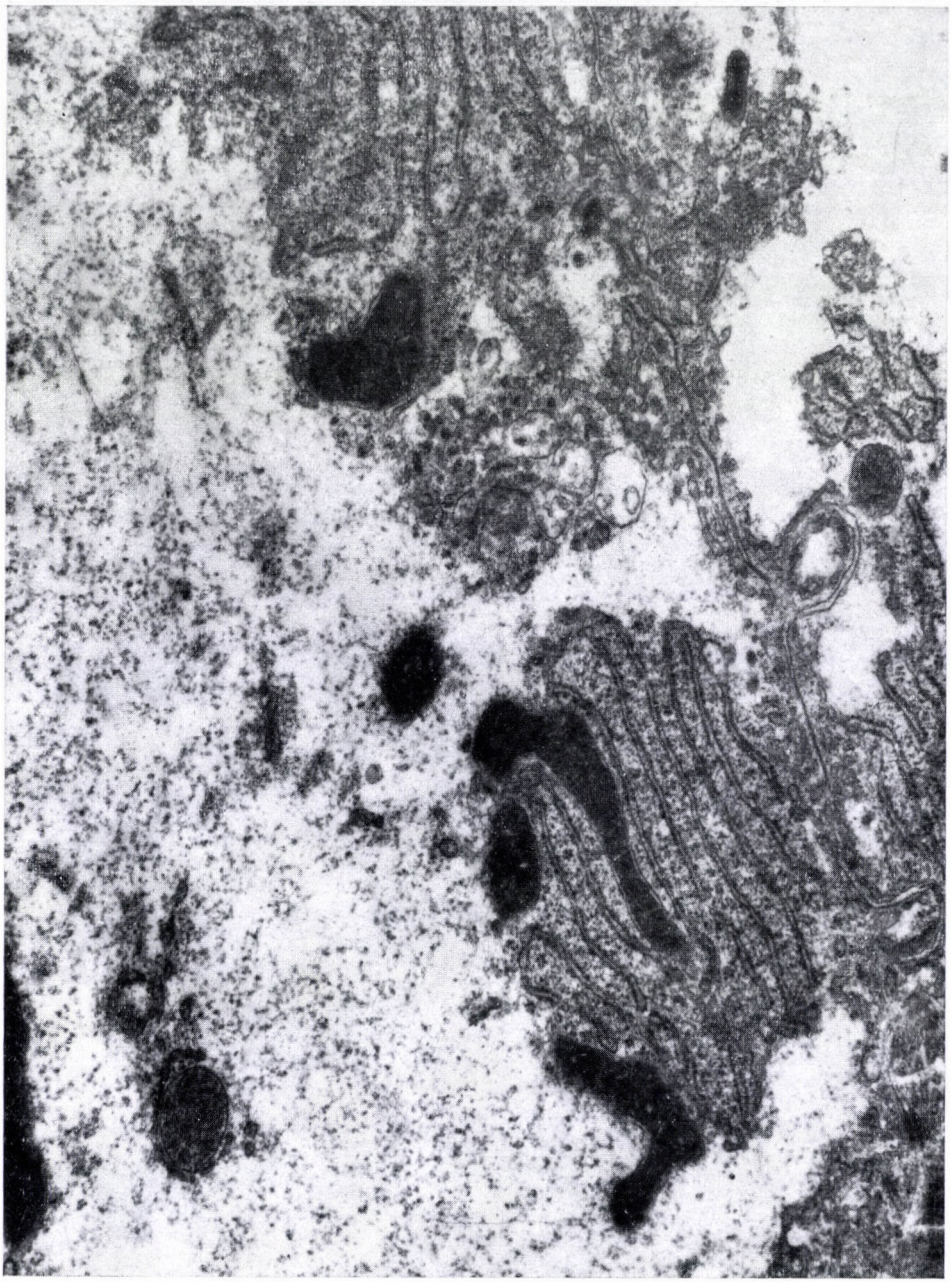

Fig. 6. The dark granules disappeared 30 min. after the electric shock, the compactness of the mitochondrial matrix is conspicuous. Other organelles are intact. (×30,600)

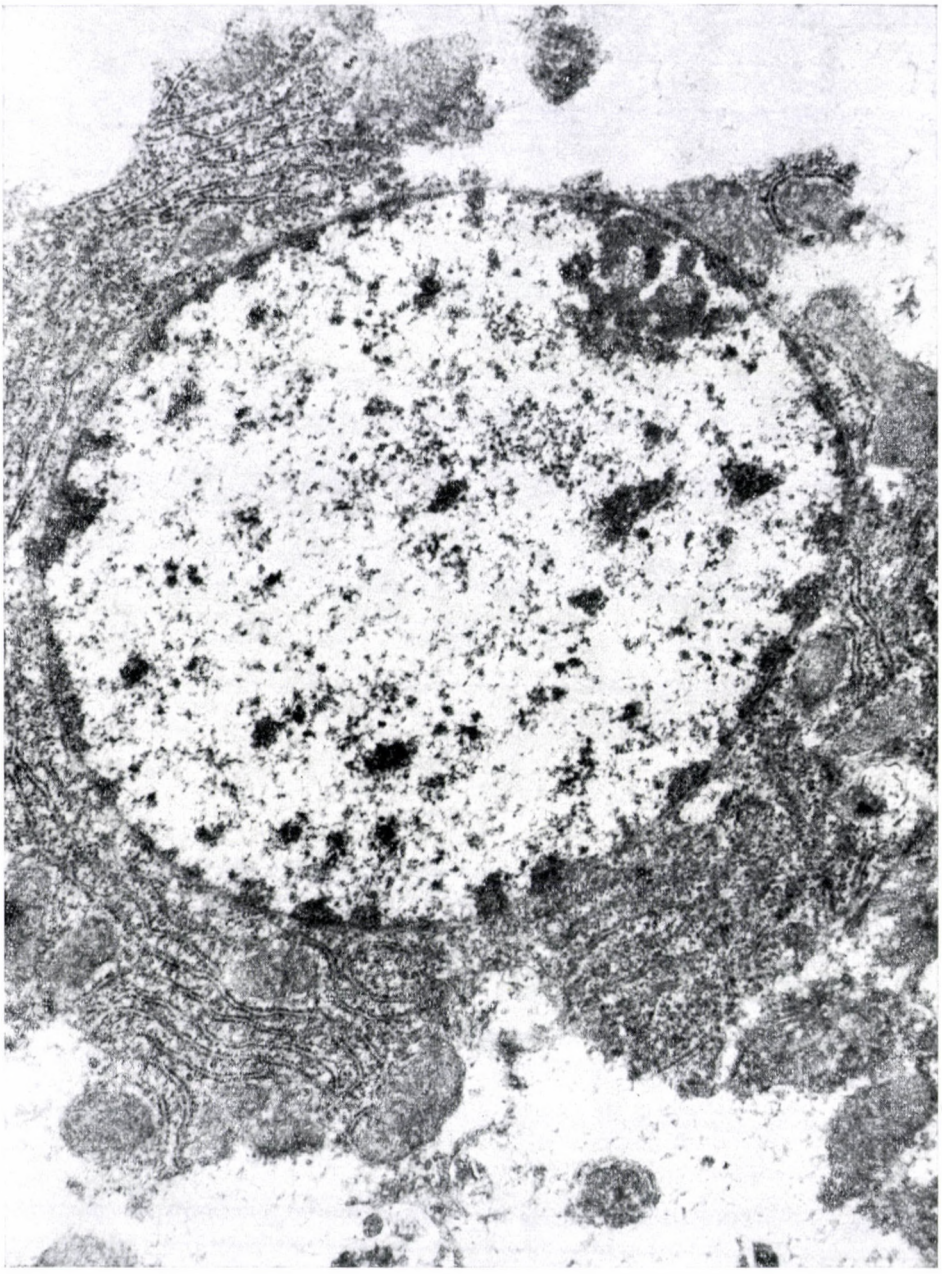

Fig. 7. The nuclear chromatin appears in form of rough granules, the nuclear membrane is extended; tails of cytoplasm are pressed to the nucleus. (×12,600)

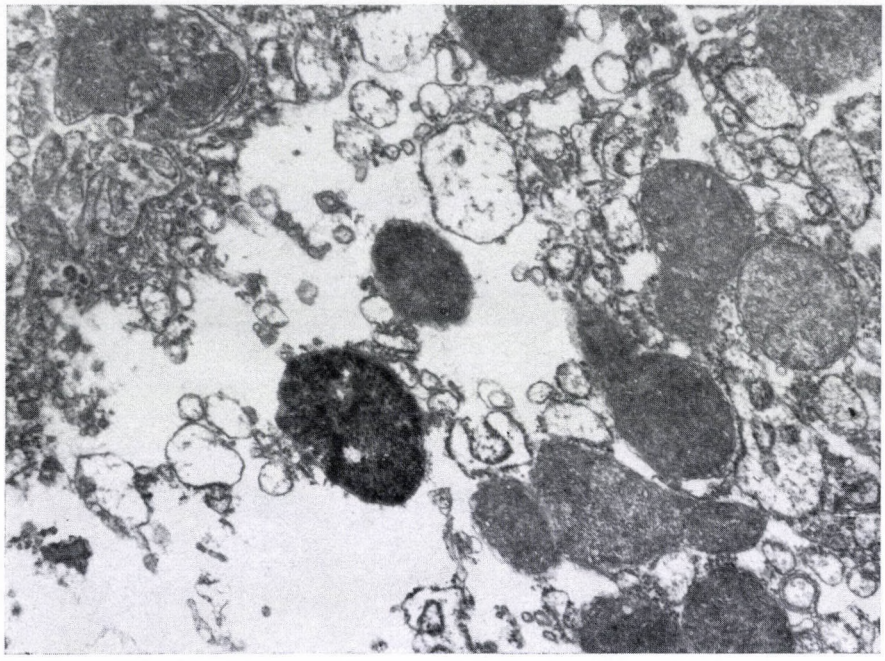

Fig. 8. The mitochondria are normal in structure; the ducts of the smoth and rough endoplamic reticulum are enlarged and almost empty. (×12,750)

granules partly scattered and partly adhering to the nuclear membrane (Fig. 7). The other organelles were normal in structure, except for a slight shrinking of mitochondria and the compactness of their matrix (Figs 6 and 7). One day later the structure of the organelles is loosened, the mitochondrial matrix is less compact, the smooth endoplasmic reticulum is increased in amount, the cisterns of the rough endoplasmic reticulum are enlarged and contain some flocculated substance (Fig. 8). Practically similar pictures were observed till the third day. Seven days after the electric shock the acinocentral cells are similar to those described above, the development of the smooth endoplasmic reticulum is especially striking. In the acinoperipheral cells the cytoplasm is almost completely filled by granulated endoplasmic reticulum and mitochondria, between them, glycogen granules occur in rosette form, but their staining is weaker than usual (Fig. 9). The cisterns of the endoplasmic reticulum are widened and practically empty (Fig. 10). Ten days after the shock most cells show a similar regenerating structure, whereas on the 20th day their structure is normal (Fig. 11).

After Ferrlecit treatment the presence of iron was detectable only in the Kupffer cells; the cytoplasm of the liver cells was Prussian-blue negative.

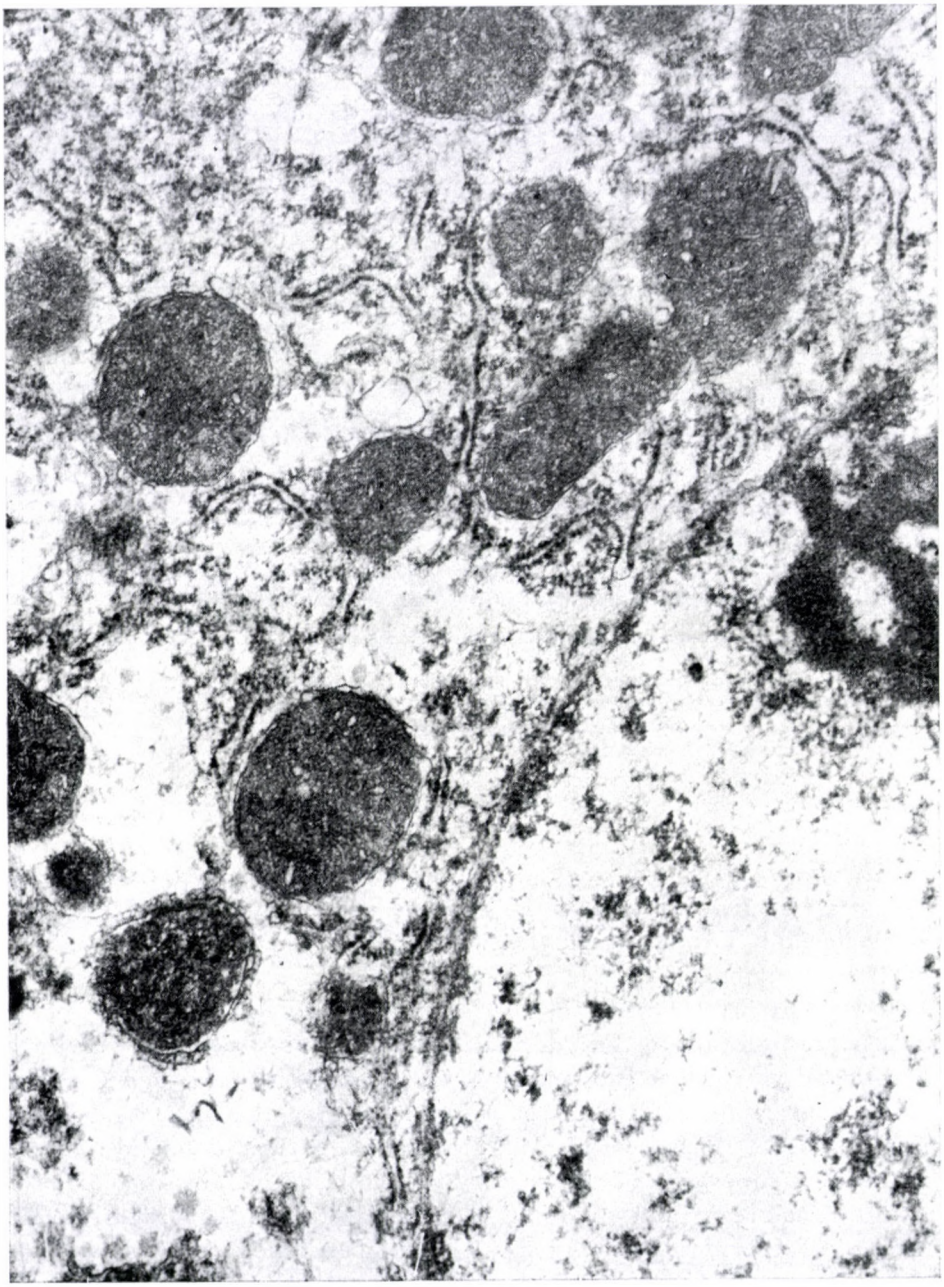

Fig. 9. Glycogen granules paler than the usual ones between the ducts of the endoplasmic reticulum. (×36,050)

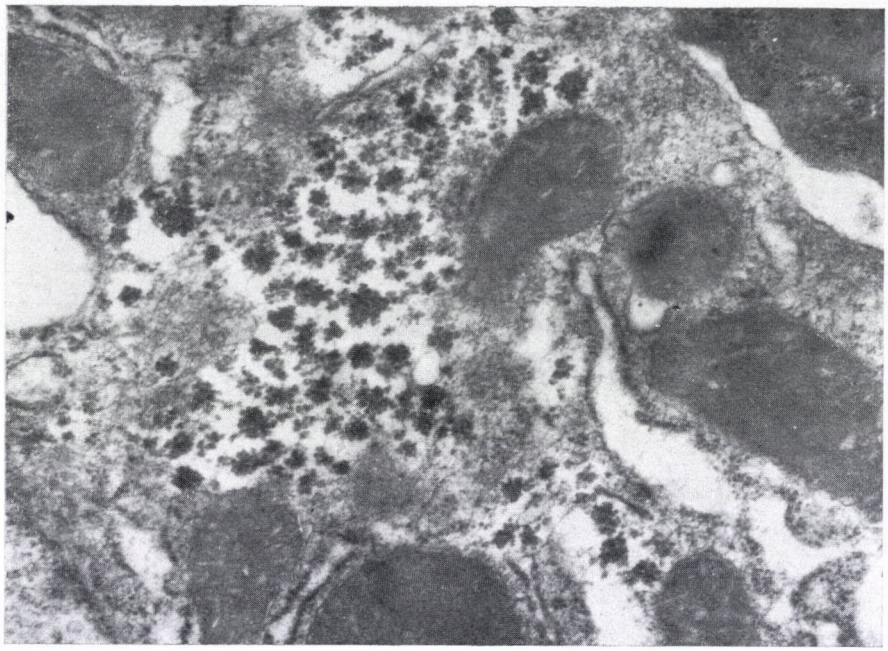

Fig. 10. Normal glycogen content. Some little flocculated substance in the widened ducts of the endoplasmic reticulum. (×31,200)

Discussion

It has been shown previously that the first signs of electrothermal damage are degenerative alterations of the endoplasmic reticulum and the mitochondria in the epithelium, the skeletal and the heart muscles [32, 41, 42, 43]. The alterations of the blood sugar level observed after an electric shock in the present investigations can be attributed to Cannon's reaction; when this is over, both the blood sugar and the total protein values show a strongly significant decrease. The enzymatic properties of the serum proteins also decrease. The fact that this decrease ensues later than that of the blood sugar value can be attributed to the different speed of their decomposition. The qualitative composition of the serum proteins also changes, first of all the amount of albumin and of alpha$_1$-globulin decreases. The slight, relative increase in IgG is most probably only a seeming one due to the decrease of the total amount of the proteins. After the 10th and 20th days, blood sugar and serum protein levels become normal and 7—8 weeks after the electric shock neither qualitative nor quantitative alterations can be observed.

There is a number of data concerning the morphology of the hepatic lesions induced by different toxic substances [3, 16, 31, 35, 38, 39, 40, 47], drugs,

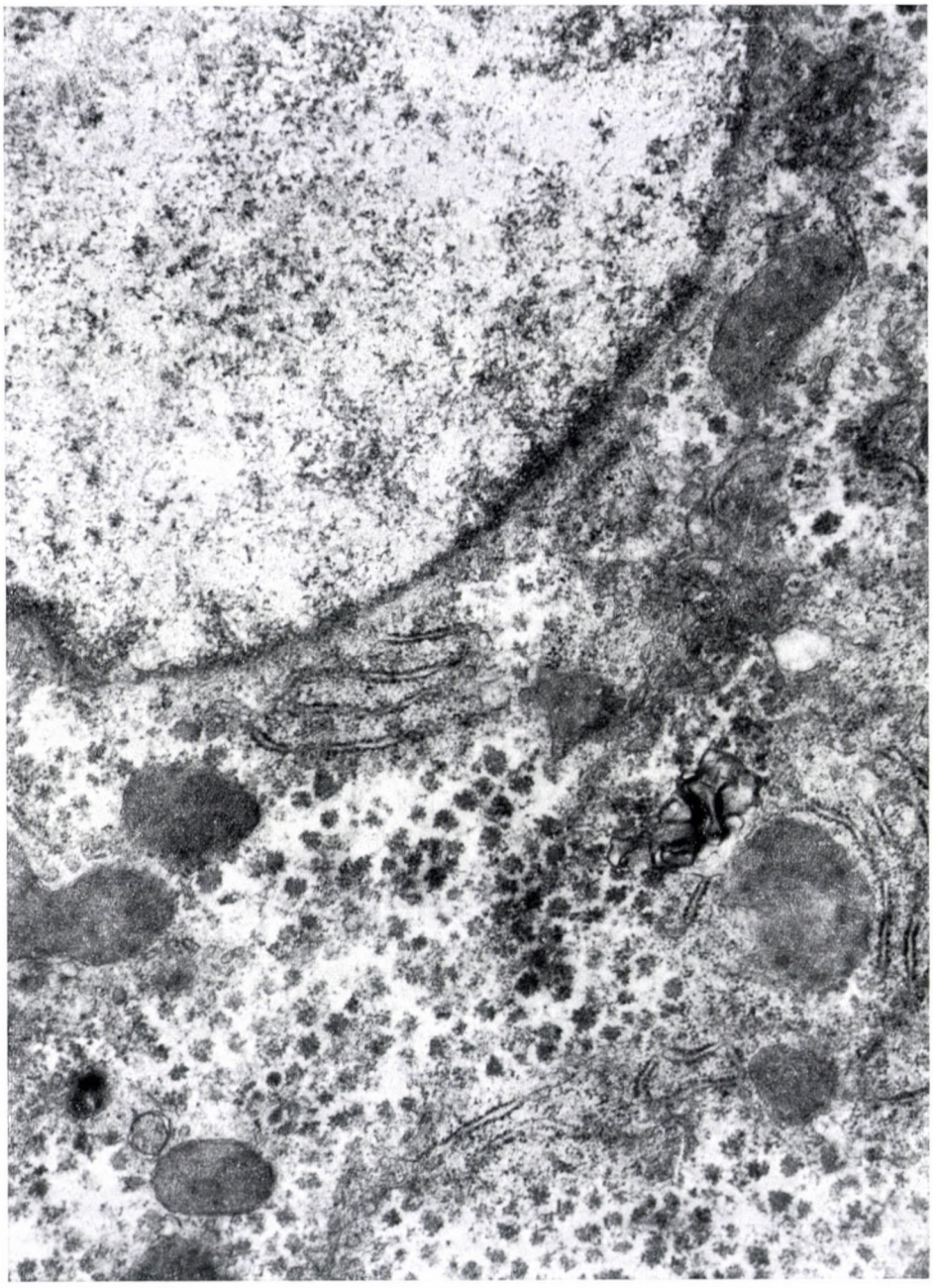

Fig. 11. Intact cell structure on 20th day. (×25,200)

carcinogens [1, 2, 10, 14, 18, 26, 30, 34, 36, 45], and on liver regeneration induced by partial hepatectomy [7, 46]. In the case of toxic influences the rapid disappearance of cellular glycogen is a common phenomenon. In the decomposition of glycogen some role is attributed to the autophagous vacuoles connected with the smooth endoplasmic reticulum, the peroxisomes [22, 23]. After the glycogen depletion, the vesicles of the smooth endoplasmic reticulum increase in number and it is here that the resynthesis of glycogen takes place [3, 12, 25, 28, 30, 34]. The glycogen detectable electronmicroscopically almost completely disappeared even in the earliest samples taken after the electric shock. A homogeneous substance of low density, without any limiting membrane had accumulated between the organelles. The cell membrane is intact and no pinocytosis or the signs of an active glycogen mobilisation were observed. The fact that the colloidal iron did not penetrate into cells speaks against a significant increase of permeability. Therefore, we assume that the disappearance of glycogen did not take place in the way mentioned above, and in the vacuoles formation of plasma inflow had no decisive role. There was an intensive PAS-reaction in the vacuoles which disappeared after diastase digestion. On this basis it seems most likely that the glycogen granules are decomposed upon the influence of the electric shock, they lose their characteristic structure, and form homogeneous, PAS-positive areas distributed uniformly in the cytoplasm.

According to literary data, the synthesis of plasma proteins starts in the ribosomes attached to the membranes of the rough endoplasmic reticulum, then they pass into the Golgi apparatus and are transported by the Golgi vesicles toward the Disse space. Therefore, the substance observed electronmicroscopically in the structures mentioned above may correspond to plasma protein [8, 15, 27, 29]. The incorporation of radioactive amino acids as well as the synthesis of plasma proteins decreases under toxic effects [1, 17, 40]. During the first hours following the electric shock the endoplasmic reticulum and the Golgi apparatus maintain their regular structure. However, later on the spaces of the granulated and smooth endoplasmic reticulum are enlarged, they and the Golgi vesicles are almost empty. The number of coated vesicles also decreases. These morphological changes are in good agreement with the decrease of the serum protein level and the changes in the blood counts.

Nevertheless, the alterations treated till now seem to be rather consequential ones and do not clarify the mechanism resulting in the damage. On the basis of the above considerations an increase in permeability and plasma exudation are unlikely to have a role. The vacuolisation induced by other physical influences such as X-ray irradiation, is more prolonged in time [11, 24]. At the same time, the mitochondrial matrix is compact and the mitochondria seem to be slightly shrunken immediately after the electric shock.

It has been shown previously during studies of isolated cardiac mitochondria shocked electrically that a decoupling of the oxidative system occurs even in areas remote from the site of the primary effect [9]. On this basis it may be assumed that the primary damage involves the energetical system of the cells, and the morphological picture as well as the damage of the carbohydrate and protein metabolism are consequences of this.

The regeneration process was similar to that taking place after other kinds of damage. At the same time, functional recovery was late as compared to the morphological regeneration, in that the cellular glycogen content had normalized by the tenth day, whereas the blood sugar values returned to the original one only after 20 days. The qualitative serum protein pattern and the enzymatic properties became normal even later, around the 50th day after the electric shock.

REFERENCES

1. Ashworth, C. T., Werner, D. J., Gloss, M. D., Arnold, N. J.: (1965) Amer. J. Path. **47,** 917. — 2. Arcasay, M., Smuckler, E. A., Benditt, E. P.: (1968) Amer. J. Path. **52,** 814. — 3. Arhelher, R. B., Broom, J. S., Boler, R. K.: (1965) Amer. J. Path. **46,** 409. — 4. Backhausz, R.: Immunodiffusion und Immunoelektrophorese. Akadémiai Kiadó, Budapest 1967. — 5. Bálint, A., Nagy, Z.: (1971) Experientia (Basel) **27,** 175. — 6. Bálint, P.: Klinikai laboratóriumi diagnosztika. Művelt Nép, Budapest 1955. — 7. Becker, F. F., Lane, B. P.: (1965) Amer. J. Path. **47,** 783. — 8. Brumi, C., Porter, K. R.: (1965) Amer. J. Path. **46,** 691. — 9. Bujdosó, Gy., Fonyó, A., Somogyi, E.: (1969) Zacchia **2,** 232. — 10. Burger, P. C., Herdson, P. B.: (1966) Amer. J. Path. **48,** 793. — 11. Catravos, G. N., McHale, G. C.: (1971) Histochemie, **25,** 247. — 12. Coimbra, A., Loblond, C. P.: (1966) J. Cell Biol. **30,** 151. — 13. Cole, S., Matter, A., Karnovsky, M. J.: (1971) Exp. molec. Path. **14,** 158. — 14. Diognordi, N., Ideo, G., DelNino, E., Franchis, R.: (1970) Lancet **1,** 1063. — 15. Fawcett, D. W.: (1955) J. nat. Cancer Inst. **15,** Suppl. 1475. — 16. Goldblatt, P. J., Wittschi, H., Friedmann, M. A., Sullivan, R. J., Skull, K. H.: (1970) Lab. Invest. **23,** 378. — 17. Guidotti, G. G., Rossi, C. B., Ragnotti, G.: (1963) Proc. Soc. exp. Biol. (N. Y.) **114,** 308. — 18. Iseri, O. A., Lieber, C. S., Gottlieb, L. S.: (1966) Amer. J. Path. **48,** 535. — 19. Kaplan, A. D.: Пражение электротоком. Москва 1951. — 20. Károly, E.: Országos Mentőszolgálat Értekezlete, Miskolc. 1965. — 21. Kirillov, S. H., Korotchkina, N. M.: (1952) Журн. невропат. психиат. **3,** 21. — 22. Kotoulos, O. B., Phillips, M. J.: (1971) Amer. J. Path. **63,** 1. — 23. Kotoulos, O. B., Ho, J., Adachi, F., Weigensberg, B. I., Phillips, M. J.: (1971) Amer. J. Path. **63,** 23. — 24. Kovács, L.: (1971) Magy. Tud. Akad. Orv. Oszt. Közl. **21,** 403. — 25. Kuhn, N. O., Olivier, M. L., Krigmann, M. R.: (1965) US Army Chemical Research and Development Laboratories. Technical Report. — 26. Lavin, P., Koss, L. G.: (1971) Amer. J. Path. **62,** 159. — 27. Ma, N. H., Bienpica, L.: (1971) Amer. J. Path. **62,** 353. — 28. Deman, J. C. H., Blok, A. P. R.: (1966) J. Histochem. Cytochem. **14,** 135. — 29. Matter, A.: (1969) J. Ultrastruct. Res. **11,** Suppl. 1. — 30. Mikota, A., Luse, S. A.: (1964) Amer. J. Path. **44,** 455. — 31. Miyai, K., Raick, A. N., Ritchie, A. C.: (1970) Lab. Invest. **23,** 268. — 32. Nemes, A., Somogyi, E., Sótonyi, P., Szabó, Z., Varga, T.: (1969) Bruns Beitr. klin. Chir. **217,** 277. — 33. Nyirő, Gy.: Psychiatria. Medicina, Budapest 1967. — 34. Porter, K. R., Brumi, C.: (1959) Cancer Res. **19,** 997. — 35. Roick, A. N., Narayanou, A. S., Ritchie, A. C.: (1971) Exp. molec. Path. **14,** 176. — 36. Rubin, E., Bocchian, P., Gang, H., Lieber, C. S.: (1970) Lab. Invest. **22,** 569. — 37. Schofield, B. H., Grossman, I. W., Arsenal, E.: (1968) Arch. Path. **86,** 208. — 38. Shinozuka, H., Lombardi, B., Farber, E.: (1971) Amer. J. Path. **63,** 161. — 39. Smuckler, E. A., Iseri, O. A., Benditt, E. P.: (1961) Biochem. biophys. Res. Comm. **5,** 270. — 40. Smuckler, E. A., Iseri, O. A., Benditt, E. P.: (1962) J. exp. Med. **116,** 55. — 41. Somogyi, E., Rózsa, Gy., Varga, T.: (1970) Acta histochem. (Jena) **35,** Suppl. 18. — 42. Somogyi, E., Sótonyi, P., Rózsa, Gy., Varga, T.: (1967) Acta morph. Acad. Sci. hung. **15,** 401. — 43. Somogyi, E., Sótonyi, P., Rózsa, Gy., Nevelős, A., Varga, T.: (1967)

Zacchia **3,** 389. — 44. SIRENSKY, N. N.: (1937) Собет. Мег. **6,** 1. — 45. THOMPSON, S. W., SPARANO, B. M., DIENER, R. M.: (1971) Amer. J. Path. **63,** 135. — 46. VIRÁGH, Sz., BARTÓK, I.: (1966) Amer. J. Path. **49,** 825. — 47. WITZLEBEN, C. L.: (1966) Amer. J. Path. **49,** 1053.

FUNKTIONELLE UND MORPHOLOGISCHE UNTERSUCHUNG DER NACH STROMVERLETZUNGEN ENTSTEHENDEN LEBERVERÄNDERUNGEN

E. SOMOGYI und T. VARGA

Nach experimenteller Stromeinwirkung auf den ganzen Körper zeigt die Konzentration des Blutzuckers und der Serumeiweiße bei Kaninchen eine vorübergehende sehr ausgesprochene Verminderung. Veränderungen treten weiterhin im qualitativen Bild der Leukozyten und in den enzymatischen Eigenschaften der Bluteiweiße auf. Reihenmäßig durchgeführte Leberbiopsien zeigten eine akut entstehende vakuoläre Degeneration der Leberzellen. Sowohl die morphologischen Veränderungen, wie auch die abweichenden Laboratoriumsbefunde sind reversibel und bei ihrer Entstehung spielen wahrscheinlich durch den elektrischen Strom verursachte Störungen der Zelloxydation eine Rolle.

ФУНКЦИОНАЛЬНОЕ И МОРФОЛОГИЧЕСКОЕ ИССЛЕДОВАНИЕ ПЕЧЕНОЧНЫХ ИЗМЕНЕНИЙ, ВОЗНИКАЮЩИХ ПОСЛЕ УДАРА ЭЛЕКТРИЧЕСКИМ ТОКОМ

Э. ШОМОДИ и Т. ВАРГА

После экспериментального удара всего тела электрическим током содержание сахара в крови и количество сывороточных белков показывают временное, весьма выраженное снижение. Имеются отклонения и в лейкоцитарной формуле и в ферментативных свойствах белков крови. Серийные биоптические исследования печени показали остро возникающее вакуольное перерождение печеночных клеток. Как морфологические, так и лабораторные отклонения оказались обратимыми и в деле их возникновения, по всей вероятности, роль играет нарушение окислительных процессов в клетках, вызванное электрическим током.

Dr. Endre SOMOGYI, Dr. Tibor VARGA
Igazságügyi Orvostani Intézet,
Budapest IX. Üllői út 93., Hungary

Acta Morphologica Acad. Sci. Hung. 19 (4), pp. 377–388, 1971

Institute of Experimental Medicine, Hungarian Academy of Sciences (Head: Prof. E. STARK), Second Institute of Pathological Anatomy (Head: Prof. H. JELLINEK), University Medical School and National Institute of Rheumatology and Medical Hydrology (Head: Prof. K. FARKAS), Budapest, Hungary

ULTRASTRUCTURE OF PANCREATIC ACINAR PARENCHYMA IN ACUTE EXPERIMENTAL PANCREATITIS OF THE PIGEON

M. PAPP, Z. NAGY and I. FODOR

(Received September 1, 1971)

Intraductal administration of sunflower oil or Na-deoxycholate into the pancreas of the pigeon elicited acute pancreatitis. After the injected sunflower oil had gained access into the acinar cells, it increased the number of zymogen granules in different stages of maturity and increased the cells' secretory activity. The normally sharp boundary between the zymogen granules and the surrounding cytoplasm became blurred; the zymogen granules merged with their environment, and/or they entered into autophagous vacuoles. Secondary lysosome-type vacuoles were also seen. Sunflower oil induced autolysis. Sodium deoxycholate impaired the acinar cells without causing any change in the shape, electron density and localization of the zymogen granules. Deoxycholate induced heterolysis.

Decomposition of neutral lipids by the pancreatic tissue of the pigeon had been originally described by BERNARD (1856). Based on this finding, it was supposed that like in the dog and the rat, edible oil injected through the excretory duct into the pancreas would cause acute necrosis of the gland also in the pigeon.

Previous studies in this laboratory have suggested the damage of acinar cells to be initiated by intra-acinar lipolysis (PAPP, BÁCSY, HORVÁTH, 1970).

Impairment of acinar cells by bile, bile acids or their salts was reported by SUM, BENCOSME, and BECK (1970). Treatment with bile was shown to elicit early ultrastructural damage of acinar cells (DOERR, DIEZEL, GRÖZINGER, LASCH, NAGEL, ROSSNER, WANKE, WILLIG, 1965; WANKE, 1968).

In this laboratory experiments have been undertaken to clarify the nature of the ultrastructural changes caused in the pancreatic acinar parenchyma of the pigeon by intraductally administered sunflower oil or sodium deoxycholate and to assess whether these changes were typical of the injected agent(s).

Material and methods

Pigeons weighing 400—500 g were divided into 4 groups, each consisting of 10 birds. The pancreatic gland was exposed by laparotomy under ether anaesthesia. Injection of 0.1—0.2 ml material into the ventral lobes was performed through the efferent duct by means of an injection syringe. Pressure was not controlled. The experimental groups were given commercial sunflower oil or 1% Na deoxycholate in Tris-HCl buffer (pH 7.1) or saline. In the

fourth group the pancreas was left intact. To visualize vascular leakage (STAUBESAND, 1963; JELLINEK, NAGY, HÜTTNER, BÁLINT, KÓCZÉ, KERÉNYI, 1969) 4 birds in each group were injected into the wing vein with colloidal iron solution (Ferrlecit, Natterman, Köln; 2 ml/100 g body weight), one bird simultaneously with, and 3 birds 2 hours after, the laparotomy.

One hour after the injection of Ferrlecit all birds were anaesthetized with ether and the ventral lobes were perfused through the pancreaticoduodenal artery (PAPP, 1970) for 10 minutes with 1.5% neutral isotonic formalin solution of +4°C temperature at a pressure of 100—130 mm Hg (HOLT, HICKS, 1961).

(i) In the four iron-treated birds and in four iron-untreated birds perfusion was continued for another 10 minutes using a 1 : 1 mixture of glutaraldehyde and formalin in 1.5% neutral isotonic solution of +4°C temperature. Subsequently several specimens were taken

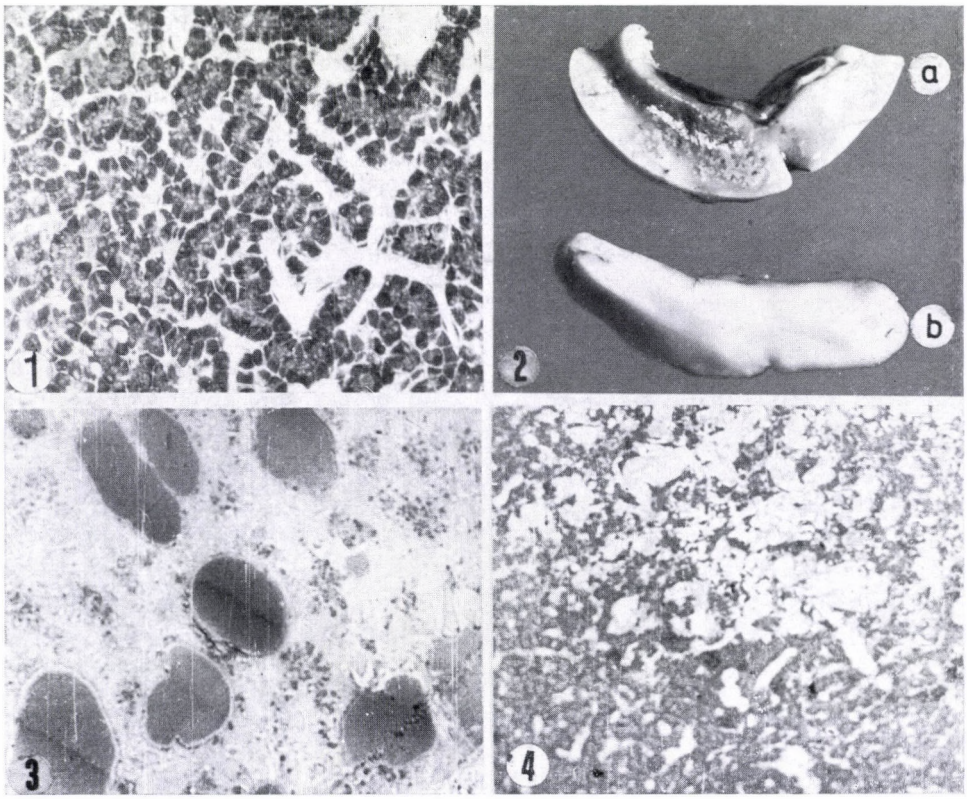

Fig. 1. Normal pancreas from pigeon (semi-thin section). In the compact parenchyma undivided by connective tissue septa, acinar cells and ductular outlets are apparent. (Toluidine blue, ×320)

Fig. 2. Control pancreas (b) and pancreas treated with sunflower oil, 3 hours after administration (a): Note necrotic areas (Benda reaction) on the surface of the oedematous gland. Natural size, gross appearance

Fig. 3. Pancreas 1 hour after administration of sunflower oil. Semi-thin section. Note oil in the distended outlets and zymogen granules at the apical poles of the acinar cells. (Toluidine blue, ×400)

Fig. 4. Pancreas 3 hours after Na-deoxycholate administration. Semi-thin section. Note radial pattern of cellular "lysis" around the ductular outlets and loss of acinar structure. (Toluidine blue, ×280)

from the pancreas and the tissue fragments were fixed in 4% neutral formalin for 24 hours and embedded in paraffin. Sections 6 μ thick were stained with haematoxylin and eosin and examined under the light microscope. Another specimen of pancreatic tissue was cut into blocks of 1 cu. mm dimension under a steromicroscope. The blocks were allowed to stand in a 1.5% solution of glutaraldehyde and formalin for 2 hours at +4°C, then immersed in buffer solution for 24 hours at 4°C, postfixed in 1% osmiumtetroxide solution (MILLONIG 1961), and embedded in Durcupan-Araldite.

Semi-thin sections cut from the blocks were stained with toluidine blue. Sections cut by an LKB III Ultratome were counterstained with lead citrate and uranyl acetate and examined in a JEM 6 AS electron microscope.

(ii) The ventral lobes of the pancreas of 2 iron-untreated pigeons from each experimental group were perfused for 10 minutes with 1.5% neutral isotonic formalin and subsequently for another 10 minutes with an 0.5% OsO_4 solution. Specimens removed from the pancreatic tissue were cut into 1 cu. mm blocks and these were allowed to stand in 0.5% OsO_4 solution for 2 hours.

Subsequent fixation and embedding were the same as described under (i).

Results

Intraductally administered sunflower oil and Na-deoxycholate caused oedema in the pancreas. The surface of the lobe treated with oil showed necrosis (Fig. 2) while that of the lobe treated with Na-deoxycholate showed haem-

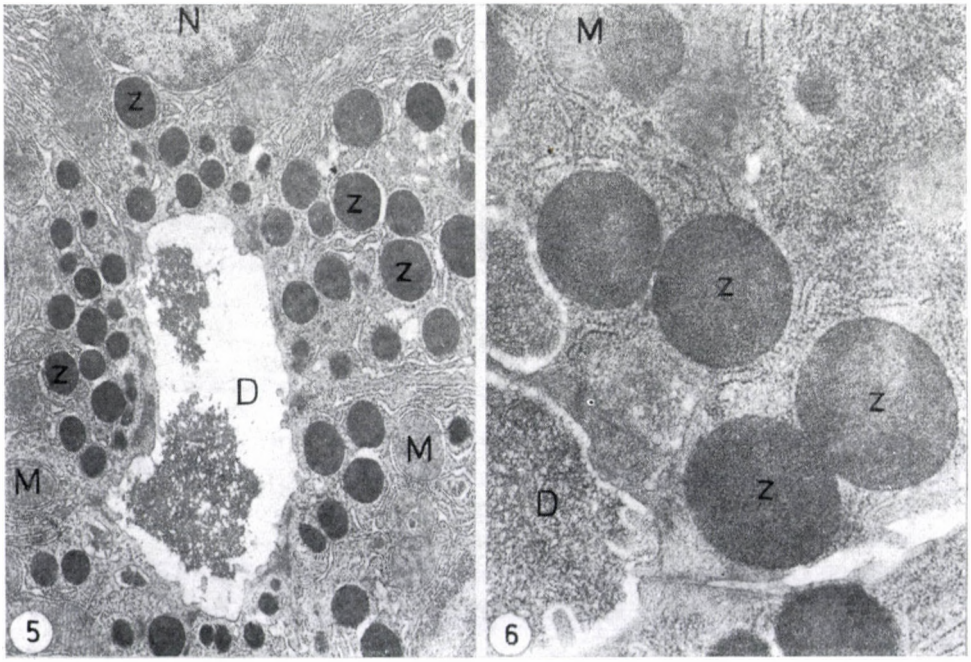

Fig. 5. Electron micrograph of normal pancreas. Note strict pattern of acinar cells around the duct (D) and nature zymogen granules (Z). M = mitochondrium; N = nucleus. (OsO_4 fixation; ×6300)

Fig. 6. Zymogen granules (Z) under high power, with surrounding membrane rarely present. D = excretory duct; M = mitochondrium. (OsO_4 fixation; ×21,000)

orrhage. Vascular changes related to the damage will be reported elsewhere (NAGY, PAPP, BÁLINT, 1971).

In light micrographs the acinar parenchyma of the pancreas shows a compact structure not subdivided by fibrous septa (Fig. 1). Treatment with sunflower oil gave rise to distension of the outlets. The number of zymogen granules appeared to increase at the apical pole of the acinar cells and a

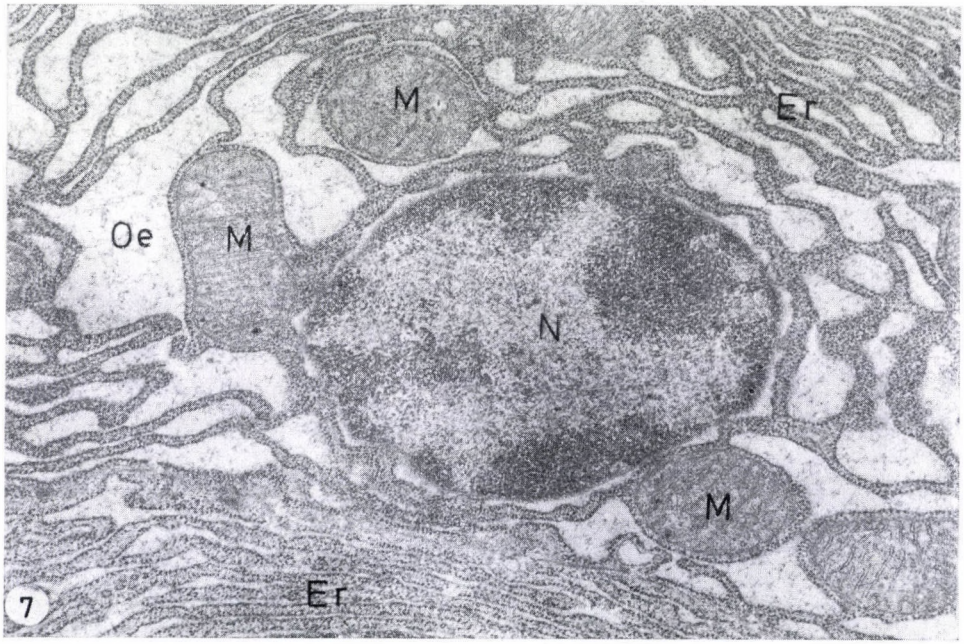

Fig. 7. Pancreas treated with saline, 3 hours after administration, with the normal acinar cell structure essentially retained. The intact ergastoplasmic sacs are distended with oedema fluid (Oe). Er = ergastoplasm; M = mitochondria; N = nucleus. (×12,500)

spotted necrosis developed (Fig. 3). Treatment with Na-deoxycholate induced necrosis and haemorrhage around the outlets (Fig. 4).

Electron micrographs of normal pancreatic acinar cells revealed zymogen granules at the apical pole. The granules were occasionally surrounded by a membrane (Figs 5, 6).

Treatment with saline resulted in the accumulation of fluid in the ergastoplasmic sacs, but did not affect the cell organelles (Fig. 7).

Treatment with sunflower oil gave rise to intracellular oedema within one hour, with the acinar cell structures undamaged; the mitochondria also became oedematous. Lipid droplets surrounded by mature zymogen granules appeared in apparently intact acinar cells (Fig. 8). Electron density of the lipid droplets

corresponded to that of the sunflower oil injected into the outlet. In other acinar cells, increased secretory activity was indicated by the appearance of several zymogen granules in different stages of maturity. Zymogen granules entered into limiting membraneless vacuoles containing ergastoplasmic fragments (Fig. 9). In places the ergastoplasmic structure was loose. Three hours later the lipid droplets were still demonstrable in the structurally disorganized

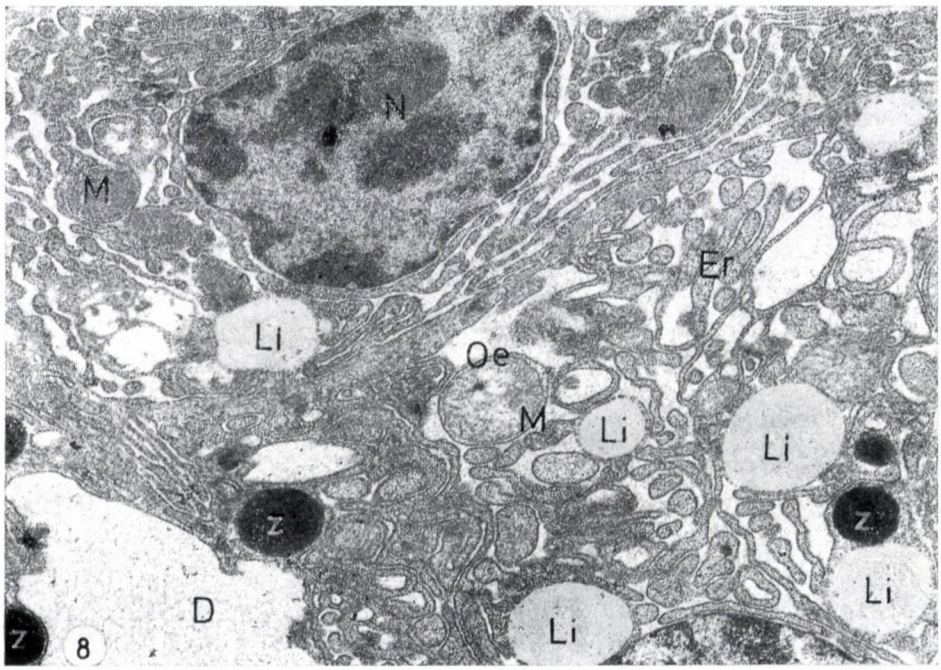

Fig. 8. Pancreatic gland 1 hour after sunflower oil administration. Intracellular oedema. Oedematus mitochondrium (Oe M). The integrity of the cellular structure is essentially maintained; the ergastoplasmic lamellae (Er) are pushed apart by oedema. Note intracellular lipid droplets (Li) and mature zymogen granules (Z). D = excretory duct; M = mitochondrium; N = nucleus. (×12,000)

acinar cells. Adjacently there were confluent zymogen granules, having lost their sharp demarcation against the ergastoplasm (Figs 10, 11). In addition, secondary lysosome-type vacuoles surrounded by a limiting membrane were seen in the acinar cells (Fig. 12).

Na-deoxycholate caused not only inter-acinar, but also intracellular oedema (Fig. 13). In the acinar cells showing different degrees of structural changes the shape, electron density and localization of the zymogen granules was essentially unchanged (Figs 13, 14).

Discussion

Claude BERNARD was the first to induce an acute necrosis of the pancreas by injecting edible oil into the duct. He supposed the oil to enter the pancreatic cells (1856). In the present experiments, intraacinar lipid droplets were detected exclusively in the oil-treated glands. Since the electron density

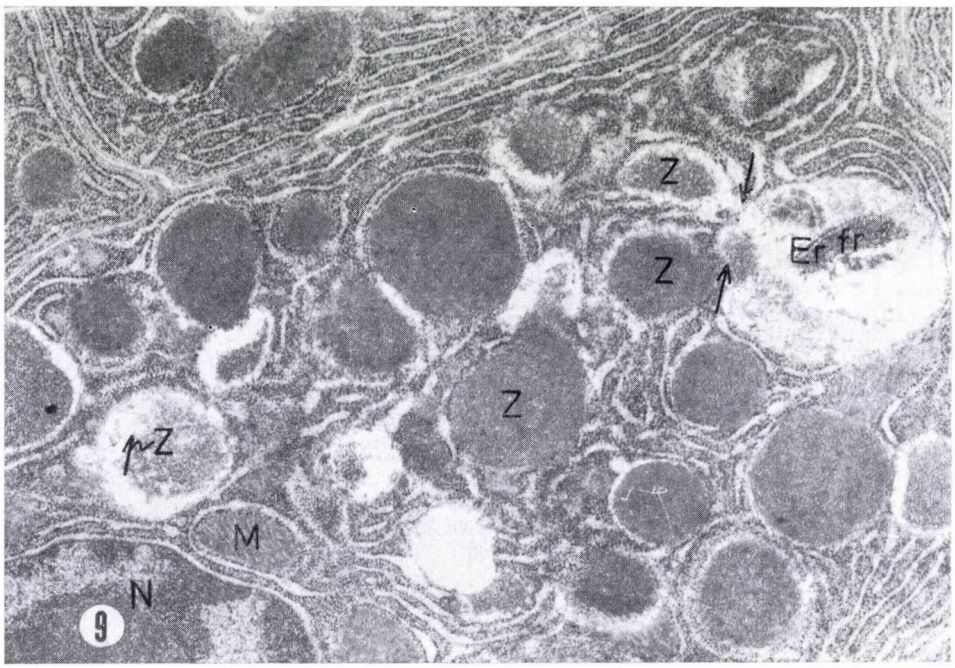

Fig. 9. Same as above. At the apical pole of the acinar cells there are zymogen granules in different stages of maturity (pZ). Zymogen granules (Z) entered into the vacuole (arrows) without limiting membrane, localized in the right medium third of the cell. The vacuole contains ergastoplasmic fragments (Er.fr). The mitochondrial matrix is electron dense. In places the ergastoplasmic structure is loose. M = mitochondrium; N = nucleus. (×17,700)

of the lipid droplets was identical with that of the injected sunflower oil in the outlets, the intraductally injected oil must have gained access to the pancreatic acinar cells. Our previous fluorescence microscopic studies showed that sunflower oil injected into the pancreas of dogs and pigeons had found its way into the acinar cells (PAPP, BÁCSY, HORVÁTH, 1970; BÁCSY, NAGY, PAPP, 1970). Passage of sunflower oil across the basement membrane of an acinar cell may be promoted by the soap formation due to lipolysis and/or by the separation of acinar cells by the injection pressure (SJÖSTRAND, ELFVIN, 1962). HESS (1903, 1905) interpreted the oil-induced acute pancreatic necrosis as a consequence of soap

intoxication. Intraductal administration of trypsin promoted the entry of Indian ink clumps into the acinar cells (NUDELMAN, MUNGER, BERNARD, 1965).

In addition to our data, lipid droplets may presumably be produced by a chronic disturbance of cell metabolism; fasting (PALADE, 1958), malonic acid injection (KÖSSLING et al., 1967), feeding on low-protein or ethanol and fat diet (WEISBLUM, HERMAN, FITZGERALD, 1962; TASSO, CLOP, SARLES,

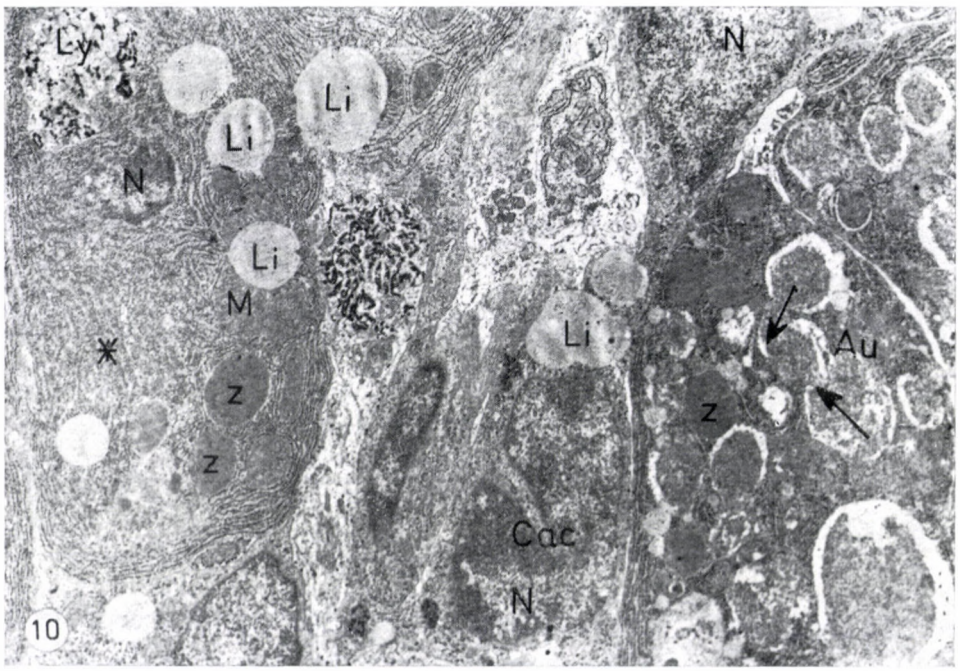

Fig. 10. Pancreas 3 hours after intraductal administration of sunflower oil. The acinar and centroacinar cells (Cac) contain lipid droplets (Li). Different degrees of cellular disorganization are apparent. The confluent zymogen granules (arrows) have lost their sharp demarcation against the ergastoplasm. The mitochondrial matrix is electron dense. The ergastoplasmic structure is loose over large areas (star). Au = autophagic vacuole; Ly = lysosome-like vacuole; M = mitochondrium; N = nucleus. (×7,800)

PICARD, 1967), during hormonal stimulation of pancreatic secretion (RIBET, FEDOU, FREXINOS, 1969), etc. In these cases, however, the lipid droplets accumulated around the mitochondria. On feeding an amino acid analogon containing diet, the location of lipid droplets was found to be non peri-mitochondrial (HRUBAN, SWIFT, WISSLER, 1962; HRUBAN et al. 1963).

Upon the administration of sunflower oil, the sharp boundary between zymogen granules and ergastoplasm tended to disappear, some zymogen granules having practically merged with the ergastoplasm. A similar phenomenon in Lipofundin-induced necrosis of the pancreas was noted light microscopically

by WANKE (1968). This might be explained by the lipase activity demonstrated histochemically at the surface of zymogen granules (ABE, KRAMER, SELIGMAN, 1964; SELIGMAN, UENO, HANKER, KRAMER, WASSERKURG, SELIGMAN, 1966). In the pancreas of the pigeon the zymogen granules are rarely surrounded by a membrane. The absence of a membrane around these granules was frequent in the duck, too (BRAUN-BLANCQUET, 1969).

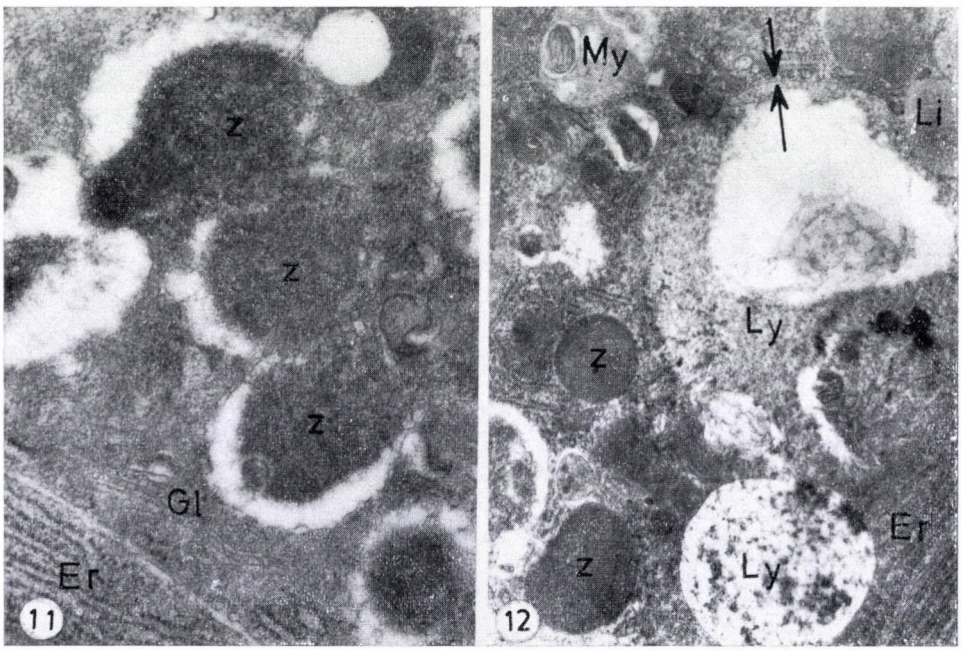

Fig. 11. Same as above, at higher magnification. Note confluent zymogen granules (Z) merging with the environment. Er = ergastoplasm; Gl = Golgi apparatus. (×21,000)

Fig. 12. Pancreas 3 hours after intraductal administration of sunflower oil. Lysosome-like vacuoles (Ly) limited by membrane (opposite arrows) contain myelin figures (My). Around the vacuoles there are lipid droplets (Li) and zymogen granules (Z) in different stages of maturity. (×12,000)

The development of autophagous vacuoles in the acinar cells is presumably related to the disturbance of protein metabolism in the exocrine pancreatic cells induced by DL-ethionine (HERMAN, FITZGERALD, 1962), low-protein diet (LAZARUS, VOLK, 1962), X-irradiation of the pancreas (VOLK, WELLMANN, LEWITAN, 1966), or on hormonal stimulation of secretion (RIBET, FEDOU, FREXINOS, 1969), etc. Focal "cytoplasmic degradation" could be elicited by a diet containing amino acid analogues (HRUBAN et al. 1962, 1963).

Confluence of zymogenic granules was noted in both the normal (EKHOLM et al. 1962; SJÖSTRAND, 1962; BRAUN-BLANCQUET, 1969) and the hormonally stimulated pancreas (ICHIKAWA, 1965; RIBET et al., 1969).

Intra- and intercellular oedema of the acinar parenchymal cells in dogs given edible oil intraductally was reported by WANKE (1968) and DOERR et al. (1965).

There is reason to suppose that sunflower oil entering the acinar cells initiates autolysis, by stimulating participation of the digestive enzymes stored in the zymogen granules. In humans, chymus reflux from the duodenum to the pancreas may initiate acute pancreatitis (MCCUTCHEON, 1968).

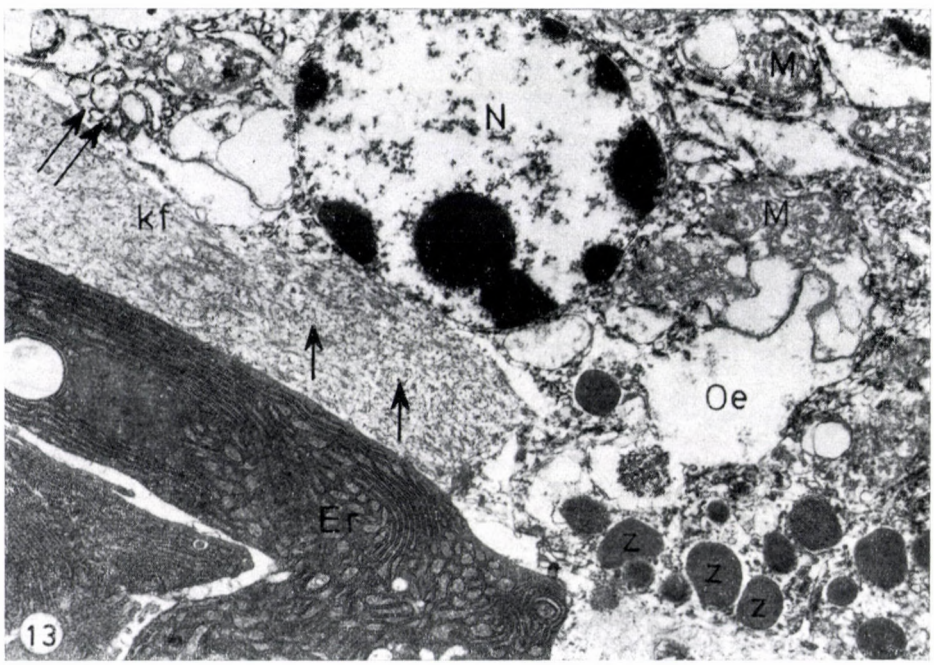

Fig. 13. Pancreas 1 hour after intraductal administration of Na-deoxycholate. The exocrine cells show different degrees of impairment. At bottom left there are acinar cells with dense matrix, some of these oedematous, but structurally essentially intact. Disorganized acinar cell at top. The impaired membranes are impregnated by colloidal iron particles (double arrows). Shape, electron density and localization of the zymogen granules (Z) remained essentially unchanged. In the nucleus (N) the chromatin has aggregated. In the intercellular space there are collagenous filaments (Kf) and colloidal iron particles (arrow). Er = ergastoplasm; M = mitochondria; Oe = oedema. (×12,000)

Previous studies (BÁCSY, NAGY, PAPP, 1970) showed fatty acids in the acinar cells after intraductal injection of sunflower oil. The pH-shift caused by the fatty acid release may promote the activation of lysosomal cathepsin (DE DUVE, 1958, 1963, 1967).

Na-deoxycholate has been shown to elicit acute necrosis of the pancreas probably by disrupting cellular membranes (WANKE, NAGEL, WILLIG 1966;

WANKE, 1968; SUM, BENCOSME, BECK, 1970). This does not seem to require involvement of digestive enzymes according to the data of WANKE et al. (1966).

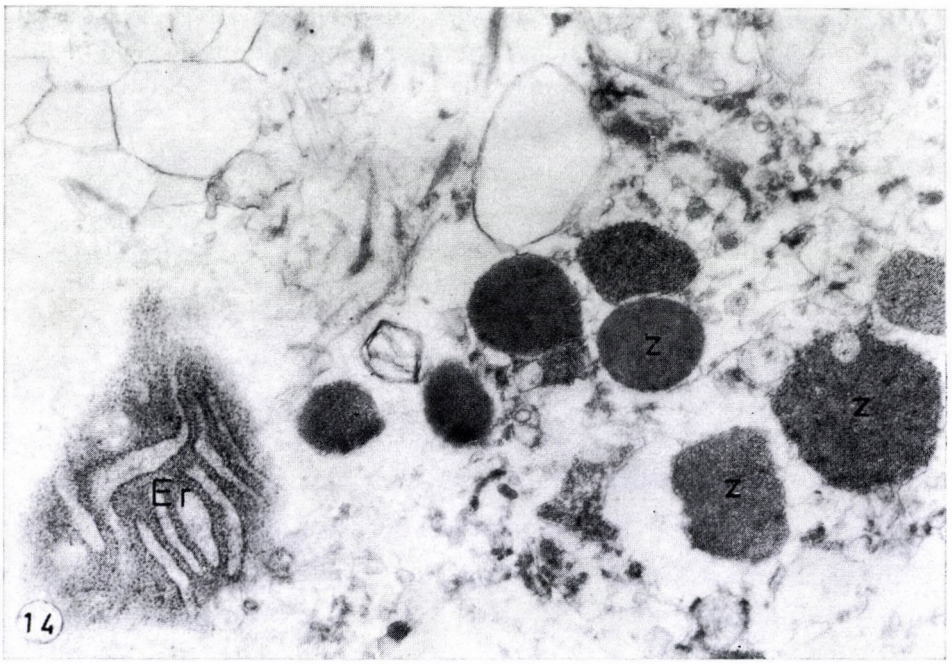

Fig. 14. Pancreas 3 hours after intraductal administration of Na-deoxycholate. Note complete lysis of cellular structure, with fragments of ergastoplasm (Er) and broken membranes. Zymogen granules (Z) with seemingly normal structure. (×18,000)

REFERENCES

1. ABE, M., KRAMER, S. P., SELIGMAN, A. M.: (1964) The Histochemical Demonstration of Pancreatic-like Lipase and Comparison with the Distribution of Esterase. J. Histochem. Cytochem. **12,** 364—383. — 2. BERNARD, CL.: (1856) Mémoire sur le pancréas et sur le rôle du suc pancréatique dans les phénomènes digestifs particulièrement dans la digestion des matières grasses neutres. J. B. Baillière, Paris, pp. 1—190. — 3. BÁCSY, E., NAGY, Z., PAPP, M.: (1970) Intra-acinar Lipolysis, an Early Sign of Intravital Pancreatic Autodigestion. Acta med. Acad. Sci. hung. **27,** 331—335. — 4. BRAUN-BLANCQUET, M.: (1969) Examen du pancréas du canard normal au microscope éléctronique précédé de son observation macroscopique et microscopique. Acta anat. (Basel) **72,** 161—194. — 5. DOERR, W., DIEZEL, P. B., GRÖZINGER, K. H., LASCH, H. G., NAGEL, W., ROSSNER, J. A., WANKE, M., WILLIG, F.: (1965) Pathogenese der experimentellen autodigestiven Pankreatitis. Klin. Wschr. **43,** 125—136. — 6. DE DUVE, C.: (1958) Lysosomes a New Group of Cytoplasmic Particles. In: Intercellular Particles. Ed: Teru Hayashi. Ronald Press, New York, pp. 128—159. — 7. DE DUVE, C.: (1963) General Properties of Lysosomes. In: The Lysosome Concept. Ed: de Reuck, A. V. S., Cameron, M. P., J. A. Churchill, London, pp. 1—31. — 8. DE DUVE, C.: (1967) Lysosomes and Phagosomes. The Vacuolar Apparatus. Protoplasma **63,** 95—98. — 9. EKHOLM, R., ZELANDER, T., EDLUND, Y.: (1962) The Ultrastructural Organization of the Rat Exocrine Pancreas. J. Ultrastruct. Res. **7,** 61—72. — 10. HERMAN, L., FITZGERALD, P. J.: (1962) The Degenerative Changes in Pancreatic Acinar Cells Caused by DL-ethionine. J. Cell Biol. **12,** 313—327. — 11. HESS, O.: (1903) Experimentelle Beitrag zur Ätiologie der Pankreas und Fettgewebsnekrose. Münch.

med. Wschr. **50,** 1905—1908. — 12. HESS, O.: (1905) Experimentelles zur Pankreas- und Fettgewebsnekrose. Münch. med. Wschr. **52,** 644—646. — 13. HOLT, S. J., HICKS, R. M.: (1961) Studies on Formalin Fixation for Electron Microscopy and Cytochemical Staining Purposes. J. Biophys. biochem. Cytol. **11,** 31—46. — 14. HRUBAN, Z., SWIFT, H., WISSLER, R. W.: (1962) Effect of beta-3-thienylalanine on the Formation of Zymogen Granules of Exocrine Pancreas. J. Ultrastruct. Res. **7,** 359—372. — 15. HRUBAN, Z., SPARCO, B., SWIFT, H., WISSLER, R. W., KLEINEFELD, R. G.: (1963) Focal Cytoplasmic Degradation. Amer. J. Pathol. **42,** 657—684. — 16. ICHIKAWA, A.: (1965) Fine Structural Changes in Response to Hormonal Stimulation of the Perfused Canine Pancreas. J. Cell Biol. **24,** 369—385. — 17. JELLINEK, H., NAGY, Z., HÜTTNER, I., BÁLINT, A., KÓCZÉ, A., KERÉNYI, T.: (1969) Investigations of the Permeability Changes of the Vascular Wall in Experimental Malignant Hypertension by Means of a Colloidal Iron Preparation. Brit. J. exp. Path. **50,** 13—16. — 18. KÖSSLING, F. K., NAGEL, M., SCHÄFER, A.: (1967) Experimentelle tryptische Pankreatitis durch metabolische Läsion. Serologische, histologische und elektronenmikroskopische Untersuchungen. Gastroenterologie, **5,** 158—168. — 19. LAZARUS, S. S., VOLK, B. W.: (1962) Electron Microscopy and Histochemistry of Rabbit Pancreas in Protein Malnutrition. (Experimental Kwashiorkor) Amer. J. Path. **44,** 95—103. — 20. MCCUTCHEON, A. D.: (1968) A Fresh Approach to the Pathogenesis of Pancreatitis. Gut **9,** 296—310. — 21. MILLONING, G.: (1961) Advantages of a Phosphate buffer for OsO_4 Solutions in Fixation. J. appl. Physics **32,** 1637. — 22. NAGY, Z., PAPP, M., BÁLINT, A.: (1971) A Light and Electron Microscopic Analysis of Vascular Injury due to Oil or Deoxycholate-induced Acute Pancreatitis. Acta morph. Acad. Sci. hung., **19,** 175—185. — 23. NUDELMAN, H. L., MUNGER, B. L., BERNARD, H. R.: (1965) The Pathological Anatomy of Acute Pancreatitis. J. Amer. med. Ass. **192,** 387—388. — 24. PALADE, G. E.: (1958) in: Functional Changes in the Structure of Cell Components. In: Subcellular Particles. Ed: T. Hayashi. Ronald Press, New York. pp. 64—83. — 25. PAPP, M.: (1970) About the Acinar-enzymatic, Vascular-inflammatory and Interstitial-lymphatic Components in the Origin of Acute Pancreatic Necrosis. Thesis. Budapest. — 26. PAPP, M., BÁCSY, E., J. HORVÁTH, E.: (1969) A lipáz jelentősége a pankreas—zsírnekrosis keletkezésében. Orvostud. **21,** 125—135. — 27. RIBET, A., FEDOU, R., FREXINOS, J.: (1969) Ultrastructure of the Canine Exocrine Pancreas Following Continuous Intravenous Infusion of Secretin and Injection of Pancreozymin. Digestion, **2,** 145—158. — 28. SELIGMAN, M. L., UENO, H., HANKER, J. S., KRAMER, S. P., WASSERKRUG, H., SELIGMAN, A. M.: (1966) Cytochemical Localization of Pancreatic Lipase with Light and Electron Microscopy. Exp. mol. Path. Suppl. **3,** 21—35. — 29. SJÖSTRAND, F. S.: (1962) The Fine Structure of the Exocrine Pancreas Cells. In: Symposium on the Exocrine Pancreas. Normal and Abnormal Function. Ed.: Reuck. A. V. S., Cameron, M. P. Churchill Ltd., London, pp. 1—19. — 30. SJÖSTRAND, I., ELFVIN, L. G.: (1962) The Layered, Asymmetric Structure of Plasma Membrane in the Exocrine Pancreas Cell of the Cat. J. Ultrastruct. Res. **7,** 504—534. — 31. STAUBESAND, J.: (1963) Zur Histophysiologie des Herzbeutels. II. Mitteilung. Elektronenmikroskopische Untersuchungen über die Passage von Metallsolen durch mesotheliale Membranen. Z. Zellforsch. **58,** 915—952. — 32. SUM, P. T., BENCOSME, A., BECK, I. T.: (1970) Pathogenesis of Bile-induced Acute Pancreatitis in the Dog: Experiments with Detergents. Amer. J. dig. Dis. **15,** 637—646. — 33. TASSO, F., CLOP, J., SARLES, H., PICARD, D.: (1967) Étude de l'action de l'éthanol et des graisses alimentaires sur le pancréas du rat. Path. et Biol. **15,** 733—745. — 34. VOLK, B. W., WELLMANN, K. F., LEWITHAN, A.: (1966) The Effect of Irradiation on the Fine Structure and Enzymes of the Dog Pancreas. Amer. J. Path. **48,** 721—754. — 35. WANKE, M.: (1968) Experimentelle Pankreatitis. G. Thieme Verlag, Stuttgart. — 36. WANKE, M., NAGEL, W. WILLIG, F.: (1966) Formen der experimentellen Pankreatitis pathoanatomisch gesehen. Frankf. Z. Path. **75,** 207—221. — 37. WEISBLUM, B., HERMAN, L., FITZGERALD, P. J.: (1962) Changes in Pancreatic Acinar Cells During Protein Deprivation. J. Cell Biol. **12,** 313—328.

DIE ULTRASTRUKTUR DES ACINAREN PARENCHYMS DER TAUBENPANKREAS BEI AKUTER EXPERIMENTELLER PANKREATITIS

M. PAPP, Z. NAGY und I. FODOR

Intraduktal in die Pankreas von Tauben eingeführtes Sonnenblumenöl oder Na-Desoxycholat rief eine akute Pankreatitis hervor. Die Sonnenblumenöltröpfchen gerieten rasch in die Acinuszellen und erhöhten die Zahl der zymogenen Körnchen verschiedener Reife und die sekretorische Aktivität der Zellen. Die scharfe Grenze zwischen den zymogenen Granula und den sie umgebenden Zytoplasma wurde verwischt, die zymogenen Granula drangen in ihre

Umgebung und (oder) gerieten in autophage Vakuolen. Weiterhin waren auch sekundäre Vakuolen lysosomen Charakters sichtbar. Das Sonnenblumenöl führt zu einer Autolyse. Das Natriumdesoxycholat schädigte schon früh die Acinuszellen, ohne jedoch die charakteristische Lokalisation, die Form oder die elektronische Densität der zymogenen Granula zu verändern. Natriumdesoxycholat ruft Heterolyse (Zytolyse) hervor.

УЛЬТРАСТРУКТУРА АЦИНАРНОЙ ПАРЕНХИМЫ ПОДЖЕЛУДОЧНОЙ ЖЕЛЕЗЫ ГОЛУБЕЙ ПРИ ОСТРОМ ЭКСПЕРИМЕНТАЛЬНОМ ПАНКРЕАТИТЕ

М. ПАПП, З. НАДЬ и И. ФОДОР

Введеные в проток поджелудочной железы голубей подсолнечное масло и дезоксихолат натрия вызывали острый панкреатит. Капельки подсолнечного масла попадали рано в ацинарные клетки и увеличивали в них число зимогенных зернышек различной степени зрелости и секреторную активность клеток. Резкая граница между зимогенными зернышками и окружающей их цитоплазмой стерлась, зимогенные зернышки проникли в окружающую их среду и (или) попали в аутофаговые вакуоли. Наблюдались также и вторичные вакуоли лизосомного характера. Подсолнечное масло вызывает аутолиз. Дезоксихолат натрия рано поражал ацинарные клетки, не изменив, однако, характерного расположения зимогенных зернышек, их формы или электронной густоты. Дезоксихолат натрия вызывает гетеролиз (цитолиз).

Dr. Miklós Papp: MTA KOKI, Budapest VIII. Szigony u. 43., Hungary
Dr. Zoltán Nagy: II. Kórbonctani Intézet, Budapest IX. Üllői út 93., Hungary
Dr. István Fodor: ORFI, Budapest II. Frankel Leo u. 17/19., Hungary

Acta Morphologica Acad. Sci. Hung. 19 (4), pp. 389—395, 1971

Department of Biology (Head: Doc. Dr. Z. SREBRO) and Department of Histology (Head: Doc. Dr. T. CICHOCKI), Institute of Biomorphology, Medical Academy, Kraków, Poland

PEROXIDASE ACTIVITY IN GLIA AND EPENDYMOCYTES OF THE MOUSE BRAIN

Z. SREBRO, T. CICHOCKI and J. GODULA

(Received September 28, 1971)

Peroxidase activity has been localized in ependymocytes and periventricular glial cells of the mouse brain. At the ultrastructural level the activity is found in 1000 Å large vesicles bounded by a double membrane. In addition, weak peroxidase activity was observed in the large dense bodies occurring in large numbers in periventricular glial cells.

Among animals tissue, peroxidase activity has been found in the proximal renal tubules, leucocytes, macrophages, lung epithelium and salivary glands [1—11, 14—17]. Ultrastructurally, the peroxidase activity is localized in microbodies (peroxisomes) [4, 7, 10, 11, 17], lysosomes [1, 3, 8], in the nuclear envelope and membranes of the endoplasmic reticulum [7]. As regards the central nervous system, there exists to our knowledge only the communication of ROGOVIN et al. [15], who showed that peroxidase activity in the central horn of the spinal cord is localized in lipofuscin granules, intramitochondrial granules, and the myelin sheath of axons. In the present report, observations on the ultrastructural localization of peroxidase activity in periventricular glial cells and ependymocytes of the mouse brain are presented.

Material and methods

Adult mice of both sexes of the inbred A strain were used. The animals were 3 months old and weighed 25 g. Immediately after decapitation very small fragments of periventricular brain tissue from the third brain ventricle were fixed by immersion in buffered 5% glutaraldehyde, pH 7.6, at 0°C, for 4 hr. The material was washed with 0.1 M phosphate buffer, pH 7.6, containing 5% saccharose, for 24—48 hr., and incubated for peroxidase according to GRAHAM and KARNOVSKY [12]. Control material was incubated in a medium from which the hydrogen peroxide had been omitted. The tissue was postfixed in 2% osmium tetroxide for 2 hr., embedded in Epon, and prepared for electron microscopy. 600—900 Å sections were made and stained with lead hydroxide [13]. The preparations were examined in a Tesla BS490A electron microscope. For light microscopy, material fixed in glutaraldehyde was cut in a cryostat and the sections were incubated in the Graham—Karnovsky medium.

Results

Light microscopically, peroxidase activity is localized in cytoplasmic granulations of periventricular glial cells and red blood cells (Fig. 1); no other structures in the brain tissue showed activity. At the ultrastructural level,

peroxidase activity is localized in the periventricular glial cells and in ependymocytes.

Fig. 2. shows a low power view of cells occupying the subependymal layer of the brain. These cells contain in the cytoplasm numerous vesicles about 1000 Å in diameter with an electron opaque core. This core shows a strong peroxidase activity as visible in Fig. 2 and the subsequent figures. The vesicles are bounded by a double membrane (Fig. 3). Along vesicles filled

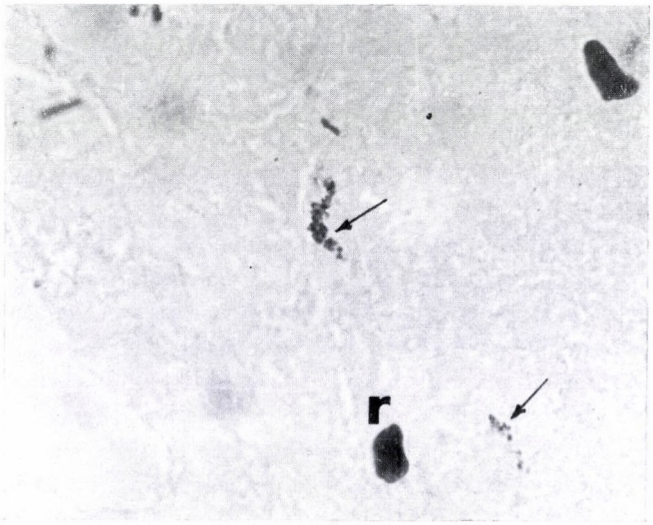

Fig. 1. Peroxidase reaction in a cryostat section of periventricular brain tissue of the mouse. Activity is present only in the cytoplasmic granulations of periventricular glial cells (arrows) and in red blood cells (r). (×800)

with the peroxidase-positive material, vesicles occur which do not show the electron-dense core or only a trace of it in the form of an electron-opaque central spot (Fig. 3). The vesicles lacking the core and those with the small one are most probably under formation. The cytoplasm of the peroxidase-positive hypependymal glial cells also contains large dense bodies bounded by a single membrane and showing a dense matrix (Figs 2—4). Generally, cells with numerous peroxidase-positive double membrane-bound vesicles show a type of dense body characterized by a homogeneous, granular matrix. This is characteristic of ependymocytes and subependymal gliacytes.

Periventricular glial cells occupying the deeper layers of the brain, although peroxidase-positive, present a somewhat different picture. The double membrane-bounded characteristic peroxidase-positive vesicles are not so numerous as in the former type of cell, while the dense bodies are more frequent (Fig. 4). Another difference is that many dense bodies show an internal lamellar

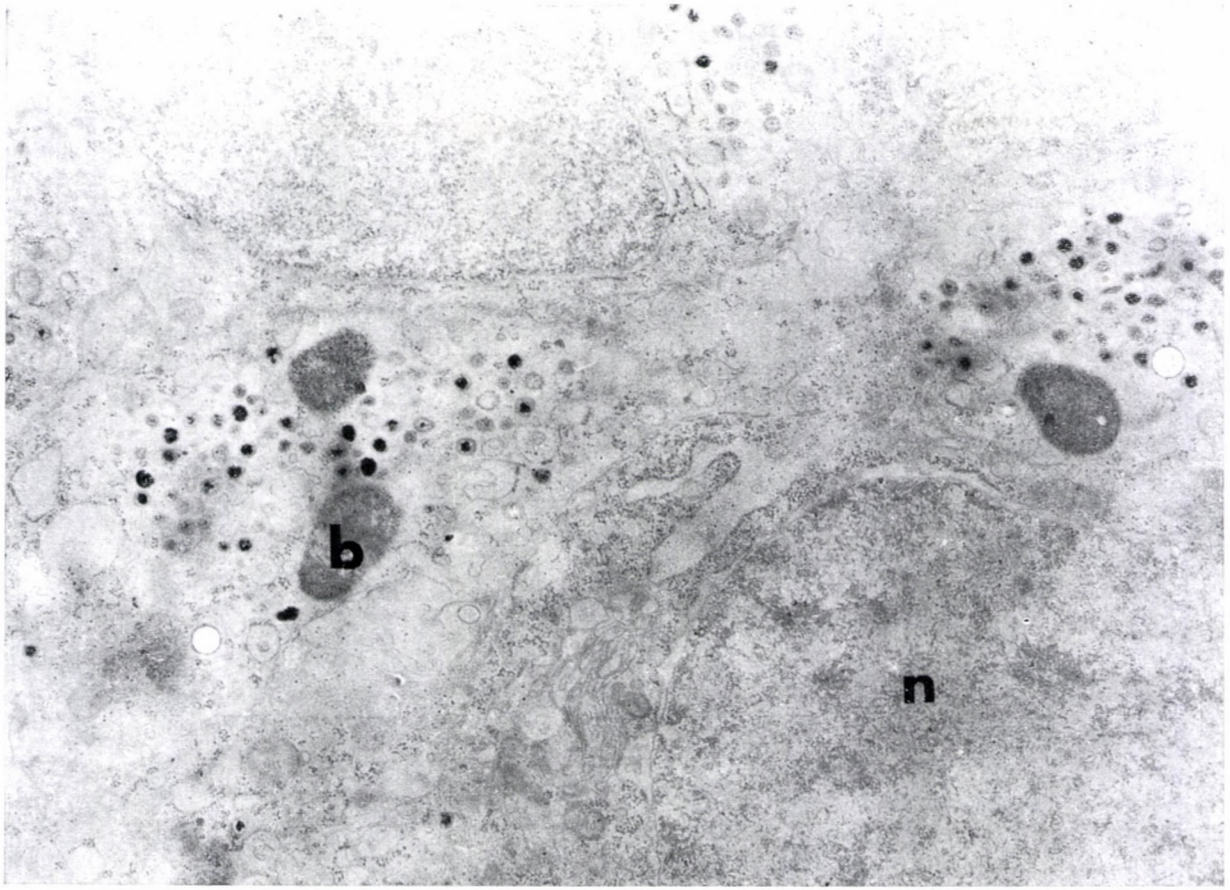

Fig. 2. Subependymal glia cytes of the mouse brain showing a positive peroxidase reaction. The activity is localized in numerous 1000 Å large cytoplasmic vesicles bounded by a double membrane. Large dense bodies with a granular matrix are also present (b); n = nucleus. Glutaraldehyde, peroxidase reaction of Graham and Karnovsky, osmium, lead hydroxide, Epon. (×8000)

structure. Different degrees of peroxidase positivity were seen in the dense bodies, the most frequent was a very weak one.

Both the ependymocytes and the periventricular glial cells, showing peroxidase activity in the typical double membrane-bounded vesicles, and the

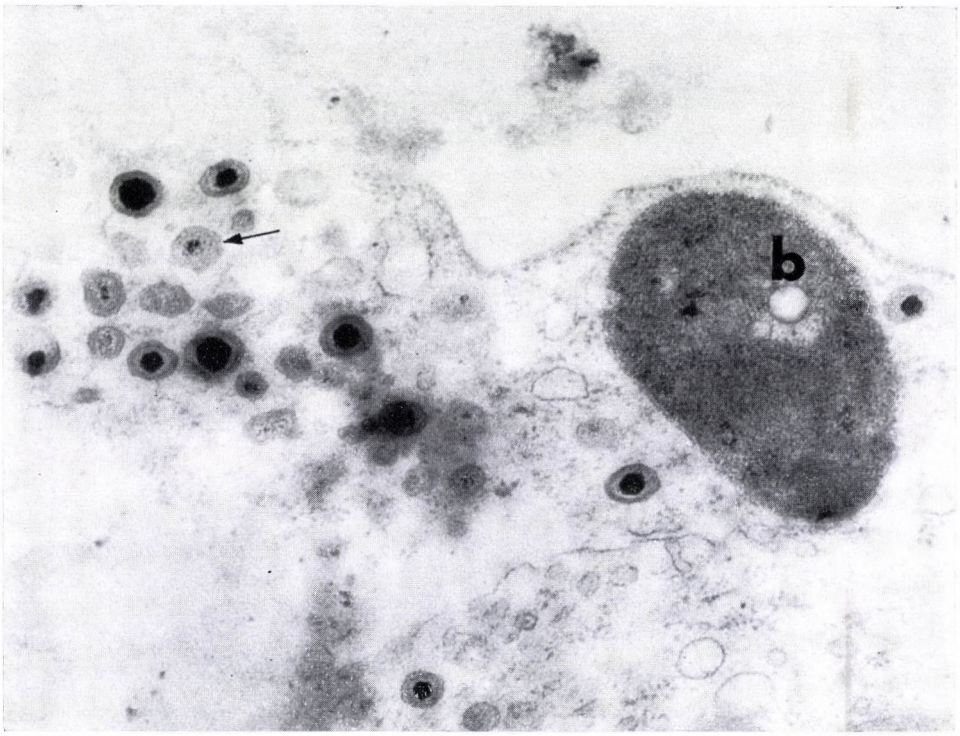

Fig. 3. Fragment of a peroxidase-positive subependymal gliacyte at higher magnification. A large dense body (b) and numerous double membrane-bounded vesicles showing strong peroxidase activity are seen. Vesicles are also present which contain only a small electron-dense spot in the centre (arrow). Glutaraldehyde, peroxidase reaction of Graham and Karnovsky, osmium, lead hydroxide, Epon. (×30,000)

numerous dense bodies, are characterized by copious rough endoplasmic reticulum. The cisterns of the endoplasmic reticulum form parallel stacks (Fig. 4) or are randomly distributed. Many cisterns are dilated, showing sometimes continuity with double membrane-bounded vesicles very similar to those with the peroxidase-positive dense core. Some of the dilated cisterns contain single membrane-bounded clear vesicles (Fig. 4).

A well-developed Golgi zone is observed in the peroxidase-positive glial cells, along with sparse mitochondria.

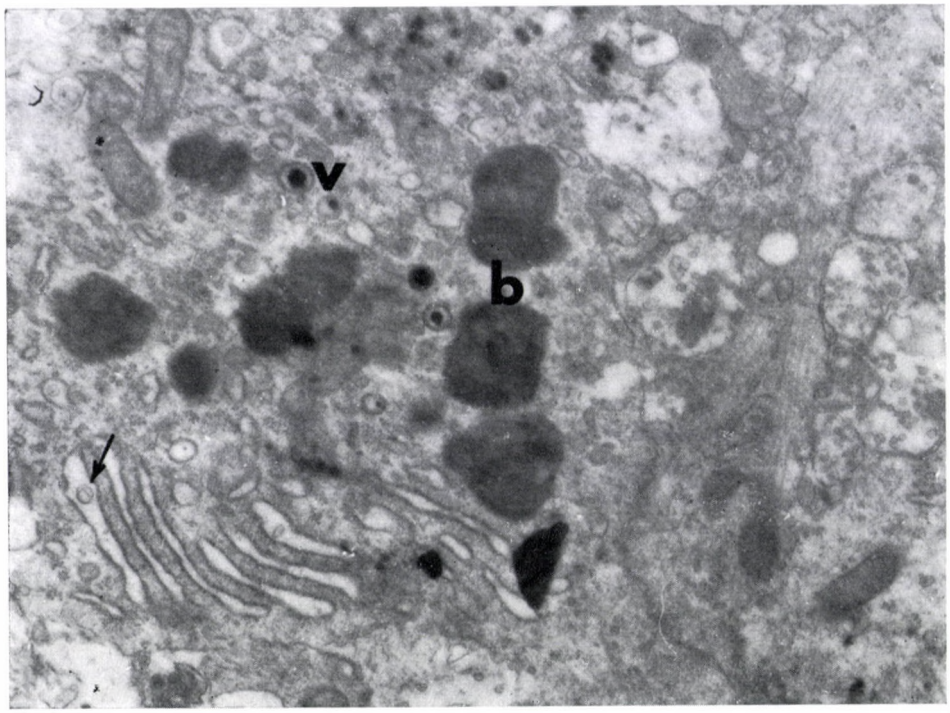

Fig. 4. Fragment of the cytoplasm of a periventricular peroxidase-positive glial cell. The characteristic double membrane-bounded vesicles showing peroxidase activity are sparse (v). Numerous dense bodies (b) with a delicate internal lamellar structure and weak peroxidase activity. Arrow indicates a clear vesicle contained in the profile of a cistern of the rough endoplasmic reticulum. The right portion of the figure is occupied by a typical neuropil. Glutaraldehyde, peroxidase reaction of Graham and Karnovsky, osmium, lead hydroxide, Epon. (×20,000)

Discussion

The results show that in the brain of mice there occur glial cells showing peroxidase activity localized in characteristic cytoplasmic structures. These are the double membrane-bounded vesicles which appear to arise in connection with the endoplasmic reticulum. Another characteristic feature of the peroxidase-positive glial cells is the presence in them of large cytoplasmic dense bodies. These dense bodies are of two types, one showing a granular homogeneous matrix, the second one containing in addition an internal laminar structure. The second type is prevalent in the periventricular gliacytes occupying deeper layers of the brain tissue. The dense bodies usually give a weak peroxidase reaction.

Thus, although peroxidase activity in the brain is localized to only one or two types of glial cells, it is nonetheless constantly found at characteristic

sites. The peroxidase-positive double membrane-bounded vesicles are different from any known structure found in the cellular elements of the central nervous system.

Peroxidase activity in kidney and liver cells is localized in peroxisomes [9, 10], the localization in other cell types varying considerably. Organelles of hypependymal gliacytes most resembling morphologically the peroxisomes are the dense bodies. Sometimes a regular paracrystalline arrangement of the internal lamellae can be observed resembling the ordered core of the peroxisomes. However, considerable differences also exist. The peroxidase-positive dense bodies in the glial cells are generally large, of uneven size and shape, showing sometimes vacuolation, the internal lamellar structures occupy a considerable proportion of the organelle mass. Thus, morphologically they resemble more the lysosomes. However, it has been shown that the peroxidase-positive granulations of the periventricular glia are negative for lysosomal enzymes [16]. The granulations of the periventricular glia are unusually rich in thiol groups [16] and it has been suggested that they may be involved in the decomposition of organic peroxides [16].

REFERENCES

1. Ackerman, G. A.: (1968) Lab. Invest. **19,** 290. — 2. Alexander, M. N.: (1959) J. biol. Chem. **234,** 1530. — 3. Bainton, D. F., Farquhar, M. G.: (1970) J. Cell Biol. **45,** 54. — 4. Beard, M. E., Allen, J. M.: (1968) J. exp. Zool. **168,** 477. — 5. Bloom, G. D., Carlsöö, B., Kumlien, A.: (1970) Histochemie **22,** 294. — 6. Carlsöö, B., Kumlien, A., Bloom, G. D.: (1971) Histochemie **26,** 80. — 7. Cotran, R. S., Litt, M.: (1970) J. Immunol. **105,** 1536. — 8. Cotran, R. S., Litt, M.: (1969) J. exp. Med. **129,** 1291. — 9. de Duve, C.: (1969) Proc. roy. Soc. Biol. (Lond.) **173,** 71. — 10. de Duve, C., Baudhuin, P.: (1966) Physiol. Rev. **46,** 323. — 11. Fahimi, H. D.: (1969) J. Cell Biol. **43,** 275. — 12. Graham, R. G., Karnovsky, M. J.: (1966) J. Histochem. Cytochem. **14,** 291. — 13. Karnovsky, M. J.: (1961) J. biochem. biophys. Cytol. **11,** 729. — 14. Petrik, P.: (1971) J. Histochem. Cytochem. **19,** 339. — 15. Rogovin, V. V., Muraviev, R. A., Pirusian, L. A.: (1971) Isv. Acad. Nauk. SSSR **3,** 453. — 16. Srebro, Z., Cichocki, T.: (1971) Acta histochem. (Jena) **41,** 108. — 17. Tsukada, H., Mochizuki, Y., Fujiwara, S.: (1966) J. Cell. Biol. **28,** 449.

PEROXYDASEAKTIVITÄT IN DEN GLIA- UND EPENDYMAZELLEN DES MÄUSEHIRNS

Z. SREBRO, T. CICHOCKI und J. GODULA

In Mäusehirn lokalisiert sich die Peroxydaseaktivität in den Ependymozyten und in den perivaskulären Gliazellen. Auf ultrastrukturellem Niveau beträgt die Aktivität 1000 Å und ist an Vesikeln mit doppelter Membrane gebunden. Gleichzeitig konnte eine schwache Peroxydase-Aktivität in den Dens-Körner großer Ausbreitung beobachtet werden, welche in großer Zahl in den periventrikularen Gliazellen zu finden waren.

АКТИВНОСТЬ ПЕРОКСИДАЗЫ В ГЛИОЗНЫХ И ЭПЕНДИМАЛЬНЫХ КЛЕТКАХ МОЗГА МЫШЕЙ

З. СРЕБРО, Т. ЦИХОЦКИ и Й. ГОДУЛА

Резюме

В мозге мышей активность пероксидазы локализируется в эпендимоцитах и в периваскулярных глиозных клетках. На ультраструктурном уровне активность связана с пузырками величиной в 1000 Å, обладающими двойной мембраной. Наряду с этим слабая активность пероксидазы наблюдалась в распространенных денсовых тельцах, которые обнаруживались в большом числе в перивентрикулярных глиозных клетках.

Dr. Z. Srebro
Dr. T. Cichocki
Dr. J. Godula
Institute of Biomorphology, Medical Academy, Kraków, Poland

Acta Morphologica Acad. Sci. Hung. 19 (4), pp. 397–415, 1971

First Institute of Pathology (Director: Prof. K. Lapis) and First Department of Ophthalmology (Director: Prof. M. Radnót), Semmelweis University Medical School, Budapest, Hungary

THE FINE STRUCTURE OF MAST CELLS IN THE TUMOURS OF PROTECTING ORGANS OF THE EYE

K. Lapis and M. Radnót

(Received April 10, 1971)

The ultrastructure of the mast cells occurring in the stroma of two neoplasms (squamous cell cancer, endothelioma) originating from the protecting organs of the eye has been studied. Two types could be differentiated. One of them is characterized by a cytoplasm filled with granules, whereas the other one contains only few granules and numerous vacuoles. The granules of the perineoplastic mast cells consist of the same two basic components as those of normal mast cells found in different tissues of the human organism. In the case of squamous cell cancer, some granules contained a third component, displaying a crystal-like formation. Five types of mast cell granules were differentiated on the basis of the distribution and organization of the subgranular structural components. As a rule, several types of granules are present in the mast cell. The size of granules in the perineoplastic mast cells was the same as in normal human tissues. A continuous or broken limiting membrane was observed around one third of the granules. Papyrus roll-like lamellar structures as well as structures displaying a lower level of organization were also observed in the cytoplasm, freely among the granules.

The mast cells have attracted attention long ago through their peculiar granules reacting with different stains [26, 27, 60, 61, 62]. They have also been studied electronmicroscopically in different specimens [10, 34, 35, 44, 48, 63, 64, 71]. The ultrastructural characteristics of the mast cells found in human skin [29], stomach [41], gum [78], tonsils [73], the connective tissue of the limbus [43] and the trachea [11, 61], have been described and their subcellular organization has been studied under normal and pathological conditions [36, 39].

A number of mast cells is always present among the cellular components of the stromal reaction appearing around malignant tumours [1, 13, 17, 23, 25, 42, 49, 50, 52, 55, 65, 66]. During the last years, the mast cells accumulating around cancers have been studied electronmicroscopically, too [49, 50]. However, these observations are not sufficient for drawing definite conclusions whether characteristic pathological alterations occur in the subcellular organization of such mast cells.

The present paper reports on observations concerning the ultrastructural organization of mast cells found in the stroma of a palpebral and an orbital tumour.

Material and methods

The important clinical data and pathohistological findings of the cases were as follows.

Mrs. S. I., 47 years old, had since one year a swelling on her lower lid which was slowly growing. At admission, on 5th October, 1970, we observed a swelling 17×4 mm in size in the central third of the lower lid on the right side, localized in the intermarginal line, involving the lachrymal point, infiltrating its surrounding and spreading over to the conjunctiva. The bulb was intact. The left side was normal. Pathohistological diagnosis: planocellular cancer.

Mr. H. P., 43 years old, had for several months a swelling of the left upper lid. Since a month he observed a node in the internal corner of the upper lid. At admission, on 26th August, 1970, the left bulb was protruded by 2 mm as compared to the right one. Cranial posterior-anterior and lateral X-ray revealed a soft shadow in the medial upper part of the left orbital cavity. The tumour removed by operation proved to be an endothelioma on the basis of histological and electronmicroscopical investigations. A detailed description of this case has been published elsewhere.

A remarkably large number of mast cells was present around the tumour in the first case and in scattered localization inside the tumour in the second one.

For electronmicroscopic study, specimens of less than 1 cu. mm volume were fixed immediately in 2% OsO_4 solution buffered with veronal-acetate according to PALADE [58] at pH 7.3 at 4°C for 1 hour. After dehydration in ethanol and propylene oxide, the material was embedded into araldite.

On the basis of half-thin sections stained with methylene blue, suitable blocks were selected, trimmed and ultrathin sections were cut. The sections stained with uranyl acetate and lead according to KARNOVSKY [45] were investigated in a JEM 7A electronmicroscope. Measurements of the granules were carried out on positive pictures prepared from the plates at a magnification of 3.4.

Results

The mast cells are large cells of oval shape, 20—25 μ in longitudinal and 8—12 μ in transversal diameter (Figs 1a and 2). As a rule, they have a round or oval nucleus 6—10 μ in diameter and of central localization. The double nuclear membrane is well outlined, the nuclear surface is smooth. Nuclei with a lobular or segmented surface were observed only occasionally. Cytoplasmic invaginations did not occur in the nuclei of mast cells.

The chromatin substance of the nuclei is of uniform distribution, no signs of marginisation appear, the nuclear substance is of medium electron density. In the majority of mast cell nuclei, there are irregular structures of high electron density and 0.03—0.1 μ in diameter, localized along the nuclear membrane at a distance of 300—400 Å (Figs 1a, 1b, 2, 5c and 8). They consist of aggregated granules of the ribosomal order of magnitude. They are distinguished from the environment by their high electron density. There is no limiting membrane around them.

The usually small nucleolus (Figs 1, 2 and 7) is conspicuous, its electron density being higher than that of the nuclear substance. As a rule, the nucleolus is localized centrally and contains the usual granular and fibrillar components. The brighter fields of lower electron density observable in the nucleolus correspond to karyoplasmic invaginations.

The most conspicuous components of the mast cell cytoplasm are the round or oval granules of high electron density and of varying size. On the basis of the number and distribution of the granules, one can distinguish two types of mast cells.

The first one (Figs. 1a and 7) is characterized by a cytoplasm crowded with granules of different internal structure, the other cytoplasmic organelles become insignificant, disappearing among the numerous granules of high density. Sometimes one can observe a narrow perinuclear zone of the cytoplasm devoid of granules, where numerous mitochondria, the centriole and the Golgi apparatus can be found (Figs 1a and 1b). The Golgi apparatus is usually weakly developed and mainly of lamellar construction. However, in the majority of the cells even the perinuclear zone is occupied by granules.

The other type of mast cell (Figs 2 and 5c) contains few dense granules; the greatest part of the cytoplasm is occupied by numerous electron transparent vacuoles different in size, limited by a single membrane. These vacuoles probably represent the structures remaining after the partial or total depletion of the granular content. This is indicated by the fact that some of them contain granulated material of considerable density, and occasionally even structures resembling lamellar papyrus rolls or corresponding to their fragments. This second type of mast cell appeared more frequently in the immediate vicinity of the cellular elements of the tumour, whereas the mast cell type crowded with granules was predominant somewhat farther from them.

Two basic components take part in the construction of the mast cell granules, viz. a fine granulated substance in different distribution and peculiar lamellar structures. The great majority of the mast cell granules consists of these basic components combined in different proportions. A third component, a peculiar crystal-like formation is also present in some granules. This, however, was observed only in the patient with epithelial cancer.

The granular component is either loose or dense, of uniform distribution, forming a ground substance or matrix of the granules. In other cases the granules aggregate and become arranged into capricious, wavy bundles about 50 mμ in diameter, forming a loose network covering the whole or part of the granule mainly the central one (Figs 3a, 3b, 3c, 4a, 4b, 4c).

The lamellar component forms characteristic structures reminiscent of papyrus rolls (Figs 3d, 3e, 3f, 3g, 3h). These consist of 3—7 membranes of concentric arrangement, separated by a uniform space about 150—180 Å in width. They appear in different forms according to the section plane. In the case of transversal section, one can see a fingerprint-like configuration, while the longitudinal sections result in cylindric formations limited by 3—4 membranes on both sides, the central part of which is filled by a fine granulated substance displaying an electron density lower than that of the limiting mem-

branes. The two ends of the cylindric formations melt into the surrounding granular substance without any distinct border.

The third, rather infrequent component of the granules is a crystal-like structure (Figs 5a and 5b) consisting of uniform linear elements of parallel arrangement. The linear elements are at constant distance from each other. They are composed by regularly arranged granules of uniform size. The crystal-like structure is embedded into a granulated matrix of higher electron density and less fine granulation.

The mast cell granules are round or oval structures 0.5—1 μ occasionally 1.5 μ in diameter. About one third of the granules is limited by a well outlined, single membrane (Figs 3a, 3c, 3d, 4a, 6a, 8). However, the limiting membrane is hardly or not at all recognizable in the majority of granules, especially around those of higher density, being of mixed or clearly lamellar composition (Figs 3f, 3g, 5a, 5b, 5f). On the basis of the variable proportions of the above components as well as the internal structure of the granules, the following types of granules could be distinguished.

There is a small number of granules which seem to be of purely granular composition (Type Gr.1) (Figs 3a, 3b, 3c). They are of high electron density, distributed uniformly, and crowded with the granular substance. As a rule, one can see no limiting membrane around this type of granule, probably because it confluates with the granular substance. On the other hand, occasionally a narrow, completely electron transparent halo appears between the dense granule of granular composition and the limiting membrane.

The second type of granule (Type Gr.2) is composed mainly by lamellar structures (Figs 3d, 3e, 3f, 3g, 3h). It is filled with fingerprint-like or cylindrical formations obtained on the transversal or longitudinal sectioning of the papyrus roll structures, the limiting membrane is smashed or recognizable only in sections on the surface of the granule, it is discontinuous or occasionally lacking. The quantity of granular components in these granules is rather small, and is distributed uniformly in the matrix or in the form of the granulated substance present in the cavities of the cylindrical formations. The arrangement of the papyrus roll-like structures in the granules is quite irregular and accidental. In this way they fall into the plane of section sometimes in longitudinal, sometimes in transversal direction.

Fig. 1a. Mast cell. The cytoplasm is crowded with granules of type Gr. 2 composed mainly by lamellar structures. Nucleolus (N1) of regular structure in the nucleus (N), granular formations of high electron density along the nuclear membrane (arrows). In the small granule-free region around the nucleus, mitochondria (M), centriole (C) and Golgi zone (G) can be seen. (×18,200)

Fig. 1b. The perinuclear granule-free region of the previous cell at higher magnification. Apart from the saccules of the centriole (C) and the Golgi zone (G), mitochondria (M) and the vesicles of the smooth endoplasmic reticulum (sEr) can be observed. Dense granular formations (arrows) near the nuclear membrane. (×36,000)

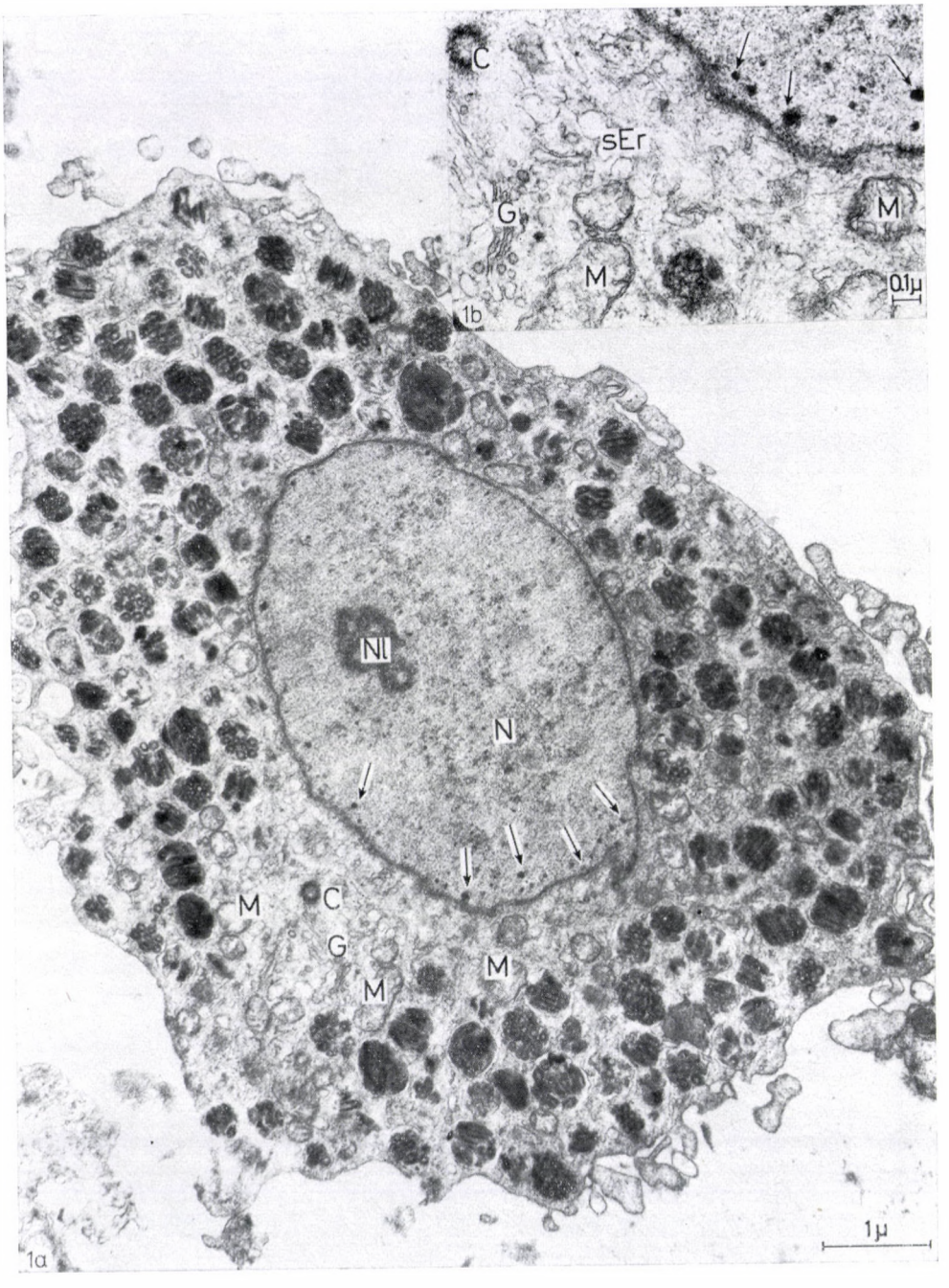
C
sEr
G
M
M
0.1μ
1b
Nl
N
M
C
G
M
M
1μ
1a

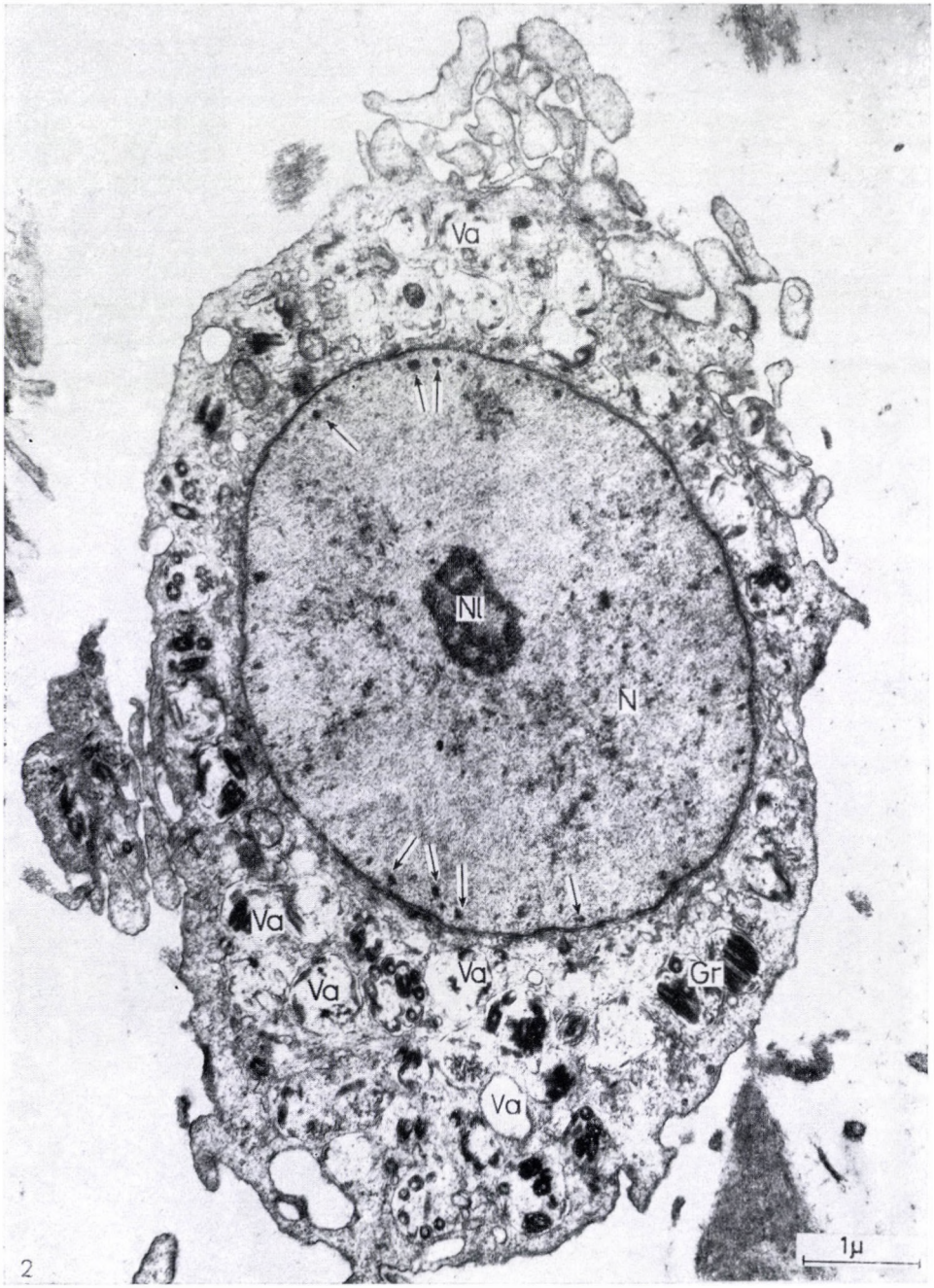

Fig. 2. A type of mast cell containing few granules (Gr) but numerous electron transparent vacuoles (Va). The nucleolus (Nl) in the nucleus (N) and dense granular formation (arrows) along the nuclear membrane can be seen

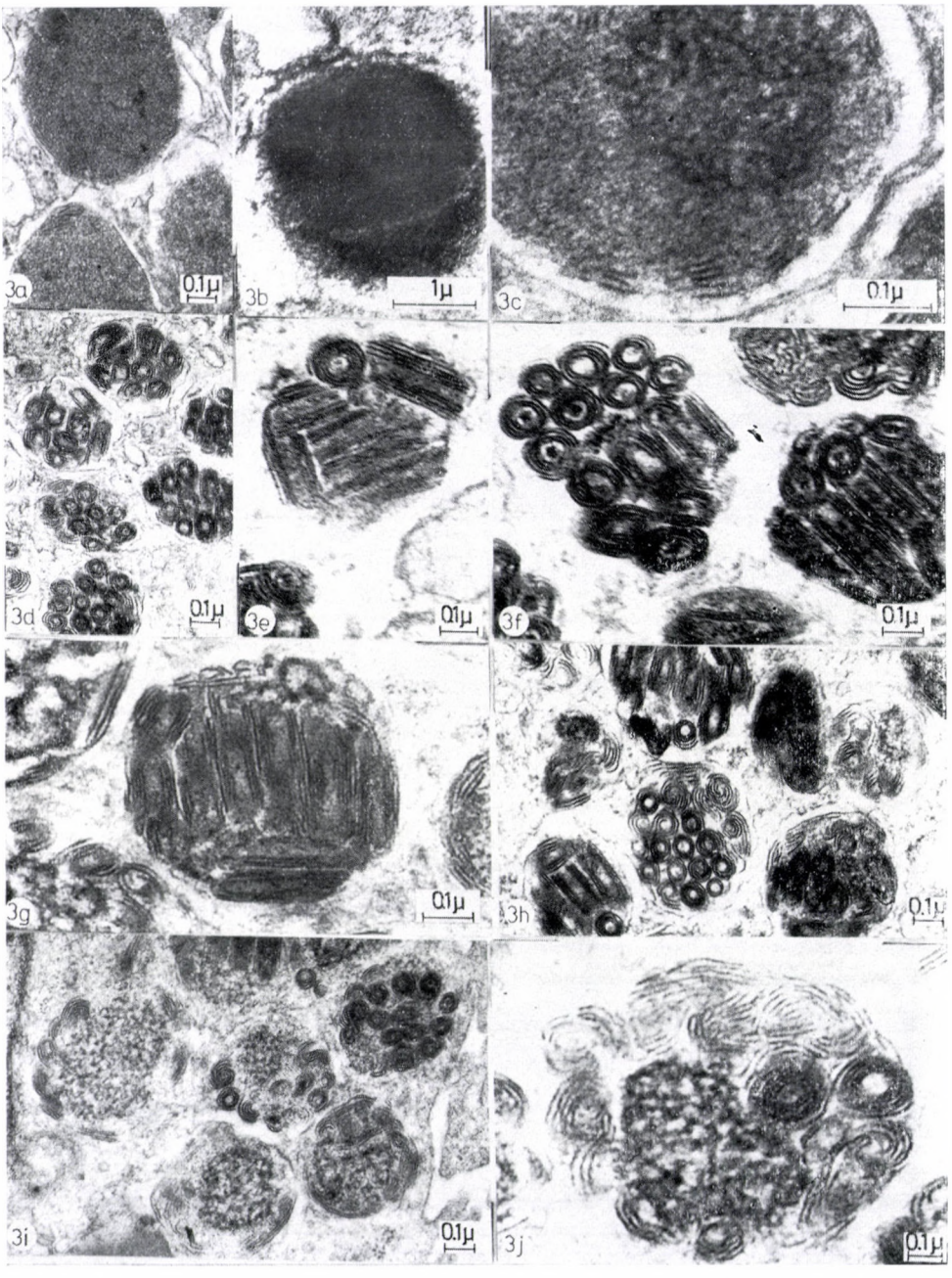

Fig. 3. Different types of mast cell granule. a), b) and c). Granules of purely granular composition (Type Gr. 1). (3a. ×44,700; 3b. ×15,000; 3c. ×150,500. d, e, f, g and h. Granules composed mainly of lamellar structures (Type Gr. 2). 3d. ×36,300; 3e. ×68,600; 3f. ×68,600; 3g. ×85,750; 3h. ×36,300. i. and j. Compound granules of mixed composition. Type Gr. 3a. 3i. ×44,500; 3j. ×68,600.)

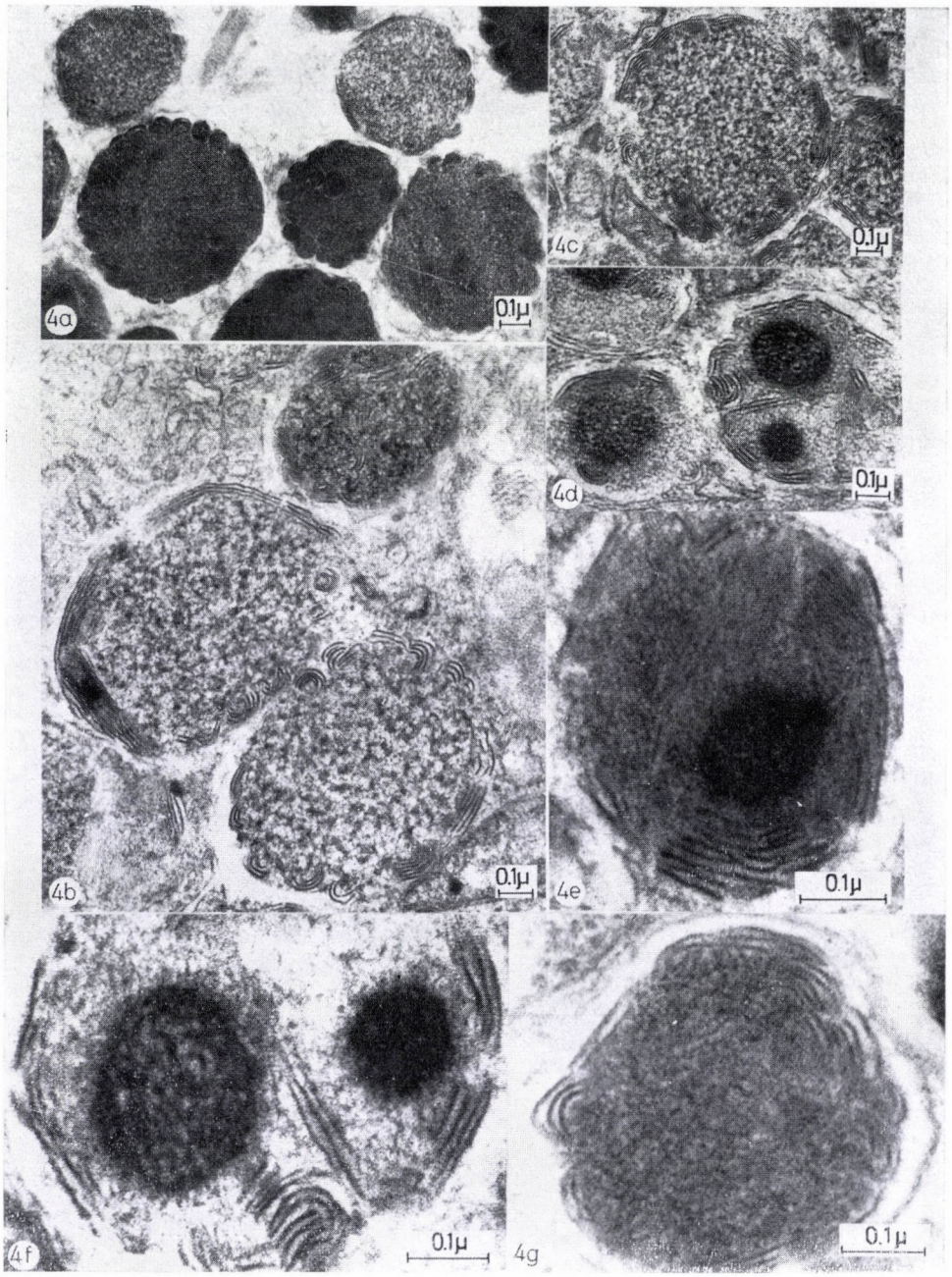

Fig. 4. Type Gr. 3b. of the compound granules of mixed composition. A narrow, electron-transparent zone can be observed between the granular substance and the surrounding unit membrane. (4a. ×44,500; 4b. ×57,400; 4c. ×44,500; 4d. ×51,000; 4e. ×150,500; 4f. 150,500; 4g. ×150,500.)

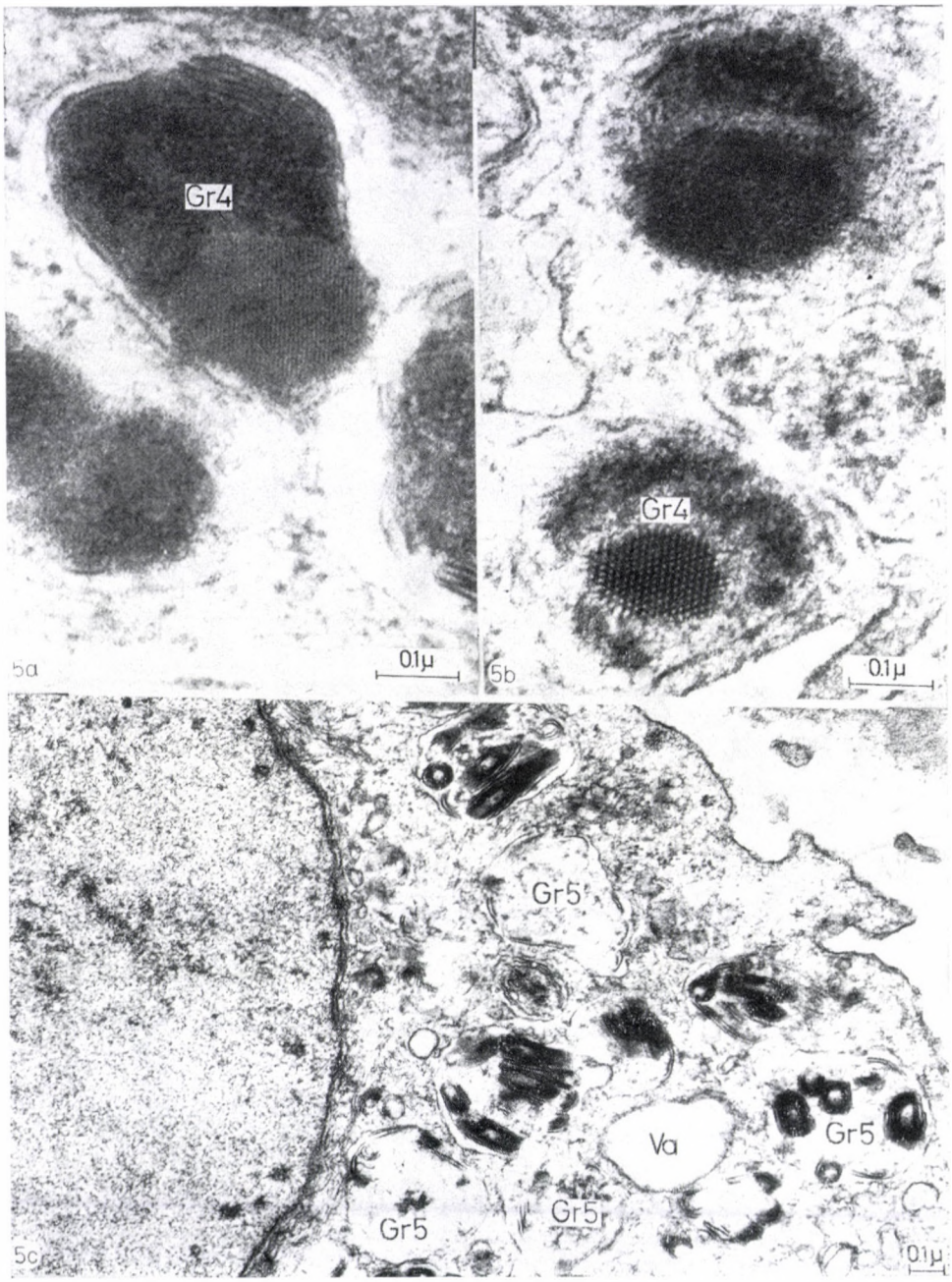

Figs 5a and 5b. Granules containing crystal-like formations. (Type Gr. 4). (5a. ×150,500; 5b. ×150,000)

Fig. 5c. Detail of a mast cell. Granular remains of heterogeneous appearance, formed in connection with the depletion of the granular content (Type Gr. 5), and electron transparent vacuoles (Va) in the cytoplasm. (×49,500)

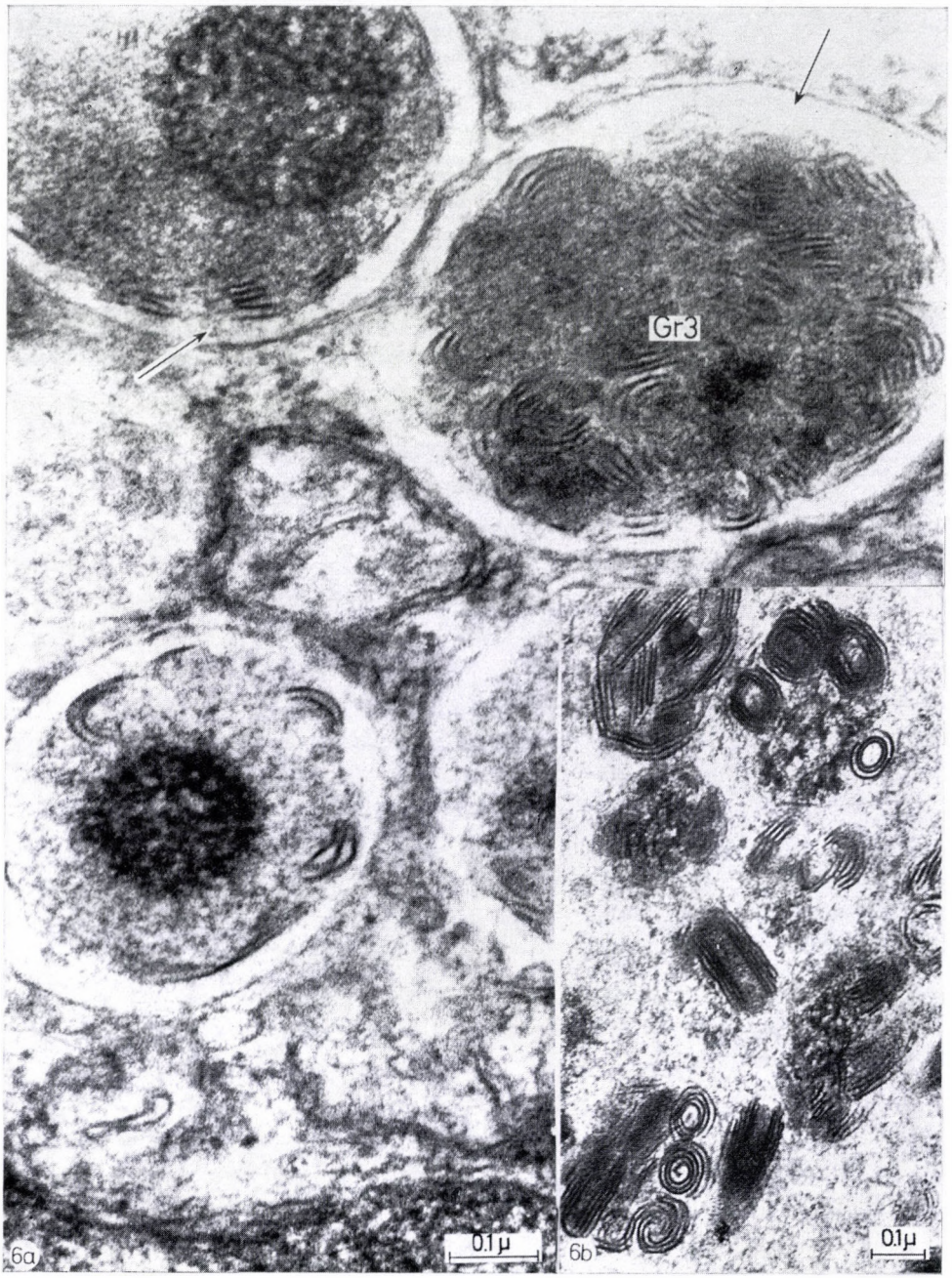

Fig. 6a. Compound mast cell granules of mixed composition. (Type Gr. 3) A narrow, electron transparent zone is to be seen between the granular substance and the limiting membrane (arrows). (×150,500)

Fig. 6b. Peculiar papyrus roll-like components of the mast cell granules, of free, "extra-granular" localization in the cytoplasm. (×85,750)

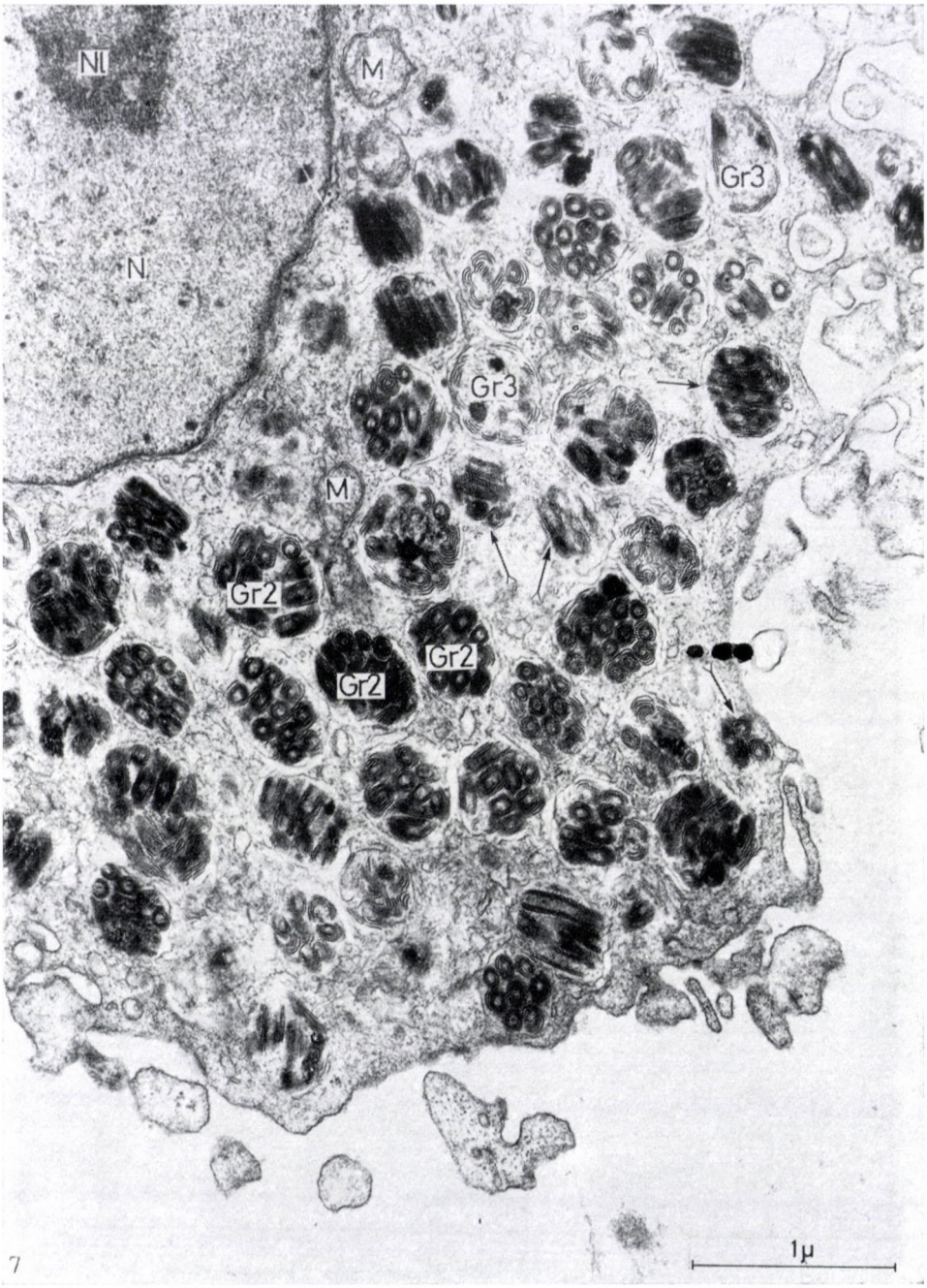

Fig. 7. Detail of a mast cell. The granules are filling the entire cytoplasm, the other cell organelles are in the background. Occasional mitochondria (M). The majority of the granules contains only lamellar elements (type Gr.2); compound granules of mixed composition (type G.3) also occur. Around the majority of the granules there is a limiting membrane often separated from the granular substance by a narrow electron transparent zone (arrows). The lamellar components of the granules are occasionally seen freely in the cytoplasm (double arrows). Detail of nucleolus (Nl) in the nucleus (N). (×36,300)

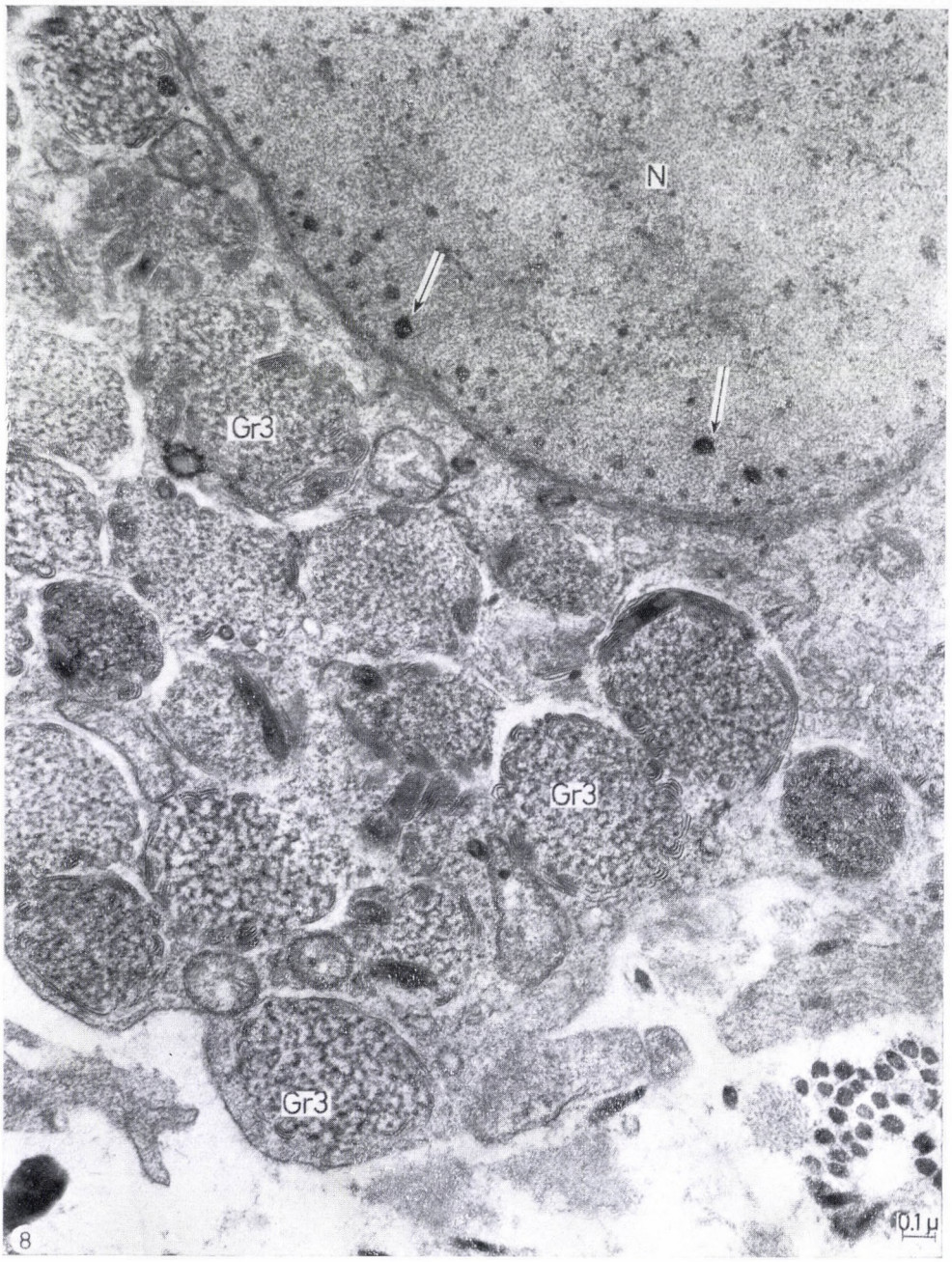

Fig. 8. Detail of a mast cell. The cytoplasm is filled by granules of decreased electron density, of mixed composition. (Type Gr. 3) Apart from the lamellar formations, a loose, network-like structure is to be recognized in the granular substance of decreased density. There is either no or only a discontinuous limiting membrane around the majority of the granules. Granular, dense formations are present in the nucleus of medium electron density (N) along the nuclear membrane. (×57,400)

The third type of granule (Type Gr.3) is a mixed or compound form (Figs 3i, 3j). In its composition both the lamellar and the granular components take part. According to the proportion and distribution of the two components, the internal structure of these granules is extremely variable. Two important forms can be distinguished.

In the first one the granular component forms capricious, dark bundles 50 Å in diameter. These net-like bundles of granular composition form threadball-like formations. The lamellar components are situated around the threadball-like formation, often at the margin of the granule. In other cases, half of the granule is occupied by a threadball of granular composition, while the other one contains lamellar structures (Figs 3i, 3j).

In the second form the granular component is predominant. The densely packed granules are filling the granule. This granular ground substance of either high or medium electron density contains several lamellar structures localized mainly at the periphery, immediately under the limiting membrane (Figs 4a, 4b, 4c, 4d).

The lamellar components are of less regular structure in the mixed or compound granules than in those composed clearly or mainly by the lamellar components. One can often see lamellar structures at the periphery of the granule, consisting of segments of circles differing in diameter, corresponding to the transversal section of a papyrus roll halved along its longitudinal axis (Figs 4b, 4f, 4g).

As a fourth type of granule (Type Gr. 4) one can mention those containing the crystal-like formation described above. This type occurred occasionally in the patient with squamous epithelial cancer (Figs 5a and 5b).

A separate fifth type (Type Gr.5) are the forms arising on depletion of the granular content (Fig. 5c). Strictly speaking this is not a type but a group of heterogeneous granule rests. Their common feature is that the limiting membrane is sharply outlined in some sections, while elsewhere it has disappeared completely. The most part of the granule is electron transparent with scattered rests of the granular component of medium electron density or those of the lamellar one of high density (Fig. 5c). The rests of the lamellar components are occasionally observed lying freely in the cytoplasm, so to say in "extragranular" localization (Fig. 6b).

Discussion

As far as the submicroscopic organization of the mast cell granules is concerned, crystalloid [7, 78], honeycomb-like [28] and granular [79] compositions are mentioned in the literature. The increasing number of ultrastructural investigations [4, 7, 8, 10, 12, 16, 24, 29, 31, 32, 34, 35, 41 ,43, 48, 54, 67, 73, 78]

has confirmed that granules of different submicroscopic organization can be separated in the same material or even cell. The majority of the ultrastructural differences, according to the opinion of more and more authors [31, 66, 69, 70, 72, 74] is determined by the chemical composition of the specific mast cell granule.

Considering this circumstance as well as the accumulation of mast cells around tumours [13, 18, 22, 25, 42, 49, 50, 55], furthermore, that the mast cell granules may contain different substances being able to influence the components, especially the ground substance of the connective tissue playing an important role in the progression and propagation of cancer [1, 4, 8, 19, 20, 21, 36, 39, 54], investigation of the subcellular organization of the mast cells accumulated around tumours may command a special interest in the general biology of cancers.

The present study was aimed at describing the ultrastructural characteristics and types of the mast cells found in the surroundings of tumours of the eye-protecting organs, and at comparing them with data, concerning the submicroscopic organization of mast cells occurring in different normal and pathological human tissues.

The characteristics of the mast cells are determined by the specific granules occurring in them. Relatively abundant and confirmed data are at disposal concerning the submicroscopic organization of these granules [4, 10, 12, 16, 28, 29, 32, 34, 35, 44, 48, 63, 64, 67, 74]. Essentially, the classification of mast cells is based on the differences observed in the number or structural characteristics of their granules. The pathological effects influence first of all the granules and manifest themselves in alterations of their number, size, shape, structure and composition. This is why our attention has been directed first of all to the granules. However, we have also studied the alterations occurring in the other organelles of the mast cells or in their organization.

The granules of human mast cells are composed of two basic components, a granular substance as well as lamellar structures of considerable density [51]. These components have been found in almost all granules of mast cells present in the different human tissues [4, 11, 13, 25, 29, 30, 31, 41, 43, 49, 50, 51, 73, 78] under both normal and pathological conditions. These two basic components may occur in different proportion and distribution in the granules.

The third and less constant component occurring infrequently in the human mast cell granules is a crystal-like structure displaying a fine linear pattern [29, 51].

A granular component is usually present in practically every other kind of secretory granule [5, 6]. Therefore, the lamellar structures can be considered characteristic components of the human mast cell, partly because similar structural elements have not been found in the mast cells of other species [61] apart from the mastocytomas of the mouse [15, 59], and also because they

have not been described in the other secretory granules of the human organism [51].

Whereas knowledge is relatively satisfactory concerning the chemical composition of the mast cell granules [8, 19, 33, 54, 67], the exact chemical composition of the subgranular components is not known. On the basis of certain electron cytochemical staining properties [46] one may, however, conclude with reservations that the lamellar components are rich in proteins, the granular ones rich in polysaccharides, whereas the crystal-like structures correspond probably to protein-polysaccharide complexes [37, 51]. The structural features are determined by the degree of sulphatation, the nature of proteins present in the granules and the relative amount of the proteins and polysaccharides [16]. The active substances stored in the mast cell granules seem to influence the structural organization to a lesser extent. For instance, histamine release is not necessarily accompanied by structural alterations [9, 28, 68].

KOBAYASHI and ASBOE-HANSEN [49, 50], observed different ultrastructural alterations in the mast cell granules in basocellular and squamous epithelial skin cancers. According to their findings, pathological alterations occurred only in the region of the cellular infiltration and in the mast cells localized in the tumour's immediate vicinity. This manifested itself in a change of the granular volume, namely in their swelling in the case of basocellular cancers, whereas, in the case of the squamous epithelial cancers significant alterations appeared even in the composition and organization of the granules as compared to those of normal tissues. The most significant difference was the appearance of pathological subgranular components such as crystalline structures, myelin formations composed by concentric lamellae in the granules. In addition, numerous mast cells showed a honeycomb-like structure of the cytoplasm, indicating its degranulation.

Two types of mast cells, one crowded with granules and another one containing only few granules but numerous electron transparent vacuoles were observed by us in the tumours of the protecting organs of the eye as well as in their surroundings. In this respect our findings agree essentially with those of KOBAYASHI et al. [51] concerning the mast cells of skin cancers. These authors described, apart from mast cells rich in granules, also mast cells poor in granules and showing a honeycomb-like cytoplasmic structure. They considered the latter type a consequence of degranulation, whereas CHRISTENSEN et al. [15] are of the opinion that they are characteristic of the young mast cell. According to our opinion this cytoplasmic structure is a result of degranulation, as supported by the fact that the granules observed in the cytoplasm of these cells are of a mature structure, the rests of lamellar structures can occasionally be recognized in the vacuoles, furthermore the so-called progranules [16] described as characteristic for premature mast cells,

localized around the Golgi zone and showing special structure, were absent in these cells.

The mast cell granules found in periocular tumours are composed by the same two basic components, namely the granular and lamellar structures (among the latter special, papyrus roll-like formations, too) as in those of the mast cells found in normal human tissues [4, 23, 29, 51, 56, 66, 74, 78] or in human skin cancers [49, 50]. The essential characteristics of the granules are determined by the proportion and distribution of these two basic components. Taking into consideration their proportion and distribution, we differentiated three types of granules occurring in both of our patients. There is no sharp border between the said types and transitional forms appear in a significant number. The different morphological pictures seem to be connected with the maturation of the granules. Even the presence of transitional forms supports this assumption.

KOBAYASHI and ASBOE-HANSEN [49] separated 6 types of granules in the mast cells found around basocellular cancers. They were able to register alterations even in the size of the different types of granules [49, 50, 51]. We have failed to find any considerable difference in size between the types of granules. The diameter of the granules was uniformly 0.35—0.75 μ in all types, which agrees with other data concerning the size of granules of human mast cells [4, 11, 29, 30, 31, 41, 43, 51, 73, 78]. There occurred significant differences from this value, the lowest and greatest granular diameters were 0.12 and 1.2 μ respectively.

The fourth type of granule containing the crystalline formations occurred only in the patient with squamous epithelial cancer, nevertheless, even there it was infrequent and sporadical. KOBAYASHI and ASBOE-HANSEN [50] described the type of granule containing crystalline structures as a characteristic manifestation of a pathological subgranular organization occurring in the mast cell granules around squamous epithelial cancer. However, these authors themselves [51] observed granules containing crystalline formations in the mast cells of the skin affected with another pathological process, urticaria pigmentosa. This fact as well as our observations according to which this type of granule appears even in mast cells around atheromas support the assumption that the crystalline structure cannot be considered a cancer-specific organization. Seemingly, this kind of subgranular organization may appear anywhere, if the granulogenesis or the depletion of the granular components are disturbed by some kind of pathological process taking place in the vicinity of the mast cells. We did not observe in our cases the other type of granules containing myelin-figures, described [50] in the mast cells of tumours and squamous epithelial cancers.

As far as its morphological appearance is concerned, the fifth type of granule described by us represents a rather heterogeneous group. The hetero-

geneous morphological appearance is connected with the depletion of the granular components as well as with its degree. It has been shown experimentally that similar changes are brought about in the ultrastructural organization of the mast cell granules during their depletion induced by different influences (X-ray, 48/80 treatment, etc.) [14, 36, 39, 47, 57, 67, 68, 69, 70, 75, 77].

Contrasting data are found in the literature concerning the limiting membrane of the mast cells. Several authors [4, 9, 53] described a distinct perigranular membrane around the mast cell granules, and considered its presence a criterion of the integrity and the good fixation of the mast cell granules. At the same time, there is usually no limiting membrane around the isolated mast cell granules [16]. Taking into consideration the data concerning the lysosomal nature of the mast cell granules [3, 38, 40, 76], the proteolytic activity of the granular components as well as the high, polyanionic heparin content of the granules, the maintenance of the integrity of the cell which contains these granules seems to be guaranteed only then, if the granule is limited by a membrane toward the surrounding cytoplasm. Therefore, it is surprising that KOBAYASHI and ASBOE-HANSEN [49, 50] should have been able to find a well-outlined, distinct limiting membrane only around 6.1% of the granules in the mast cells surrounding the basocellular carcinomas, and even in our material only about one third of the granules showed a well-defined limiting membrane. Most probably, the absence of a well-defined membrane or its discontinuity is an artifact of fixation and processing in a considerable part of the cases. On the other hand, the finding may be explained by a confusion of the membrane with the dense ground substance of the granules. Thus, it seems likely that the limiting membrane comes into being as a rule around every granule and exists till their lysis, and what is more, as it is shown by our findings, it persists during the lysis or even after it for some time.

Apart from the alterations of the granular organization of the perineoplastic mast cells, no characteristic ultrastructural changes have been reported [49, 50]. Neither have we observed specific and constant alterations, except a certain peculiar nuclear one, as compared to the ultrastructure of the mast cells of normal tissues.

The peculiar nuclear alteration observed in our cases involved the appearance of irregular, dense bodies of granular composition in the karyoplasm along the nuclear membrane. Similar formations have been described neither in the mast cells of normal human tissues nor in those found in the vicinity of pathological processes. The composition and significance of these bodies is unknown. One might expect an elucidation of the problems arising in connection with them from the method of preferential staining by EDTA (ethylene diamine tetraacetate) in aldehyde-fixed material as well as from the application of methods of enzyme digestion on ultrathin sections.

REFERENCES

1. Asboe-Hansen, G.: (1957) Cancer Res. **17,** 792. — 2. Athanassiades, Th. J., Herman L., Henninger, G. R.: (1965) Lab. Invest. **14,** 409. — 3. Benditt, E. P.: (1958) Ann. N. Y. Acad. Sci. **73,** 204. — 4. Benditt, E. P., Lagunoff, D.: (1964) Progr. Allergy, **8,** 195. — 5. Benedeczky, I., Lapis, K.: (1968) Beitr. path. Anat. **137,** 403. — 6. Benedeczky, I., Lapis, K.: Septième Congrès International de Microscopie Electronique, Grenoble. 1970. — 7. Bloom, G. D.: (1963) Ann. N. Y. Acad. Sci. **103,** 53. — 8. Bloom, G. D.: In: B. W. Zweifach, L. Grant, and R. T. McCluskey, (eds): The Inflammatory Process. Academic Press, New York, London. 1965. — 9. Bloom, G. D., Haegermark, Ö.: (1965) Exp. Cell. Res. **40,** 637. — 10. Bloom, G. D., Friberg, U., Larsson, B.: (1965) Nord. Vet-Med. **8,** 43. — 11. Brinkman, G. L.: (1968) J. Ultrastruct. Res. **23,** 115. — 12. Burton, A. L., Bensley, S. H.: (1958) Anat. Rec. **130,** 280. — 13. Cawley, E. P., Hochligeti, C.: (1961) Arch. Derm. **83,** 145. — 14. Chakravarty, N., Gustafson, G. T., Phil, E.: (1967) Acta path. microbiol. scand. **71,** 233. — 15. Christensen, H. E., Iversen, O. H., Rask-Nielsen, R.: (1963) J. nat. Cancer Inst. **30,** 763. — 16. Combs, J. W.: (1966) J. Cell Biol. **31,** 563. — 17. Cramer, W., Simpson, W. L.: (1944) Cancer Res. **4,** 601. — 18. Csaba, G., Forgács, A.: (1970) Acta morph. Acad. Sci. hung. **18,** 17. — 19. Csaba, G., Surján, L. jr.: (1970) Acta biol. Acad. Sci. hung. **21,** 243. — 20. Csaba, G., Török, O.: (1969) Acta biol. Acad. Sci. hung. **21,** 63. — 21. Csaba, G., Török, O.: (1970) Acta biol. Acad. Sci. hung. **21,** 273. — 22. Csaba, G., Oláh, I., Kapa, E.: (1970) Acta biol. Acad. Sci. hung. **21,** 255. — 23. Csaba, G., Ács, T., Horváth, C., Mold, K.: (1961) Brit. J. Cancer, **15,** 327. — 24. Csaba, G., Dunay, Cs., Oláh, I., Törő, I.: (1967) Acta biol. Acad. Sci. hung. **18,** 345. — 25. Dunn, M. R., Montgomery, O. B.: (1957) Lab. Invest: **6,** 542. — 26. Ehrlich, P.: (1877) Arch. mikr. Anat. **13,** 263. — 27. Ehrlich, P.: (1879) Arch. Anat. Physiol. **3,** 166. — 28. Fawcett, D. W.: (1955) Anat. Rec. **121,** 29. — 29. Fedorko, M. E., Hirsch, J. G.: (1965) J. Cell Biol. **26,** 973. — 30. Feeney, L., Hogan, M. J.: (1961) Amer. J. Ophthal. **51,** 185. — 31. Fernando, N. V. P., Movat, H. Z.: (1963) Exp. mol. Path. **2,** 450. — 32. Fujita, T.: (1965) Z. Zellforsch. Abt. Histochem. **66,** 66. — 33. Glick, D., Bonting, S. L., Denboer, D.: (1956) Proc. Soc. exp. Biol. (N. Y.) **92,** 357. — 34. Gusek, W.: (1960) Proc. Europ. Conf. on Electron Microscopy, Delft. 1960. **2,** 912. — 35. Gusek, W.: (1961) Arch. klin. exp. Derm. **213,** 573. — 36. Gustafson, G. T.: (1968) Acta path. microbiol. scand. **74,** 114. — 37. Gustafson, G. T., Phil, E.: (1967) Acta path. microbiol. scand. **69,** 393. — 38. Gustafson, G. T., Phil, E.: (1967) Nature (Lond.) **216,** 697. — 39. Gustafson, G. T., Phil, E.: (1967) J. Ultrastruct. Res. **20,** 300. — 40. Hashimoto, K., Gross, B. G., Lever, W. F.: (1966) J. invest. Derm. **46,** 139. — 41. Hibbs, R. G., Burch, G. E., Phillips, J. H.: (1960) Amer. Heart J., **60,** 121. — 42. Higuchi, K.: (1930) Folia haemat. (Lpz.) **41,** 401. — 43. Iwamoto, T., Smelser, G. K.: (1965) Invest. Ophthal. **4,** 815. — 44. Iwersen, O. H., Christensen, H. E., Rask-Nielsen, R.: (1964) Acta path. microbiol. scand. **60,** 194. — 45. Karnofsky, A. D.: In Plattner, Pl. A. (ed): Chemotherapy of Cancer. Elsevier Publishing Company, Amsterdam—London—New York. 1964. p. 3. — 46. Kay, D. H., Cosslett, V. E.: Techniques for Electron Microscopy, Blackwell, Oxford, 1965. p. 254. — 47. Kelényi, G.: (1953) Acta morph. Acad. Sci. hung. **3,** 377. — 48. Klug, H.: (1961) Acta biol. med. germ. **6,** 545. — 49. Kobayashi, T., Asboe-Hansen, G.: (1969) Acta derm.-venereol. **49,** 111. — 50. Kobayashi, T., Asboe-Hansen, G.: (1969) Acta derm.-venereol. **49,** 233. — 51. Kobayashi, T., Midtgard, K., Asboe-Hansen, G.: (1968) J. Ultrastruct. Res. **23,** 153. — 52. Koenig, W.: (1955) Z. ges. exp. Med. **126,** 64. — 53. Lagunoff, D.: (1968) Biochem. Pharmacol. Suppl. 221. — 54. Lagunoff, D., Phillips, M., Iseri, O. A., Benditt, E. P.: (1964) Lab. Invest. **13,** 1331. — 55. Lascano, E. F.: (1958) Cancer, **11,** 1110. — 56. Michels, N. A.: in: Downey: Handbook of Hematology. Vol. 1. Hoeber, New York, 1938. — 57. Mota, I., Ishii, T.: (1960) Brit. J. Pharmacol. **15,** 82. — 58. Palade, G. E.: (1952) J. exp. Med. **95,** 285. — 59. Rask-Nielsen, R., Christensen, H. E.: (1963) J. nat. Cancer Inst. **30,** 843. — 60. Recklinghausen, F. v.: (1963) Virchows Arch. path. Anat. **28,** 157. — 61. Rhodin, J. A. G.: The Connective Tissue. Williams and Wilkins, Baltimore, 1967. P. 1. — 62. Riley, J. F.: The Mast Cells. Livingstone, Edinburgh, 1959. — 63. Rogers, G. E.: (1956) Exp. Cell. Res. **11,** 393. — 64. Schauer, A.: (1962) Naturwissenschaften **49,** 382. — 65. Scott, K. G., Scheline, R. R., Stone, R. S.: (1958) Cancer Res. **18,** 927. — 66. Selye, H.: The Mast Cells. Butterworths, Washington, 1965. — 67. Serafini-Fracassini, A., Durward, J. J., Crawford, J.: (1969) J. Ultrastruct. Res. **28,** 131. — 68. Singleton, E. M., Clark, S. L.: (1965) Lab. Invest. **14,** 1744. — 69. Smith, D. E.: (1963) Ann. N. Y. Acad. Sci. **103,** 40. — 70. Smith, D. E., Lewis, Y. S.: (1955) Amer. J. Physiol. **183,** 662. — 71. Smith, D. E., Lewis, Y. S.: (1957) J. biophys. biochem. Cytol. **3,** 9. — 72. Smith, D. E.: (1963) Int. Rev. Cytol. **14,** 327. — 73. Stoeckenius, W.: (1965) Exp. Cell. Res. **11,** 656. — 74. Thiéry, J. P.: (1963) Mikroskopie, **2,** 549. — 75. Van den Brenk, H. A. S.: (1958) Brit. J. exp. Path. **39,** 356. — 76. Van Orden, L. S., III.,

VUGMAN, I., BENSCH, K. G., GIARMAN, N. J.: (1967) J. Pharmacol. exp. Ther. **158,** 195. — 77. VIKLICKY, V.: (1970) Folia biol. (Prague) **16,** 347. — 78. WEINSTOCK, A., ALBRIGHT, J. T.: (1967) J. Ultrastruct. Res. **17,** 245. — 79. WIGHT, P. A. L.: (1970) Acta anat. (Basel) **75,** 100. — 80. WINQUIST, G.: (1963) Ann. N. Y. Acad. Sci. **103,** 352.

DIE FEINSTRUKTUR DER MASTZELLEN BEI GESCHWULSTEN DER SCHUTZORGANE DES AUGES

K. LAPIS und M. RADNÓT

Verfasser untersuchten die ultrastrukturellen Züge der Mastzellen im Stroma von den Schutzorganen des Auges ausgehenden Tumoren (Epithelzellenkrebs, Endotheliom), aufgrund welcher sie zwei Typen der in den Tumoren vorkommenden Mastzellen unterschieden. Der eine Typ wird durch mit Granula überfülltem Zytoplasma, der andere Typ — durch wenig Granula aber viele Vakuolen enthaltendem Zytoplasma charakterisiert. Nach Beobachtungen der Verfasser nehmen im Aufbau der Granula der Mastzellen in der Umgebung von Tumoren dieselben zwei grundlegenden strukturalen Komponenten teil, wie im Falle der in verschieden normalen Gewebe des menschlichen Organismus befindlichen Mastzellen. Im Falle des Plattenepithelkrebses nahm in einem geringen Teil der Granula noch eine dritte Komponente — und zwar eine kristallähnliche Formation — an deren Struktur teil. Aufgrund der Verteilung der subgranularen strukturellen Komponenten unterscheiden die Verfasser 5 Typen der Mastzellengranula. In ein und derselben Mastzelle waren gewöhnlich mehrere Typen von Mastzellengranula vorhanden. Die Größe der Granula in der Umgebung des Tumors unterschied sich nicht von der Größe der Granula von in normalen menschlichen Geweben vorkommenden Mastzellen. Um ein Drittel der Granula beobachteten Verfasser das Bestehen einer kontinuierlichen oder diskontinuierlichen Membrane. Zwischen den Granula beobachteten Verfasser weiterhin sich frei im Zytoplasma befindliche Papyrusrollenartige, weniger hoch organisierte plattenartige Strukturen.

ТОНКАЯ СТРУКТУРА ТУЧНЫХ КЛЕТОК В ОПУХОЛЯХ ЗАЩИТНЫХ ОРГАНОВ ГЛАЗА

К. ЛАПИШ и М. РАДНОТ

Авторы изучали на двух опухолях, исходивших из защитных органов глаз (рак плоского эпителия и эндотелиома) ультраструктурные черты встречающихся в строме тучных клеток, на основании чего они дифференцировали два типа тучных клеток, встречающихся в опухолях. Один тип характеризуется битком набитой зернышками цитоплазмой, а другой тип характеризуется небольшим числом зернышек, но зато цитоплазмой, содержащей много вакуолей. На основании наблюдений авторов в структуре зернышек тучных клеток вблизи опухоли участвуют те же два основных структурных конпонента, как и в случае тучных клеток, имеющихся в различных нормальных тканях человеческого организма. В случае плоскоэпителиального рака в незначительной части зернышек в их структуре участвовал и третий компонент, а именно кристаллоподобное образование. На основании организации субгранулярных структурных элементов авторы дифференцируют пять типов зернышек тучных клеток. В одной и той же тучной клетке обычно было несколько типов зернышек. Величина зернышек в тучных клетках в окрестности опухолей не отличалась от таковой в тучных клетках нормальных человеческих тканей. Вокруг одной триты зернышек авторы наблюдали непрерывную и прерывистую перепонку. Между зернышками наблюдались также и свободно расположенные в цитоплазме папирусоподобные менее высоко организованные пластинчатые структуры.

Dr. Károly LAPIS: I. Kórbonctani Intézet,
Budapest VIII. Üllői út 26., Hungary
Dr. Magda RADNÓT: I. Szemészeti Klinika,
Budapest VIII. Illés u. 15., Hungary

Acta Morphologica Acad. Sci. Hung. 19 (4), pp. 417—432, 1971

Abteilung für Elektronenmikroskopie (Direktor: Prof. Dr. H. DAVID) des Pathologischen Instituts (Direktor: Prof. Dr. H. L. KETTLER) der Humboldt-Universität, Berlin, II. Pathologisches Institut (Direktor: Prof. Dr. H. JELLINEK) und I. Kinderklinik (Direktor: Prof. Dr. P. GEGESI-KISS) der Medizinischen Semmelweis Universität, Budapest*

LYMPHKNOTENULTRASTRUKTUR BEI NIEMANN-PICKSCHER KRANKHEIT**

T. KERÉNYI, J. ROMHÁNYI und G. PÓDER

(Eingegangen am 13. September, 1971)

Bei einem 9monatigen, an Niemann-Pickscher Krankheit leidenden Mädchen wurden die Speicherzellen eines subkutanen Lymphknotens histologisch und elektronenmikroskopisch untersucht. Im Lymphknoten konnte keine Fibrose nachgewiesen werden, die Struktur war erhalten, in der Umgebung des Lymphsinus ließen sich aber mehrere Speicherzellen beobachten. Elektronenmikroskopisch war in verschiedenen Zellformationen — Histiozyten, Retikulumzellen, Endothelzellen, glatten Muskelzellen der Blutgefäße, Lymphoblasten, Lymphozyten — eine Speicherung nachzuweisen. Hydration und Struktur der gespeicherten Substanz waren in den einzelnen Zelltypen unterschiedlich. In den Histiozyten traten Mitochondriendegeneration, Zytolysosombildung, atypische Zellorganellen und Kernveränderungen in Erscheinung. Außer den angeführten Veränderungen waren eigenartige Partikeln zu beobachten, welche einige Verfasser vorangehend in den Langerhansschen Zellen der menschlichen Haut und bei Histiocytose X vorgefunden haben.

Die chemische Struktur der bei Niemann-Pickscher Krankheit gespeicherten Lipide wurde durch die Untersuchungen von KLENK (1934) geklärt. Des weiteren vermochten DIEZEL (1954) sowie FEYRTER (1962) zu beweisen, daß die gespeicherte, vornehmlich aus Sphingomyelin bestehende Lipidmischung eine, den einzelnen Speicherzellarten entsprechend unterschiedliche Zusammensetzung zeigt. Die ultrastrukturellen Einzelheiten der Speicherzellen und ihrer Lipideinschlüsse wurden in den Leukozyten von LAZARUS und Mitarb. (1967), in der Milz und der Leber von Ross und Mitarb. (1961) sowie VOLK und WALLACE (1966), in hirnbioptischem Material von TERRY (1963) untersucht. Mit der diesbezüglichen Untersuchung der Lymphknoten haben sich TERRY (1963) sowie LYNN und TERRY (1964) befaßt.

In unserem, in vorliegender Arbeit dargestellten Fall vermochten wir einerseits bisher nicht beschriebene Speicherzellanomalien, andererseits gewisse Partikeln zu beobachten, die vorangehend von BIRBECK und Mitarb. (1961) in den Langerhansschen Zellen der Haut und von BASSET und TURIAF (1963) bei Histiocytose »X« vorgefunden worden waren.

* Für ihre, bei der Zusammenstellung und Abfassung unserer Arbeit geleistete Hilfe sind wir Herrn Prof. Dr. H. DAVID, Leiter der Elektronenmikroskopischen Abteilung d. Humboldt-Universität Berlin, Herrn Dr. P. WEISS und Frl. I. UERLINGS zu besonderem Dank verpflichtet.

** In den letzten Jahren wurde es klar, daß die Krankheit keine klinische und biochemische Einheit bildet. Bei bestimmten Formen ist die Sphingomyelin-Speicherung mit Cholesterin-Ablagerung begleitet (PHILIPPART u. Mitarb. 1969).

Material und Methodik

A. M. 9monatiges Mädchen. Klinikaufnahme wegen retardierter Entwicklung und hochgradiger Hepatosplenomegalie. Aufgrund der klinischen Befunde konnte die Gauchersche Krankheit ausgeschlossen werden. Blutausstrich: bei 50—60% der Lymphozyten und Monozyten trat vakuoliertes Plasma in Erscheinung. Im Knochenmarkpunktat befanden sich 40—60 μ große Schaumzellen. Histologischer Befund des entfernten pfefferkerngroßen Lymphknotens (rechts 6, ICR, in der vorderen Axillarlinie): erhaltene Struktur, keine Fibrose, im Sinus marginalis zahlreiche Lymphozyten; in der Umgebung des Randsinus sowie des Marksinus 20—60 μ große Schaumzellen mit eosinophilem Zytoplasma. Auf den hilusnahen Gebieten kamen diese Zellen in größerer Anzahl vor, außerdem war auch die Menge der durch dieselben gespeicherten und sich anläßlich der Einbettung ausgelösten Lipidsubstanz beträchtlicher. In den Gefrierschnitten färbte sich der Inhalt der Schaumzellen mit Sudan III lebhaft orange, und zeigte intensive Doppelbrechung. Eine ähnliche körnige Färbung ließ sich auch in den Paraffinschnitten nach Sudanschwarz-Färbung erkennen. Der Vakuoleninhalt erwies sich als PAS-negativ (FEYRTER, 1962; DIEZEL, 1954). Im Zytoplasma der Schaumzellen sowie der Endothelzellen der Kleinarterien und Postkapillaren, in dem mit Chromalaun fixierten und mit dem BAKERschen saueren Hämatein gefärbten Material waren bläulich-scharze Körnchen zu beobachten (Abb. 3c). Vorbereitung des Materials zur elektronenmikroskopischen Untersuchung: Fixierung der Rinden- und Markstückchen in einem aus 3 Vol. 4%iger Formalinlösung (HOLT und HICKS, 1961) und 1 Vol. 25%iger Glutaraldehydlösung (TÖRŐ, JOÓ, 1966) bestehenden Gemisch; Nachfixierung in isotonischer, gepufferter Osmiumtetroxydlösung (MILLONIG, 1962), Entwässerung in Alkohol, Einbettung in Durcupan. Zunächst wurden die aufzuarbeitenden Gebiete anhand der halbdünnen Schnitte ausgewählt; zur Verfertigung der Schnitte diente ein LKB-Ultrotom, zur Untersuchung der Präparate kamen die Elektronenmikroskope JEM 6C und Elmiskop IA (Siemens) zur Anwendung. Die Schnitte wurden mit gesättigter Uranylazetatlösung und Bleizitrat (REYNOLDS, 1963) kontrastiert.

Ergebnisse

Etwa 50% der Lymphozyten und nahezu 70% der Lymphoblasten enthielten 0,5—2 μ große elektronendichte Einschlüsse, unter denen einige mit einer Membran umgeben waren. Die sich in den Lymphozyten befindlichen Lipide verfügten über eine größtenteils feinkörnige, zuweilen aber über eine unregelmäßige, lamellare Struktur (Abb. 1a, b). In den, den Retikulumfasern entlang verlaufenden Retikulumzell-fortsätzen traten Einschlüsse in Erscheinung, die in bezug auf Größe und Struktur den Lipidkörpern der Lymphoblasten ähnlich waren (Abb. 1a). In den Retikulumzellen (Retikulumzellen und Histiozyten ließen sich nicht mit Sicherheit unterscheiden) und in den, von den Fasern unabhängig verlaufenden Fortsätzen derselben befanden sich 1—6 μ große Einschlüsse mit unregelmäßiger lamellarer Struktur. Die Densität des Inhalts der auf diesen Gebieten ebenfalls beobachtbaren Einschlüsse mit körniger Struktur war mit ihrer Größe umgekehrt proportional (Abb. 1c). In der Umgebung dieser Zellfortsätze konnte eine große Menge degenerierter Zellfragmente, extrazellulärer Zellorganellen (hauptsächlich Mitochondrien) sowie über eine körnige oder eine lockere, konzentrisch-lamellare Struktur verfügender Lipidkörper beobachtet werden (Abb. 1a, c, 3d). Die Mehrzahl der die regelmäßigste konzentrische lamellare Struktur aufweisenden Einschlüsse befand sich im Zytoplasma der Histiozyten (Abb. 1b, 2a, 3a, 7a).

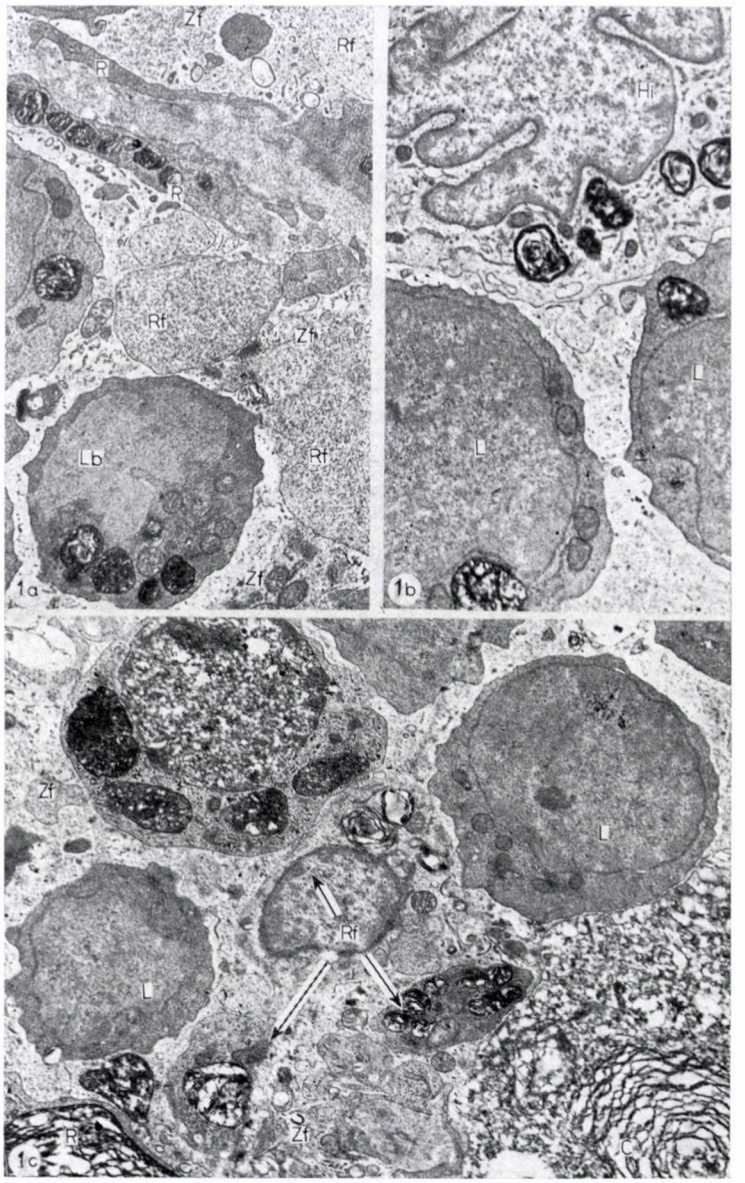

Abb. 1a. 0,5—2 μ große osmiophile Einschlüsse von identischem Typ im Plasma eines Lymphoblasts und im faserumhüllenden Fortsatz einer Retikulumzelle (R). Zellfragmente (Zf). Strukturlose Retikulumfortsätze (Rf). JEM 60, ×8200

Abb. 1b. Lipidkörper von unterschiedlichem Typ im Zytoplasma der Lymphozyten (L) und in einem Histiozyt (Hi). Die im Histiozyt ersichtlichen Einschlüsse verfügen über eine konzentrisch-lamelläre Struktur. JEM 60. ×10 400

Abb. 1c. Unter den Lymphozyten befinden sich Retikulumzellfortsätze mit Einschlüssen von unterschiedlicher Größe, Struktur und Densität. Retikulumzelle mit hochgradiger Speicherung (R). Zyklomembranöse Struktur in einer zerfallenden Zelle (C). Zellfragmente (Zf). JEM 6C. ×3200

Die Periodizität der Membran betrug 90 Å (Abb. 3a, 7a). Mitunter kamen auch in ein und derselben Zelle Einschlüsse mit einer lamellaren bzw. körnigen Struktur vor (Abb. 3a). Die Endothelzellen der Gefäßwand zeigten ein hochgradiges, die Glattmuskelzellen und Perizyten ein etwas mäßigeres Speicherungsvermögen (Abb. 3b, 3d). In den letzterwähnten Zellen ließen sich vorwiegend 0,4—1 μ große, über eine unregelmäßige Lamellarstruktur verfügende

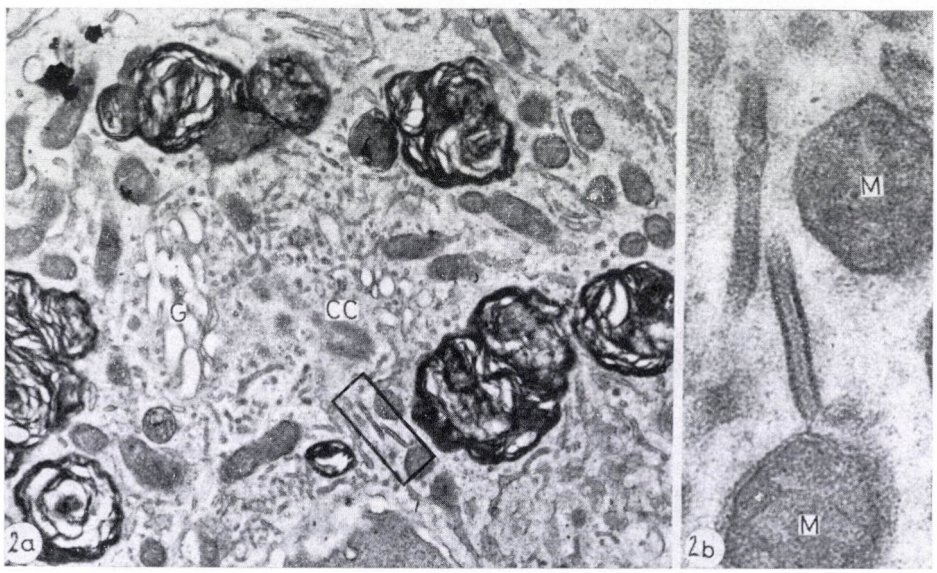

Abb. 2a. In einem, in der Umgebung des Golgischen Feldes (G) und des Zytozentrums (CC) liegenden Histiozyt lamellenförmige Speicherkörper. In der Nähe des glatten endoplasmatischen Retikulums zwei Langerhanssche Körper (eingerahmt). JEM 6C. ×15 000
Abb. 2b. Stärkere Vergrößerung der in Abb. 3a dargestellten Langerhansschen Körper. Mitochondrien mit verschwommener Struktur (M). JEM 6C. ×40 000

Lipideinschlüsse erkennen. Stellenweise war das Endothel der Arteriolen fenestriert. Die Lipideinschlüsse der Lymphozyten und Lymphoblasten standen mit den geringzahligen Zellorganellen in keiner Verbindung, in den Histiozyten konnte aber — vornehmlich in der Umgebung des Golgi-Apparats und des vermehrten glatten endoplastischen Retikulums — eine Anhäufung von Speicherkörpern beobachtet werden (Abb. 2a). Während etwa 40% der Histiozyten-Mitochondrien von normaler Struktur waren, ließen sich bei mehr als der Hälfte dieser Gebilde Strukturanomalien feststellen: Quellung, Auflösung der Struktur, Teilung der Mitochondrien (Abb. 4a), Myelinfigurbildung (Abb. 4b), Verdickung und Fragmentation der äußeren Grenzmembran (Abb. 5a), homogene und lamellare Lipideinschlüsse in den Mitochondrien sowie in ihrer unmittelbaren Nähe (Abb. 4c, 5b). In den Lymphozyten- und Lymphoblast-Mitochondrien ist die Struktur fast nicht mehr zu erkennen, auf der Ober-

fläche befinden sich kleine, mit Matrix ausgefüllte Protrusionen, wo auch die äußere und innere Membran ineinanderschmilzt. In den intensiv speichernden Histiozyten waren die freien Ribosome gering an der Zahl und auch der Gehalt an endoplastischem Retikulum war niedrig, dagegen enthielten sie häufig Zytolysosome mit einem ribosomalen oder mitochondrialen Inhalt oder mit endoplasmatischen Retikulumfragmenten. In den meisten dieser Zytolysosomen befanden sich nebst normalen Plasmabestandteilen auch feinkörnige oder unregelmäßig lamellierte Lipideinschlüsse (Abb. 6a, b). In einer anderen Gruppe der Zytolysosome ließ sich eine ausdrückliche Verdichtung des Zytoplasmas beobachten. Im Zytoplasma der aktiv-eiweißsynthetisierenden Zellen — welche beträchtliche Mengen der Ribosome und der endoplasmatischen Retikula enthielten — traten häufig flockige Vakuolen mit mäßiger Elektrondensität in Erscheinung (Abb. 6c). Einige dieser Gebilde standen mit Myelinfiguren, wieder andere mit Lipideinschlüssen im Zusammenhang (Abb. 6d), ihre dreischichtige Membran war von auffallender Dicke (90—100 Å) (Abb. 6d). Im Plasma der Histiozyten waren — besonders in der Nähe des Kerns und des Golgi-Apparats — 0,2—0,8 μ lange, 500—600 Å breite, mit einer dreischichtigen, 90—100 Å dicken Membran umgrenzte stabförmige Organellen vorzufinden (Abb. 2a, b, 7a). In einem Teil dieser Organellen verlief in der Mitte, zwischen den Grenzmembranen eine, über eine charakteristische (110—150 Å) Querstreifung verfügende, oder eine doppelte, keine Periodizität aufweisende Linie (Abb. 7a). Fallweise vermochten wir derartige Organellen auch unter den Zellfragmenten im extrazellulären Raum nachzuweisen (Abb. 7b, s. Pfeil). In ihrer Umgebung befand sich zumeist endoplasmatisches Retikulum mit glatter Oberfläche (Abb. 2a) und mehrere 1300—1800 Å große, runde, doppelwandige Gebilde (Abb. 7b, c). Zuweilen blähte sich das eine Ende dieser stabförmigen Körper auf, worauf sie die Form eines Tennisschlägers annahmen. In einigen Fällen standen diese Strukturen mit doppelwandigen runden Körpern im Zusammenhang (Abb. 7c). An anderen Stellen bildeten diese runden Körper, in paarweiser Anordnung, brillenartige Formationen (Abb. 8a).

Im Kern der Histiozyten befanden sich zahlreiche Perichromatingranula, in der Mitte des Kerns traten von Fall zu Fall 0,2—0,6 μ große, mit feinflockiger Substanz ausgefüllte Vakuolen in Erscheinung (Abb. 8b). In der Umgebung der Zellfortsätze waren nebst den strukturarmen interstitiellen Zellfragmenten häufig auch Demarkationserscheinungen zu beobachten (Abb. 8c).

Besprechung

Die lamellöse Struktur der Einschlüsse wurde durch die meisten Forscher, die sich mit der Ultrastruktur des bei Niemann-Pickscher Krankheit gespeicherten Lipidgemisches befaßten, erwähnt (Ross und Mitarb., 1961;

TERRY, 1963; LYNN und TERRY, 1964; CASPER und WOLMAN, 1964; KING, 1966; DAVID, 1967; GALFI, 1967). Die Untersuchungen von ROSS und Mitarb. (1961) in bezug auf die in den Milz- und Leberzellen beobachtbaren Speichervakuolen bei verschiedenen Thesaurismosen ergaben, daß die Ultrastruktur der erwähnten Gebilde charakteristisch und von diagnostischem Wert ist. In unserem Fall, in dem ausgedehnter Zellzerfall vorlag, ergibt sich jedoch die Frage, ob wohl sämtliche Lipide die Produkte des primär-pathologischen Stoffwechsels sind, oder ob zumindest in den Histiozyten, die Einschlüsse zum Teil auch Strukturlipide enthalten. In diesen Fällen gelangen in den Einschlüssen — wahrscheinlich den eigenartigen Stoffwechselverhältnissen der Histiozyten zufolge — die polaren Lipidmolekeln zum Übergewicht (DIEZEL, 1964; CASPER und WOLMAN, 1964; STEJSKAL und Mitarb., 1966; LAZARUS und Mitarb., 1967; PHILIPPART und Mitarb., 1969) und bilden im wässerigen Medium sich regelmäßig anordnende Myelinfiguren (STOECKENIUS, 1959, 1962). Werden unsere Aufnahmen mit den Abbildungen der erwähnten Verfasser verglichen, so ergibt sich, daß die obige Feststellung in bezug auf die Lymphknoten — trotz der Variabilität der Lipideinschlüsse — gültig ist. Aufgrund der beobachteten Erscheinungen, d. h. der großen Menge der extrazellulär liegenden Lipideinschlüsse und des Zellzerfalls, dürfte auch die Möglichkeit einer eventuellen Klasmatose erwogen werden.

Die geringe Menge des zur Verfügung stehenden Untersuchungsmaterials ermöglichte die Durchführung einer eingehenden histochemischen Analyse — so z. B. die Pyridinextraktion — bedauerlicherweise nicht. Die eine unterschiedliche elektronenmikroskopische Struktur aufweisenden Lipidkörper ergaben aber lichtmikroskopisch stets identische Färbungsreaktionen. Da bei der Niemann-Pickschen Krankheit nicht nur der Sphingomyelin-Stoffwechsel, sondern auch der Zerebrosid-Umsatz gestört sind, dürfte angenommen werden, daß in jenen Zellen, in denen sich Einschlüsse mit einer körnigen Struktur befinden, die in geringerem Maße polaren Zerebroside und Ganglioside überwiegen (DIEZEL, 1954).

→

Abb. 3a. Feinkörnige und lamellöse Einschlüsse im Histiozytenplasma; das letzterwähnte Gebilde besitzt ein inhomogenes Zentrum. Die 35 Å dicken Lamellen verlaufen in einer Entfernung von 90 Å parallel oder auch paarweise nebeneinander. Zwischen den beiden dicken Lamellen ist eine etwa 10 Å dünne Linie ersichtlich. Siemens I. A., ×76 400

Abb. 3b. Tangential geschnittene Wand einer kleinen Arterie mit lipidspeichernden glatten Muskelzellen (↑). Hochgradige Speicherung in der Endothelzelle (E). Basalmembran (B). Siemens I. A. ×8000

Abb. 3c. Hilusarterie des Lymphknotens. Dunkle Färbung der phospholipidspeichernden Endothelzellen (Backersche saure Hämateinfärbung); die roten Blutkörperchen färbten sich ebenfalls dunkel. ×120

Abb. 3d. Arteriole mit speicherndem Endothel (E) und Glattmuskelzellen (MC). Im Lumen ist ein Lymphozyt mit einem Lipidkörper ersichtlich. Die Einschlüsse sind größtenteils kleiner als 1 μ, elektronendicht, feingranuliert oder unregelmäßig lamellös. In der Umgebung eines Histiozytenfortsatzes (Hi) degenerierte Zellbestandteile: Lipidkörper (↑) und Mitochondrien (‡). Siemens, I. A. ×8000

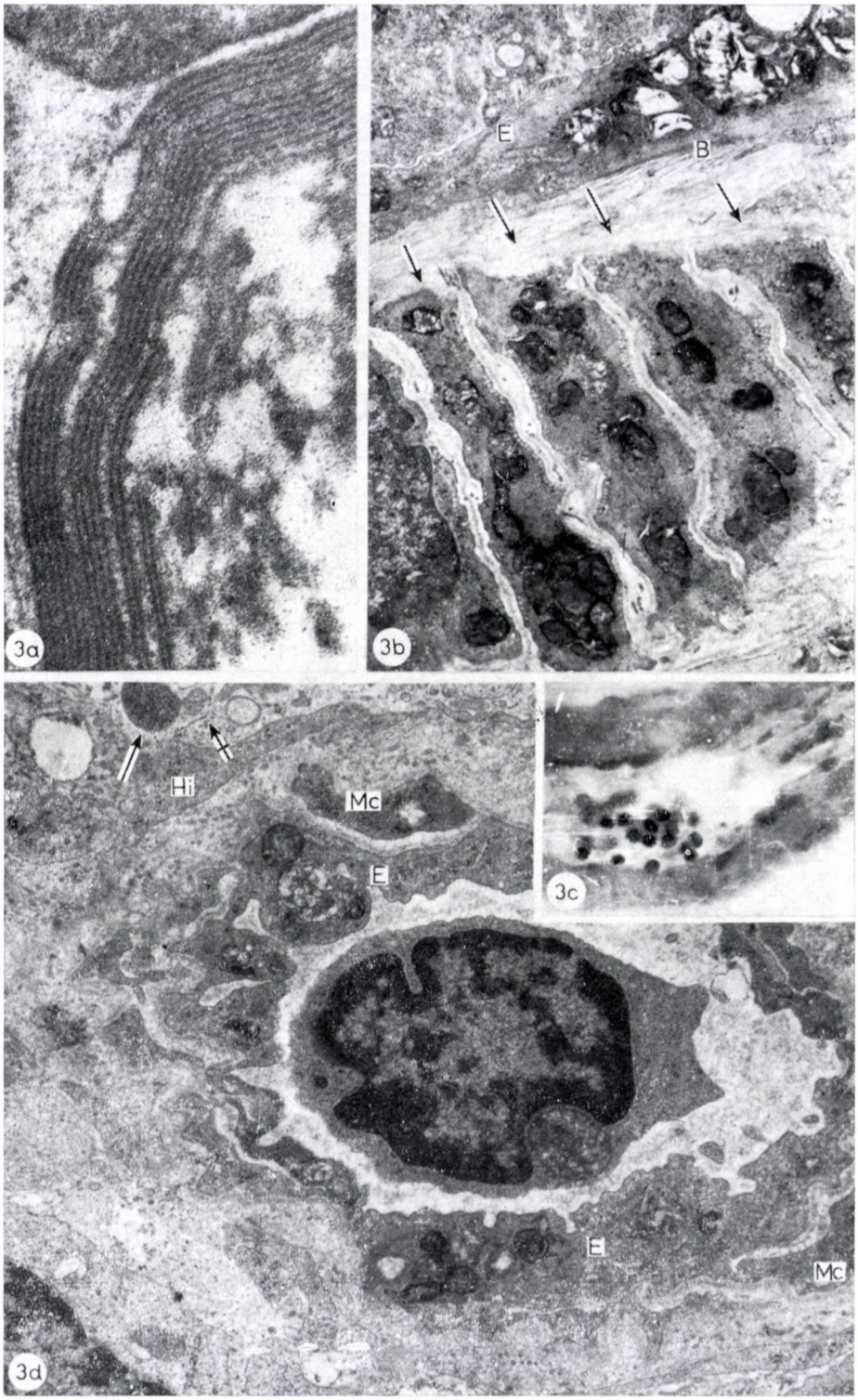
3a
E
B
3b
Hi
Mc
E
3c
E
Mc
3d

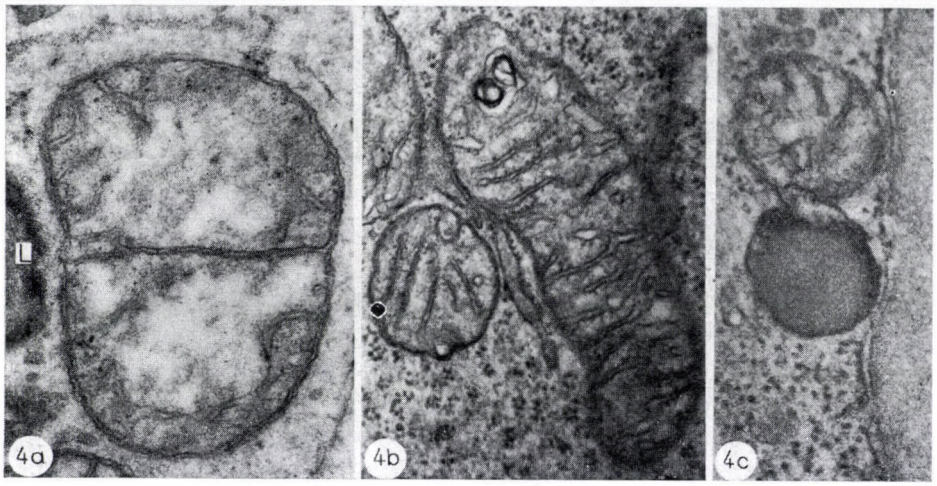

Abb. 4a. Angeschwollenes, sich teilendes Mitochondrium im Histiozyt. Lipidkörper (L). Siemens I. A. ×48 000

Abb. 4b. Myelinfigurbildung in der Umgebung der Christae mitochondriales. Siemens, I. A. ×36 000

Abb. 4c. Homogener Lipidkörper in Verbindung mit einem Mitochondrium. Siemens I. A. ×48 000

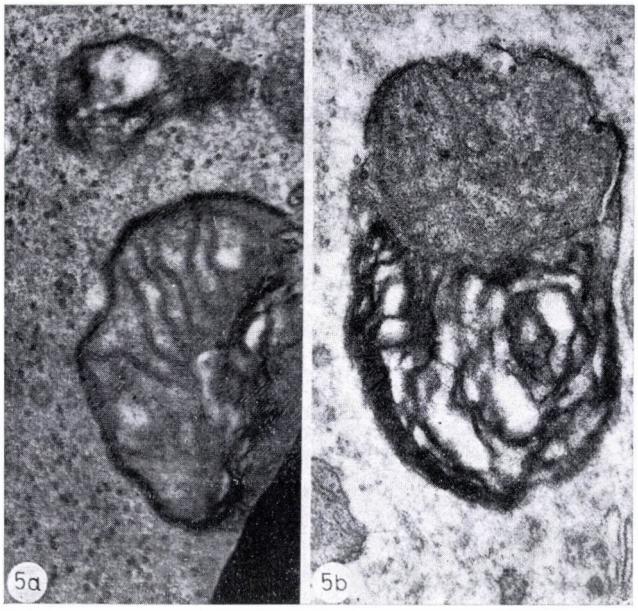

Abb. 5a. Diffuse Vermehrung und osmiophile Umwandlung der äußeren Mitochondriummembran im Histiozyt. Siemens I. A. ×48 000

Abb. 5b. Lamellöser Lipidkörper in enger Verbindung mit einem degenerierten Mitochondrium. Siemens I. A. ×88 000

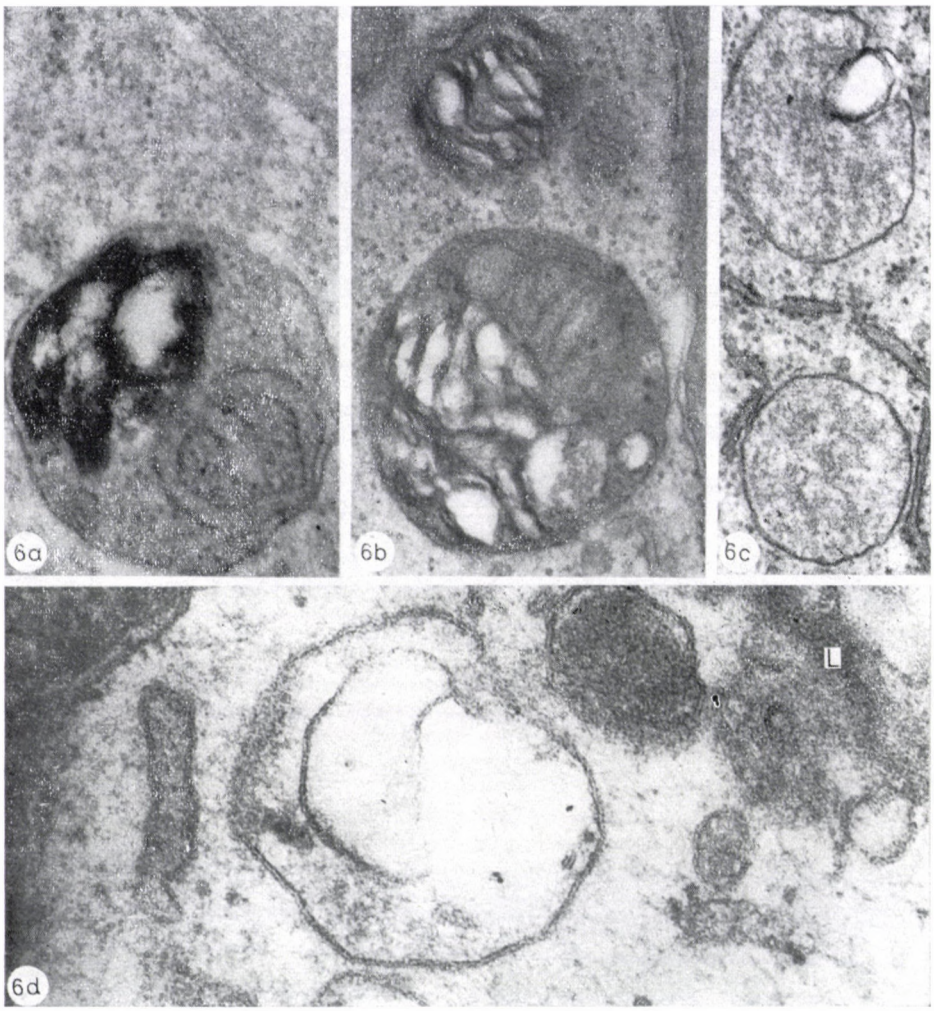

Abb. 6a. Verdichtetes Plasma, rauhes endoplasmatisches Retikulum und Lipidsubstanz im Zytolysosom. Siemens I. A. ×48 000
Abb. 6b. Zytolysosom mit lipidartigem und mitochondrialem Inhalt. Siemens I. A. ×48 000
Abb. 6c. Vakuolen mit flockigem Histiozytenplasmainhalt. Siemens I. A. ×48 000
Abb. 6d. Die dickwandigen Vakuolen enthalten häufig Membranteilchen und dichtes feingranuliertes Material. Verschmelzung der Vakuolen mit den über einen identischen granulären Inhalt verfügenden Lipidkörpern (L). Siemens I. A. ×80 000

Laut Volk und Wallace (1966) sowie Wallace und Mitarb. (1966) sind die Speicherungskörper der Leber lysosomalen Ursprungs. Lynn und Terry (1964) hielten dagegen bei Niemann-Pickscher Krankheit bei Erwachsenen weder den mitochondrialen noch den lysosomalen Ursprung für wahrscheinlich. Die saure Phosphatase-Aktivität der Speicherungskörper ist — wie darauf die Untersuchungen von Terry (1963) hingewiesen haben — außer-

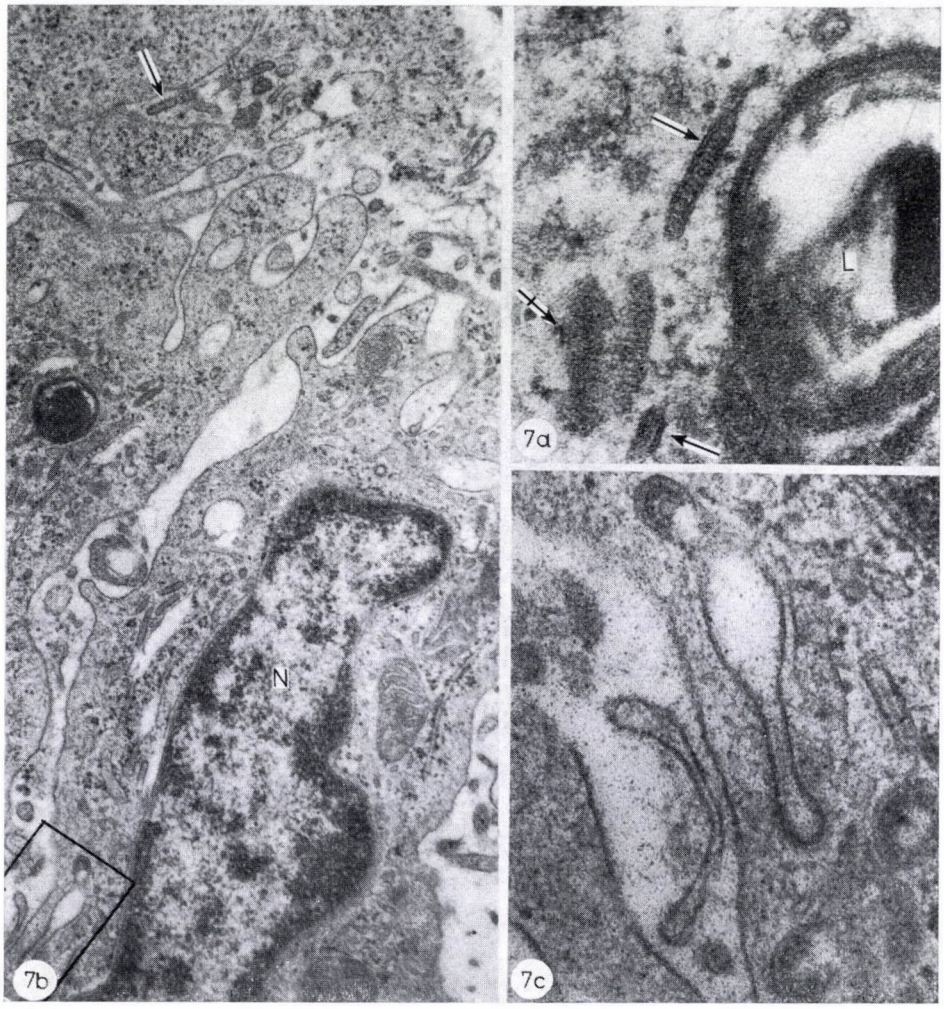

Abb. 7a. Quer- (↑) und Flachschnitt (↕) von Langerhansschen Körpern und ein Lipidkörper (L) im Histiozytenplasma. Die Länge der dargestellten Partikeln beträgt 0,3 μ, die Breite macht 500 Å aus. Die begrenzende dreischichtige Membran besitzt eine Dicke von 100 Å, die Periodizität der Querstreifung beträgt 130 Å. Siemens I. A. ×80 000

Abb. 7b. Zahlreiche stabförmige Organellen im Plasma der benachbarten Histiozyten. Oben eine extrazelluläre Organelle (↑). Der eingerahmte Abschnitt in Abb. 7c. Nucleus (n). Siemens I. A. ×24 000

Abb. 7c. Ein, an einem Ende tennisschlägerartig aufgeblähtes Gebilde in Verbindung mit einem 1300 Å großen, durch eine doppelte Membran umgrenzten Rundkörper. In der Mitte des schmalen Teiles verlaufen in einem Abstand von 100 Å nebeneinander zwei, keine Querstreifung aufweisende 30 Å dicke Linien. Rechts unten eine runde und eine C-förmige Struktur (die letzterwähnte Partikel hat sich vermutlich aus veränderten glatten endoplasmatischen Retikula gebildet). Siemens I. A. ×80 000

ordentlich gering. Die von Ross und Mitarb. (1961) beschriebenen Übergangsformen bis zur Entwicklung der Lipofuscin-Residualkörper, vermochten wir in unserem Fall nicht vorzufinden. Anhand der Beobachtung, daß sämtliche Mitochondrien gewisse Schädigungen aufweisen, vertraten die letzterwähnten Verfasser und auch David (1967) die Ansicht, daß die Speicherung in den Mitochondrien beginnt. Die Mitochondrien waren zwar auch in unserem Material lädiert, außerdem ließ sich in den Histiozyten eine sich von den mäßig geschädigten Mitochondrien bis zu den Lipidkörpern erstreckende formalgenetische Reihe zusammenstellen, wegen der Aldehydfixierung (wobei die mit den Mitochondrien verbundenen Myelinkörper im Vergleich zu dem ausschließlich mit Osmium fixierten Material häufiger vorkommen) haben wir aber diese Veränderungen nicht eindeutig, als die ersten Zeichen der Speicherung betrachtet (Pick, 1967; Ericson und Bibenfeld, 1967). Die beschriebenen Degenerationsformen der Mitochondrien und die Myelinfiguren kommen häufig auch bei hypoxischen Zellveränderungen vor (Bade und Schumacher, 1964; Ericson und Glinsmann, 1965; Glinsmann und Ericson, 1966; Pick, 1967; Richter und Mitarb., 1967). In den retikulohistiozytären Elementen der Milz und der Lymphknoten, vor allem in den Mitochondrien kommt es bekanntlich häufig zur Vermehrung endogener und exogener Substanzen (Gabler, 1960; Hirosawa, 1968; Watanuki und Mitarb., 1969). Schaffer und Bassler (1966) vermochten in den Gaucherschen Zellen das Ineinanderschmelzen der äußeren und inneren Mitochondrienmembranen sowie Protrusionsbildung zu beobachten.

Die Zytolysosombildung, welche sich in den hypoxischen oder toxisch geschädigten Zellen bekanntlich regelmäßig abspielt (Hruban und Mitarb., 1963; David, 1968), meldet sich offensichtlich in den stoffwechselaktiven Histiozyten am intensivsten. In den späteren Stadien umwandeln sich diese Gebilde aller Wahrscheinlichkeit nach in Lipideinschlüsse mit einer lamellarkörnigen Struktur.

Die Speicherung der Glattmuskelzellen der Gefäßwand weist entweder auf eine pathologische Lipidsynthese oder auf die Phagozytose der Zellen (Buck, 1962; Parker und Odland, 1966; Weiss, 1968).

Die von uns bei Niemann-Pickscher Krankheit beobachteten Gebilde mit stabförmigem Querschnitt wurden zuerst von Birbeck und Mitarb. (1961) als Langerhanssche Körper beschrieben, und zwar haben die erwähnten Verfasser diese Formationen in den intensiv eiweißsynthetisierenden Langerhansschen Zellen der menschlichen Haut beobachtet. Basset und Turiaf (1965), die diese Organellen bei Histiocytose X in Lungen- und Knochenläsionen vorfanden, erwogen die Möglichkeit in bezug auf ihre eventuelle virusartige Eigenart. Während Cancilla und Mitarb. (1967), Hüttner und Mitarb. (1968), Schöngut und Mitarb. (1968) die erwähnten Gebilde im eosinophilen Granulom bzw. in den Histiozyten der durch Letterer-Sivesche Krankheit bedingten

Hautläsionen nachwiesen, fanden OLÁH und Mitarb. (1968) in den — annehmbar epidermalen — Zellen des Rattenthymus ähnliche Strukturen. Die von RÖHLICH und TÖRŐ (1965) in den Endothelzellen des Lebersinus und den Retikulumzellen der Lymphknoten beobachteten Partikel zeigten eine ähnliche Struktur wie die von uns beobachteten, der Größenordnung nach wichen sie jedoch von diesen ab. Die von uns vorgefundenen Organellen waren im Vergleich zu den in der Literatur beschriebenen etwas kleiner, außerdem schienen sie eher mit dem glatten endoplastischen Retikulum sowie mit der umgewandelten Form desselben, den 1300—1800 Å großen, doppelwandigen Gebilden im Zusammenhang zu stehen als mit der Zellmembran. Von strukturellem Standpunkt aus stimmen manche der von uns beobachteten Partikel mit dem von SAGEBIEL und REED (1968) hergestellten Dreidimensionsmodell nicht überein. Obwohl zwischen den Langerhansschen Körpern und den über eine ebenso dicke dreischichtige Membran und einen flockigen Inhalt verfügenden Vakuolen kein direkter Übergang nachzuweisen ist, dürfte anhand der Identität der Dicke der Grenzmembran die eventuelle Verwandtschaft der beiden Gebilde erwogen werden. Damit im Zusammenhang könnte angenommen werden, daß die ungewöhnlich gestalteten Langerhansschen Körper einerseits an der Lipidspeicherung teilnehmen, andererseits die ausdrucksvollen Zeichen der gesteigerten Aktivität der Histiozyten sind. Auch das wäre möglich, daß einzelne extrazelluläre Langerhanssche Körper — den extrazellulären Lipidkörpern und Mitochondrien ähnlich — aus Zellzerfall stammen.

WATANUKI und Mitarb. (1969) haben bei Mäusen im Kern der phagozytierenden Histiozyten intranukleare Gebilde mit feingranulierter Struktur beobachtet. Die in unserem Fall vorgefunden Kerneinschlüsse waren jedoch mit einer Membran umgeben und verfügten über einen flockigen Inhalt. Unseres Erachtens wäre es möglich, daß diese Gebilde nebst den zahlreichen, auf allgemeine Stoffwechselstörung weisenden Veränderungen die Zeichen einer Eiweißretention im Kern sind.

Abb. 8a. Atypische endoplasmatische Retikulumformationen im Histiozytenplasma: brillen-, ring- und C-förmige Strukturen. Siemens I. A. ×80 000

Abb. 8b. Vakuole mit feinflockigem Inhalt im Histiozytenkern. Mehrere Perichromatingranula (↑). Siemens I. A. ×80 000

Abb. 8c. Demarkationsartige Zytolysosombildung im Histiozytenfortsatz mit verdichtetem ribosomenreichem Plasma. Siemens I. A. ×00

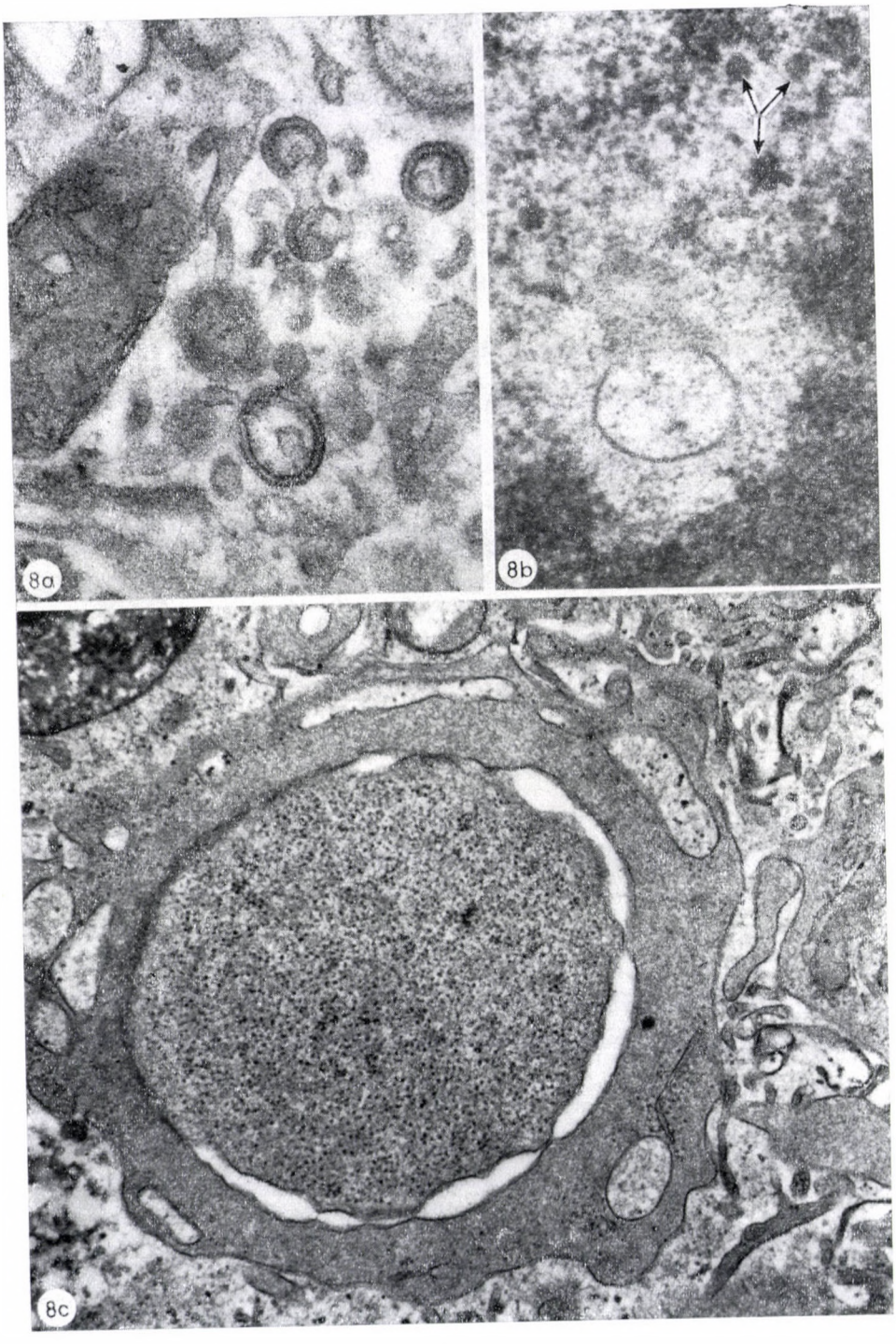
8a
8b
8c

LITERATUR

1. BADE, E. G., SCHUMACHER, A.: (1964) Veränderungen der submikroskopischen Struktur der Leberzellen der Maus nach temporärer Ischämie. Frankfurt. Z. Path. **74,** 29—45. — 2. BÁLINT, J. A., NYHAN, W. L., LIEMAN, P., TURNER, D. A.: (1961) Lipid Patterns in Niemann-Pick Disease. J. Lab. clin. Med. **58,** 548—558. — 3. BIRBECK, M. S., BREATNACH, A. S., EVERALL, J. S.: (1961) An Electron Microscope Study of Basal Melanocytes and High-level Clear Cells (Langerhans Cells) in Vitiligo. J. invest. Derm. **37,** 51—58. — 4. BUCK, R. C.: (1962) Lesions in the Rabbit Aorta Produced by Feeding a High Cholesterol Diet Followed by a Normal Diet. An Electron Microscopic Study. Brit. J. exp. Path. **43,** 236—240. — 5. CANCILLA, P. A., LAHEY, M. E., CARNES, W. H.: (1967) Cutaneous Lesions of Letterer-Siwe Disease. Cancer Res. **20,** 1986—1991. — 6. CASPER, J., WOLMAN, M.: (1964) Demonstration of Myelin Figures by Fluorescence in Some Pathologic Tissues. Lab. Invest. **13,** 27—31. — 7. DAVID, H.: Veränderungen bei Speicherungskrankheiten. In: Elektronmikroskopische Organpathologie. 464—465. Verlag Volk und Gesundheit. Berlin, 1967. — 8. DAVID, H.: (1968) Das Schicksal von Ribosomen, Polysomen und granulären endoplasmatischen Retikulum in Cytolysomen. Exp. Path. **2,** 57—69. — 9. DIEZEL, P. B.: (1954) Histochemische Untersuchungen an primären Lipoidosen: Amaurotische Idiotie, Gargoylismus, Niemann-Pick'sche Krankheit, Gaucher'sche Krankheit, mit besonderer Berücksichtigung des Zentralnervensystems. Virchows Arch. path. Anat. **326,** 89—118. — 10. ERICSSON, J. L. E., GLINSMANN, W. H.: (1965) Electron Microscopic Observations on Focal Degenerative Cytoplasmic Alteration in Liver Cells Induced by Hypoxia. Acta path. microbiol. scand. **64,** 151—152. — 11. ERICSSON, J. L. E., BIBERFELD, P.: (1967) Studies on Aldehyde Fixation. Fixation Rates and Their Relation to Fine Structure and Some Histochemical Reactions in Liver. Lab. Invest. **17,** 281—298. — 12. FEYRTER, F.: (1962) Über die Unterschiedlichkeit der Speicherzellen beim Morbus Niemann-Pick. Frankfurt. Z. Path. **71,** 474—484. — 13. GABLER, G.: (1960) Über die Transformation des Chondrions bei Speicherung makromolekularer Stoffe (Dextran, Periston). Elektronenmikroskopische Untersuchung an Reticuloendothel des Rattenmilz. Virchows Arch. path. Anat. **333,** 230—240. — 14. GÁLFI, I., BATA, G., IMHOF, S.: (1967) Niemann-Picksche Krankheit bei einem 11 1/2 Jahre alten Knaben. Acta Paediat. Acad. Sci. hung. **8,** 355—362. — 15. GLINSMANN, W. H., ERICSSON, J. L. E.: (1966) Observations on the Subcellular Organisation of Hepatic Parenchymal Cells II. Evolution of Reversible Alterations Induced by Hypoxia. Lab. Invest. **15,** 762—777. — 16. HIROSAWA, K.: (1968) Electron Microscopic Studies on Pigment Granules in the Substantia nigra and Locus coeruleus of the Japanese Monkey Macaca fuscate yakui. Z. Zellforsch. **88,** 187—203. — 17. HOLT, S. J., HICKS, R. M.: (1961) Studies on Formalin Fixation for Electron Microscopy and Cytochemical Staining Purposes. J. Biophys. biochem. Cytol. **11,** 31—34. — 18. HRUBAN, Z., SPARGO, B., SWIFT, H., WISSLER, R. W.: (1963) Focal Cytoplasmic Degradation. Amer. J. Path. **42,** 657—683. — 19. HÜTTNER, I., KÁDÁR, A., SCHÖNGUT, L., BASSET, F., CSERHÁTI, E.: (1968) Sajátos ultrastructuralis képletek Letterer-Siwe kór bőr-laesiojában. Morph. Ig. Orv. Szle, **8,** 1—10. — 20. KING, D. W.: Ultrastructural Aspect of Diseases. Hoebert Medical Division. Harper and Row. New York. 1966. — 21. KLENK, E.: (1934) Über die Natur der Phosphatide der Milz bei der Niemann-Pick'schen Krankheit. Hoppe-Seilers Z. physiol. Chem. **229,** 151—156. — 22. LAZARUS, S. S., VERHAMANY, V. G., SCHNECK, L., VOLK, B. W.: (1967) Fine Structure and Histochemistry of Peripheral Blood Cells in Niemann-Pick Disease. Lab. Invest. **17,** 155—170. — 23. LYNN, R., TERRY, R. D.: (1964) Lipid Histochemistry and Electron Microscopy in Adult Niemann-Pick Disease. Amer. J. Med. **37,** 987—994. — 24. MCCUSKER, J. J., PARSONS, D. B.: (1962) Niemann-Pick Disease. Report of Two Cases in Siblings Including the Necropsy and Histochemical Findings in One. Arch. Path. **74,** 127—136. — 25. MILLONIG, G.: Further Observations on a Phosphate Puffer for Osmium Solutions in Fixation. In: Symposion on Electron Microscopy. Philadelphia, 1962. Ed. Breese S. S. Jr., Academic Press, New York. — 26. OLÁH, I., DUNAY, Cs., RÖHLICH, P., TÖRŐ, I.: (1968) A Special Type of Cells in the Medulla of the Rat Thymus. Acta biol. Acad. Sci. hung. **19,** 97. — 27. PARKER, F., ODLAND, D. F.: (1966) A Correlative Histochemical, Biochemical and Electron Microscope Study of Experimental Atherosclerosis in the Rabbit Aorta with Special Reference to the Myo-intimal Cell. Amer. J. Path. **48,** 197—240. — 28. PHILIPPART, M., MARTIN, L., MARTIN, J. J., MENKES, J. H.: (1959) Niemann-Pick Disease. Morphologic and Biochemical Studies in the Visceral Form with Late Central Nervous System Involvement. (Crockers group C). Arch. Neurol. **20,** 227—238. — 29. PICK, J.: (1967) Pigment, Abnormal Mitochondrie and Laminar Bodies in Human Sympathetic Neurons. An Electron Microscopical Study. Z. Zellforsch. **82,** 118—135. — 30. REYNOLDS, E. S.: (1963) The Use of Lead Citrate at High pH as an Electron-opaque Stain in Electron-Microscope. J. Cell Biol. **17,** 208. — 31. RICHTER, L., TORHOST, U., ROHR, P. H.: (1967) Entstehungsmöglichkeiten intrazellulärer Myelinfiguren. Elektronenmikroskopische Untersuchung am Modell des proximalen Tubulus nach Phen-

acetinbelastung. Frankfurt. Z. Path. **77,** 363—370. — 32. ROMHÁNYI, J., PODER, GY., KERÉNYI, T.: Niemann-Picksche Krankheit in einem Säugling. Acta Paediat. Acad. Sci. hung. 1969. (In press). — 33. ROOS, B., COTTIER, H., ROSSI, E.: (1961) Elektronmikroskopische Beobachtungen bei Speicherkrankheiten. Pathol. Microbiol. **24,** 278—279. — 34. ROSSIER, A., CALDERS, R., SARRUT, S.: (1959) Un signe pathognomique de la maladie de Niemann-Pick les lymphocytes vacuolés. Arch. franc. Pédiat. **16,** 1358—1361. — 35. RÖHLICH, P., TÖRŐ, I.: (1965) Uptake of Phylomicron Particles by Reticular Cells of Mesenterial Lymph Nodes of the Rat. In: Electron Microscopy. Proceedings of the European Regional Conference held in Prague. Vol. B. 225. — 36. SAGEBIEL, R. W., REED, T. H.: Serial Reconstruction of the Characteristic Granule of the Langerhans Cell. J. Cell Biol. **36,** 595—602. — 37. SCHÄFER, A., BÄSSLER, R.: (1966) Elektronmikroskopische Beobachtungen bei Morbus Gaucher. Zbl. allg. Path. path. Anat. **109,** 444. — 38. SCHÖNGUT, L., KÁDÁR, A., HÜTTNER, I., BASSET, F., CSERHÁTI, E.: (1968) Données ultrastructurales nouvelles dans l'histiocytese »X«. Acta Paediat. Acad. Sci. hung. **9,** 11—15. — 39. STEJSKAL, J., STEJSKALOVÁ, A., PAZDERKA, V.: (1966) Storage Reticuloses. Neoplasma (Bratisl.) **13,** 489—500. — 40. STOCKENIUS, W.: (1959) Electron Microscope Study of Myelin Figures. J. Biophys. biochem. Cytol. **5,** 491—500. — 41. STOCKENIUS, W.: (1962) Some Electron Microscopic Observations on Lipidcrystalline Phases in Lipid Water Systems. J. Cell Biol. **12,** 221—229. — 42. TERRY, R. D.: (1963) The Fine Structure of Lipoidosis. Bull. N. Y. Acad. Med. **39,** 606—609. — 43. TÖRŐ, I. JR., JOÓ, F.: (1966) An Aldehyde Mixture as a Fixative for the Preservation of Both Fine Structure and Acid Phosphatase Activity. I. Advantage of the Method for Block Incubation. Acta biol. Acad. Sci. hung. **17,** 265—279. — 44. VOLK, B. W., WALLACE, B. J.: (1966) The Liver in Lipidosis. An Electron Microscopic and Histochemical Study. Amer. J. Path. **49,** 203—225. — 45. WALLACE, B. J., VOLK, B. W., SCHNECK, L., KAPLAN, H.: (1966) Fine Structural Localization of Two Hydrolytic Enzymes in the Cerebellum of Children with Lipidoses. J. Neuropath. exp. Neurol. **25,** 76—96. — 46. WATANUKI, T., MIURA, A. B., KOIZUMI, K.: (1969) Elektronmikroskopische und enzymhistochemische Untersuchungen über den morphologischen Unterschied zwischen Retikulumzellen und Sinusendothelien des Mäuselymphknotens. Virchows Arch. path. Anat. **346,** 130—153. — 47. WEISS, P.: (1968) Submikroskopische Charakteristik und Reaktionsformen der glatten Muskelzelle unter besonderer Berücksichtigung der Gefäßwandmuskelzelle. Z. mikr.-anat. Forsch. **78,** 305—331.

OBSERVATIONS ON THE ULTRASTRUKTURE OF LYMPH NODES IN NIEMANN-PICK DISEASE

T. KERÉNYI, J. ROMHÁNYI and GY. PÓDER

Histological and electron microscopic studies were performed on the storage cells of a subcutaneous lymph node from a 9 months old girl, suffering from Niemann-Pick disease. Fibrosis could not be observed in the lymph node, the structure was retained, several storage cells could be detected however in the area of the lymphatic sinus.

Electron microscopic examinations revealed storage in different cell types, thus in histiocytes, reticular cells, endothelial cells, in the smooth muscle cells of the blood vessels, in lymphoblast cells and lymphocytes. The hydration and structure of the stored material appeared to be different in the individual cell types. Degeneration of the mitochondria, lysosome formation, atypical cell organelles and changes of the nuclei were seen in the histiocytes. Characteristic particles, observed by certain authors in the Langerhans cells of human skin and in histiocytosis X, were also present besides the above mentioned alterations.

ДАННЫЕ К УЛЬТРАСТРУКТУРЕ ЛИМФАТИЧЕСКИХ УЗЛОВ ПРИ БОЛЕЗНИ НИМАНА-ПИКА

Т. КЕРЕНИ, Й. РОМХАНИ и Д. ПОДЕР

У 9-месячной девочки, страдавшей болезнью Нимана-Пика проводилось гистологическое и электронномикроскопическое исследование фагодитрарных клеток подкожного лимфатического узла. В лимфатическом узле фиброз не мог быть выявлен, структура была

сохранена, но в окрестности лимфатического узла наблюдалось несколько фагоцитарных клеток. Электронномикроскопическим путем можно было в различных клеточных образованиях — гистоцитах, ретикулярных клетках, эндотелиальных клетках, гладкомышечных клетках кровеносных сосудов, в лимфобластах и лимфоцитах — выявить накопление. Структура накопившегося вещества в различных типах клеток была различная. В гистоцитах имели место перерождение митохондриев, образование цитосом, атипичные клеточные органеллы и изменения ядра. Помимо приведенных изменений наблюдались своеобразные частицы, которые некоторыми авторами были раньше обнаружены в клетках Лангерганса человеческой кожи и при гистоцитозе X.

Dr. Tibor KERÉNYI: II. Kórbonctani Intézet, Budapest IX. Üllői út 93., Hungary und Abt. f. Elektronenmikroskopie d. Path. Inst. d. Humboldt-Universität, Berlin, DDR

Dr. József ROMHÁNYI, Dr. Georg PODER: I. Gyermekklinika, Budapest VIII. Bókay János u. 53., Hungary

RECENSIO

Prof. Dr. Béla KELLNER: **Die Ausbreitung des Krebses. Invasion und Metastasierung.** Akadémiai Kiadó, Budapest 1971. Gemeinschaftsausgabe des Akadémiai Kiadó Budapest mit dem Verlag Urban und Schwarzenberg. München—Berlin—Wien. 333 pages, 128 partly coloured figures and 29 tables.

Everybody interested in tumour pathology will enjoy this book. In the introduction it is emphasized that the problem of metastasis formation is still quite often discussed on the basis of some 19th century theories. The considerable recent progress in the field of therapy of primary tumours renders increasingly necessary to develop a modern approach to the study of pathogenesis and mechanism of metastasis formation.

This book by Professor Kellner has the advantages of both a textbook and a monograph. It presents in a most concise manner the body of generally accepted facts on metastases, reviews the relevant literature, discusses the results of his own studies, and gives his views on the problems in question. The short introduction is followed by a survey of the development of our knowledge on metastasis formation. A whole chapter is devoted to the phenomenon of "Ablösung" i.e. separation of tumour cells from the primary tumour, together with the theory of embolic-dissemination. Factors involved in the process of "Ablösung" viz. ameboidal movement of tumour cells, low calcium content of the tumour tissue, the phenomenon of permeation and so called Zwergzellen are reviewed. Comments are made on the possible role of infection in metastasis formation. In this chapter he presents his own theory of metastasis formation. He supposes "disjunction" separation of tumour cells from the primary tumour to be a consequence of necrobiotic processes in the growing tumour. This would explain the appearance of early pericarcinomatous metastases in the immediate neighbourhood of the primary tumour. The different forms of disjunction are presented and illustrated with a series of excellent light microscopic photographs and electron micrographs. Interactions between the tumour and the surrounding normal tissue are reviewed. The different views on the most fundamental biological feature of tumours, the infiltrative growth are also considered and richly illustrated.

Further chapters deal with another basic process of metastasis formation viz. the penetration into, and dissemination through the lymph and blood vessels. A survey of premetastatic changes of lymph nodes and the different types of metastases is given and the relation of morphologic changes of lymph nodes and the immunobiological state of the tumourous organism is discussed. The morphology, behaviour and fate of tumour cells in the blood stream are considered separately on the basis of the author's experimental findings. A large chapter is devoted to the third fundamental phenomenon, the settling down of liberated and circulation transported tumour cells at a new site — so called Ansiedlung. The earliest morphological alterations caused by the settled tumour cells are shown in a series of highly informative figures. The origin and further fate of two- and multinucleated tumour cells are discussed in detail. Their importance in metastasis formation has been demonstrated by the author and his coworkers.

The essentially theoretical chapters are followed by one on the clinico-pathology of the metastasis formation. The problem of metastasis formation by implantation is treated separately. The chapter entitled "Die Entwicklung der Geschwulst im Hinblick auf Metastasierung" is of special importance, since it reflects most clearly the author's dynamic concept on the development of precancerous conditions. His ideas and views are based on several decades' work in the field of pathology and experimental cancer research.

The chapter devoted to the discussion of the kinetics of metastatic growth appears

to me as one of the most valuable parts of this book. It also contains a survey of the possible ways to quantitate the kinetics of metastasis formation. A separate chapter is devoted to the relatives of morphology and biology of the primary tumour and its metastases. The chapter "Attempts to influence experimentally the formation of metastases" contains a broad review of the relevant data. Further, the classic and new diagnostic methods for the demonstration of metastases are discussed. The chapter dealing with the grading of malignancy of tumours on a histological basis is of considerable practical importance. The last chapter entitled "Prophylaxis and Therapy of Metastases" contains the recent results of experimental and clinical studies evaluated on the basis of literary data and the author's own views. The basic principles of a possible rational therapy are outlined. This chapter has been written with extreme care. To my opinion, however, the author seems to be too cautious and sceptical in evaluating achievements in the prophylaxis and therapy of metastases.

I think, that with some minor modifications part of the 24 chapter could have been more concise or even be melted into eachother. This might be considered if a new edition would later be planned.

Tables and figures in black and white are of excellent quality—this is unfortunately not true for the colour plates. The list of references is rich and includes both eastern and western authors.

Undoubtedly this book will be used extensively by scientists working in the fields of experimental cancer research and clinical oncology. It is likely to become a classic book on tumour pathology.

Dr. K. LAPIS

INDEX

Morphologia normalis et experimentalis

Lázár, Gy: The Projection of the Retinal Quadrants on the Optic Centres in the Frog; a Terminal Degeneration Study 325

Veress, B.—Baintner, jr. K.: Absorption of Colostrum in the Rat and the Cat: A Comparative Electron Microscopic Study 335

Somogyi, E.—Varga, T.—Sótonyi, P.—Solti, F.—Szabó, Z.—Rényi-Vámos, F.—Földes, I.—Várkonyi, S.: Effect of Immunosuppressive Agents on the Tissue Reaction around the Pacemaker Electrode 349

Somogyi, E.—Varga, T.: Functional and Morphological Changes of the Liver Induced by Electric Shock 363

Papp, M.—Nagy, Z.—Fodor, I.: Ultrastructure of Pancreatic Acinar Parenchyma in Acute Experimental Pancreatitis of the Pigeon 377

Srebro, Z.—Cichocki, T.—Godula, J.: Peroxidase Activity in Glia and Ependymocytes of the Mouse Brain 389

Pathologia

Lapis, K.—Radnót, M.: The Fine Structure of Mast Cells in the Tumours of Protecting Organs of the Eye 397

Kerényi, T.—Romhányi, J.—Poder, G.: Lymphknotenultrastruktur bei Niemann-Pickscher Krankheit 417

Recensio 433

Printed in Hungary

A kiadásért felel az Akadémiai Kiadó igazgatója — Műszaki szerkesztő: Várhelyi Tamás

A kézirat nyomdába érkezett: 1971. XII. 14. — Terjedelem: 9,75 (A/5) ív, 76 ábra

71.72831 Akadémiai Nyomda, Budapest — Felelős vezető: Bernát György

The Acta Morphologica publish papers on experimental medical subjects in English, French, German and Russian.

The Acta Morphologica appear in parts of varying size, making up volumes.

Manuscripts should be addressed to:

Acta Morphologica, Budapest IX., Tűzoltó u. 58.

Correspondence with the editors and publishers should be sent to the same address.

The rate of subscription is $ 16.00 per volume.

Orders may be placed with "Kultúra" Foreign Trade Company for Books and Newspapers (Budapest I., Fő utca 32. Account No. 43-790-057-181) or with representatives abroad.

Les Acta Morphologica paraissent en français, allemand, anglais et russe et publient des travaux du domaine des sciences médicales expérimentales.

Les Acta Morphologica sont publiés sous forme de fascicules qui seront réunis en volumes.

On est prié d'envoyer les manuscrits destinés à la rédaction à l'adresse suivante:

Acta Morphologica, Budapest IX., Tűzoltó u. 58.

Toute correspondance doit être envoyée à cette même adresse.

Le prix de l'abonnement est de $ 16.00 par volume.

On peut s'abonner à l'Entreprise du Commerce Extérieur de Livres et Journaux «Kultúra» (Budapest I., Fő utca 32. Compte-courant № 43-790-057-181) ou à l'étranger chez tous les représentants ou dépositaires.

«Acta Morphologica» публикуют трактаты из области экспериментальных медицинских наук на русском, немецком, английском и французском языках.

«Acta Morphologica» выходят отдельными выпусками разного объема. Несколько выпусков составляют один том.

Предназначенные для публикации авторские рукописи следует направлять по адресу:

Acta Morphologica, Budapest IX., Tűzoltó u. 58.

По этому же адресу направлять всякую корреспонденцию для редакции и администрации. Подписная цена — $ 16.00 за том.

Заказы принимает предприятие по внешней торговле книг и газет «Kultúra» (Budapest I., Fő utca 32. Текущий счет № 43-790-057-181) или его заграничные представительства и уполномоченные.

Reviews of the Hungarian Academy of Sciences are obtainable at the following addresses:

ALBANIA
Drejtorija Qëndrone e Përhapjes dhe Propagandimit të Librit
Kruga Konferenca e Pazes
Tirana

AUSTRALIA
A. Keesing
Box 4886, GPO
Sydney

AUSTRIA
GLOBUS
Höchstädtplatz 3
A — 1200 Wien XX

BELGIUM
Office International de Librairie
30, Avenue Marnix
Bruxelles 5
Du Monde Entier
5, Place St. Jean
Bruxelles

BULGARIA
HEMUS
11 pl Slaveikov
Sofia

CANADA
Pannonia Books
2, Spadina Road
Toronto 4, Ont.

CHINA
Waiwen Shudian
Peking
P. O. B. 88

CZECHOSLOVAKIA
Artia
Ve Směčkách 30
Praha 2
Poštovní Novinová Služba
Dovoz tisku
Vinohradská 46
Praha 2
Mad'arská Kultura
Václavské nám. 2
Praha 1
SLOVART A. G.
Gorkého
Bratislava

DENMARK
Ejnar Munksgaard
Nörregade 6
Copenhagen

FINLAND
Akateeminen Kirjakauppa
Keskuskatu 2
Helsinki

FRANCE
Office International de Documentation de Librairie
48 rue Gay-Lussac
Paris 5

GERMAN DEMOCRATIC REPUBLIC
Deutscher Buch-Export und Import
Leninstraße 16
Leipzig 701
Zeitungsvertriebsam.
Fruchtstraße 3—4
1004 Berlin

GERMAN FEDERAL REPUBLIC
Kunst und Wissen
Erich Bieber
Postfach 46
7 Stuttgart S.

GREAT BRITAIN
Blackwell's Periodicals
Oxenford House
Magdalen Street
Oxford
Collet's Subscription Import Department
Dennington Estate
Wellingborough, Northants.
Robert Maxwell and Co. Ltd.
4 — 5 Fitzroy Square
London W. 1

HOLLAND
Swetz and Zeitlinger
Keizersgracht 471—487
Amsterdam C.
Martinus Nijhof
Lange Voorhout 9
The Hague

INDIA
Hind Book House
66 Babar Road
New Delhi 1

ITALY
Santo Vanasia
Via M. Macchi 71
Milano
Libreria Commissionaria Sansoni
Via La Marmora 45
Firenze
Techna
Via Cesi 16.
40135 Bologna

JAPAN
Kinokuniya Book-Store Co. Ltd.
826 Tsunohazu 1-chome
Shinjuku-ku
Tokyo
Maruzen and Co. Ltd.
P. O. Box 605
Tokyo-Central

KOREA
Chulpanmul
Phenjan

NORWAY
Tanum-Cammermeyer
Karl Johansgt 41 — 43
Oslo 1

POLAND
RUCH
ul. Wronia 23
Warszawa

ROUMANIA
Cartimex
Str. Aristide Briand 14—18
Bucureşti

SOVIET UNION
Mezhdunarodnaya Kniga
Moscow G—200

SWEDEN
Almquist and Wiksel
Gamla Brogatan 26
S—101 20 Stockholm

USA
F. W. Faxon Co. Inc.
15 Southwest Park
Westwood Mass. 02070
Stechert Hafner Inc.
31. East 10th Street
New York, N. Y. 10003

VIETNAM
Xunhasaba
19, Tran Quoc Toan
Hanoi

YUGOSLAVIA
Forum
Vojvode Mišića bro
Novi Sad
Jugoslovenska Knjiga
Terazije 27
Beograd

15. VI. 1972

Index: 26.017